

Tumor Infiltrating Cytotoxic CD8 T-Cells Predict Clinical Outcome of Neuroblastoma in Children

Abstract

Context: Neuroblastoma is often infiltrated by inflammatory cells, particularly macrophages and T lymphocytes, but the significance of these cells remains unclear. One possible role of these inflammatory cells is that they represent a cell-mediated immune response against cancer. CD8+ lymphocytes are a known crucial component of cell-mediated immunity. The purpose of this study was to explore the prognostic value of tumor-infiltrating CD8+ cytotoxic lymphocytes in Neuroblastoma. **Subjects and Methods:** Tumor-infiltrating CD8+ lymphocytes were assessed by immunohistochemical staining of tumor tissue from 36 neuroblastoma from April 2008 to May 2015. The number of CD8+ T-cells was counted in tumor nest (intratumoral) and in the fibrovascular stroma of tumor (peritumoral), and their relationship with clinicopathologic outcome was determined. **Results:** The total number of CD8+ cells was inversely correlated with tumor histology grade ($P < 0.001$), vascular invasion ($P < 0.001$), capsular invasion ($P < 0.002$), calcification ($P < 0.005$), necrosis of tumor ($P < 0.001$), regional lymph nodes invasion ($P < 0.003$), distant metastasis ($P < 0.003$), stage ($P < 0.003$), and was positive correlated with N-myc oncogene presentation ($P < 0.002$) in neuroblastoma. However, there were no correlation between patient's age, sex, and size of tumor with infiltration of CD8+ cells ($P < 0.097$, $P < 0.142$, and $P < 0.722$, respectively). **Conclusions:** In this analysis, total CD8 T-cell count was a dependent prognostic factor in children. Total number and stromal CD8 lymphocytes were associated with better patient survival ($P < 0.003$ and $P < 0.05$, respectively) in children. These results suggest that tumor-infiltrating CD8 T lymphocytes have antitumor activity and influence the behavior of neuroblastoma and might be potentially be exploited in the treatment of neuroblastoma in children.

Keywords: Children, cytotoxic CD8 lymphocyte, neuroblastoma, outcome

Introduction

Dramatic improvements in survival have been achieved for children and adolescents with cancer.^[1] Between 1975 and 2010, childhood cancer mortality decreased by more than 50%.^[1-3] For neuroblastoma, the 5-year survival rate increased over the same time, from 86% to 95% for children younger than 1 year and from 34% to 68% for children aged 1–14 years.^[2] Childhood and adolescent cancer survivors require close monitoring because cancer therapy side effects may persist or develop months or years after treatment. Numerous innate and adaptive immune effector cells and molecules participate in the recognition and destruction of cancer cells, a process that is known as cancer immunosurveillance.^[4-6] immune system's natural capacity to detect and destroy abnormal cells may prevent the development of many cancers.

However, cancer cells are sometimes able to avoid detection and destruction by the immune system. Cancer cells may reduce the expression of tumor antigens on their surface, making it harder for the immune system to detect them, express proteins on their surface that induce immune cell inactivation and induce cells in the surrounding environment (microenvironment) to release substances that suppress immune responses and promote tumor cell proliferation and survival.^[6] In the past few years, the rapidly advancing field of cancer immunology has produced several new methods of treating cancer, called immunotherapies that increase the strength of immune responses against tumors. Immunotherapies either stimulate the activities of specific components of the immune system or counteract signals produced by cancer cells that suppress immune responses. The present study was designed to analyze CD8+ T-cells in

This is an open access article distributed under the terms of the Creative Commons Attribution-NonCommercial-ShareAlike 3.0 License, which allows others to remix, tweak, and build upon the work non-commercially, as long as the author is credited and the new creations are licensed under the identical terms.

For reprints contact: reprints@medknow.com

How to cite this article: Rahbar M, Mehrazma M, Karimian M. Tumor infiltrating cytotoxic CD8 T-Cells predict clinical outcome of neuroblastoma in children. *Indian J Med Paediatr Oncol* 2018;39:159-64.

Mahtab Rahbar,
Mitra Mehrazma,
Mersedeh Karimian

Department of Pathology, Iran
University of Medical Science,
Tehran, Iran

Address for correspondence:
Dr. Mahtab Rahbar,
Iran Medical Science
University, Tehran, Iran.
E-mail: rahbarahbar@gmail.com

Access this article online

Website: www.ijmpo.org

DOI: 10.4103/ijmpo.ijmpo_78_17

Quick Response Code:



neuroblastoma, which showed that CD8+ T-cells infiltrated into cancer cell nests could reflect antitumor immunity. The various T-cell subsets infiltrating neuroblastoma is limited to a few studies conducted on a small number of specimens and show different types of immune cells infiltrating neuroblastoma. Some authors identified populations of CD4+ and CD8+ T-cells in NB, and others show CD25+ T-cells or cells with effector memory phenotype in NB.^[7,8] However, it is still unclear whether the presence of CD8+ cytotoxic lymphocytes provides any prognostic information in childhood neuroblastoma. Therefore, the aim was to analyze the influence of density and distribution of CD8+ cytotoxic lymphocytes on patient prognosis in well-characterized series of children with neuroblastoma during about 5 years follow-up.

Subjects and Methods

We retrospectively analyzed 36 children with neuroblastoma in Iran medical Science University (Ali Asghar hospital) between April 2008 and May 2015. The minimum follow-up period for every individual case was set to be 18 months. Informed consent was obtained from every patient's parent to be involved in the study. We have excluded the patients with immunosuppressive problems or who suffered from chronic background disease. None of these patients received preoperative immunotherapy. The age of patients ranged from 2 to 108 months of age (mean, 43 months). They were 22 males (61%) and 14 females (39%) and male: female ratio was 1.6. The patients received complete resection of the tumor with regional lymph node dissection. Resected specimens were fixed in formalin and embedded in paraffin for the routine histopathological diagnosis. Data included demographic parameters: age, gender, and also histopathology data: tumor size, histology pattern, mitosis-karyorrhexis index (MKI) index, capsular invasion, vascular invasion, necrosis, calcification, stage and finally, N-myc amplification of each tumor were extracted of files. Disease-free survival (DFS) was defined as the time interval from the date of diagnosis to the date of first relapse/progression, or the date of the last follow-up for surviving patients.

Immunohistochemistry

Formaldehyde-fixed paraffin-embedded blocks were cut into 6 μm sections for immunohistochemical staining. At first, samples were deparaffinized and subjected to heat-induced antigen retrieval using EnVision FLEX Target retrieval solution at low- or high-pH (citrate buffer pH 6.1 and Tris/EDTA pH 9.0, respectively) at 96°C for 15 min with PT-link (Dako). For single staining, the avidin/biotin blocking system (Thermo Fisher Scientific, Fremont, CA, USA) was used according to the manufacturer's instructions (DakoCytomation, Glostrup, Denmark, USA). Tissue sections were incubated (60 min at room temperature) with monoclonal antibodies against CD8 (clone C8/144B, dilution 1:100) followed by incubation with streptavidin-alkaline phosphatase (Dako).

Bound streptavidin was detected with Fast Red chromogen substrate (Dako) and levamisole in the reaction mixture for 10 min at room temperature. Sections of normal tonsils were used as positive controls of immunohistochemistry staining of CD8+ lymphocytes which are distributed mainly in the paracortical lymphoid tissue of tonsil.

Manual and digital microscope acquisition

The digital microscope used for real-time slide browsing and workflow control from remote workstations. Furthermore, two pathologists counted total numbers of CD8+ T lymphocytes each tumor core in two compartments: in nest and peritumoral fibrovascular stroma using a Nikon Eclipse 80i microscope (Nikon, Tokyo, Japan). The density of CD8 lymphocyte in the peritumoral fibrovascular stroma (peritumoral location) and in nests of tumoral cells (nest location) were recorded by two-blinded examiners as the number of positive cells per unit tissue surface area (mm^2) which is defined the density of tumor cells. For statistical analysis, the logarithm of the mean density of three fields for each sample was used. We semiquantitatively scored the degrees of infiltration into four groups as follows: 0, nil; I, mild; II, moderate; and III, severe. CD8+ T-cells were counted in two compartments in each tumor: in nest location and in peritumoral location. The total number of CD8+ T-cells was determined by combining the counts for the two locations. The average numbers of 0, 1–19, 20–49, and over 50 were scored as 0, I, II, and III, respectively. Scores were also rechecked randomly by a second observer. Interobserver agreement was found ($\kappa = 0.69$).

Statistical analysis

We quantified or semi-quantified each variable as described above and then made correlation with the patients' clinical outcome with Pearson's Chi-squared method for each variable and using computer Software SPSS Version 16.0 (Chicago, SPSS Inc). We judged correlation significant with Fisher's exact test, crosstab, one-way ANOVA, and then reported *P* value for correlation effects of each variable.

Results

We retrospectively analyzed 36 children with neuroblastoma to investigate the relationship between the type, density, and location of CD8 T-cells within neuroblastoma lesions and the clinical outcome of patients; we performed *in situ* immunohistochemical analysis in 36 neuroblastoma samples about 7-year follow-up data. The age of patients ranged from 5 to 108 months of age (mean, 43 months). They were 22 males (61%) and 14 females (39%) and the male: female ratio was 1.6. The density of total T lymphocytes (CD8+) quantified in tumor cell nests and peritumoral fibrovascular stroma ranged from samples with prominent infiltrates in cohort study, to others with no infiltration [Figure 1a-c].

Representative density of CD8+ T-cells in neuroblastoma samples. CD8+ T-cells (brown) and tumor cells (blue)

are shown in septa (1a) and in nest (1b) and perivascular regions (1c). The density of CD8+ T-cells was recorded as the number of positive cells per unit of tissue surface area (Original magnification $\times 200$) [Figure 1a-c]

DFS, from the date of diagnosis to the date of first relapse/progression, or the date of the last follow-up was performed by stratifying the subjects according to score value for CD8+ T-cell density [Figure 2a and b]. The density of CD8+ T-cells in both locations was significantly correlated with patient outcome.

Kaplan–Meier curves show the DFS of patients according to the CD8+ T-cell density scale in the septa (2a) and nest (2b) tumor regions [Figure 2a and b].

We found that total density of CD8+ cells in two location, intratumoral nest, and peritumoral fibrovascular stroma were inversely correlated with tumor histology degree ($P < 0.001$, according to the International Neuroblastoma Pathology Classification [INPC]), vascular invasion ($P < 0.001$), stage ($P < 0.003$, according to the International Neuroblastoma Staging System [INSS]), MKI Index ($P < 0.002$), capsular invasion ($P < 0.003$), vascular invasion ($P < 0.005$), regional lymph node invasion ($P < 0.002$), percentage of necrosis in tumor ($P < 0.001$), calcification of tumor ($P < 0.005$) and was positive correlated with N-myc oncogene presentation ($P < 0.002$) in neuroblastoma. However, there were no correlation between patient's age, sex, and size of tumor with total number of CD8+ cells ($P < 0.097$, $P < 0.142$, and $P < 0.722$, respectively). According to these results, we investigated how to combine analysis of density, and location of immune cells in the tumoral nest and peritumoral fibrovascular stroma could improve DFS. We found that a higher density of CD8+ T-cells was associated with a

favorable histology ($P < 0.001$) and low staging ($P < 0.003$) and finally a favorable prognosis with the better clinical outcome [Table 1]. DFS represents inverse correlation with peritumoral CD8+ T-cell infiltration ($P < 0.005$) and also DFS and tumor regression represents positive correlation with intratumoral nest and peritumoral fibrovascular stroma of CD8+ T-cell infiltration ($P < 0.002$ and $P < 0.001$, respectively). According to these results, we can claim that these immunological criteria could be associated with the better clinical outcome and finally, the proliferative activity of CD8+ T-cells in tumor could have an important role in antitumor immunity [Table 2].

Scoring of CD8+ T lymphocytic infiltration in the different locations in neuroblastoma of children ($n = 36$). infiltrating lymphocyte in nest of the tumor, infiltrating lymphocyte in the fibrovascular stroma of tumor [Table 1].

Clinicopathologic characteristics and distribution of CD8+ intratumoral lymphocytes in the study population (INPC), INSS, tumor-infiltrating lymphocyte, total score (TIL [ts]).

Discussion

Herein, we provide new insight into the density and strategic location of tumor-infiltrating CD8 T-cells in neuroblastoma and their association with clinical outcome. We found that a strong infiltration of CD8+ T-cells is significantly associated with better DFS. Most importantly, we showed that CD8+ T-cell infiltration is an independent prognostic factor and improves the prediction of the clinical outcome when combined with the well-established positive N-myc marker. Intriguingly, we found that neuroblastomas with favorable outcome were characterized by a more structured CD8+ T-cell infiltration, which was gradually lost in tumors with poor prognosis. The more density of proliferating CD8+ T-cells in low-risk neuroblastoma reflects the key role of these cells in the spontaneous tumor regression. This hypothesis is supported by a series of dated observations including the strong T-cell infiltration in well-differentiated neuroblastoma and show a significant correlation between lymphocytic infiltration and particularly

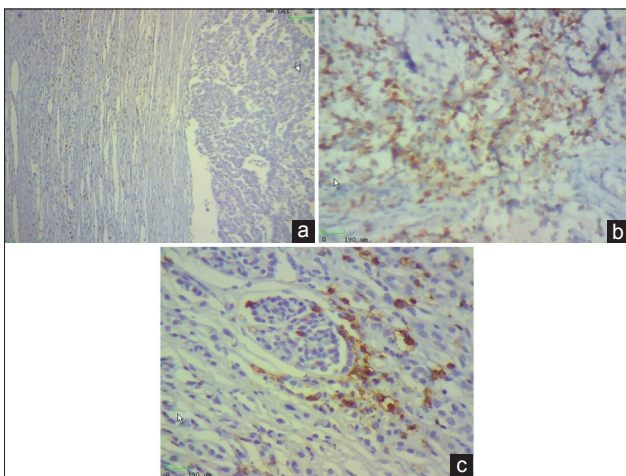


Figure 1: Representative density of CD8+ T-cells in neuroblastoma samples. CD8+ T-cells (brown) and tumor cells (blue) are shown in septa (a) Representative density of CD8+ T-cells in neuroblastoma samples. CD8+ T-cells (brown) and tumor cells (blue) are shown in nest (b) Representative density of CD8+ T-cells in neuroblastoma samples. CD8+ T-cells (brown) and tumor cells (blue) are shown peri vascular regions (c)

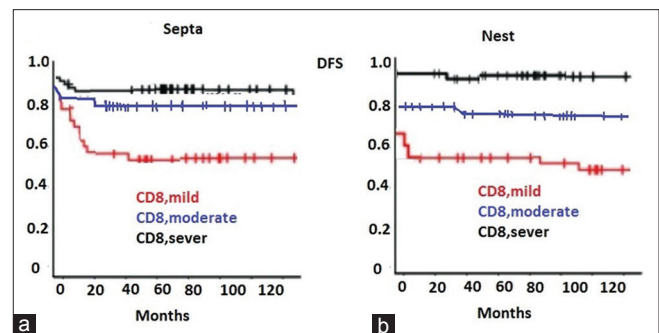


Figure 2: Kaplan–Meier curves show the disease-free survival of patients according to the CD8+ T-cell density scale in the septa (a) Kaplan–Meier curves show the disease-free survival of patients according to the CD8+ T-cell density scale in nest (b) tumor regions

Table 1: Scoring of CD8+ T lymphocytic infiltration in the different locations in neuroblastoma of children (n = 36)

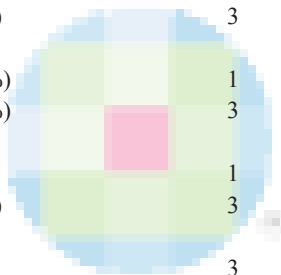
Patient	Tumor Stage	Tumor Grade	IL (nest)				IL (stroma)			
			0	I	II	III	0	I	II	III
1	II	Favorable			+				+	
2	II	Favorable			+					+
3	II	unFavorable	+						+	
4	III	Favorable	+						+	
5	II	Favorable			+					+
6	II	Favorable			+				+	
7	I	Favorable				+				+
8	IV	unFavorable	+					+		
9	II	Favorable			+			+		
10	I	Favorable			+				+	
11	II	Favorable			+				+	
12	II	Favorable			+			+		
13	III	Favorable	+					+		
14	II	Favorable			+			+		
15	III	Favorable	+					+		
16	II	Favorable			+				+	
17	I	Favorable			+				+	
18	II	Favorable			+				+	
19	IV	unFavorable	+				+			
20	I	Favorable			+			+		
21	II	Favorable			+		+			
22	III	unFavorable			+		+			
23	I	Favorable			+			+		
24	I	Favorable			+				+	
25	IV	unFavorable	+				+			
26	III	unFavorable	+				+			
27	II	Favorable			+		+			
28	II	Favorable			+		+			
29	I	Favorable			+				+	
30	III	unFavorable	+				+			
31	I	Favorable			+				+	
32	IV	unFavorable	+				+			
33	II	Favorable			+				+	
34	III	Favorable	+				+			
35	I	Favorable			+				+	
36	II	Favorable			+				+	
Tumor Stage			<i>P</i> value<0.003							
Tumor Grade			<i>P</i> value<0.001							

with the duration of neuroblastoma survival,^[9-11] some findings support the hypothesis that infiltrating T-cells influence the behavior of neuroblastoma and distinct cytotoxicity against neuroblastoma cells of peripheral blood and TILs from patients with neuroblastoma might have important effect on the treatment of patients.^[1] In agreement with these observations, we found that tumors with different outcome displayed a different density of CD8+ T-cells lymphocyte: neuroblastomas with good prognosis were characterized by a higher number of proliferating T-cells in proximity to tumor cells.^[12] This picture clearly reflects a different functional state of infiltrating T-cells that

coincides with the amplification of N-myc in neuroblastoma cells. The most comprehensive clinical studies correlating tumor-infiltrating leukocytes with disease outcome have been performed in colorectal cancer, where the general conclusion has been that DFS is positively associated with a coordinated Th1/CD8+ T-cell infiltration.^[13] A similar result was reached for breast cancer.^[14,15] and for hepatocellular carcinoma, where NK markers and the chemokine's CCL2, CCL5, and CXCL10 were additional immune signatures predictive of patient survival (at early stages of the disease).^[16,17] Yang *et al.* show that in mice, overall survival of neuroblastoma increased if infiltration of NK and CD8+ T-cells by immunotherapy is associated with routine treatment initiation.^[18] A new approach to the adoptive immunotherapy of cancer with TILs has been claimed by another study.^[19] Seeger emphasis on more effective immunotherapeutic strategies on neuroblastoma that will be integrated with new cytotoxic drug and irradiation therapies to improve survival and quality of life for patients with high-risk neuroblastoma.^[20] Our data suggest that infusion of tumor-specific T-cells could induce long-lasting complete remission of aggressive neuroblastoma, as already demonstrated in long-term follow-up of melanoma patients.^[21] CD8+ T-cells may migrate into cancer cell nests, exhibiting a higher proliferation. The major histocompatibility complex (MHC) class I molecule required to be expressed by cancer cells for the recognition of cancer cells by T-cells which provides evidence in colorectal cancer cells.^[22] In cervical neoplasia, no clear correlation was reported between the expression of MHC class I molecules by neoplastic cells and infiltration of CD8+ T-cells into the neoplastic tissue.^[23] In previous studies, it was believed that TILs in melanoma can represent the immune reaction/response to melanocyte which is measured by the level of lymphocytic infiltrate present at the base of the vertical growth phase of the tumor and is sometimes categorized as brisk, no brisk, or absent.^[24] The most brisk TILs response is found in thin tumors.^[25] The 5- and 10-year survival rates for melanoma with a vertical growth phase and a brisk infiltrate were 77% and 55%, respectively. For tumors with a no brisk infiltrate, the 5- and 10-year survival rates were 53% and 45%, respectively, and for tumors with absent TILs, the 5-and 10-year survival rates were 37% and 27%, respectively.^[25] There is a need for a uniform definition of host response in terms of type and location of infiltrate before the role of TILs can be clarified. TILs could be an important new therapy for melanoma.^[26,27] The study results suggest that the cell-mediated immune reaction has an important role in the outcome of neuroblastoma, as described in other tumor types such as colorectal carcinoma.^[22] As previously described, CD8+ T-cell count was correlated with a higher histologic grade in colon cancer and this mechanism results that tumor escape from immune-mediated destruction. Our results, however, suggest that the adaptive immune response plays a role in preventing tumor invasion in

Table 2: Clinicopathologic characteristics and distribution of CD8+ intratumoral lymphocytes in the study population

Characteristics	%Patients	iTIL mean score	sTIL mean score	P
Age at diagnosis, months				0.097
< 18	12 (33.5%)	1	1	
≥18 months and <5 years	18 (50%)	3	2	
≥5 years	6 (16.5%)	2	1	
Sex				0.142
Male	22 (61%)	2	2	
Female	14 (39%)	2	1	
Tumor size (cm)				0.722
≤2	5 (14%)	2	1	
>2-5	16 (44.5%)	3	2	
>5	15 (41.5%)	2	2	
Grade (INPC)				0.001
Favorable Histopathology	28 (77.5%)	2	1	
Unfavorable Histopathology	8 (22.5%)	1	2	
Nodal status				0.002
Positive	11 (30%)	1	2	
Negative	25 (70%)	3	2	
Lymph vascular invasion				0.005
Present	22 (61%)	1	2	
Not present	14 (39%)	3	2	
Capsular invasion				0.003
Present	11 (30%)	1	1	
Not present	25 (70%)	3	2	
Tumoral Necrosis				0.001
Present	10 (27.5%)	1	1	
Not present	26 (72.5%)	3	2	
Distant Metastasis				0.002
Present	4 (11%)	1	1	
Not present	32 (89%)	3	2	
Stage (INSS)				0.003
I	9 (25%)	3	2	
II	16 (44.5%)	2	2	
III	7 (19.5%)	1	1	
IV	4 (11%)	0	1	
N-myc oncogene				0.002
Present	30 (83%)	1	2	
Not present	6 (17%)	3	1	
Tumor Regression				0.001
Present	4 (11%)	0	1	
Not present	32 (89%)	3	2	



children. When the tumor is clinically apparent, the proposed tumor-associated factors (possibly the antigenic determinants or danger signals) and inflammatory elements may provide an efficient adaptive immune reaction that averts tumor progression. The tumor might not stimulate an immune response in the early stages, perhaps because of a lack of danger signals. It is generally believed that antitumor immune responses are focused in the draining lymph nodes.^[22] Our observations, however, suggest that this could also occur in the tumor site. Despite the presence of a lymphocytic infiltrate in breast cancer, complete regression of breast cancer is extremely rare. Moreover, the fact that a tumor is present at all and its continued growth despite

the presence of cytotoxic CD8 lymphocytes imply that the host immune response is not completely successful.^[28] Mina *et al.* defined an immunoscore based on the presence of CD3+, CD4+, and CD8+ infiltrating T-cells that associates with favorable clinical outcome in MYCN-amplified tumors, improving patient survival when combined with the v-myc avian myelocytomatosis viral oncogene neuroblastoma derived homolog (MYCN) status.^[29]

Limitations of the study

The limitations are a small sample size ($n = 36$) and a single hospital-based study. It is a retrospective study which makes it difficult to ascertain the accuracy and reliability

of the information collected and to obtain information on potential confounding variables.

Conclusions

This study investigates the prognostic significance of tumor-infiltrating CD8+ T-cells in a fairly numerous collection of neuroblastoma patients. The information presented here might be useful in the clinical management of neuroblastoma with potential impact on patient outcome. In conclusion, this study provides strong evidence that CD8+ lymphocyte infiltration is an independent factor associated with improved free survival in patients with primary neuroblastoma. This suggests that cytotoxic T-cells have clinically significant antitumor activity against neuroblastic tumor cells. The results of this study support further investigation of this line of potential therapeutic intervention.

Financial support and sponsorship

Nil.

Conflicts of interest

There are no conflicts of interest.

References

- Howlader N, Noone AM, Krapcho M, Garshell J, Neyman N, Altekruse SF, *et al.*, (eds). SEER Cancer Statistics Review, 1975-2010, Section 29. Bethesda, MD: National Cancer Institute; 2013.
- Smith MA, Altekruse SF, Adamson PC, Reaman GH, Seibel NL. Declining childhood and adolescent cancer mortality. *Cancer* 2014;120:2497-506.
- Howlader N, Noone AM, Krapcho M, Garshell J, Miller D, Altekruse SF, *et al.*, (eds). SEER Cancer Statistics Review, 1975-2012, Bethesda, MD: National Cancer Institute; 2014.
- Dunn GP, Old LJ, Schreiber RD. The immunobiology of cancer immunosurveillance and immunoeediting. *Immunity* 2004;21:137-48.
- Kim R, Emi M, Tanabe K. Cancer immunoeediting from immune surveillance to immune escape. *Immunology* 2007;121:1-14.
- Demaria S, Pikarsky E, Karin M, Coussens LM, Chen YC, El-Omar EM, *et al.* Cancer and inflammation: Promise for biologic therapy. *J Immunother* 2010;33:335-51.
- Facchetti P, Prigione I, Ghiotto F, Tasso P, Garaventa A, Pistoia V, *et al.* Functional and molecular characterization of tumour-infiltrating lymphocytes and clones thereof from a major-histocompatibility-complex-negative human tumour: Neuroblastoma. *Cancer Immunol Immunother* 1996;42:170-8.
- Carlson LM, De Geer A, Sveinbjornsson B, Orrego A, Martinsson T, Kogner P, *et al.* The microenvironment of human neuroblastoma supports the activation of tumor-associated T lymphocytes. *Oncoimmunology* 2013;2:e23618.
- Martin RF, Beckwith JB. Lymphoid infiltrates in neuroblastomas: Their occurrence and prognostic significance. *J Pediatr Surg* 1968;3:161-4.
- Squire R, Fowler CL, Brooks SP, Rich GA, Cooney DR. The relationship of class I MHC antigen expression to stage IV-S disease and survival in neuroblastoma. *J Pediatr Surg* 1990;25:381-6.
- Valteau D, Scott V, Carcelain G, Hartmann O, Escudier B, Hercend T, *et al.* T-cell receptor repertoire in neuroblastoma patients. *Cancer Res* 1996;56:362-9.
- Mina M, Boldrini R, Citti A, Romania P, D'Alicandro V, De Ioris M, *et al.* Tumor-infiltrating T lymphocytes improve clinical outcome of therapy-resistant neuroblastoma. *Oncoimmunology* 2015;4:e1019981.
- Fridman WH, Mlecnik B, Bindea G, Pagès F, Galon J. Immunosurveillance in human non-viral cancers. *Curr Opin Immunol* 2011;23:272-8.
- Martinet L, Garrido I, Filleron T, Le Guellec S, Bellard E, Fournie JJ, *et al.* Human solid tumors contain high endothelial venules: Association with T- and B-lymphocyte infiltration and favorable prognosis in breast cancer. *Cancer Res* 2011;71:5678-87.
- Ladoire S, Arnould L, Mignot G, Apetoh L, Rébé C, Martin F, *et al.* T-bet expression in intratumoral lymphoid structures after neoadjuvant trastuzumab plus docetaxel for HER2-overexpressing breast carcinoma predicts survival. *Br J Cancer* 2011;105:366-71.
- Chew V, Chen J, Lee D, Loh E, Lee J, Lim KH, *et al.* Chemokine-driven lymphocyte infiltration: An early intratumoural event determining long-term survival in resectable hepatocellular carcinoma. *Gut* 2012;61:427-38.
- Laça T, Silva-Santos B. The split nature of tumor-infiltrating leukocytes: Implications for cancer surveillance and immunotherapy. *Oncoimmunology* 2012;1:717-25.
- Yang RK, Kalogiropoulos NA, Rakhmilevich AL, Ranheim EA, Seo S, Kim K, *et al.* Smaller neuroblastoma tumors in mice intratumorally treated with Hu14.18-IL2 have more activated tumor-infiltrating lymphocytes and better outcome. *Cancer Immunol Immunother* 2013;62:1303-13.
- Rosenberg SA, Spiess P, Lafreniere R. A new approach to the adoptive immunotherapy of cancer with tumor-infiltrating lymphocytes. *Science* 1986;233:1318-21.
- Seeger RC. Immunology and immunotherapy of neuroblastoma. *Semin Cancer Biol* 2011;21:229-37.
- Hinrichs CS, Rosenberg SA. Exploiting the curative potential of adoptive T-cell therapy for cancer. *Immunol Rev* 2014;257:56-71.
- Mlecnik B, Tosolini M, Kirilovsky A, Berger A, Bindea G, Meatchi T, *et al.* Histopathologic-based prognostic factors of colorectal cancers are associated with the state of the local immune reaction. *J Clin Oncol* 2011;29:610-8.
- Angevin E, Kremer F, Gaudin C, Hercend T, Triebel F. Analysis of T-cell immune response in renal cell carcinoma: Polarization to type 1-like differentiation pattern, clonal T-cell expansion and tumor-specific cytotoxicity. *Int J Cancer* 1997;72:431-40.
- Elder DE, Guerry D 4th, VanHorn M, Hurwitz S, Zehngbot L, Goldman LI, *et al.* The role of lymph node dissection for clinical stage I malignant melanoma of intermediate thickness (1.51-3.99 mm). *Cancer* 1985;56:413-8.
- Mihm MC Jr, Clemente CG, Cascinelli N. Tumor infiltrating lymphocytes in lymph node melanoma metastases: A histopathologic prognostic indicator and an expression of local immune response. *Lab Invest* 1996;74:43-7.
- Rosenberg SA, Dudley ME. Cancer regression in patients with metastatic melanoma after the transfer of autologous antitumor lymphocytes. *Proc Natl Acad Sci U S A* 2004;101 Suppl 2:14639-45.
- Rosenberg SA, Yannelli JR, Yang JC, Topalian SL, Schwartzentruber DJ, Weber JS, *et al.* Treatment of patients with metastatic melanoma with autologous tumor-infiltrating lymphocytes and interleukin 2. *J Natl Cancer Inst* 1994;86:1159-66.
- Stewart TH, Heppner GH. Immunological enhancement of breast cancer. *Parasitology* 1997;115 Suppl:S141-53.
- Mina M, Boldrini R, Citti A, Romania P, D'Alicandro V, De Ioris M, *et al.* Tumor-infiltrating T lymphocytes improve clinical outcome of therapy-resistant neuroblastoma. *Oncoimmunology* 2015;4:e1019981.