

(289)

COPYRIGHT 2018 © BY THE ARCHIVES OF BONE AND JOINT SURGERY

**RESEARCH ARTICLE**

# Different References for Valgus Cut Angle in Total Knee Arthroplasty

Hamidreza Yazdi, MD; Ara Nazarian, DrSc; Jim S Wu, MD; Arash Amiri, MD; Poopak Hafezi, MD; Margaret Babikian, BA; Amin Mohamadi, MD; Reza Pakdaman, MD; Mohammad Ghorbanhoseini, MD

Research performed at Firoozgar Hospital, Tehran, Iran and BIDMC, Harvard Medical School, Boston, Massachusetts, USA

Received: 07 October 2017

Accepted: 04 March 2018

**Abstract**

**Background:** The valgus cut angle (VCA) of the distal femur in Total Knee Arthroplasty (TKA) is measured preoperatively on three-joint alignment radiographs. The anatomical axis of the femur can be described as the anatomical axis of the full length of the femur or as the anatomical axis of the distal half of the femur, which may result in different angles in some cases. During TKA, the anatomical axis of the femur is determined by intramedullary femoral guides, which may follow the distal half or near full anatomical axis, based on the length of the femoral guide. The aim of this study was to compare using the anatomical axis of the full length of the femur versus the anatomical axis of the distal half of the femur for measuring VCA, in normal and varus aligned femurs. We hypothesized that the VCA would be different based upon these two definitions of the anatomical axis of the femur.

**Methods:** Full-length weight bearing radiographs were used to determine three-joint alignment in normal aligned (Lateral Distal Femoral Angle; LDFA =  $87^\circ \pm 2^\circ$ ) and varus aligned (LDFA  $>89^\circ$ ) femurs. Full-length anatomical axis-mechanical axis angle (angle 1) and distal half anatomical axis-mechanical axis angle (angle 2) were measured in all subjects by two independent orthopedic surgeons using a DICOM viewer software (PACS). Angles 1 and 2 were compared in normal and varus aligned subjects to determine whether there was a significant difference.

**Results:** Ninety-seven consecutive subjects with normally aligned femurs and 97 consecutive subjects with varus aligned femurs were included in this study. In normally aligned femurs, the mean value of angle 1 was  $5.05^\circ \pm 0.76^\circ$  and for angle 2 was  $3.62^\circ \pm 1.19^\circ$ , which were statistically different ( $P=0.0001$ ). In varus aligned femurs, the mean value of angle 1 was  $5.42^\circ \pm 0.85^\circ$  and for angle 2 was  $4.23^\circ \pm 1.27^\circ$ , which were also statistically different ( $P=0.0047$ ).

**Conclusion:** The two different methods of outlining the anatomical axis of the femur lead to different results in both normal and varus-aligned femurs. This should be considered in determination of the valgus cut angle on pre-operative radiographs and be adjusted according to the length of the intramedullary guide.

**Level of evidence:** III

**Keywords:** Anatomical axis, Preoperative planning, Total Knee Arthroplasty, Valgus cut angle

**Introduction**

In total knee arthroplasty (TKA), normal alignment is important for favorable patient outcome (1). The valgus cut angle (VCA) of the distal femur is

determined based on the angle between the anatomical and mechanical axes of the femur. The mechanical axis is one of the most important factors determining

**Corresponding Author:** Mohammad Ghorbanhoseini, Tufts Medical Center, General Surgery Department, Boston, MA, USA  
Email: [dr\\_ghhoseini@yahoo.com](mailto:dr_ghhoseini@yahoo.com)



THE ONLINE VERSION OF THIS ARTICLE  
[ABJS.MUMS.AC.IR](http://ABJS.MUMS.AC.IR)

prognosis of surgery (2-5). Achieving normal knee alignment in the surgeries of the knee, such as TKA is crucial (5-8). VCA is measured on a three-joint alignment radiograph preoperatively. The anatomical axis of the femur can be outlined either by using the full length of the femur or by using the distal half of the femur, which may lead to different results (3). Several studies have shown that varus or valgus malalignment are associated with unfavorable outcomes after TKA (9-12). To reduce the failure rate of this procedure, normal mechanical balance in the joints must be restored (3). The aim of this study is to compare the VCA of distal femur determined by anatomical axis of the either full length or distal half of the femur in both normal and varus aligned femurs. We hypothesized that the VCA would be different based on these two definitions of the anatomical axis and this should be considered in pre-operative planning.

### Materials and Methods

Intitutional Review Board approval was obtained. From Jan 2011 to Dec 2013, 194 subjects were recruited from the outpatient clinic located in our university hospital. Patients with full length alignment view radiographs who met the inclusion criteria for this study were enrolled.

In order to determine the mechanical Lateral Distal Femoral Angle (mLDFA), the center of the femoral head was identified using the PACS software (Clear Canvas Workstation Version 2.0.12729.37986 SP1). Next, a line was drawn tangent to the articular surface of the femoral condyle, and another was drawn from the center of the femoral head to the deepest part of the intercondylar notch in the distal femur. The angle between intersection of these two lines is called mLDFA, which determines whether the femoral shaft is classified as normal, varus or valgus [Figure 1].

Femurs were categorized as normal if the mLDFA was between  $85^{\circ}$  to  $89^{\circ}$ , in varus if mLDFA was greater than  $89^{\circ}$  or in valgus if the mLDFA was less than  $85^{\circ}$ . Those with valgus femurs were excluded. Other exclusion criteria were deformity of the lower limb, previous surgery on the lower limb or presence of radiographic signs for osteoarthritis.

To outline the anatomical axis of the full length of the femur, a point equidistant from medial and lateral cortices of the femur, 1-3 cm distal to the lesser trochanter, was marked. Then a line was drawn from this point to the deepest point of the intercondylar notch, which created an angle between the mechanical and anatomical axes of the full length of the femur. We named it Angle 1 [Figure 2].

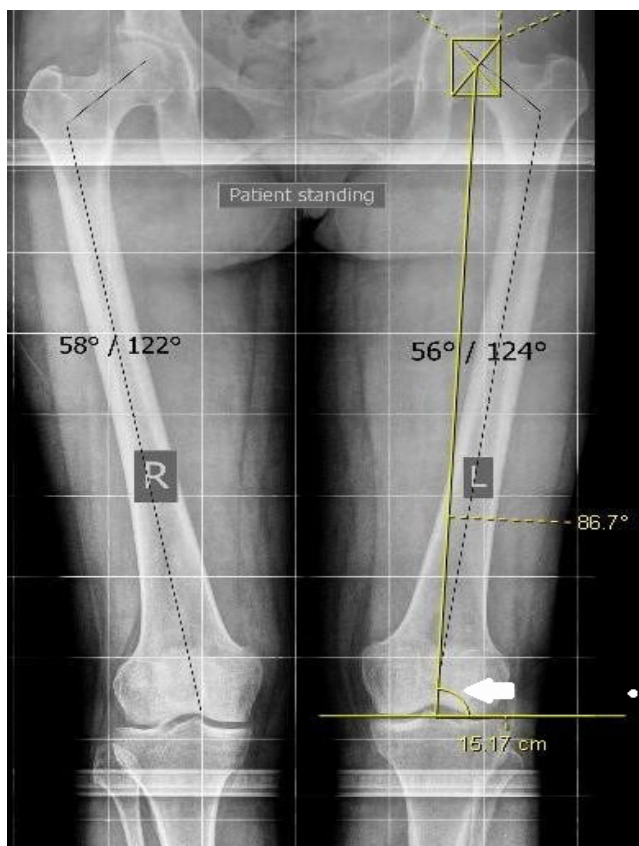


Figure 1. Mechanical - Lateral Distal Femoral Angle (mLDFA, white arrow).

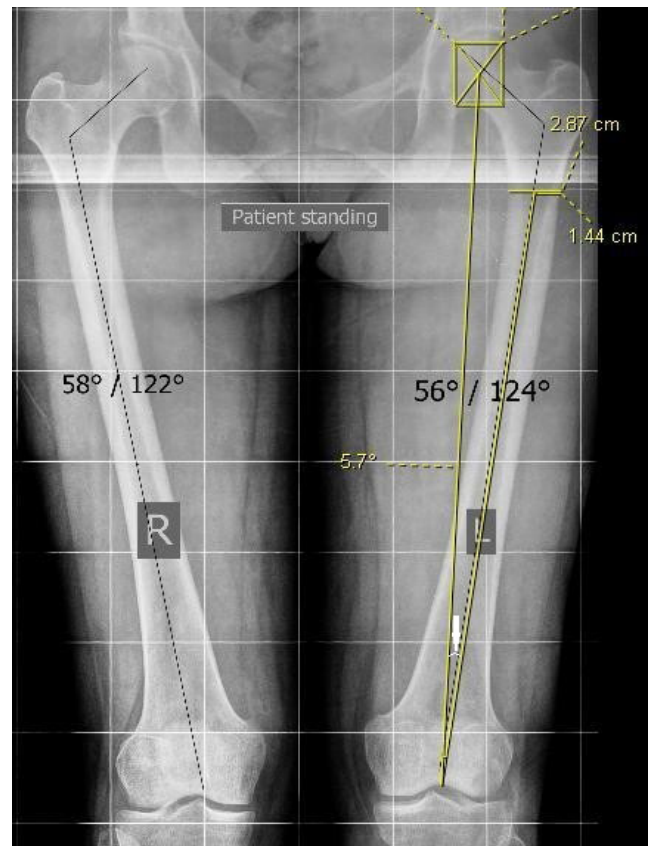


Figure 2. Angle between the mechanical axis of the femur and the anatomical axis of the full length of the femur (Angle 1, white arrow).

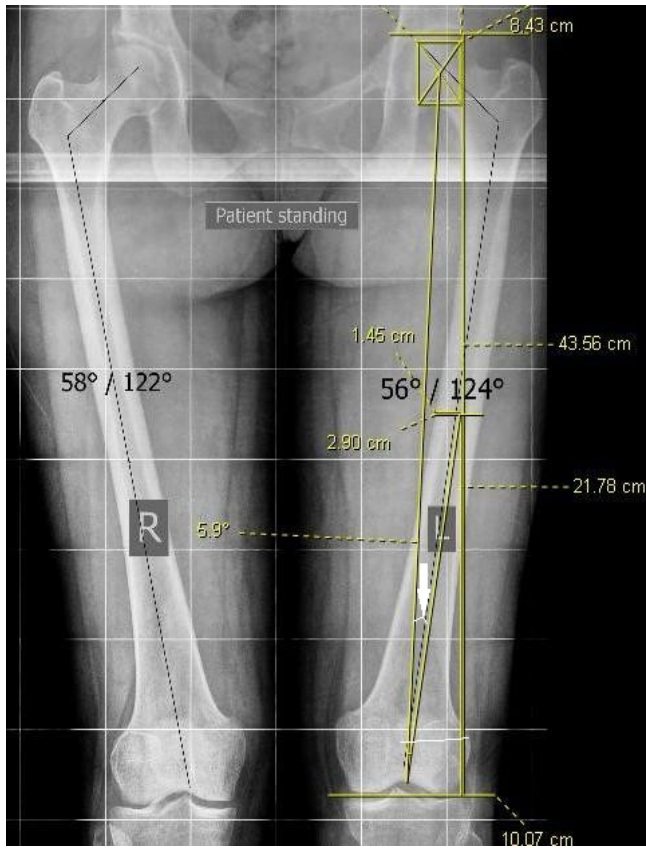


Figure 3. Angle between the mechanical axis of the femur and the anatomical axis of the distal half of the femur (Angle 2, white arrow).

To outline the angle between the mechanical axis of the femur and the anatomical axis of the distal half of the femur, which we named Angle 2, we marked the midway between the proximal femoral head to the most distal articular surface. At this level, we marked the point in the middle of medial and lateral cortices and then drew a line from this point to the deepest point of the intercondylar notch. This line represents the anatomical axis of the distal half of the femur. The angle between this line and the mechanical axis of femur was measured [Figure 3].

All measurements were performed by two orthopedic surgeons using a DICOM viewing software (PACS). Angles 1 and 2 were compared using t-test in normal and varus

aligned cases.

### Results

Ninety-seven consecutive subjects with normal and 97 consecutive subjects with varus aligned femurs were included in this study. The mean age was  $35.51 \pm 12.15$  years old (range: 18 to 65 years). 55.6% of the subjects were female (n=108) and 44.4% of the subjects were male (n=86).

The average lateral distal femoral angle (LDFA) in the normal femoral axis and the varus groups were  $87.54^\circ \pm 0.86^\circ$  and  $90.89^\circ \pm 0.88^\circ$  respectively. There was a significant difference in mean LDFA values between the normal and varus groups ( $P=0.001$ ). In the normal aligned femur group the mean values for angles 1 and 2 were  $5.05^\circ \pm 0.76^\circ$  and  $3.62^\circ \pm 1.19^\circ$  respectively, which were statistically significant ( $P=0.0001$ ). In the varus aligned femur group, the mean values of angles 1 and 2 were  $5.42^\circ \pm 0.85^\circ$  and  $4.23^\circ \pm 1.27^\circ$ , respectively, and the differences were significant as well ( $P=0.0047$ ). There was no correlation between angles 1 and 2 in relation to the length of the femur in patients with varus aligned femurs ( $P=0.50$ ) or for patients with normally aligned femoral axes ( $P=0.70$ ) [Table 1].

### Discussion

This study shows that utilizing either the anatomical axis of the full length of the femur or the anatomical axis of the distal half of the femur would result in different valgus cuts in TKA, in both normally aligned and varus femurs. The mean value of angle 1 (the angle between the mechanical axis of the femur and anatomical axis of the full length of the femur) was  $5.05^\circ \pm 0.76^\circ$  and the mean value of angle 2 (the angle between the mechanical axis of the femur and anatomical axis of the distal half of the femur) was  $3.62^\circ \pm 1.19^\circ$  in normal aligned femurs, which were statistically different ( $P=0.0001$ ). In varus aligned femurs, the mean value of angle 1 was  $5.42^\circ \pm 0.85^\circ$  and for angle 2 was  $4.23^\circ \pm 1.27^\circ$ , which were also different ( $P=0.0047$ ).

TKA systems use 2 types of intramedullary guide, short and long. The short guides follow the path of the anatomical axis of the distal half of the femur, which is different from the anatomical axis of the full length of the femur. So, it is crucial that the surgeons consider the system they are working with, and choose between the anatomical axis of the full length and the distal half of the femur according to the length of the intramedullary guide of the system they are using in pre-op planning.

Surgeons have utilized several ways to measure the

Table 1. Comparison between angle 1 and 2 in normal aligned and varus aligned femurs					
		Number of patients	Mean	SD	P value
Normal femurs	Angle 1	97	5.05	0.76	$P=0.0001$
	Angle 2	97	3.62	1.19	
Varus femurs	Angle 1	97	5.42	0.85	$P=0.0047$
	Angle 2	97	4.23	1.27	

**Table 2. Comparison of valgus cut angel in different studies**

		VCA* based on full anatomical axis (Degree ± SD)	VCA* based on distal half anatomical axis (Degree ± SD)	
<b>Moreland et al.</b>		5.8±0.7 (right)	4.0±0.7 (right)	<i>P</i> <0.001
		6.0±1.0 (left)	4.1±0.9 (left)	
<b>Oswald et al.</b>		5.9 ± 1.9	5.7 ± 1.8	<i>P</i> >0.05
<b>Present study</b>	Normal aligned femurs	5.05 ± 0.76	4.62 ± 1.19	0.0001
	Varus aligned femurs	5.42 ± 0.85	5.23 ± 1.27	0.04

\* Valgus cut angle

axial alignment of the lower extremity, especially in total knee arthroplasty pre-op planning (3). Generally in TKA, the valgus cut angle of distal femur is defined by the angle between mechanical and anatomical axes of the femur (13). The mechanical axis of the femur is a line drawn from the center of the femoral head to the center of the knee joint (14). However, for determining the anatomic axis of the femur a full-length or distal half axis can be used. Moreland et al introduced a method for measuring valgus knee angle, in which full-length femur is used for determination of anatomical axis of the femur (4). In this method, femoral anatomic axis I is defined as a line connecting femoral shaft center I, which itself is determined by bisecting the proximal-to-distal femur length and the mid-shaft medial-to-lateral femur width, with the center of the knee. Then, femoral shaft center II is determined 10 cm above the center of the knee, midway between the medial and lateral surfaces, and femoral anatomic axis II is defined by a line drawn between femoral shaft center I and II. In the second step, valgus angles I and II are separately formed by the intersection of the femoral anatomic axes I and II with the mechanical axis of the femur.

Oswald et al developed another method for measuring valgus cut angle using distal radiographs of the femur. In his method, mechanical axis of the femur is divided into three different anatomical axes, including distal femoral anatomical axis, central femoral anatomical axis and long femoral anatomical axis [Table 2] (10). The distal femoral anatomical axis is defined by connecting the midpoint of the cortical shaft 20 cm above the knee-joint line with the deepest point in the intercondylar notch. The central femoral anatomical axis is defined by connecting the midpoint of the cortical shaft at one-half of the femoral length with the midpoint of the cortical shaft 10 cm above the joint line. Finally, by connecting the midpoint of the cortical shaft at two-thirds of the femoral length with the midpoint of the cortical shaft at one-third of the femoral length, the long femoral anatomical axis is drawn. Oswald did not detect any statistical difference between these three angles (10).

In this study there were some limitations. We didn't include valgus knees. Also we didn't investigate the sagittal alignment of the limb which may have some effects. We think these 2 limitations should be addressed in future studies.

The distinctive aspects of this study compared to

Moreland et al and Oswald et al were the large number of subjects and including 2 separate populations with normal and varus aligned femurs. Another important difference between this study and previous similar studies was that we considered the deepest part of intercondylar notch as the reference point for anatomical axis. This point is the entry point of the intramedullary guide and is more relevant in pre-op and intra-operative planning rather than previous methods.

Based on this study, the two different measurements of anatomical axis of the femur lead to different results in both normal and varus-aligned femurs. This difference should be considered in determination of the valgus cut angle on pre-operative radiographs and be adjusted according to the length of used intramedullary guide intra operatively.

Hamidreza Yazdi MD

Arash Amiri MD

Department of knee Surgery, Firoozgar Hospital, Neuromusculoskeletal Research Center, Iran University of Medical Sciences, Tehran, Iran

Ara Nazarian DrSc

Margaret Babikian BA

Amin Mohamadi MD

Center for Advanced Orthopaedic Studies at BIDMC - Harvard Medical School, Boston, MA, USA

Jim S Wu MD

BIDMC, Harvard Medical School, Boston, MA, USA

Poopak Hafezi MD

McLean Hospital, Harvard Medical School, Boston, MA, USA

Reza Pakdaman MD

Department of Radiology, Brigham and Women's Hospital, Harvard Medical School, Boston, MA, USA

Mohammad Ghorbanhoseini MD

Tufts Medical Center, General Surgery Department, Boston, MA, USA



## References

1. Pabinger C, Berghold A, Boehler N, Labek G. Revision rates after knee replacement. Cumulative results from worldwide clinical studies versus joint registers. *Osteoarthritis Cartilage*. 2013; 21(2):263-8.
2. Insall JN, Kelly M. The total condylar prosthesis. *Clin Orthop Relat Res*. 1986; 205(1):43-8.
3. Hsu RW, Himeno S, Coventry MB, Chao EY. Normal axial alignment of the lower extremity and load-bearing distribution at the knee. *Clin Orthop Relat Res*. 1990; 255(1):215-27.
4. Moreland JR, Bassett LW, Hanker GJ. Radiographic analysis of the axial alignment of the lower extremity. *J Bone Joint Surg Am*. 1987; 69(5):745-9.
5. Jeffery RS, Morris RW, Denham RA. Coronal alignment after total knee replacement. *J Bone Joint Surg Br*. 1991; 73(5):709-14.
6. Bargren JH, Blaha JD, Freeman MA. Alignment in total knee arthroplasty. Correlated biomechanical and clinical observations. *Clin Orthop Relat Res*. 1983; 173(1):178-83.
7. Ritter MA, Faris PM, Keating EM, Meding JB. Postoperative alignment of total knee replacement. Its effect on survival. *Clin Orthop Relat Res*. 1994; 299(1):153-6.
8. Lotke PA, Ecker ML. Influence of positioning of prosthesis in total knee replacement. *J Bone Joint Surg Am*. 1977; 59(1):77-9.
9. Nagamine R, Kondo K, Ikemura S, Shiranita A, Nakashima S, Hara T, et al. Distal femoral cut perpendicular to the mechanical axis may induce varus instability in flexion in medial osteoarthritic knees with varus deformity in total knee arthroplasty: a pitfall of the navigation system. *J Orthop Sci*. 2004; 9(6):555-9.
10. Oswald MH, Jakob RP, Schneider E, Hoogewoud HM. Radiological analysis of normal axial alignment of femur and tibia in view of total knee arthroplasty. *J Arthroplasty*. 1993; 8(4):419-26.
11. Yousof Gomrokchi A, Yazdi H, Nazarian A, Hafezi P, Lechtig A, Hanna P, et al. Gentamycin in the irrigating solution to prevent joint infection after anterior cruciate ligament (ACL) reconstruction. *Arch Bone Jt Surg*. 2018; 6(Supple 1):2.
12. Ehrlichman LK, Gonzalez TA, Macaulay AA, Ghorbanhoseini M, Kwon JY. Gravity reduction view: a radiographic technique for the evaluation and management of weber b fibula fractures. *Arch Bone Jt Surg*. 2017; 5(2):89-95.
13. Schoenmakers DAL, Feczko PZ, Boonen B, Schotanus MGM, Kort NP, Emans PJ. Measurement of lower limb alignment: there are within-person differences between weight-bearing and non-weight-bearing measurement modalities. *Knee Surg Sports Traumatol Arthrosc*. 2017; 25(11):3569-75.
14. Seo JG, Moon YW, Kim SM, Jo BC, Park SH. Easy identification of mechanical axis during total knee arthroplasty. *Yonsei Med J*. 2013; 54(6):1505-10.