

Received: 21 April 2018

Revised: 30 April 2018

Accepted: 1 May 2018

DOI: 10.1002/ccr3.1599

CASE REPORTWILEY **Clinical Case Reports** Open Access

Appendix epidermoid cyst: Presenting as an acute appendicitis

Mahtab Rahbar 

Pathology Department, Iran University of Medical Sciences, Tehran, Iran

CorrespondenceMahtab Rahbar, Pathology Department, Iran University of Medical Sciences, Tehran, Iran.
Email: rahbarahbar@gmail.com**Key Clinical Message**

We report a rare case of a cystic mass in an appendix in a patient who presented nausea, vomiting, and sharp pain in lower right abdomen and mimicking acute appendicitis. Although this entity is very rare, careful physical observation, imaging, and pathology can be helpful to make an accurate diagnosis.

KEYWORDS

acute appendicitis, epidermoid cyst, vermiform appendix

1 | INTRODUCTION

Epidermoid cyst of the appendix is rare.^{1,2} Epidermoid cysts are cystic lesions originating from the inclusion of non-neuronal ectoderm during embryogenesis, and they are found in multiple locations. Depending on their location and size, epidermoid cysts may be incidental findings or cause a variety of symptoms, including pain, gastrointestinal disorders. An epidermoid cyst is commonly lesion of the skin but unusually described in organs outside of the skin.³⁻⁹ To our knowledge, epidermoid cyst of the gastrointestinal tract has only been described only in 2 cases.^{1,2} Diagnostic imaging is helpful in making the diagnosis, although histopathologic examination is the gold standard in the final diagnosis of the lesion. Therefore, surgical resection is indicated to establish a diagnosis and prevent eventual complications, such as rupture, hemorrhage, and infection.

2 | CASE HISTORY

A 5-year-old Iranian girl was presented with a 3 days history of anorexia, intermittent vomiting and intermittent dull pain near the navel or the upper abdomen that becomes sharp as it moves to the lower right abdomen, followed by migration of pain to the right lower quadrant. During this period, she had no urinary symptoms. Physical

examination revealed a firm rounded mass in the lower right abdomen. Routine hematologic and biochemical analyses and urinalysis were performed. The only laboratory findings were polymorphonuclear leukocytosis and high CRP. There was no history of any abdominal trauma or surgery in the past. On abdominal sonography, a 5-cm diameter cystic mass was visible in the lower right abdomen, postal to the cecum, and cranial to the bladder. The lumen of the appendix was dilated and suggestive of cystic pressure effect. The content of the cystic mass was hypoechoic with floating hyperechoic material. In view of the clinical and ultrasonographic findings, an immediate explorative laparotomy was recommended. At surgery, the appendix was resected. No other abnormalities were detected. The patient had an uneventful recovery from surgery and was discharged from the clinic 1 day later. At follow-up examinations, about 1 month after surgery, she was considered clinically unremarkable.

The resected tissue was fixed in 10% neutral buffered formalin. Grossly, on cut section, there is a 5 cm diameter thin-walled unilocular cyst filled with creamy contents (Figure 1). The lesion was located within the smooth muscle layers of the appendix. Tissue was embedded in paraffin, cut at a thickness of 6 μ m, and stained with hematoxylin and eosin. On histologic examination, there is a distributed cystic wall tissue was lined with an epidermis-like epithelium including a granular cell layer. The cavity of the cyst was filled with lamellar keratin. Significant tissue inflammation and intense

This is an open access article under the terms of the Creative Commons Attribution-NonCommercial-NoDerivs License, which permits use and distribution in any medium, provided the original work is properly cited, the use is non-commercial and no modifications or adaptations are made.

© 2018 The Authors. *Clinical Case Reports* published by John Wiley & Sons Ltd.

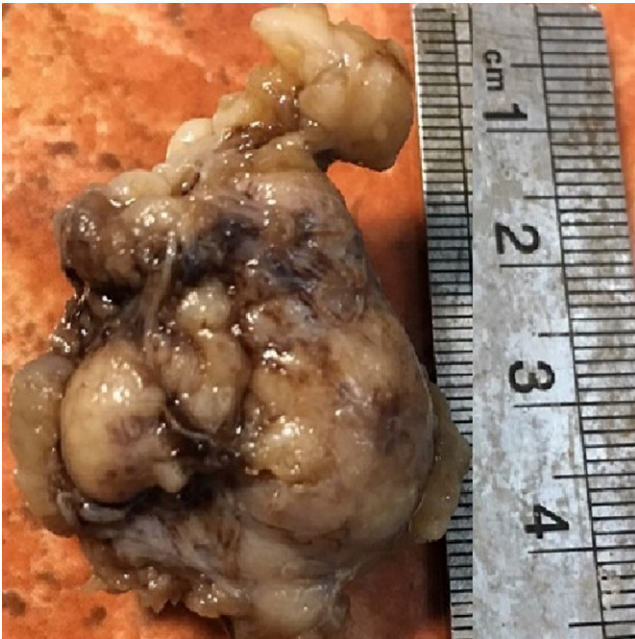

FIGURE 1 Gross photograph of resected vermiform appendix specimen showing an irregular mass adherent to the wall of Appendix

foreign body giant cell reaction have been noted on appendix wall and around the cyst also (Figure 2). Based on these findings, a diagnosis of the epidermoid cyst was made.

3 | DISCUSSION

Epidermoid cysts represent the most common cutaneous cysts.¹⁰ While they may occur anywhere on the body. Other more common locations are the central nervous system, lumbar spine, and bone especially the phalanges.^{11,12} The definitive diagnosis is made after excision by a pathologist based on the microscopic appearance of a cystic lesion lined by cornified epithelium containing lamellated keratin without calcifications. The histogenesis of an epidermoid cyst is uncertain. These cysts can be acquired and arose from implantation of embryogenic ectodermal fragments in the intraabdominal cavity to growth during injury or surgery. Epidermoid cysts can be congenital may arise the inclusion of ectodermal elements during embryological development.^{7,13} Clinical signs associated with intestinal epidermoid cysts vary from slow-growing intraabdominal masses and vague gastrointestinal symptoms, to acute abdominal pain due to cyst rupture or volvulus.¹⁴⁻¹⁶ Diagnosis of epidermoid cyst based on imaging is not a significant and histological examination is high.^{17,18} Differential diagnoses of abdominal masses such as acute inflammation, volvulus, obstruction, and neoplasms should be considered.¹⁴ Complete surgical excision is considered curative although recurrence after incomplete excision is possible. Epidermoid cysts are benign lesions, but very rare cases of malignancy arising from these lesions are described.¹⁹

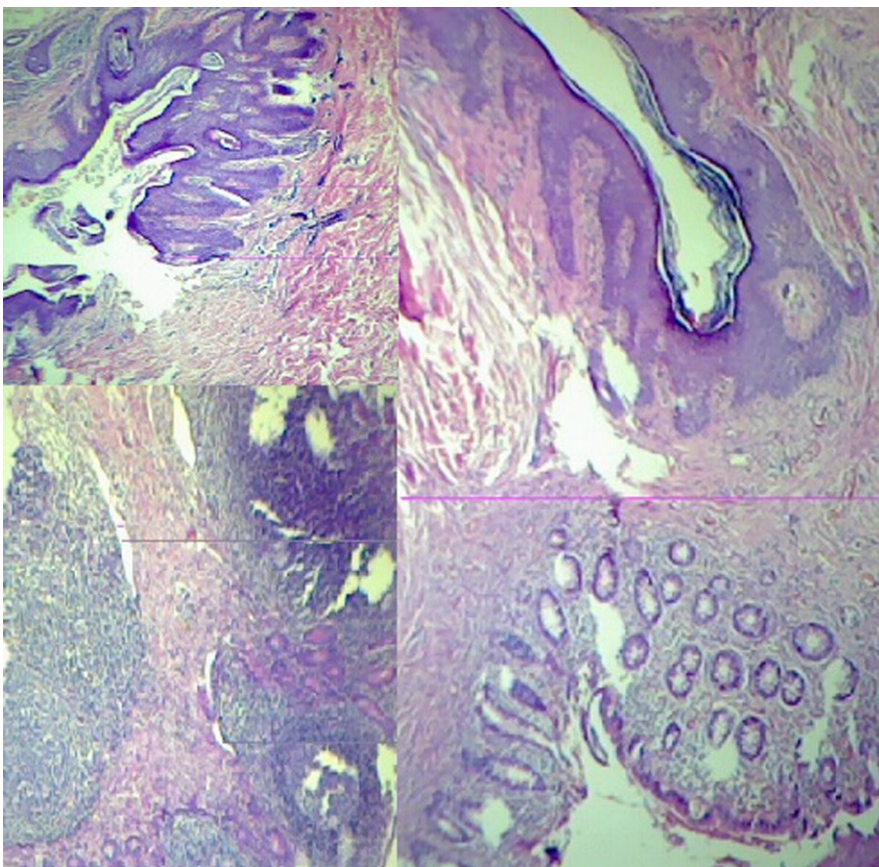


FIGURE 2 Sections of the cyst wall showing stratified squamous epithelial lining with underlying fibrous tissue (H and E, ×400)

4 | CONCLUSION

This is the third report that epidermoid cyst arising from the vermiform appendix. Although epidermoid cysts are rare clinicians should keep in their mind in cases with abdominal pain including in the childhood period.

CONFLICT OF INTEREST

None declared.

AUTHORSHIP

MR: wrote the manuscript and edited the images and also obtained the consent, reviewed and edited the manuscript.

ORCID

Mahtab Rahbar  <http://orcid.org/0000-0002-9756-9126>

REFERENCES

1. Piserchia NE, Davey RB. Epidermoid cyst of the appendix. *J Pediatr Surg*. 1980;15:674-675.
2. Cotton MH, Blake JR. Dermoid cyst: a rare tumor of the appendix. *Gut*. 1986;2:334-336.
3. Maskey P, Rupakheti S, Regmi R, et al. Splenic epidermoid cyst. *Kathmandu Univ Med J*. 2007;5:250-252.
4. Ramos Pleguezuelos FM, Amérigo J, Vidal Puga C, et al. Testicular epidermoid cyst. *Arch Esp Urol*. 2008;61:643-646.
5. Lim SC, Kim CS. Intrarenal epidermal cyst. *Pathol Int*. 2003;53:574-578.
6. Fernández-Castroagudín J, Bustamante Montalvo M, Delgado Blanco M, et al. Epidermoid cyst: a rare cause of cystic liver disease. *Gastroenterol Hepatol*. 2001;24:247-249.
7. Mady HH, Melhem MF. Epidermoid cyst of the cecum of an elderly man with no previous history of surgery: a case report and review of the literature. *Int J Colorectal Dis*. 2002;17:280-283.
8. Uzunlar A, Bukte Y. Epidermoid cyst of the cecum in an elderly man. *Ann Saudi Med*. 2006;26:477-479.
9. Rahbar M, Setayeshi KH, Jahanbin SH. Cystic teratoma of the pancreas. *Iran J Med Sci*. 2015;33:63-65.
10. Handa U, Kumar S, Mohan H. Aspiration cytology of epidermoid cyst of terminal phalanx. *Diagn Cytopathol*. 2002;26:266-267.
11. Dhebri AR, Afify SE. Unusual pathology of the colon: inclusion dermoid cyst. *Eur J Gastroenterol Hepatol*. 2004;16:233-234.
12. Macomb RK, Penner DW. Epidermoid (Epithelial) cyst of the terminal phalanx of a finger: case report and review of the literature. *Can Med Assoc J*. 1962;87:770-771.
13. Pear BL, Wolff JN. Epidermoid cyst of the cecum. *JAMA*. 1969;207:1516-1517.
14. Zabkowski T, Wajszczuk M. Epidermoid cyst of the scrotum: a clinical case. *J Urol*. 2014;11:1706-1717.
15. Al-Arfaj AA, El-Shawarby MA, Al-Mulhim FA, Lardhi AA. Mesenteric cystic teratoma in children. *Saudi Med J*. 2003;24:1388-1390.
16. Verswijvel G, Janssens F, Vanboven H, Palmers Y. Spontaneous rupture of mesenteric dermoid cyst: a rare cause of abdominal pain. *Eur Radiol*. 2004;8:1517-1518.
17. Morgan GJ, Bes TM, Berger Severo I, De Barros Coelho Bicocca E, Jannke HA. Intratesticular and intraovarian epidermoid inclusion cysts: report of two cases. *J Bras Patol Med Lab*. 2013;49:130-133.
18. Zavras N, Machairas N, Foukas P, Lazaris A, Patapis P, Machairas A. Epidermoid cyst of an intrapancreatic accessory spleen: a case report and literature review. *World J Surg Oncol*. 2014;12:92.
19. Caratozzolo E, Massani M, Recordare A, et al. Squamous cell liver cancer arising from an epidermoid cyst. *J Hepatobiliary Pancreat Surg*. 2001;8:490-493.

How to cite this article: Rahbar M.

Appendix epidermoid cyst: Presenting as an acute appendicitis. *Clin Case Rep*. 2018;6:1321-1323.

<https://doi.org/10.1002/ccr3.1599>