

See discussions, stats, and author profiles for this publication at: <https://www.researchgate.net/publication/281340290>

RAD50 Single-Nucleotide Polymorphism in Predominantly Antibody Deficiency

Article in *Journal of investigational allergology & clinical immunology: official organ of the International Association of Asthmology (INTERASMA) and Sociedad Latinoamericana de Alergia e Inmunología* · August 2015

Source: PubMed

2

READS

80

13 authors, including:



Saeid Nemati

Islamic Azad University Tehran Dental Branch

11 PUBLICATIONS 37 CITATIONS

[SEE PROFILE](#)



Ali Akbar Amirzargar

Tehran University of Medical Sciences

134 PUBLICATIONS 2,341 CITATIONS

[SEE PROFILE](#)



Elham Farhadi

Iran University of Medical Sciences

96 PUBLICATIONS 356 CITATIONS

[SEE PROFILE](#)



Armin Hirbod-Mobarakeh

Hirbod Psychiatry Clinic

43 PUBLICATIONS 277 CITATIONS

[SEE PROFILE](#)

Some of the authors of this publication are also working on these related projects:



aspirin desensitization for AERD patients [View project](#)



Pediatric studies [View project](#)

Allopurinol Desensitization: A Fast or Slow Protocol?

Bruno Soares J, Caiado J, Lopes A, Pereira Barbosa M
Immunoallergology Department, Hospital Santa Maria, Lisbon, Portugal

Key words: Allopurinol. Drug hypersensitivity. Desensitization.

Palabras clave: Allopurinol. Hipersensibilidad a medicamentos. Desensibilización.

The main indication for treatment with allopurinol is hyperuricemia in patients with gout and uric acid nephrolithiasis. It is particularly indicated in patients with chronic renal insufficiency (CRI), as this renders uricosuric drugs ineffective.

Adverse reactions are estimated to affect 2% of patients treated with allopurinol [1], and range from mild rash (in the majority of cases) to severe reactions such as Stevens Johnson syndrome, toxic epidermal necrolysis [2], and allopurinol hypersensitivity syndrome (approximately 0.4% of cases) [3].

Desensitization attempts have been reported, several with successful outcomes [4-9]. Patients are eligible for allopurinol desensitization when they have mild reactions or when no alternative treatments are available, since in many countries, such as Portugal, substitute drugs are not available.

We describe our experience with 2 allopurinol desensitization protocols in an immunoallergology department. We performed a chart review of all patients who underwent desensitization with allopurinol between 2003 and 2013. Nineteen patients underwent 21 desensitizations with either a slow protocol (starting with a 10- μ g dose and ending with a 100- or 300-mg dose after 16 days) or a fast protocol (starting with 50 μ g and ending with 100 mg after 5 days, although if necessary, this can be later increased to 300 mg).

Demographic characteristics, indication for treatment with allopurinol, type and timing of reaction, number of previous reactions, comorbidities, and desensitization protocol and outcome were recorded. Patients were contacted by phone to confirm current drug tolerance.

The 19 patients had a mean (SD) age of 64.1 (14) years and a median age of 66 years (range, 43-83 years); 63% were men. All the patients met the criteria for treatment: 14 had gout, 2 had kidney stones, and 3 had both.

Six patients (32%) had absolute indication for treatment with allopurinol due to CRI. The majority of patients (68%) had experienced just 1 prior reaction, 4 had experienced 2 reactions, and 2 had experienced 3 or more reactions.

Nine patients had experienced maculopapular rash, 3 urticaria, 2 angioedema, 2 generalized erythema and pruritus,

and 2 pruritus without cutaneous lesions. One man had experienced edema and erythema on the penis. The reactions had been immediate in 5 patients and delayed in 14.

Two patients were desensitized twice. Patient #10 first underwent a slow protocol, which she tolerated. She subsequently stopped taking allopurinol due to maintenance of normal uric acid levels, but 1 year later the hyperuricemia returned. Full-dose intake of allopurinol was attempted but was unsuccessful. The patient underwent desensitization again, but this time with a fast protocol. The result was successful. The other patient (#16) underwent both the fast and slow protocols, but failed to achieve tolerance.

Overall, 11 desensitizations (52%) were successful and resulted in good control of uric acid levels and thus of the underlying symptoms (Table). Eight patients are currently taking 100 mg of allopurinol while 3 are taking 300 mg daily. The 16-day protocol had a 64% success rate (7/11 desensitizations), while the 5-day protocol had a 40% success rate (4/10 desensitizations). There were thus 10 unsuccessful desensitizations. In 9 of the cases, the patients developed a reaction during the protocol and in the 10th case, the patient's symptoms resumed 1 week after completion of the protocol. Of the 13 patients who had reported only 1 prior reaction, 54% were unable to tolerate the desensitization, while in the group of 6 patients who had had 2 or more previous reactions, 33% were unable to tolerate it.

While the pathological mechanism underlying allopurinol hypersensitivity is not fully understood, CRI has been suggested as a risk factor for adverse reactions [10], probably due to underexcretion and accumulation of allopurinol and its metabolite oxypurinol [5]. Because there are no alternatives to allopurinol in many countries, numerous desensitization procedures have been studied and developed over the past 30 years. In our series, half of the patients with CRI and 54% of those without tolerated desensitization. We cannot therefore draw any conclusions as to the relevance of CRI in this context.

Most of the literature on allopurinol desensitization refers to slow protocols, which are based on very gradual dose increases, generally over a period of 28 days [4,5,7,9]. Fast desensitization protocols are less common [8]. In our department, we started out by using only a slow protocol, although it was shorter than most of the protocols previously reported. We now, however, mostly use the faster 5-day protocol [8], as it is more convenient for both patients and the department. The overall success rate of desensitization in our department (52%) is lower than rates reported in larger series (66%-78%) [5,6,9], although these series only studied 1 type of protocol. Our results show that the 5-day protocol was not tolerated in 60% of cases; 5 of the 6 patients in whom the protocol failed did not complete desensitization due to symptoms, which in some cases were more severe than the initial reaction, and 1 started showing symptoms again a week after completion of the protocol. The slow protocol was

Table. Type of Reactions and Desensitization Outcomes

Patient	Initial Reaction		Protocol	Breakthrough Reactions		Current Tolerance
	Type	Timing		Characteristics	Timing	
1	Facial pruritus	Delayed	16 days	n/a	n/a	Yes
2	Generalized rash	Delayed	16 days	n/a	n/a	Yes
3	Generalized rash	Delayed	16 days	Generalized maculopapular rash and bullous exanthema on the legs	delayed	No
4	Urticaria	Immediate	16 days	n/a	n/a	Yes
5	Lip angioedema	Immediate	16 days	Lip angioedema	Immediate	No
6	Urticaria	Immediate	16 days	Generalized maculopapular rash	Delayed	No
7	Urticaria	Immediate	16 days	n/a	n/a	Yes
8	Generalized rash	Delayed	16 days	n/a	n/a	Yes
9	Angioedema	Immediate	16 days	n/a	n/a	Yes
10	Generalized pruritus	Delayed	Both	n/a	n/a	Yes
11	Generalized rash	Delayed	5 days	n/a	n/a	yes
12	Generalized erythema and pruritus	Delayed	5 days	n/a	n/a	Yes
13	Generalized erythema and pruritus	Delayed	5 days	Generalized erythema and pruritus	Delayed	No
14	Edema and erythema of the penis	Delayed	5 days	Generalized rash	Delayed	No
15	Generalized rash and pruritus	Delayed	5 days	Generalized dermatitis, eyelid edema	Delayed	No
16	Generalized rash, hand pruritus	Delayed	Both	Generalized erythema and pruritus	Delayed	No
17	Generalized rash and erythema, face angioedema	Delayed	5 days	n/a	n/a	Yes
18	Generalized rash	Delayed	5 days	Generalized pruritus, bronchospasm	Delayed	No
19	Generalized dermatitis	Delayed	5 days	Generalized dermatitis	Delayed	No

Abbreviation: n/a, not applicable.

tolerated in 64% of cases, which is more similar to previously reported results [5,6,9].

Confirmation of allopurinol hypersensitivity requires a thorough clinical history and challenge tests, since there are no other validated tests. In our series, 68% of patients reported only 1 previous episode of a suspected reaction. Due to the urgent need for resuming treatment with allopurinol, a clinical decision was made to skip the challenge and proceed to desensitization. The procedure was not tolerated in over half of these patients (54%), confirming hypersensitivity. In the remaining 6 patients who tolerated desensitization a diagnosis was not confirmed, as at the time, the benefits of desensitization outweighed the need for confirmation.

In conclusion, the risks and benefits of allopurinol desensitization must be weighed up in each patient. The fact that the slow protocol was more frequently tolerated than the fast one raises the question as to whether the fast protocol should be retained in view of its lower success rates. As previously mentioned, the 16-day protocol we use is shorter than most of the slow protocols described in the literature, rendering it more convenient for patients, while still producing similar results to those reported in the largest case series reported to date [9].

Funding

The authors declare that no funding was received for the present study.

Conflicts of Interest

The authors declare that they have no conflicts of interest.

References

1. Fam AG. Difficult gout and new approaches for control of hyperuricemia in the allopurinol-allergic patient. *Curr Rheumatol Rep.* 2001 Feb;3(1):29–35.
2. Moniz P, Casal D, Mavioso C, Videira J, Almeida MA. Síndrome de Stevens-Johnson e necrólise tóxica epidérmica: um estudo retrospectivo de 15 anos. *Acta Médica Port.* 2011;24(1):59–70.
3. Arellano F, Sacristán JA. Allopurinol hypersensitivity syndrome: a review. *Ann Pharmacother.* 1993 Mar;27(3):337–43.
4. Meyrier A. Desensitisation in a patient with chronic renal disease and severe allergy to allopurinol. *Br Med J.* 1976 Aug 21;2(6033):458.

5. Fam AG, Lewtas J, Stein J, Paton TW. Desensitization to allopurinol in patients with gout and cutaneous reactions. *Am J Med.* 1992 Sep;93(3):299–302.
6. Silva SL, Santos AS, Pregal AL, Pedro E, Ferreira MB, Carlos AP, Barbosa MP. Allopurinol: experience in desensitization. *Rev Port Imunoalergologia* 2004; 12:390-9.
7. Kelso JM, Keating RM. Successful desensitization for treatment of a fixed drug eruption to allopurinol. *J Allergy Clin Immunol.* 1996 May;97(5):1171–2.
8. Nitti F, Fumagalli M, Incorvaia C. Rush desensitization to allopurinol. *Allergy.* 2003 Jul;58(7):690.
9. Fam AG, Dunne SM, Iazzetta J, Paton TW. Efficacy and safety of desensitization to allopurinol following cutaneous reactions. *Arthritis Rheum.* 2001;44(1):231–8.
10. Vazquez-Mellado J, Morales EM, Pacheco-Tena C, Burgos-Vargas R. Relation between adverse events associated with allopurinol and renal function in patients with gout. *Ann Rheum Dis.* 2001;60(10):981–3.

■ *Manuscript received January 27, 2014; accepted for publication, September 4, 2014.*

Joana Bruno Soares

Hospital Santa Maria, Centro Hospitalar Lisboa Norte
 Av. Prof. Egas Moniz
 1649-035 Lisbon
 Portugal
 E-mail: joanabsoares@gmail.com

Recurrent Anaphylaxis Due to Enoxaparin

Leguísamo S, Prados Castaño M, Piñero Saavedra M, Cimbollek S

Allergy Department, University Hospital Virgen del Rocío, Sevilla, Spain

Key words: Anaphylaxis. Enoxaparin allergy. Fondaparinux.

Palabras clave: Anafilaxia. Alergia a enoxaparina. Fondaparinux.

Heparin and low-molecular-weight heparin are widely used anticoagulants in the prophylaxis and treatment of thromboembolic diseases and in hemodialysis. Although heparins are very common, allergic reactions due to substances in this group are rare. The most common reactions involve cell-mediated hypersensitivity with clinical manifestations of erythematous plaques and occasionally maculopapular exanthemas. The most dangerous hypersensitivity reaction is heparin-induced thrombocytopenia, a type II IgG antibody-mediated reaction. Heparin-induced thrombocytopenia II and anaphylaxis are infrequent [1-2]. Anaphylaxis is a serious, life-threatening generalized or systemic hypersensitivity reaction [3]. Early diagnosis of potentially life-threatening adverse events and identification of alternatives is therefore clinically important.

In some anticoagulant-associated hypersensitivity reactions detailed allergologic investigation may help to identify safe treatment alternatives. In suspected IgE-mediated hypersensitivity, serial serum tryptase measurements during an acute episode, skin tests including prick, intradermal, and patch tests, as well as challenge tests are the most reliable diagnostic tools for heparin- or hirudin-induced anaphylaxis [1].

We present the case of a 51-year-old man with a history of uncontrolled polycystic disease who developed chronic kidney disease requiring hemodialysis. His usual treatment involved taking multivitamins, folic acid, omeprazole, and calcium.

Five minutes after initiating the fifth hemodialysis session, the patient presented facial erythema, dyspnea, and chest tightness. Tachycardia at 120 bpm, hypotension, and desaturation (PO₂ of 85%) were observed. A few minutes later he began with chills, shivering, and an increase in temperature from 36.6°C to 37.8°C. There were no other associated skin lesions or thromboembolic effects; the only drug used during this procedure was intravenous enoxaparin. The patient required acute treatment with fluid, oxygen, corticosteroid, and intravenous antihistamine. The next hemodialysis was well tolerated until enoxaparin was administered at the end of the session, with the patient presenting identical symptoms and responding to treatment as before.

Infection as a possible cause was ruled out. No remarkable analytical findings were observed during either episode. Serial determination of serum tryptase after the first episode

Table. Results of Serial Serum Tryptase Measurements (mcg/L)

	Prehemodialysis	2 Hours	6 Hours
First episode	-	6.65	7.48
Second episode	7.55	8.16	7.51

and prior to and after the administration of enoxaparin in the second episode was measured. The results are shown in the Table. An allergy study was performed using skin prick, intradermal, and patch tests with heparin-sodium, bemparin, nadroparin, dalteparin, enoxaparin, fondaparinux, and latex. A basophil activation test (BAT) with enoxaparin and fondaparinux was also performed using a previously described technique [4]. After obtaining informed consent, a challenge test was performed with fondaparinux to assess its viability as an alternative anticoagulant. No variations in tryptase levels were observed. Cutaneous tests and BAT were negative. Subcutaneous and intravenous fondaparinux was tolerated at full doses.

There are few reports in the literature of adverse reactions to low-molecular-weight heparins. Anders and Trautmann [7] also described a case of anaphylaxis due to enoxaparin. In their patient, prick tests to enoxaparin, fondaparinux, heparin-sodium, dalteparin, and danaparoid were positive; they also used BAT and the result was negative as in our case. BAT was proposed as a complementary method for the *in vitro* diagnosis of heparin allergy by Caballero et al [8] after obtaining positive results with heparin-sodium and enoxaparin in patients with allergic reactions to heparins.

Another case of anaphylaxis due to enoxaparin was described by MacLaughlin et al [9], but the limitation of that case report was that skin tests (prick or intradermal) and BAT were not performed to confirm the diagnosis of an allergic reaction.

In our case there was a clear relationship between the anaphylactic reaction and the administration of enoxaparin at different times of the hemodialysis, excluding therefore the involvement of other components used in the hemodialysis process, such as dialysis membranes or disinfectants. Hemodialysis with the same components was well tolerated after changing the anticoagulant to fondaparinux.

Mast cells and basophils are considered critical components of an allergic response because they express the high-affinity IgE receptor and secrete mediators known to be responsible for the symptoms and pathology of allergy diseases. Serum tryptase concentration is the best biomarker to assess mast cell activation and is considered a specific marker of mast cell degranulation. This enzyme remains elevated hours after systemic allergic reactions [3]. Berkun et al [6] confirmed the diagnosis of heparin allergy by skin tests and elevated serum tryptase levels and deduced allergy to enoxaparin through positive skin tests. In our case we did not observe any variation in serum tryptase levels.

In the studies summarized above, skin testing was used to reach a diagnosis of anaphylaxis due to an allergic reaction. Serum tryptase elevation and basophil activation involve the

same mechanism. However, the diagnostic value of cutaneous tests with heparins seems to be low [5]. BAT results can sometimes be suggestive of an IgE-mediated reaction, but the test is not widely available [4,8].

Our patient tolerated fondaparinux as an alternative treatment, as previously reported in a case of enoxaparin-induced anaphylaxis [10]. There have been descriptions of non-IgE-mediated adverse reactions to heparins, such as heparin-induced thrombocytopenia, and in such cases, there may be broad cross-reactivity among heparins. However, hirudins, danaparoid, and fondaparinux can all be used as valid alternatives [2].

In conclusion, we have presented a patient who developed an immediate adverse reaction to enoxaparin in which an IgE mechanism could not be demonstrated with cutaneous or *in vitro* tests and fondaparinux proved to be a safe alternative.

Funding

The authors declare that no funding was received for the present study.

Conflicts of Interest

The authors declare that they have no conflicts of interest.

References

- Bircher AJ, Harr T, Hohenstein L, Tsakiris DA. Hypersensitivity reactions to anticoagulant drugs: diagnosis and management options. *Allergy*. 2006; 61:1432-40.
- Warkentin TE, Greinacher A. Heparin induced anaphylactic and anaphylactoid reactions: two distinct but overlapping syndromes. *Expert Opin Drug Saf*. 2009; 8:129-44.
- Schwartz LB. Diagnostic value of tryptase in anaphylaxis and mastocytosis. *Immunol Allergy. Clin North Am* 2006; 26: 451–63.
- Sanz ML, Gamboa PM, Antépara I, Ussuf C, Villa I, García-Avilés C, Chazot M, De Weck AL. Flow cytometric basophil activation test by detection of CD63 expression in patients with immediate type reactions to betalactam antibiotics. *Clin Exp All* 2002; 32: 277-86
- Corominas M, García Robaina JC, Rodríguez V, Delgado J, García Ortega P. Reacciones alérgicas por fármacos poco habituales (II): de masa molecular alta u orgánicos. In: Pelaez Hernández A, Dávila González I.J, editors. *Tratado de Alergología*. SEAC. Ergon; 2007. p. 1562-4
- Berkun Y, Havivw Y S, Schwartz L B and Shalit M. Heparin-induced recurrent anaphylaxis. *Clin Exp Allergy* 2004; 34: 1916-8.
- Anders D and Trautmann A. Allergy anaphylaxis due subcutaneously injected heparin. *Allergy asthma & Clinical immunology*. 2013; 9:1
- Caballero MR, Fernández-Benítez M. Allergy to heparin: a new *in vitro* diagnostic technique. *Allergol Immunopathol*. 2003; 31:324–8.
- MacLaughlin EJ, Fitzpatrick KT, Sbar E, Jewell C. Anaphylactoid reaction to enoxaparin in a patient with deep venous thrombosis. *Pharmacotherapy*.2002; 22: 1511-5.

10. Harr T, Scherer K, Tsakiris A and Bircher J. Immediate type hypersensitivity to low molecular weight heparins and tolerance of unfractionated heparin and fondaparinux. *Allergy* 2006; 61:787-8.

■ Manuscript received May 18, 2014; accepted for publication, September 8, 2014.

Santiago Leguísamo

Servicio de Alergología
Centro de Diagnóstico y Tratamiento
Hospital Universitario Virgen del Rocío.
Manuel Siurot S/N
Seville 41013, Spain
E-mail address: santiagoleguisamo@gmail.com

***RAD50* Single-Nucleotide Polymorphism in Predominantly Antibody Deficiency**

Nemati S¹, Amirzargar AA^{1,2}, Farhadi E^{1,3}, Hirbod-Mobarakeh A^{2,4,5}, Nabavi M⁶, Soltani S², Mahdavi SA⁷, Shahinpour S⁸, Arshi S⁶, MirAhmadian M¹, Nicknam MH^{1,2}, Aghamohammadi A⁸, Rezaei N^{1,5,8}

¹Department of Immunology, School of Medicine, Tehran University of Medical Sciences, Tehran, Iran

²Molecular Immunology Research Center, Tehran University of Medical Sciences, Tehran, Iran

³Hematology Department, School of Allied Medical Science, Iran University of Medical Sciences, Tehran, Iran

⁴Students' Scientific Research Center, Tehran University of Medical Sciences, Tehran, Iran

⁵Universal Scientific Education and Research Network (USERN), Tehran, Iran

⁶Department of Allergy and Immunology, Rasool-e-Akram Hospital, Iran University of Medical Sciences, Tehran, Iran

⁷Pediatric Respiratory Diseases Research Center, National Research Institute of Tuberculosis and Lung Diseases (NRITLD), Shahid Beheshti University of Medical Sciences, Tehran, Iran

⁸Research Center for Immunodeficiencies, Pediatrics Center of Excellence, Children's Medical Center, Tehran University of Medical Sciences, Tehran, Iran

Key words: Common variable immunodeficiency. IgA deficiency. Genetic susceptibility. Single nucleotide polymorphism; *RAD50*.

Palabras clave: Inmunodeficiencia común variable. Deficiencia de IgA. Susceptibilidad genética. Polimorfismo de nucleótido simple. *RAD50*.

Common variable immunodeficiency (CVID) and selective IgA deficiency (SIgAD) constitute 2 important predominantly antibody deficiencies. Patients with CVID usually have reduced levels of at least 2 immunoglobulin isotypes, predisposing them to a number of infections, while patients with SIgAD simply have reduced levels of serum IgA and may be asymptomatic [1-4]. Some patients with SIgAD also have IgG subclass deficiency and may occasionally progress to CVID [5]. *RAD50*, which has a major role in several steps of DNA mismatch repair (MMR), seems to be associated with SIgAD and CVID [6]. The present study was performed to evaluate the association between *RAD50* and susceptibility to SIgAD or CVID in an Iranian population.

Thirty-nine patients with CVID (21 males and 18 females) and 19 patients with SIgAD (10 males and 9 females) from leading referral hospitals in Tehran, Iran, were enrolled in this study. All the patients were diagnosed according to the standard criteria, defined by the International Union of Immunological Societies: Primary Immunodeficiency Diseases Classification Committee [7]. Thirty-four healthy individuals (20 males and 14 females) were included as the control group. Informed consent was obtained from all participants before sampling, and the study was approved by the ethics committee of Tehran University of Medical Sciences.

In order to determine allele frequencies for the *RAD50* single-nucleotide polymorphism (SNP) *Rs2237060*, 5 mL of peripheral blood was collected from all the participants in EDTA-treated tubes and genomic DNA was extracted from peripheral blood leucocytes using the proteinase K phenol-chloroform extraction method. Real-time PCR allelic discrimination TaqMan genotyping assays (Applied Biosystems) and the ABI 7300 Real-Time PCR system were used to determine allele frequencies. Reactions were processed following standard protocols established by Applied Biosystems.

The frequencies of all genotypes were compared between patient and control groups (Table). Allele frequencies for the previously reported *Rs2237060* SNP were similar in patients and healthy controls. Although the AA genotype was more common in patients with CVID and SIgAD compared with controls, the difference was not significant. On comparing patients with CVID and patients with SIgAD, no significant differences in allele frequencies were observed.

This study analyzed the contribution of the *RAD50* SNP *Rs2237060* to susceptibility to SIgAD and CVID. An association between this SNP and SIgAD and CVID was recently reported in Swedish patients with these 2 diseases [6]. We did not, however, observe this association in our study. In another recent study by our group [8], we also failed to observe another association reported in the Swedish study, namely an association between an intronic SNP of the AICDA gene and SIgAD/CVID [6].

The reason for the discordance between our results and those of the Swedish study is probably related to the heterogeneous nature of CVID and SIgAD. Although *RAD50* might be a risk factor for CVID or SIgAD in a subset of patients in the Swedish study, this subset may constitute a small percentage of our study population or may even have been absent. Another possibility is high variability in allele frequencies between different ethnic groups.

Normal quantities of IgA-bearing B-cell precursors in the majority of patients with SIgAD and normal numbers of IgA-, IgG-, and IgM-bearing B cell precursors in the majority of patients with CVID provide evidence on normal class-switch recombination (CSR) in CVID and SIgAD [9,10]. It has been suggested that in most patients, the disease results from blockage in differentiation of mature B cells into plasma cells [9,10]. However, *RAD50* SNPs may be involved in a subset of patients with decreased levels of somatic hypermutation (SHM) and CSR. However, there are still some controversies in this regard, and the genetic defect involved in CVID and SIgAD has not yet been identified.

In conclusion, the results of our study did not confirm the previously reported association between the *RAD50* SNP *Rs2237060* and the development of either CVID or SIgAD. Although we did not find any association between *RAD50* and CVID or SIgAD, a growing body of evidence shows the importance of DNA MMR in the pathogenesis of CVID and SIgAD in a subtype of patients. Elucidating the exact role of proteins involved in MMR, CSR, and SHM in the pathogenesis of these diseases may help us to classify patients into subgroups, paving the way for the treatment of patients with certain subclasses of disease [10]. Therefore, despite our negative result, future studies should continue to investigate associations between CVID and SIgAD and variations of genes involved not only in MMR, but also in CSR and SHM in different ethnic groups. It would also be of interest to analyze these associations along with the rate of SHM and CSR and extent of radiosensitization.

Funding

This study was supported by a grant (90-03-30-13868) from Tehran University of Medical Sciences.

Table. Genotype Frequencies of *RAD50* at *Rs2237060* in Patients With CVID or SIgAD and Control Individuals

Genotypes	Controls (n=34), No. (%)	Primary Antibody Deficiencies (n=58)			SIgAD (n=19) vs Controls			CVID (n=39) vs Controls			SIgAD vs CVID (n=58)	
		Frequency, No. (%)	P Value	OR (95% CI)	Frequency, No. (%)	P Value	OR (95% CI)	Frequency, No. (%)	P Value	OR (95% CI)	P Value	OR (95% CI)
AA	23 (67.6)	33 (56.9)	.42	0.63 (0.24-1.67)	11 (57.9)	.68	0.66 (0.18-2.44)	22 (56.4)	.46	0.62 (0.21-1.79)	.86	0.94 (0.27-3.27)
AC	10 (29.4)	18 (31.0)	.94	1.08 (0.39-3.01)	6 (31.6)	.88	1.11 (0.28-4.38)	12 (30.8)	.89	1.07 (0.35-3.27)	.81	0.96 (0.25-3.70)
CC	1 (2.9)	7 (12.1)	.25	4.53 (0.52-102.46)	2 (10.5)	.29	3.88 (0.25-117.17)	5 (12.8)	.21	4.85 (0.50-115.85)	.58	1.25 (0.18-10.48)

Abbreviations: CVID, common variable immunodeficiency; SIgAD, selective IgA deficiency.

Conflicts of Interest

The authors declare that they have no conflicts of interest.

References

1. Aghamohammadi A, Farhoudi A, Moin M, Rezaei N, Kouhi A, Pourpak Z, Yaseri N, Movahedi M, Gharagozlou M, Zandieh F, Yazadni F, Arshi S, Mohammadzadeh I, Ghazi BM, Mahmoudi M, Tahaei S, Isaiean A. Clinical and immunological features of 65 Iranian patients with common variable immunodeficiency. *Clin Diagn Lab Immunol*. 2005;12:825-32.
2. Aghamohammadi A, Parvaneh N, Rezaei N. Common variable immunodeficiency: a heterogeneous group needs further subclassification. *Expert Rev Clin Immunol*. 2009;5:629-31.
3. Cunningham-Rundles C, Bodian C. Common variable immunodeficiency: clinical and immunological features of 248 patients. *Clin Immunol*. 1999;92:34-48.
4. Salehzadeh M, Aghamohammadi A, Rezaei N. Evaluation of immunoglobulin levels and infection rate in patients with common variable immunodeficiency after immunoglobulin replacement therapy. *J Microbiol Immunol Infect*. 2010;43:11-7.
5. Aghamohammadi A, Mohammadi J, Parvaneh N, Rezaei N, Moin M, Espanol T, et al. Progression of selective IgA deficiency to common variable immunodeficiency. *Int Arch Allergy Immunol*. 2008;147:87-92.
6. Offer SM, Pan-Hammarstrom Q, Hammarstrom L, Harris RS. Unique DNA repair gene variations and potential associations with the primary antibody deficiency syndromes IgAD and CVID. *PLoS One*. 5:e12260.
7. Al-Herz W, Bousfiha A, Casanova JL, Chapel H, Conley ME, Cunningham-Rundles C, et al. Primary immunodeficiency diseases: an update on the classification from the international union of immunological societies expert committee for primary immunodeficiency. *Front Immunol*. 2:54.
8. Farhadi E, Nemati S, Amirzargar AA, Hirbod-Mobarakeh A, Nabavi M, Soltani S, et al. AICDA single nucleotide polymorphism in common variable immunodeficiency and selective IgA deficiency. *Allergol Immunopathol (Madr)*. 2014;42:422-6.
9. Schroeder HW, Jr. Genetics of IgA deficiency and common variable immunodeficiency. *Clin Rev Allergy Immunol*. 2000;19:127-40.
10. Ohm-Laursen L, Schjebel L, Jacobsen K, Permin H, Svejgaard A, Barington T. Normal ICOS, ICOSL and AID alleles in Danish patients with common variable immunodeficiency. *Scand J Immunol*. 2005;61:566-74.

Manuscript received August 3, 2014; accepted for publication, September 11, 2014.

Nima Rezaei

Research Center for Immunodeficiencies
Children's Medical Center Hospital
Dr Gharib St. Keshavarz Blvd
Tehran 14194, Iran
E-mail: rezaei_nima@tums.ac.ir

Oral Allergy Syndrome Due to Nut Oleosins

Montoro Lacomba J¹, Doménech Witek J², Pineda de la Losa F³, Jover Cerdà V²

¹Hospital Arnau de Vilanova, Valencia, Spain

²Sección de Alergología, Hospital General de Elda, Elda, Alicante, Spain

³Laboratorios Diater, Madrid, Spain

Key words: Oral allergy syndrome. Peanuts. Walnuts. Oleosins.

Palabras clave: Síndrome de alergia oral. Cacahuets. Nueces. Oleosinas.

IgE-mediated reactions to fruits and vegetables are common in patients with allergy symptoms caused by pollen. Different families of defense, structural, and storage proteins have been described as major allergens in pollen-food allergy syndrome.

The most serious reactions reported include gastrointestinal, skin, eye, respiratory, and cardiovascular symptoms. Anaphylactic reactions due to foodstuffs usually occur immediately and are diagnosed by skin prick testing, specific IgE determination, and, when required, oral provocation.

We report the case of a 55-year old woman who reported several episodes of oral pruritus (Grade 0 allergy reaction) after eating fried peanuts and raw walnuts and 1 episode of lingual

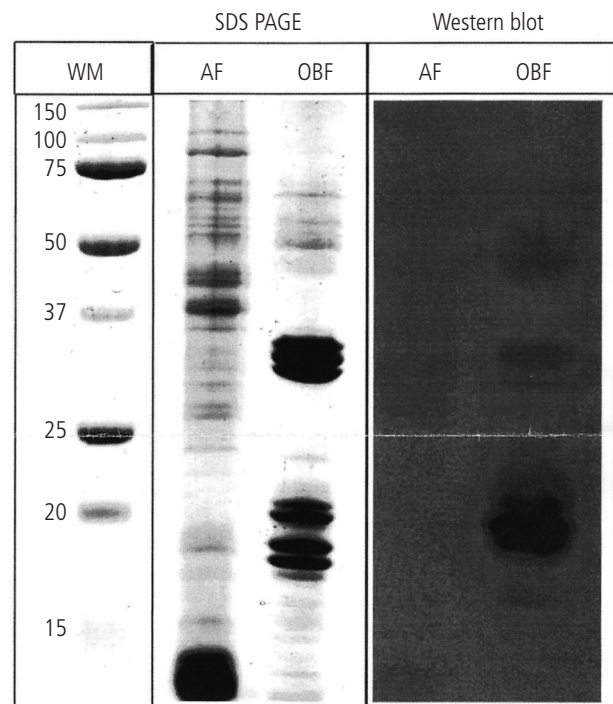


Figure. Immunoblotting with the patient's serum. Note the bands that identify oleosins (18-20 kDa) and probably caleosins (35-37 kDa). MW indicates molecular weight; AF, aqueous fraction; OB, oil body fraction.

angioedema (Grade 2 allergy reaction) after eating oil-fried peanuts. The patient did not eat other kinds of nuts and reported no problems with other plant foods, only mild symptoms with some spices. Symptoms consistent with rhinoconjunctivitis had been observed after exposure to dust and seasonally since the patient was 20 years old (over 30 years before the onset of symptoms with the ingestion of nuts). All the symptoms were mild and did not require treatment.

Skin prick tests were carried out with a full battery of foodstuffs including spices and common aeroallergens in our setting (ALK Abelló Laboratories). Specific IgE to pollens, house dust mites, and nuts was determined, and prick-by-prick skin tests were performed with peanuts, walnuts, olive oil, and sunflower oil. Serum was obtained for immunoblotting.

Skin prick tests were positive for *Dermatophagoides pteronyssinus* (3 mm), *Dermatophagoides farinae* (3 mm), and grass pollen (3 mm), and negative for the remaining aeroallergens and foodstuffs tested, including profilin and lipid transfer protein (purified natural date palm profilin and commercial peach extract from ALK Abelló). The prick-by-prick tests for peanuts, walnuts, olive oil, and sunflower oil were negative in all cases. Total IgE was 27.5 IU/mL and specific IgE was negative for walnuts (0.01 kU/L), *D pteronyssinus*, *D farinae* (0.01 kU/L), lolium (0.10 kU/L), peanuts (0.01 kU/L), and almonds (0.01 kU/L).

Immunoblotting showed bands with a molecular weight of 18 to 20 kDa corresponding to the oleosins, and of 35 to 37 kDa, probably corresponding to the caleosins.

Allergy to nuts is one of the most prevalent allergies in our setting. In general, these are sensitivities that trigger severe IgE-mediated reactions that can cause moderate or severe anaphylaxis. In the case of peanuts, the protein fractions identified to date correspond to storage proteins (Ara h 1, 2 and 3), lipid transfer protein (Ara h9), and PR10 (Ara h8) [1].

Recent reports have described new protein fractions, called oleosins, which are recognized by IgE antibodies from patients sensitized to olives, sesame, and nuts, and which cause allergic reactions ranging from oral allergy syndrome to anaphylaxis [2,3]. These reports used standard prick tests and specific IgE determinations, which provided negative results. Although isolated reports have shown sensitization to the agents tested using prick-by-prick tests prepared with saline, in most cases specific techniques to conserve the lipid fractions of the extracts were required. Patch tests were useful in these cases, with positive readings just 20 minutes after application of the patch. This might be explained by the low molecular weight of the sensitizing oleosins.

More recent reports have not only identified oleosins as sensitizing lipid fractions (fractions Ara h10 and 11 of peanuts) but also establish that these are gastroresistant allergens. This might explain the cases of anaphylaxis reported in the literature and the existence of cross-reactivity with other plant foods such as buckwheat, which has been tested by RAST inhibition techniques [4].

In conclusion, we have reported the case of a patient with oral pruritus after ingestion of peanuts and walnuts and allergic sensitization to oleosins. Skin prick tests, prick-by-prick tests, and specific IgE were negative for the suspected foodstuffs.

We hypothesize that these negative results might be due to the lipid nature of the allergen in question and, therefore, the difficulties inherent in its processing. Interestingly, most allergenic extracts are obtained by water-soluble methods that could eliminate these lipid derivatives of the allergenic extract [1]. The role of lipid derivatives in food allergies requires deeper investigation. In the present case, we advised our patient to strictly avoid all kinds of nuts. Unfortunately, she did not want to continue the study with other procedures, such as patch testing or further diagnostic procedures.

Acknowledgments

We thank Dr. F. Pineda de la Losa and Diater Laboratories (Madrid, Spain) for their invaluable assistance in reaching an etiologic diagnosis in the case described and in the writing of the article.

Funding

The authors declare that no funding was received for the present study.

Conflicts of Interest

The authors declare that they have no conflicts of interest.

References

1. Beyer K, Morrow E, Li XM, Bardina L, Bannon GA, Burks AW, Sampson HA. Effects of cooking methods on peanut allergenicity. *J Allergy Clin Immunol*. 2001 Jun;107(6):1077-81.
2. Pineda F, Palacios R, Vilella R, Pascal M, Bartra J. Anaphylactic reactions caused by oil body fraction lipoproteins. *Allergy Net*. 2001; 66: 701-8
3. Alonzi C, Campi P, Gaeta F, Pineda F, Romano A. Diagnosing IgE-mediated hypersensitivity to sesame by an immediate-reading "contact test" with sesame oil. *J Allergy Clin Immunol*. 2011 Jun;127(6):1627-9
4. Kobayashi S, Katsuyama S, Wagatsuma T, Okada S, Tanabe S. Identification of a new IgE-binding epitope of peanut oleosin that cross-reacts with buckwheat. *Biosci Biotechnol Biochem*. 2012;76(6):1182-8.

■ Manuscript received September 29, 2014; accepted for publication, December 29, 2014.

Joan Doménech Witek

Sección de Alergología
Hospital Elda
Carretera de Sax
03600 Elda
Alicante, Spain
E-mail:joanwitek@yahoo.es

Treatment of Severe Cold-Induced Urticaria in a Child With Omalizumab

Alba Marín JC¹, Martorell Aragones A², Satorre Viejo I¹, Gastaldo Simeon E³

¹*Neumología y Alergia, Servicio de Pediatría, Hospital Universitario de La Ribera, Alzira, Spain*

²*Unidad de Alergia, Hospital General Universitario, Valencia, Spain*

³*Servicio de Pediatría, Hospital Universitario de La Ribera, Alzira, Spain*

Key words: Urticaria. Cold urticaria. Anaphylaxis. Omalizumab.

Palabras clave: Urticaria. Urticaria por frío. Anafilaxia. Omalizumab.

Cold urticaria is typically induced by contact with cold water or cold air, and the reaction often occurs on rewarming of the exposed area [1,2]. Wanderer et al [3] proposed a classification for cold urticaria based on severity of reactions; they referred to local reactions in exposed areas of skin (type 1), generalized urticaria (type 2), and episodes associated with systemic symptoms (type 3). It is important to highlight that systemic anaphylactic reactions are common in cold urticaria and occur most often during swimming or aquatic activities [4], which can result in death. Thus, it is imperative that patients with cold-induced urticaria be cautioned against swimming, bathing, or similar water activities, and be provided with self-injectable epinephrine.

We describe the case of a 2-year-old boy who presented urticarial rashes after exposure to cold temperatures. The first episode had occurred at a ski resort when the patient was aged 18 months. After a few minutes outside, despite being adequately dressed for the cold, he developed a widespread urticarial rash. After that, the episodes of urticarial rash became more frequent in cold winter months and interfered with kindergarten attendance. There were no associated constitutional symptoms, such as fever or arthralgias. The patient was able to tolerate the ingestion of cold liquids and food.

At the age of 23 months, in June, while the patient and his classmates were throwing cold water at each other in the kindergarten playground, he suddenly experienced widespread urticaria, a lack of energy, and a reduced level of consciousness for 90 minutes. He improved on arrival at the hospital, regaining a normal level of consciousness and with all his vital signs within normal ranges.

His past medical history did not reveal anything significant. He was not atopic and had never had asthmatic or rhinitis symptoms, dermatitis, or other cutaneous lesions. There was no evidence of reactions to different types of food or drugs. He had not undergone any blood transfusions, and none of the members of his family had ever experienced cold-induced rashes.

Physical examination did not reveal any abnormalities. The skin was lesion-free and the lymph nodes were of a normal size. The chest was clear to auscultation, the abdomen was soft, and there was no organomegaly.

A threshold ice cube challenge test, which consists of the application of an ice cube on the skin of the right forearm for 30 seconds, 1, 2, and 5 minutes and measuring the time needed to induce skin response [2], resulted in the appearance of a large wheal and flare within 2 minutes, despite the fact that the patient was being treated with antihistamines.

Complete blood count revealed normal values. The biochemical parameters analyzed (glucose, creatinine, urea, total proteins, iron, ferritin, C3, and C4) were within normal ranges. Aspartate transaminase and alanine transaminase were slightly elevated (69.5 and 75.7 respectively), but in a subsequent test, they had returned to normal (40.3 and 19.6 respectively). The erythrocyte sedimentation rate was 6 mm/h, and the reactive C protein level was 0.02 mg/dL. Cold agglutinins were not detectable.

Anti-tissue transglutaminase IgA titers were within the normal range. Total IgE was 14.9 IU/mL. Antibodies from hepatitis C, toxoplasmosis, and cytomegalovirus were undetectable, as were IgM antibodies to Epstein-Barr virus. IgG antibodies to Epstein-Barr virus, however, were positive (index 1.01).

The clinical history of the patient's reactions, the absence of systemic illness, the negative results for cryoproteins, and the positive ice cube challenge test were consistent with a diagnosis of primary cold urticaria [1,2]. We established preventive treatment with cetirizine (2.5 mg twice daily) and concomitant use of montelukast (4 mg once daily). Hydroxyzine syrup was prescribed for mild reactions following cold exposure, and the family was instructed in the use of injectable epinephrine for episodes involving generalized urticaria or systemic symptoms. Despite this treatment, however, the patient continued to experience episodes of generalized urticaria, and we therefore opted for an empirical trial with omalizumab (75 mg every 4 weeks).

After the sixth injection of omalizumab, we repeated the threshold ice cube challenge test and observed no wheals after 10 minutes of application. In addition, we decided to expose the patient to cold water, trying to mimic the conditions that had triggered the anaphylactic reaction in the kindergarten playground. We covered the patient's body with cold wet

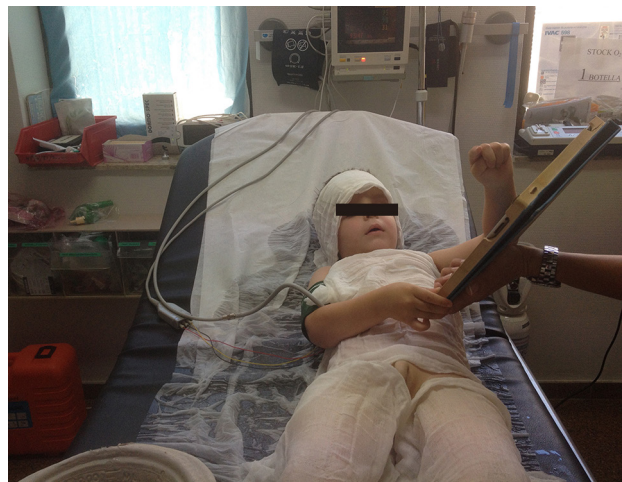

Figure. Exposure to cold water, in an attempt to mimic the conditions that triggered the anaphylactic reaction.

dressings, while monitoring vital signs. Every few minutes, we replaced dressings that were becoming warm with new cold dressings. This procedure was continued for 20 minutes (Figure, informed consent obtained). When all the dressings had been removed, there were only some small erythematous areas observable on the hip and left leg; there were no wheals and the patient's vital signs remained stable.

After 9 months of treatment, the patient started to bathe in the family swimming pool, and only developed mild cutaneous erythema in a few spots. He could also stay outside during cold months without developing lesions in exposed skin areas.

The marked improvement in this patient and in another case reported in the literature following treatment with omalizumab [5] adds strength to the proposed pathogenetic role for IgE in cold-induced mast cell activation in patients with cold-induced urticaria [6].

This is one of the few cases reported of successful response to treatment with omalizumab in severe cold-induced urticaria [5,7,8]. We found only 1 case describing this treatment in a pediatric patient [5], in which successful treatment of cold-induced urticaria-anaphylaxis with omalizumab was reported in a 12-year-old girl. In that case, after a few months of treatment with omalizumab, exposure to cold air and bathing in the sea produced only mild cutaneous pruritus and not urticaria, allowing the patient to ski and swim. Our patient also improved enormously, and after a few months of treatment with omalizumab, was able to do typical activities for his age. Both patients had a negative ice cube challenge test after treatment with omalizumab.

Studies on other patients with cold-induced urticaria are necessary to establish the clinical effectiveness of omalizumab observed in these cases.

Funding

The authors declare that no funding was received for the present study.

Conflicts of Interest

The authors declare they have no conflicts of interest.

References

- Zuberbier T, Aberer W, Asero R, Bindslev-Jensen C, Brzoza Z, Canonica Hebert J, Hide M, Kaplan A, Kapp A, Abdul Latiff AH, Mathelier-Fusade P, Metz M, Nast A, Saini SS, Sánchez-Borges M, Schmid-Grendelmeier P, Simons FE, Staubach P, Sussman G, Toubi E, Vena GA, Wedi B, Zhu XJ, Maurer M. The EAACI/GA(2) LEN/EDF/WAO Guideline for the definition, classification, diagnosis, and management of urticaria: the 2013 revision and update. *Allergy*. 2014 ;69:868-87.
- Magerl M, Borzova E, Giménez-Arnau A, Grattan CE, Lawlor F, Mathelier-Fusade P, Metz M, Mlynek A, Maurer M; EAACI/GA2LEN/EDF/UNEV. The definition and diagnostic testing of physical and cholinergic urticarias EAACI/GA2LEN/EDF/UNEV consensus panel recommendations. *Allergy*. 2009 ;64:1715-21.
- Wanderer AA, Grandel KE, Wasserman SI, Farr RS. Clinical characteristics of cold-induced systemic reactions in acquired cold urticaria syndromes: recommendations for prevention of this complication and a proposal for a diagnostic classification of cold urticaria. *J Allergy Clin Immunol*. 1986; 78:417-23.
- Alangari AA, Twarog FJ, Shih MC, Schneider LC. Clinical features and anaphylaxis in children with cold urticaria. *Pediatrics*. 2004;113:313-7.
- Successful treatment of cold-induced urticaria/anaphylaxis with anti-IgE. Boyce JA. *J Allergy Clin Immunol*. 2006;117:1415-8.
- Sussman G, Hébert J, Barron C, Bian J, Caron-Guay RM, Laflamme S, Stern S. Real-life experiences with omalizumab for the treatment of chronic urticaria. *Ann Allergy Asthma Immunol*. 2014 ;112:170-4.
- Brodská P, Schmid-Grendelmeier P. Treatment of severe cold contact urticaria with omalizumab: case reports. *Case Rep Dermatol*. 2012 ;4:275-80.
- Le Moing A, Bécourt C, Pape E, Dejobert Y, Delaporte E, Staumont-Sallé D. Effective treatment of idiopathic chronic cold urticaria with omalizumab: report of 3 cases. *J Am Acad Dermatol*. 2013;69:99-101.

■ *Manuscript received October 26, 2014; accepted for publication, January 19, 2015.*

José Carlos Alba Marín
Hospital Universitario de La Ribera
Carretera de Corbera s/n.
46600 Alzira, Spain
E-mail: jcalba@hospital-ribera.com

Do Asthmatic Patients and Their Physicians Agree on the Presence and Severity of Allergic Rhinitis?

Baiardini I¹, Braido F¹, Molinengo G², Ferrando M¹, Canonica GW¹
¹Allergy & Respiratory Diseases Clinic, DIMI, University of Genoa, IRCCS AOU San Martino-IST, Genoa, Italy
²Department of Psychology, University of Turin, Italy

Key words: Rhinitis. Asthma. Concordance. Persistence. Severity.

Palabras clave: Rinitis. Asma. Concordancia. Persistencia. Gravedad.

Allergic rhinitis (AR) and asthma often coexist. Up to 80% of asthma patients have AR, and more than 40% of AR patients complain of asthma [1]. The links between these 2 conditions are well characterized, and both likely represent a continuum of the same disease.

The Allergic Rhinitis and its Impact on Asthma (ARIA) guidelines [2] underline the importance of such links, provide recommendations on prevention and treatment, and suggest that asthma patients should be evaluated for AR and that all AR patients should undergo asthma tests.

Both the severity and the duration of rhinitis symptoms are determinants of asthma control [3]. Rhinitis is associated with increased unscheduled visits, risk of hospitalization, and drug consumption due to asthma [3]. Moreover, irrespective of their level of asthma control, patients with rhinitis reported worse health-related quality of life scores [4].

These data support the hypothesis that optimal management of AR can improve asthma. A combined treatment strategy should be planned in order to achieve the best possible health status [2].

Despite the availability of evidence-based guidelines, recommendations are not fully applied in clinical practice [5], with the result that AR often goes undiagnosed [6]. Few AR patients seek medical care, because they underestimate their disease or self-manage it [2].

We hypothesized that patients and physicians could have different perceptions of AR. Our hypothesis was verified using the database of a recent cross-sectional study that assessed the prevalence of obstructive sleep apnea syndrome symptoms in a large sample of asthma patients with and without comorbid rhinitis [7]. We sought to explore the perception of the presence and severity of rhinitis in asthma patients and their physicians.

The full methodology of the study whose database we used has been reported elsewhere [7]. Briefly, a quantitative questionnaire-based research program was implemented. The study population included adult patients with asthma diagnosed by their general practitioner (GP) according to the Global Initiative for Asthma [8] guidelines. After obtaining informed consent, the GPs indicated the presence and the classification of AR according to the ARIA guidelines [2] on the basis of the clinical features or data from the patient's medical record by ticking a precoded form.

Patients then completed a questionnaire to provide demographic characteristics (age, sex, height, and weight),

presence of 2 or more AR symptoms besides cold, and frequency and severity of AR symptoms. Specific questions put to patients included "Do you have one or more of these symptoms (runny nose, stuffy nose, itchy nose, sneezing, and itchy eyes) without having a cold?", "When you have such symptoms how long do they last? (less than 4 days a week for less than 1 month or more than 4 days a week for more than 1 month)", and "When you have these symptoms, do they affect your sleep?"

Physicians were blinded to the patients' replies in order to ensure objectivity.

The study was conducted between March and December 2011 throughout Italy and involved 1700 GPs participating in a continuing medical education program who were asked to enroll a maximum of 5 consecutive asthma patients.

Continuous variables were expressed as mean (SD). Potential associations between patients and GPs' answers were evaluated using the chi-square test.

The κ index (9) was used to assess the degree of concordance between the patient and the physician in reporting the presence and severity of rhinitis.

Of the 1700 participating physicians, 1678 (98.7%) completed the questionnaire and enrolled at least 2 patients each. Of the 3950 patients, 3527 (89.3%) signed an informed consent form and completed the questionnaire.

Fifty-three patients with an incomplete questionnaire were excluded. Thus, the analyses were performed on a sample of 3474 patients (mean age, 48.93 [15.16]; males, 59.5%).

A total of 1526 patients (44.1%) reported the presence of AR. GPs indicated the presence of AR in 2382 patients (69.5%). An association was found between patients' perception of disease and physicians' judgment with respect to the presence of rhinitis (chi-square, 133.95; $P < .001$), but the level of concordance was poor ($\kappa = 0.17$).

In 1201 cases, both patients and GPs reported the presence of AR, which was defined as persistent by 48.7% of patients and 51.6% of physicians. As for persistence of AR, a significant association was detected between patient and GP evaluations (chi-square, 73.6; $P < .001$), but concordance was again poor ($\kappa = 0.2$).

AR was classified as moderate-severe by 14.4% of patients and 43.1% of physicians. A significant association was found between patients and GPs with respect to severity (chi-square, 17.7; $P < .00$), but concordance remained weak ($\kappa = 0.4$).

Although the ARIA guidelines emphasize the relevance of AR and its impact on asthma management, implementation of guidelines in clinical practice is often unsatisfactory [5]. Difficulties in the application of recommendations could be ascribed to several factors, including poor patient-physician communication and different perceptions of a clinical problem [4]. The present study, which was performed on a large population of asthma patients, showed that the level of concordance between GPs and their patients with respect to AR is poor. As shown in other diseases [10], patient-physician concordance makes it possible to share clinical management. On the contrary, poor concordance could lead the physician to make choices that are not matched to patient's experience, thus leaving the patient with untreated symptoms and exposed to potential asthma triggers.

Our study should be viewed in the light of its limitations. The cross-sectional design and the a priori exclusion of variables that could affect concordance (eg, time allotted for the visit, personal characteristics of the physician and the patient) weaken our findings.

In conclusion, our results highlight the need for further interventions aimed at increasing awareness, perception, and management of AR, especially in asthma patients.

Acknowledgments

The authors thank ARMIA (Associazione Ricerca Malattie Immunologiche e Allergiche) and ASPADIRE (Associazione Pazienti Disturbi Respiratori nel Sonno) and acknowledge Dr Marianna Bruzzone for linguistic assistance with the manuscript.

Funding

The authors declare that no funding was received for this study.

Conflicts of Interest

The authors declare that they have no conflicts of interest.

References

1. Brozek JL, Bousquet J, Baena-Cagnani CE, Bonini S, Canonica GW, Casale TB, van Wijk RG, Ohta K, Zuberbier T, Schönemann HJ; Global Allergy and Asthma European Network; Grading of Recommendations Assessment, Development and Evaluation Working Group. Allergic Rhinitis and its Impact on Asthma (ARIA) guidelines: 2010 revision. *J Allergy Clin Immunol*. 2010;126:466-76.
2. Braidó F, Arcadipane F, Marugo F, Hayashi M, Pawankar R. Allergic rhinitis: current options and future perspectives. *Curr Opin Allergy Clin Immunol*. 2014;14:168-76.
3. Bousquet J, Schönemann HJ, Samolinski B, Demoly P, Baena-Cagnani CE, Bachert C, Bonini S, Boulet LP, Bousquet PJ, Brozek JL, Canonica GW, Casale TB, Cruz AA, Fokkens WJ, Fonseca JA, van Wijk RG, Grouse L, Haahtela T, Khaltaev N, Kuna P, Lockey RF, Lodrup Carlsen KC, Mullol J, Naclerio R, O'Hehir RE, Ohta K, Palkonen S, Papadopoulos NG, Passalacqua G, Pawankar R, Price D, Ryan D, Simons FE, Togias A, Williams D, Yorgancioglu A, Yusuf OM, Aberer W, Adachi M, Agache I, Ait-Khaled N, Akdis CA, Andrianarisoa A, Annesi-Maesano I, Ansotegui IJ, Baiardini I, Bateman ED, Bedbrook A, Beghé B, Beji M, Bel EH, Ben Kheder A, Bennoor KS, Bergmann KC, Berrissoul F, Bieber T, Bindslev Jensen C, Blaiss MS, Boner AL, Bouchard J, Braidó F, Brightling CE, Bush A, Caballero F, Calderon MA, Calvo MA, Camargos PA, Caraballo LR, Carlsen KH, Carr W, Cepeda AM, Cesario A, Chavannes NH, Chen YZ, Chiriac AM, Chivato Pérez T, Chkhartishvili E, Ciprandi G, Costa DJ, Cox L, Custovic A, Dahl R, Darsow U, De Blay F, Deleanu D, Denburg JA, Devillier P, Didi T, Dokic D, Dolen WK, Douagui H, Dubakiene R, Durham SR, Dykewicz MS, El-Gamal Y, El-Meziane A, Emuzyte R, Fiocchi A, Fletcher M, Fukuda T, Gamkrelidze A, Gereda JE, González Diaz S, Gotua M, Guzmán MA, Hellings PW, Hellquist-Dahl B, Horak F, Hourihane JO, Howarth P, Humbert M, Ivancevich JC, Jackson C, Just J, Kalayci O, Kaliner MA, Kalyoncu AF, Keil T, Keith PK, Khayat G, Kim YY, Koffi N'goran B, Koppelman GH, Kowalski ML, Kull I, Kvedariene V, Larenas-Linnemann D, Le LT, Lemièrre C, Li J, Lieberman P, Lipworth B, Mahboub B, Makela MJ, Martin F, Marshall GD, Martínez FD, Masjedi MR, Maurer M, Mavale-Manuel S, Mazon A, Melen E, Meltzer EO, Mendez NH, Merk H, Mihaltan F, Mohammad Y, Morais-Almeida M, Muraro A, Nafti S, Namazova-Baranova L, Nekam K, Neou A, Niggemann B, Nizankowska-Mogilnicka E, Nyembue TD, Okamoto Y, Okubo K, Orru MP, Ouedraogo S, Ozdemir C, Panzner P, Pali-Schöll I, Park HS, Pigearias B, Pohl W, Popov TA, Postma DS, Potter P, Rabe KF, Ratomaharo J, Reitano S, Ring J, Roberts R, Rogala B, Romano A, Roman Rodriguez M, Rosado-Pinto J, Rosenwasser L, Rottem M, Sanchez-Borges M, Scadding GK, Schmid-Grendelmeier P, Sheikh A, Sisul JC, Solé D, Sooronbaev T, Spicak V, Spranger O, Stein RT, Stoloff SW, Sunyer J, Szczeklik A, Todo-Bom A, Toskala E, Tremblay Y, Valenta R, Valero AL, Valeyre D, Valiulis A, Valovirta E, Van Cauwenberge P, Vandenplas O, van Weel C, Vichyanond P, Viegi G, Wang DY, Wickman M, Wöhrl S, Wright J, Yawn BP, Yiallourous PK, Zar HJ, Zernotti ME, Zhong N, Zidarn M, Zuberbier T, Burney PG, Johnston SL, Warner JO; World Health Organization Collaborating Center for Asthma and Rhinitis. Allergic Rhinitis and its Impact on Asthma (ARIA): achievements in 10 years and future needs. *J Allergy Clin Immunol*. 2012;130:1049-62.
4. Braidó F, Baiardini I, Balestracci S, Ghiglione V, Stagi E, Ridolo E, Nathan R, Canonica GW. Does asthma control correlate with quality of life related to upper and lower airways? A real life study. *Allergy*. 2009;64:937-43.
5. Baiardini I, Braidó F, Bonini M, Compalati E, Canonica GW. Why do doctors and patients not follow guidelines? *Curr Opin Allergy Clin Immunol*. 2009;9:228-33.
6. Bousquet J, Bodez T, Gehano P, Klossek JM, Liard F, Neukirch F, Le Gal M, Janin N, Allaf B. Implementation of guidelines for allergic rhinitis in specialist practices. A randomized pragmatic controlled trial. *Int Arch Allergy Immunol*. 2009;150:75-82.
7. Braidó F, Baiardini I, Lacedonia D, Facchini FM, Fanfulla F, Molinengo G, Canonica GW; Italian Society of Respiratory Medicine (SImeR). Sleep apnea risk in asthmatic patients with or without comorbid rhinitis. *Respir Care*. 2014;59:1851-6.
8. GINA Global Initiative for Asthma. Global strategy for asthma management and prevention NHBL/WHO Workshop Report. 2008. Available from: www.ginasthma.com
9. Cohen J. A coefficient of agreement for nominal scales. *Educ Psychol Meas* 1960;20:37-46
10. Miravittles M, Ferrer J, Baró E, Lleonart M, Galera J. Differences between physician and patient in the perception of symptoms and their severity in COPD. *Respir Med*. 2013;107:1977-85

Manuscript received November 10, 2014; accepted for publication January 22, 2015.

Ilaria Baiardini

Allergy & Respiratory Diseases Clinic – DIMI - University of Genoa, IRCCS AOU San Martino-IST Pad. Maragliano, Largo Rosanna Benzi 10. 16132 Genoa, Italy
E-mail: ilaria.baiardini@libero.it

Successful Oral Desensitization in a Patient With Hypersensitivity Reaction to Crizotinib

Sánchez-López J^{1,2}, Viñolas N^{2,3}, Muñoz-Cano R^{1,2}, Pascal M^{2,4}, Reguart N^{2,3}, Bartra J^{1,2}, Valero A^{1,2,5}

¹*Servei de Pneumologia i Al·lèrgia, ICT, Hospital Clinic, Universitat de Barcelona, Barcelona, Spain*

²*Institut d'Investigacions Biomèdiques August Pi i Sunyer (IDIBAPS), Barcelona, Spain*

³*Servei d'Oncologia Mèdica, ICMHO, Hospital Clinic, Universitat de Barcelona, Barcelona, Spain*

⁴*Servei d'Immunologia, CDB, Hospital Clinic, Universitat de Barcelona, Barcelona, Spain*

⁵*Centro de Investigaciones Biomédicas en Red de Enfermedades Respiratorias (CIBERES), Barcelona, Spain*

Key words: Crizotinib. Desensitization. Drug hypersensitivity. Non–small cell lung cancer.

Palabras clave: Crizotinib. Desensibilización. Hipersensibilidad a medicamentos. Cáncer de pulmón de células no pequeñas.

Crizotinib (Xalkori, Pfizer) is an anticancer drug that acts as an anaplastic lymphoma kinase (ALK) and c-ros oncogene 1 inhibitor. It has proven to be more efficacious than standard chemotherapy in advanced ALK-positive non–small cell lung cancer (NSCLC), which represents 4–6% of all cases of NSCLC [2]. Crizotinib is becoming a first-line treatment in patients with NSCLC.

Cutaneous reactions to crizotinib are reported in both phase I and phase III trials at a frequency of 11% and 9%, respectively, and are vaguely described as cutaneous rashes. The only cases of reactions to crizotinib are 1 report of severe photosensitivity dermatitis [3] and, more recently, 2 cases in which the manifestations were urticaria and maculopapular rash, respectively [4].

Suitable alternatives to target-specific drugs are not usually available. When hypersensitivity reactions do occur, it is worth evaluating desensitization [5]. This approach has been in use for some time, but in the last few years it has become increasingly important with the progressive emergence of target-specific therapies [6]. Desensitization consists of the administration of increasing doses—usually doubling up—of the culprit drug at fixed time intervals of 15–30 minutes, thus avoiding mast cell and basophil degranulation [5]. Different protocols have been described, especially for antineoplastic agents and monoclonal antibodies [6–8], and most are designed for intravenous administration. In the case reports described above [3,4], application of a 12-step desensitization protocol enabled patients to tolerate the drug. Here, we report a new case of hypersensitivity reaction in which the patient underwent a complete allergy workup and a fast oral desensitization protocol.

The patient was a 78-year-old woman (nonsmoker) diagnosed with metastatic ALK-positive NSCLC who started receiving oral crizotinib 250 mg twice daily in January 2014

as a third-line treatment. The drug was well tolerated for the first 40 days, and the patient only experienced grade II asthenia and grade I edema. Four hours after the morning dose, the patient presented with itchy hives on the head, chest, and back. The reaction improved progressively during the day without medication, but 1 hour after intake of the following dose, the reaction became more intense, with associated facial edema. She was treated with intramuscular dexchlorpheniramine 5 mg by her general practitioner, who prescribed oral cetirizine 10 mg twice daily and advised her to suspend crizotinib. The symptoms disappeared 10 hours later.

The oncologist revisited the patient and assessed the efficacy of crizotinib. As a partial response was obtained according to the Response Evaluation Criteria in Solid Tumors rules [9], the decision was taken to continue with the same treatment, and the patient was referred to the allergy unit for a workup. On March 25, 2014, the patient was evaluated by an allergist. After giving her written informed consent, she underwent a skin prick test (SPT) and intradermal tests (IDT) with the culprit drug following the European Network for Drug Allergy recommendations [10]. Briefly, crizotinib capsules were suspended in water for injection at a concentration of 25 mg/mL and then diluted to 1:1000. SPT was carried out at 25 mg/mL and IDT at 1:1000 and 1:100 of the SPT concentration. The results were negative. The results were also negative in 5 controls. Drug handling and dilutions were carried out at the hospital's pharmacy for safety reasons. A basophil activation test was also performed on fresh whole blood using the Flow2CAST kit (Bühlmann). The stimulus used was a solution of crizotinib in dimethyl sulfoxide at different concentrations (0.05, 0.03, 0.005, 0.003, 0.001, and 0.0003 mg/mL), but no stimulus was detected at any dose.

As crizotinib was the most efficacious drug for treatment, a rapid oral desensitization protocol was proposed. On April 3, 2014, the patient received intramuscular dexchlorpheniramine 5 mg and intramuscular methylprednisolone 40 mg 30 minutes before starting the desensitization protocol. The oncologist established the target dose at 200 mg owing to potential toxicity and the patient's decision. Increasing doses of a suspension of crizotinib—prepared in the same way as for the SPT—were administered stepwise at intervals of 30 minutes following the schedule shown in the Table. A cumulative dose of 200 mg was administered over 2 hours. The protocol was designed according to our previous experience in oral desensitization protocols and risk assessment based on the characteristics of the reaction and the tests performed. Vital signs were monitored throughout the procedure, and no alterations in heart rate or blood pressure were recorded. The patient remained under observation at the allergy unit for 2 hours after the last dose, and no adverse reactions were observed.

The patient subsequently continued to receive oral crizotinib at 200 mg twice daily. No further adverse reactions were reported after more than 7 months of treatment, except for asthenia and edema (both grade I).

In August 2014, the patient complained of lightheadedness and vertigo. Cranial nuclear magnetic resonance revealed a hyperintense image in the right pontomesencephalic region that was compatible with metastasis. As radiosurgery was indicated, crizotinib had to be discontinued on October 15, 2014. On December 11, 2014, crizotinib was reintroduced

Table. Crizotinib Desensitization Protocol^a

Step	Dose, mg
1	10
2	15
3	25
4	50
5	100

^aDoses were administered every 30 minutes, with a final observation period of 120 minutes.

with the same desensitization schedule, and no adverse events were recorded.

Although we could not demonstrate an IgE-mediated mechanism, the onset and characteristics of the reaction point to a type I hypersensitivity reaction. Negative skin test results are not infrequent in suspected hypersensitivity reactions [6,8], even in those where a desensitization protocol is successful; therefore, mechanisms other than IgE-mediated mechanisms could be involved. Since crizotinib was more efficacious than other drugs in the present case, a desensitization procedure was the best option.

A complete allergy workup should be mandatory for this kind of reaction, as we need as much information as possible to select and tailor treatment. The protocol we applied was successful, despite our limited experience. It was also faster and shorter than that of Awad et al [4] (2 hours vs 3 hours and 5 steps vs 12 steps). The protocol should be tested in more patients to confirm its usefulness in the treatment of hypersensitivity reactions to crizotinib.

Funding

The authors declare that no funding was received for the present study.

Conflicts of Interest

The authors declare that they have no conflicts of interest.

References

- Shaw AT, Kim D-W, Nakagawa K, Seto T, Crinó L, Ahn M-J, De Pas T, Besse B, Solomon BJ, Blackhall F, Wu YL, Thomas M, O'Byrne KJ, Moro-Sibilot D, Camidge DR, Mok T, Hirsh V, Riely GJ, Iyer S, Tassell V, Polli A, Wilner KD, Jänne PA. Crizotinib versus Chemotherapy in Advanced ALK-Positive Lung Cancer. *N Engl J Med*. 2013;368:2385-94.
- Koivunen JP, Mermel C, Zejnullahu K, Murphy C, Lifshits E, Holmes AJ, Choi HG, Kim J, Chiang D, Thomas R, Lee J, Richards WG, Sugarbaker DJ, Ducko C, Lindeman N, Marcoux JP, Engelman JA, Gray NS, Lee C, Meyerson M, Janne PA. EML4-ALK fusion gene and efficacy of an ALK kinase inhibitor in lung cancer. *Clin Cancer Res*. 2008;14:4275-83.
- Oser MG, Janne PA. A severe photosensitivity dermatitis caused by crizotinib. *J Thorac Oncol*. 2014;9:e51-3.
- Awad MM, Lax TP, Slawski BR, Shaw AT. Successful Desensitization of Two Patients with ALK-Positive Lung Cancer and Hypersensitivity to Crizotinib. *J Thorac Oncol*. 2014;9:1726-8.
- Cernadas JR, Brockow K, Romano A, Aberer W, Torres MJ, Bircher A, Campi P, Sanz ML, Castells M, Demoly P, Pichler WJ. General considerations on rapid desensitization for drug hypersensitivity - a consensus statement. *Allergy*. 2010;65:1357-66.
- Brennan PJ, Rodriguez Bouza T, Hsu FI, Sloane DE, Castells MC. Hypersensitivity reactions to mAbs: 105 desensitizations in 23 patients, from evaluation to treatment. *J Allergy Clin Immunol*. 2009;124:1259-66.
- Castells MC, Tennant NM, Sloane DE, Hsu FI, Barrett NA, Hong DI, Laidlaw TM, Legere HJ, Nallamshetty SN, Palis RI, Rao JJ, Berlin ST, Campos SM, Matulonis UA. Hypersensitivity reactions to chemotherapy: outcomes and safety of rapid desensitization in 413 cases. *J Allergy Clin Immunol*. 2008;122:574-80.
- Madrigal-Burgaleta R, Berges-Gimeno MP, Angel-Pereira D, Ferreira-Monteagudo R, Guillen-Ponce C, Pueyo C, Gomez de Salazar E, Alvarez-Cuesta E. Hypersensitivity and desensitization to antineoplastic agents: outcomes of 189 procedures with a new short protocol and novel diagnostic tools assessment. *Allergy*. 2013;68:853-61.
- Eisenhauer EA, Therasse P, Bogaerts J, Schwartz LH, Sargent D, Ford R, Dancey J, Arbuck S, Gwyther S, Mooney M, Rubinstein L, Shankar L, Dodd L, Kaplan R, Lacombe D, Verweij J. New response evaluation criteria in solid tumours: revised RECIST guideline (version 1.1). *Eur J Cancer*. 2009;45:228-47.
- Brockow K, Romano A, Blanca M, Ring J, Pichler W, Demoly P. General considerations for skin test procedures in the diagnosis of drug hypersensitivity. *Allergy*. 2002;57:45-51.

■ Manuscript received October 28, 2014; accepted for publication January 22, 2015.

Jaime Sánchez-López
Hospital Clínic i Provincial
Villarroel 170
08036 Barcelona
Spain
E-mail: jasanche@clinic.uib.es

Anaphylaxis to Intravenous Methylprednisolone Hemisuccinate in a Patient With Immune Thrombocytopenia

Álvarez Caro F¹, García González V¹, González García J¹, García Mozo R¹, García Normiella B¹, Gómez Farpón A²

¹Servicio de Pediatría, Hospital de Cabueñes, Gijón, Spain

²Área de Gestión de Pediatría, Hospital Universitario Central de Asturias, Oviedo, Spain

Key words: Methylprednisolone. Anaphylaxis. Immune thrombocytopenia. Corticosteroids.

Palabras clave: Metilprednisolona. Anafilaxia. Púrpura trombocitopénica autoinmune. Corticoides.

An 11-year-old boy weighing 26 kg was admitted to our hospital with a 4-day history of mucocutaneous purpura secondary to immune thrombocytopenia (ITP). Large bruises were present on both legs, and petechial lesions were observed on his neck. His platelet count was 11 000 platelets/mm³, with no red cell or leukocyte abnormalities. Clotting was normal. The child had had asthma for several years and was taking inhaled fluticasone. He occasionally required oral prednisolone or deflazacort combined with inhaled salbutamol to treat exacerbations. No adverse reactions to these drugs were noted.

The patient ate sole 15 minutes before starting treatment for ITP with intravenous methylprednisolone hemisuccinate. He experienced itching, generalized urticaria, eyelid angioedema, and moderate bronchospasm within 3 minutes of administration. The infusion of methylprednisolone was stopped, and the patient recovered after treatment with intramuscular adrenaline (300 µg), intravenous dexchlorpheniramine (4 mg), and nebulized salbutamol (4 mg). His symptoms resolved after 25 minutes.

We performed a skin prick test (SPT) and an intradermal test (IDT) with corticosteroids and an SPT with latex and sole. SPT was performed by applying a drop of the test solution at full concentration (only SPT could be performed for prednisolone because the only formulation available is for

oral use). The results of both SPT and IDT were considered positive when the wheal reaction was at least 3 mm larger than that elicited by the saline control.

The results of SPT using methylprednisolone hemisuccinate (10 mg/mL), hydrocortisone (100 mg/mL), prednisolone (7 mg/mL), triamcinolone (40 mg/mL), dexamethasone (4 mg/mL), budesonide (0.5 mg/mL), betamethasone (6 mg/mL), sole, and latex were all negative. The IDT with methylprednisolone hemisuccinate at a 1:10 dilution (1 mg/mL) was positive (15×15 mm). The results of IDT to the other corticosteroids (hydrocortisone, triamcinolone, budesonide, dexamethasone, and betamethasone) were negative. SPT and IDT to corticosteroids at those concentrations were negative in patients who were not allergic to corticosteroids (controls). Excipients (monosodium and disodium phosphate) were excluded, as the patient had tolerated them in the other drugs.

The result of an oral challenge with prednisolone (25 mg) and dexamethasone (12 mg) was negative, as was that of an intravenous challenge with hydrocortisone (160 mg). All challenges were performed in a hospital setting under medical supervision and with intravenous access and the necessary medications, personnel, and equipment to treat anaphylactic reactions. Challenges were graded using incremental doses (1:10, 1:1) every 1 hour. The drugs tested are shown in the Table.

Prior to discharge, the patient received oral prednisolone to increase his platelet level to 49 000/mm³. He was discharged with oral prednisolone (46 mg every 12 hours) for 6 days and an epinephrine autoinjector and experienced no further adverse reactions.

Although corticosteroids are usually prescribed for their antiallergenic effects, immediate hypersensitivity reactions, including anaphylactic reactions, and delayed allergic reactions, mainly allergic contact dermatitis, have been reported [1]. Immediate reactions are less frequent than delayed reactions, and their exact incidence is unknown [1]. Previously published data show that the conditions associated with a greater risk of developing immediate hypersensitivity to corticosteroids include renal transplant, rheumatic disease, hypersensitivity to nonsteroidal anti-inflammatory drugs, and asthma with significant exposure to parenteral corticosteroids [1-5]. In the case we report, the patient had never received intravenous corticosteroids. Moreover, to our knowledge, hematological diseases have never been reported

Table. Drugs Tested

Drug	Skin Prick Test		Intradermal Test		Challenge
Methylprednisolone hemisuccinate	10 mg/mL	0×0 mm	1:10	15×15 mm	Not done
Hydrocortisone	100 mg/mL	0×0 mm	1:10	0×0 mm	Tolerated
Prednisolone	7 mg/mL	0×0 mm	1:10	0×0 mm	Tolerated
Triamcinolone	40 mg/mL	0×0 mm	1:10	0×0 mm	Not done
Budesonide	0.5 mg/mL	0×0 mm	1:1	0×0 mm	Not done
Dexamethasone	4 mg/mL	0×0 mm	1:10	0×0 mm	Tolerated
Betamethasone	6 mg/mL	0×0 mm	1:10	0×0 mm	Not done

to be a risk factor, as in the case we present. The role of the immunological disease ITP in the hypersensitivity reaction experienced by the patient we describe is unknown.

Some authors suggest that the corticosteroids most commonly involved in immediate hypersensitivity reactions are methylprednisolone and hydrocortisone and that the reaction results from their affinity for serum proteins [6,7]. Others conclude that the most frequently involved drugs are oral prednisone and prednisolone, both of which are commonly used for outpatient therapy [5]. Information about the sensitivity and specificity of SPT and IDT to corticosteroids is limited, although sensitivity has been estimated at 86% [5]. In vitro tests such as allergen-specific IgE detection with corticosteroids and the basophil activation test are difficult to perform but can effectively complement skin tests [1].

Cross-reactivity between drugs has also been suggested, as some patients reacted to more than 1 corticosteroid [5,8]. Ventura et al [8] suggested that hydrocortisone is more likely to cross-react with methylprednisolone than with dexamethasone or betamethasone. The largest available series (15 patients) revealed no patterns of cross-reactivity based on the clinical history and the results of the skin tests [5]; therefore, systematic individualized evaluation of the sensitization/tolerance profile is necessary [1]. In the case we report, the patient reacted to methylprednisolone hemisuccinate but tolerated other corticosteroids including hydrocortisone. Succinate ester in particular seems to have immunological potential, but the mechanism of action has not yet been clarified [9]. As it is impractical to recommend complete avoidance of systemic corticosteroids because of their widespread use, it is mandatory to offer the patient alternative corticosteroids (especially in diseases such as ITP, where corticosteroids are a key treatment). A graded drug challenge is usually required to confirm tolerability. In this regard, a negative IDT result correlates with clinical tolerance in many patients [5,10]. Rachid et al [5] described a patient who tolerated 2 courses of an alternative corticosteroid and had an anaphylactic reaction to the third course. Injectable epinephrine for emergency use is recommended in outpatients with corticosteroid allergy who are receiving an alternative well-tolerated corticosteroid.

In conclusion, our findings are compatible with IgE-mediated anaphylaxis due to methylprednisolone hemisuccinate confirmed by IDT. We found no cross-reactivity to prednisolone, dexamethasone, or hydrocortisone in the context of ITP. Clinicians should not underestimate the allergenic potential of corticosteroids and should be aware that severe anaphylactic reactions to corticosteroids can even occur in individuals with no predisposing conditions. Therefore, patients who require high doses of corticosteroids should be carefully monitored, regardless of their disease.

Funding

The authors declare that no funding was received for the present study.

Conflicts of Interest

The authors declare that they have no conflicts of interest.

References

1. Baeck M, Goossens A. Immediate and delayed allergic hypersensitivity to corticosteroids: practical guidelines. *Contact Dermatitis*. 2012;66:38-45.
2. Saito R, Moroi S, Okuno H, Ogawa O. Anaphylaxis following administration of intravenous methylprednisolone sodium succinate in a renal transplant recipient. *Int J Urol*. 2004;11:171-4.
3. Laine-Cessac P, Moshinaly H, Gouello JP, Geslin P, Allain P. [Severe anaphylactoid reactions after intravenous corticosteroids. Report of a case and review of the literature]. *Therapie*. 1990;45:505-8. French.
4. Dajani BM, Sliman NA, Shubair KS, Hamzeh YS. Bronchospasm caused by intravenous hydrocortisone sodium succinate (Solu-Cortef) in aspirine-sensitive asthmatics. *J Allergy Clin Immunol*. 1981;68:201-4.
5. Rachid R, Leslie D, Schenider L, Twarog F. Hypersensitivity to systemic corticosteroids: an infrequent but potentially life-threatening condition. *J Allergy Clin Immunol*. 2011;127:524-8.
6. Koutsostathis N, Vovolis V. Severe immunoglobulin E-mediated anaphylaxis to intravenous methylprednisolone succinate in a patient who tolerated oral methylprednisolone. *J Investig Allergol Clin Immunol*. 2009;19:330-2.
7. Freedman MD, Shocket AL, Chapel N, Gerber JG. Anaphylaxis after intravenous methylprednisolone administration. *J Am Med Assoc*. 1981;245:607-8.
8. Ventura MT, Calogiuri GF, Matino MG, Dagnello M, Buquicchio R, Foti C, Di Corato R. Alternative glucocorticoids for use in cases of adverse reaction to systemic glucocorticoids: a study on 10 patients. *Br J Dermatol*. 2003;148:139-41.
9. Venturini M, Lobera T, del Pozo MD, González I, Blasco A. Immediate hypersensitivity to corticosteroids. *J Investig Allergol Clin Immunol*. 2006;16:51-6.
10. Kamm GL, Hagemeyer KO. Allergic-type reactions to corticosteroids. *Ann Pharmacother*. 1999;33:451-60.

■ Manuscript received November 26, 2014; accepted for publication February 5, 2015.

Francisco Álvarez Caro

C/ Álvaro Flórez Estrada 2, 12 CI
33012 Oviedo (Asturias)
Spain

E-mail: franciscoalvarez130@msn.com

Rhinitis Due to Larvae Used in Pet Food

Uriarte SA¹, Fernández-Nieto M^{1,2}, Carnés J³, López-Matas MA³, Sastre J^{1,2}

¹Fundación Jiménez Díaz, Allergy Department, Madrid, Spain

²CIBER de Enfermedades Respiratorias, Instituto de Salud Carlos III, Spain

³R&D Department, Laboratorios LETI SL, Madrid, Spain

Key words: Rhinitis. *Tenebrio molitor*. Larvae. Pet food.

Palabras clave: Rinitis. *Tenebrio molitor*. Larvae. Pet food.

Insect larvae are potent sensitizers in the workplace and in other settings [1,2]. Several larvae have been reported to be allergenic, including *Tenebrio molitor* [3], *Galleria mellonella* [4], *Calliphora erythrocephala* [5], *Calliphora vomitoria* [6], and *Lucila caesar*.

The life cycle of *T molitor* consists of 3 stages, namely, larva, pupa, and adult. Owing to its high protein content (20%) and high lipid and chitin content, the larva of *T molitor* is used as live food for insectivorous pets, fishing bait, and human consumption. Humans may be exposed to this larva in the workplace or at home.

We report the case of a 54-year-old woman with no previous history of atopic disease who presented at the outpatient clinic of our hospital with a 4-month history of persistent dry cough that tended to worsen during the morning and late afternoon. Her condition did not improve despite treatment with antitussive drugs. During the previous months, the patient had also experienced increasingly recurrent episodes of sneezing, nasal itching, and rhinorrhea at home with no apparent trigger, although she did notice an improvement while she was away from home. All of the symptoms were observed outside springtime.

The patient had 7 pet geckos with which she had been in close contact for 3 years, feeding them *T molitor* larvae twice a day (morning and afternoon). She did not use a protective mask or gloves to feed the animals.

A physical examination revealed no skin lesions, and findings of anterior rhinoscopy and cardiopulmonary auscultation were normal. A chest x-ray showed asymmetry in the soft tissue, with no other abnormalities. The Mantoux test was negative.

Skin prick tests were performed with common inhalants, and the only reactions were to olive and grass pollen. Prick-by-prick testing was positive for dermal remnants of *T molitor* larvae (4×5 mm) and negative for dermal remnants of gecko. Prick testing with aqueous extract of *T molitor* larvae (10% wt/vol) was positive (6×4 mm) in the patient but negative in 5 controls, who had never been exposed to *T molitor*. Spirometry results were normal, with no reversibility after inhalation of a bronchodilator. The fraction of exhaled nitric oxide (FeNO) was 13 ppb. The result of a methacholine challenge test was negative (PC₂₀ >16 mg/dL).

A specific nasobronchial provocation (SNBP) was performed with an aqueous extract of *T molitor* larvae (10% wt/vol) using the tidal volume method with a face mask covering the nose and mouth as previously described [7]. The patient presented intense anterior rhinorrhea 6 minutes after the procedure commenced. No significant changes in acoustic rhinometry parameters were observed during the 24 hours after SNBP; in fact, the maximum fall in minimal cross-sectional area in acoustic rhinometry was 13.8% at 20 minutes after SNBP. Forced expiratory volume during the first second (FEV₁) did not change during the 24 hours after SNBP. FEV₁ and peak expiratory flow were monitored using a computerized asthma monitor (Amos, Jaeger) every hour except when the patient was sleeping. A methacholine challenge test performed 24 hours after SNBP was negative (PC₂₀ >16 mg/dL), and no significant change in FeNO was recorded 24 hours after SNBP (11.4 ppb). Baseline nasal cytology revealed few leukocytes and no eosinophils, and the post-SNBP cytology revealed eosinophils (10%). The patient had not come into contact with *T molitor* larvae in the 2 months before the SNBP, and her respiratory symptoms had improved significantly.

A *T molitor* larvae extract was prepared by homogenization in PBS 0.01 M, pH 7.4. Two consecutive extractions were made (4 hours at 4°C and overnight at 4°C). The content was centrifuged and the supernatant collected, dialyzed, filtered, frozen, and freeze-dried. Protein content was measured using the Lowry-Biuret method (Sigma).

SDS-PAGE with *T molitor* larvae extract (20 µg protein/lane) (Figure, A) revealed several protein bands. The most abundant bands were observed at 65, 25, 20, and 12 kDa. An IgE immunoblotting analysis performed with the patient's serum revealed 4 bands at approximately 65, 40, 35, and 28 kDa (Figure, B).

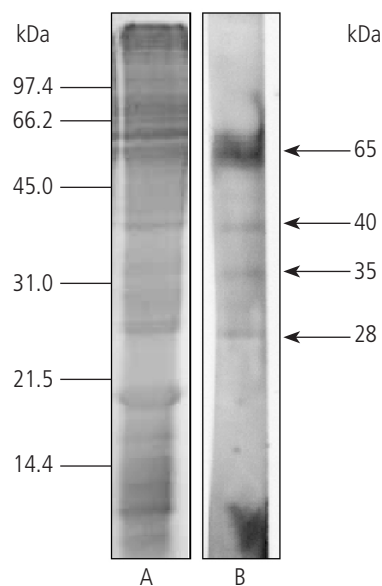


Figure. Protein SDS-PAGE (A) and immunoblot (B) with serum IgE from the patient. Twenty micrograms of the lyophilized *Tenebrio molitor* extract was loaded in both cases. For the immunoblot, the serum was used half-diluted. Molecular weight markers are shown on the left. IgE-binding bands are marked with arrows.

We report a case of allergy caused by exposure to *T molitor* larvae in the home. The SNBP showed a positive nasal response based on the presence of nasal symptoms during the test and the presence of eosinophils (10%) in post-SNBP nasal cytology, although according to the criteria of Dordal et al [8] (ie, positivity in SNBP defined as a >25% fall in minimal cross-sectional area), no significant changes were recorded in post-SNBP acoustic rhinometry parameters. We report a rare case of IgE-mediated rhinitis due to *T molitor* larvae in a patient exposed at home. We recorded a positive nasal response (symptoms and eosinophils in nasal cytology), a positive skin prick test result to aqueous extract of *T molitor* larvae, and an IgE immunoblotting result that revealed 4 IgE proteins binding to *T molitor* larvae extract. We also describe IgE-binding proteins that have not been described previously. In 1990, Schroeckenstein et al [9] described protein bands of 32 and 52 kDa in a *T molitor* pupa extract and bands of 22, 61, and 67 kDa at other stages of this insect. We did not find any similarity to the IgE-binding bands reported by our group in a patient with allergy to *Galleria mellonella* larvae (bands of 18, 23, 24, 38, 70, 73, and 77 kDa) [10].

Acknowledgments

We are grateful to Oliver Shaw for his help with the English version of the manuscript.

Funding

The authors declare that no funding was received for the present study.

Conflicts of Interest

The authors declare that they have no conflicts of interest.

References

1. Siracusa A, Bettini P, Bacocoli R, Severini C, Verga A, Abbritti G. Asthma caused by live fish bait. *J Allergy Clin Immunol*. 1994;93:424-30.
2. Siracusa A, Marcucci F, Spinozzi F, Marabini A, Pettinari L, Pace ML, Tacconi C. Prevalence of occupational allergy due to live fish bait. *Clin Exp Allergy*. 2003;33:507-10.
3. Bernstein DI, Gallagher JS, Bernstein IL. Mealworm asthma: clinical and immunologic studies. *J Allergy Clin Immunol*. 1983;72:475-80.
4. Villalta D, Martelli P, Mistrello G, Roncarolo D, Zanoni D. Bee moth (*Galleria mellonella*) allergic reactions are caused by several thermolabile antigens. *Allergy*. 2004;59:1002-5.
5. Sestini P, Innocenti A. Late asthmatic reaction due to larvae of *Calliphora erythrocephala* used as fishing bait. *Allergol Immunopathol (Madr)* 1987;15:25-8.
6. Pazzaglia M, Tullo S, Tosti A. Occupational protein contact dermatitis due to *Calliphora vomitoria* larvae (maggots) bred as fishing bait. *Contact Dermatitis*. 2003;48:176.
7. Ruiz-García M, García del Potro M, Fernández-Nieto M, Barber D, Jimeno-Nogales L, Sastre J. Profilin: a relevant aeroallergen? *J Allergy Clin Immunol*. 2011;128:416-8.
8. Dordal MT, Lluch-Bernal M, Sánchez MC, Rondón C, Navarro A, Montoro J, Matheu V, Ibáñez MD, Fernández-Parra B, Dávila I, Conde J, Antón E, Colás C, Valero A. Allergen-specific nasal provocation testing: review by the rhinoconjunctivitis committee of the Spanish Society of Allergy and Clinical Immunology. *J Investig Allergol Clin Immunol*. 2011;21(1):1-12.
9. Schroeckenstein DC, Meier-Davis S, Bush RK. Occupational sensitivity to *Tenebrio molitor* Linnaeus (yellow mealworm). *J Allergy Clin Immunol*. 1990;86:182-8.
10. Madero MF, Enríquez-Matas A, Fernández-Nieto M, Sastre B, Del Pozo V, Pastor C, Quirce S, Sastre J. Characterization of allergens from the fish bait *Galleria mellonella*. *J Allergy Clin Immunol*. 2007;119:1021-2.

■ Manuscript received December 20, 2014; accepted for publication February 6, 2015.

Silvia Uriarte

Fundación Jiménez Díaz
Reyes Católicos Avenue 2
28040 Madrid
Spain
E-mail: sauriarte@fjd.es

Analysis of Mutations in the *IL2RG* Gene in 2 Asian Infants With X-linked Severe Combined Immunodeficiency

Hara Y¹, Kobayashi N¹, Maruyama Y¹, Motobayashi M¹, Shigemura T¹, Ohara O², Agematsu K³, Koike K¹

¹Department of Pediatrics, Shinshu University School of Medicine, Matsumoto, Japan

²Department of Technology Development, Kazusa DNA Research Institute, Chiba, Japan

³Department of Infection and Host Defense, Shinshu University, Graduate School of Medicine, Matsumoto, Japan

Key words: X-linked severe combined immunodeficiency. *IL2RG* mutation. CD132 expression. Genotype-phenotype.

Palabras clave: Inmunodeficiencia combinada severa ligada a x. Mutación *IL2RG*. Expresión CD132. Genotipo-fenotipo.

Severe combined immunodeficiency (SCID) comprises a genetically heterogeneous group of primary immunodeficiency disorders [1]. Mutations in the *IL2RG* gene encoding the common γ chain of the interleukin-2 receptor (CD132) are found exclusively in X-linked SCID, which accounts for a half of all SCID cases, and result in a lack of both T and NK cells (T⁻B⁻NK⁻ phenotype) in most patients [2]. CD132 is a type I transmembrane glycoprotein that serves as a subunit for many cytokine receptors, including IL-2, IL-4, IL-7, IL-9, IL-15, and IL-21 [3,4]. The present study describes 2 types of mutations detected in the *IL2RG* gene of 2 Asian male infants with SCID: a novel missense mutation in exon 3 and a nonsense mutation in exon 2. Although the latter is listed at the National Human Genome Research Institute (<http://www.research.nhgri.nih.gov/scid/>), its clinical phenotype has not yet been reported.

Patient 1 was a 6-month-old Japanese male firstborn who was delivered normally following an uneventful pregnancy at 36 weeks of gestation to a nonconsanguineous couple. There was no family history of immunodeficiency. At 2 weeks of age, the patient was found to have white plaques on his palate and was diagnosed with oropharyngeal candidiasis. At 5 months, he experienced recurrent fever with cough and was admitted to Shinshu University Hospital, Nagano, Japan for treatment. On admission, his white blood cell count was 3980/ μ L (neutrophils, 1910/ μ L; and lymphocytes, 1234/ μ L). Flow cytometry revealed decreased numbers of CD3⁺ T cells (99/ μ L) and CD16⁺CD56⁺ NK cells (24/ μ L) but a normal B-cell count (1098/ μ L). Serum IgG, IgA, and IgM levels were low (26 mg/dL [normal range for age, 290-950 mg/dL], 1 mg/dL [8-50 mg/dL], and 4 mg/dL [46-176 mg/dL], respectively). Computed tomography (CT) of the chest revealed a absent thymus and an extensive ground-glass pattern in all lung fields.

Patient 2 was a 2-month-old male firstborn who was delivered at full term to a nonconsanguineous couple of Chinese origin. Three of his maternal uncles had died of unknown causes during infancy. The patient experienced high

fever at 2 months of age and was referred to Shinshu University Hospital 1 week later. Physical examination revealed mild hepatomegaly. The white blood cell count was low (1110/ μ L), and severe neutropenia (55/ μ L) was observed. The lymphocyte count was also reduced (666/ μ L), with marked decreases in numbers of CD3⁺ T cells (133/ μ L) and CD16⁺CD56⁺ NK cells (33/ μ L). The B-cell count was normal (483/ μ L). Serum transaminase levels were high (aspartate aminotransferase, 313 [22-64] IU/L; and alanine aminotransferase, 406 [13-55] IU/L), as were lactate dehydrogenase levels (649 [203-410] IU/L). The patients also had hypogammaglobulinemia (IgG, 289 [290-960] mg/dL; IgA, 2 [0-28] mg/dL; and IgM, 6 [26-112] mg/dL). CT of the chest revealed a absent thymus. Cultures of blood, sputum, throat swab, and urine were negative. Cytomegalovirus (CMV) antigenemia was detected. Administration of ganciclovir and foscarnet led to an improvement in liver function. One week later, the values of neutrophils and CD16⁺CD56⁺ NK cells had risen to 1675/ μ L and 276/ μ L, respectively. However, CMV antigenemia was not completely negative.

Flow cytometry revealed that expression of CD132 on peripheral blood CD19⁺CD20⁺ B cells was remarkably less intense in cases 1 and 2 than in healthy controls (Figure, A). CD132 expression in CD4⁺ and CD8⁺ T cells was markedly elevated in patient 1, yet apparently normal in patient 2. However, expression of CD132 on CD56⁺ NK cells in case 2 was low. Fluorescence in situ hybridization analysis of the X and Y chromosomes of bead-selected CD3 lymphocytes revealed 46XX chromosomes, showing that the T cells were maternally engrafted for both cases, whereas 98% of CD56⁺ NK cells in patient 2 expressed XY signals, indicating that they were of patient origin.

In patient 1, amplification and sequencing of the coding region of the *IL2RG* gene using reverse-transcriptase polymerase chain reaction (RT-PCR) revealed a nonsense mutation at the 3' end of exon 2 (c. 269 G>A, p. Trp90X). Electrophoresis of the RT-PCR product using primers spanning exons 1 through 8 revealed a faint, short mRNA band and a faint, normal-sized band (Figure, B). No bands from the patient's mRNA were detected with primers for exons 2 and 3. We therefore considered that the faint, normal-sized band could be traced back to maternal T cells. Sequence analysis of the patient's mRNA revealed that exon 2 (c. 208 to 361) had been skipped (Figure, B), thus suggesting markedly reduced expression of *IL2RG* mRNA associated with exon 2 skipping. Meanwhile, patient 2 had a single base deletion at exon 3 (c. 359delA) that resulted in a frameshift mutation. This pathological variant of p. Lys120ArgfsX26 has not been previously described.

Both patients underwent unrelated cord blood cell transplantation after conditioning with thymoglobulin, fludarabine, and melphalan. Patient 1 achieved immunological reconstitution and successful clinical recovery. Patient 2 achieved reconstitution of the immune system but developed CMV encephalitis 1 month after cord blood cell transplantation that caused a mobility disorder of the lower limbs.

We report 2 infants with X-linked SCID and mutations that caused stop or exon skipping in the *IL2RG* gene. A Trp90X mutation caused a T⁻B⁻NK⁻ phenotype, whereas

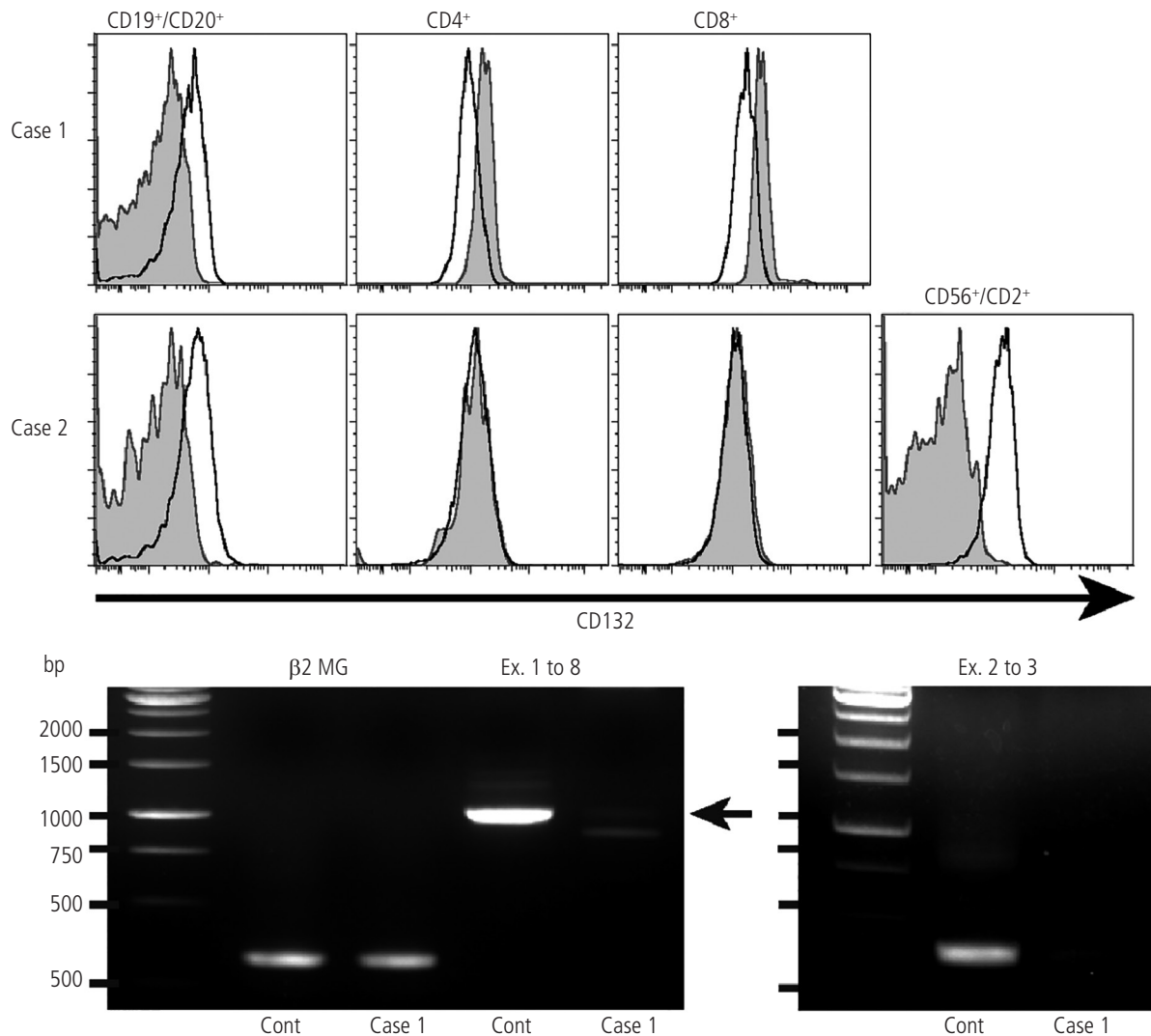


Figure A. Surface interleukin 2 receptor γ (*IL2RG*) expression on $CD19^+CD20^+$ B cells, $CD4^+$ T cells, $CD8^+$ T cells, and $CD2^+CD56^+$ NK cells of patients (shaded areas) and healthy controls (outlined areas). Cells were incubated with anti-*IL2RG* (CD132)-PE and surface markers for each lineage and analyzed using flow cytometry. **B.** Reverse-transcriptase polymerase chain reaction (RT-PCR) analysis of *IL2RG* mRNA using primers spanning exon 1 to exon 8 or exon 2 and exon 3 primer pairs of case 1 and a healthy control. Electrophoresis of the RT-PCR product from primers spanning exon 1 to exon 8 revealed a faint short-length mRNA band (arrow). Cont indicates control; Ex, exon.

the novel mutation Lys120ArgfsX26 resulted in a $T^+B^+NK^+$ phenotype. SCID patients with near normal numbers of NK cells have been reported [5]. Although most $T^+B^+NK^+$ SCID cases are caused by a deficiency in the interleukin-7 receptor α chain, an *IL2RG* deficiency may also be involved. Patient 2 was diagnosed as having X-linked SCID during the first infection of his life and underwent hematopoietic stem cell transplantation. However, he later experienced neurological complications due to CMV encephalitis. Neonatal screening of T-cell receptor excision is useful for detecting patients with SCID, and screening programs have been established in the United States and Europe [6,7]. Early diagnosis by means of such a screening test at birth, before infection, will improve the prognosis and quality of life of SCID patients.

Funding

This work was supported by a Health Labor Sciences Research Grant from The Ministry of Health Labor and Welfare.

Conflicts of Interest

The authors declare that they have no conflicts of interest.

References

1. Buckley RH. Molecular defects in human severe combined immunodeficiency and approaches to immune reconstitution. *Annu Rev Immunol.* 2004;22:625-55.

2. Buckley RH, Schiff RI, Schiff SE, Markert ML, Williams LW, Harville TO, Roberts JL, Puck JM. Human severe combined immunodeficiency: genetic, phenotypic, and functional diversity in one hundred eight infants. *J Pediatr*. 1997;130(3):378-87.
3. Sugamura K, Asao H, Kondo M, Tanaka N, Ishii N, Ohbo K, Nakamura M, Takeshita T. The interleukin-2 receptor gamma chain: its role in the multiple cytokine receptor complexes and T cell development in XSCID. *Annu Rev Immunol*. 1996;14:179-205.
4. Habib T, Senadheera S, Weinberg K, Kaushansky K. The common gamma chain (gamma c) is a required signaling component of the IL-21 receptor and supports IL-21-induced cell proliferation via JAK3. *Biochemistry*. 2002;41(27):8725-31.
5. Ginn SL, Smyth C, Wong M, Bennetts B, Rowe PB, Alexander IE. A novel splice-site mutation in the common gamma chain (gamma c) gene IL2RG results in X-linked severe combined immunodeficiency with an atypical NK+ phenotype. *Hum Mutat*. 2004;23(5):522-3.
6. Chan K, Puck JM. Development of population-based newborn screening for severe combined immunodeficiency. *J Allergy Clin Immunol*. 2005;115(2):391-8.
7. Adams SP, Rashid S, Premachandra T, Harvey K, Ifederu A, Wilson MC, Gaspar HB. Screening of neonatal UK dried blood spots using a duplex TREC screening assay. *J Clin Immunol*. 2014;34(3):323-30.

■ *Manuscript received October 20, 2014; accepted for publication February 9, 2015.*

Norimoto Kobayashi

Department of Pediatrics, Shinshu University School of
Medicine
Asahi 3-1-1, Matsumoto 390-8621, Nagano, Japan
E-mail: norimoto@shinshu-u.ac.jp