

See discussions, stats, and author profiles for this publication at: <https://www.researchgate.net/publication/276158763>

# Simple facet joint repair with dynamic pedicular system: Technical note and case series

Article in *Journal of craniovertebral junction and spine* · April 2015

DOI: 10.4103/0974-8237.156049

## CITATIONS

## READS

75

7 authors, including:



**Ali Fahir Ozer**

Koc University and American Hospital in Istanbul

210 PUBLICATIONS 1,553 CITATIONS

SEE PROFILE



**Tunc Oktenoglu**

American Hospital

118 PUBLICATIONS 823 CITATIONS

SEE PROFILE



**Phillip Cezayirli**

Albert Einstein College of Medicine

6 PUBLICATIONS 18 CITATIONS

SEE PROFILE



**Deniz U. Erbulut**

University of Toledo

34 PUBLICATIONS 116 CITATIONS

SEE PROFILE


Some of the authors of this publication are also working on these related projects:



neurosergery [View project](#)

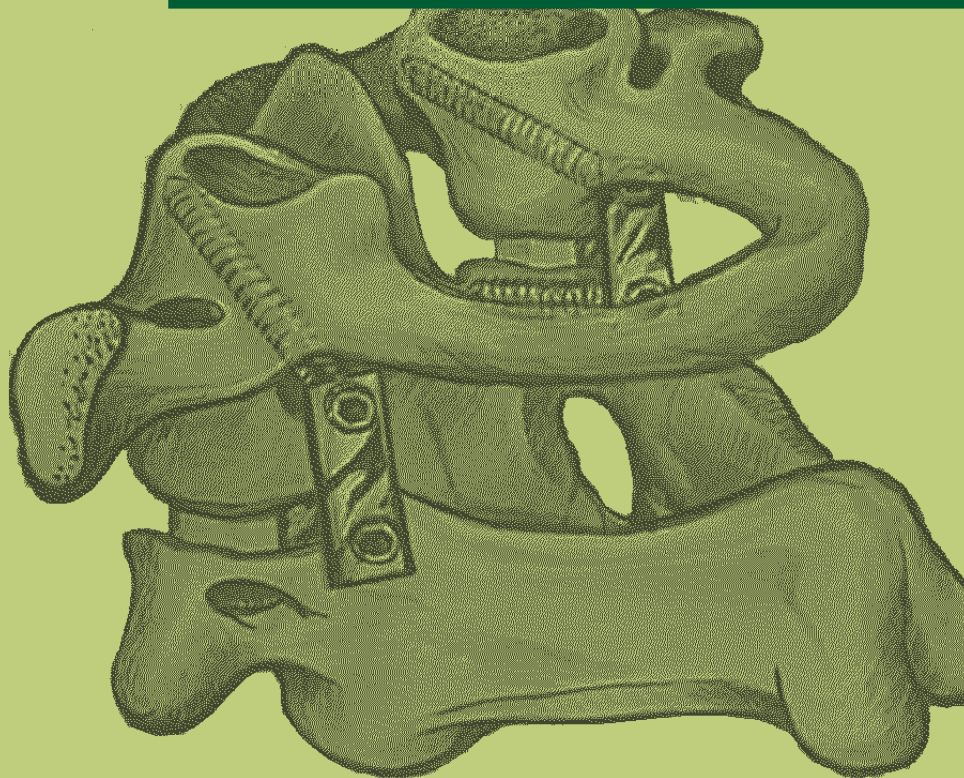

metastatic lung adenocarcinoma in a non-functioning gonatotroph pituitary adenoma [View project](#)



# Journal of Craniovertebral Junction & Spine

[www.jcvjs.com](http://www.jcvjs.com)



Apr-Jun 2015 / Vol 6 / Issue 2

## Original Article

# Simple facet joint repair with dynamic pedicular system: Technical note and case series

Ali Fahir Ozer, Tuncer Suzer, Mehdi Sasani<sup>1</sup>, Tunc Oktenoglu<sup>1</sup>, Phillip Cezayirli<sup>2</sup>, Hosein Jafari Marandi<sup>3</sup>, Deniz Ufuk Erbulut<sup>4</sup>

Koc University Medical School, Neurosurgery Department, <sup>1</sup>American Hospital, Neurosurgery Department, <sup>4</sup>Koc University, Mechanical Engineering Department, Istanbul, Turkey, <sup>2</sup>Albert Einstein College of Medicine/Montefiore Medical Center, Neurosurgery Residency, New York, USA, <sup>3</sup>Iran University of Medical Science, Hazrat Rasoul Medical Complex, Spine Surgery Division, Tehran, Iran

Corresponding author: Prof. Ali Fahir Ozer, Department of Neurosurgery, Koc University School of Medicine, Rumelifeneri Yolu Sariyer, Istanbul - 34450, Turkey. E-mail: [alifahirozer@gmail.com](mailto:alifahirozer@gmail.com)

Journal of Craniovertebral Junction and Spine 2015, 6:17

## Abstract

**Purpose:** Facet joints are important anatomical structures for the stability of spine. Surgical or degenerative damage to a facet joint may lead to spinal instability and causes clinical problems. This article explains the importance of facet joints, reviews facet replacement systems, and describes a simple and effective method for facet replacement after surgical removal of facet joints. **Materials and Methods:** Ten patients were operated with the diagnosis of unilateral nerve root compression secondary to facet degeneration. The hypertrophic facet joints were removed with microsurgical techniques and the roots were decompressed. Then, a unilateral artificial facet joint was created using two hinged screws and a dynamic rod. **Results:** The clinical outcome of all the patients was determined good or excellent at second and last follow-up (mean 13.3 months) controls using visual analog scale (VAS) and Oswestry Disability Index (ODI) scores. Radiological evaluations also demonstrated no implant-related complications. **Conclusions:** The authors suggest that, if removal of a facet joint is necessary to decompress the nerve roots, the joint can be replaced by a construct composed of two hinged screws connected by a dynamic rod. This simple system mimics the function of a normal facet joint and is an effective technique for unilateral facet joint replacement.

**Key words:** Dynamic rod, hinged screw, lumbar facet joint replacement, unilateral dynamic stabilization

## INTRODUCTION

Lumbar facet joints are important providers of stability in lumbar spinal segments. Changes to facets are part of the degenerative process in functional segments of the spine. During degeneration, facet joint surfaces become damaged

and separate from each other. Capsular ligaments may tear and increase in volume due to hypertrophy. As well, facets begin to move medially and exhibit tropism. These changes reduce vertebral foramina volume, and ultimately cause anatomic and dynamic foraminal stenosis. The nerve root in each involved foramen becomes compressed by surrounding degenerative tissues.

Most patients with facet degeneration are pain-free in supine position, but experience pain during standing and walking. Standing position increases loading on the lumbar spine and reduces foraminal volume. This narrowing of the foramina compresses the involved nerve roots, and the resultant ischemia leads to malnourishment of the nerve tissue. These pathological changes cause pain to radiate to the leg along the nerve root trajectory.

Access this article online	
Quick Response Code:	Website: <a href="http://www.jcvjs.com">www.jcvjs.com</a>
	DOI: 10.4103/0974-8237.156049



Many attempts have been made to replace degenerated facet joints. Instrumentation systems such as the Total Posterior System (TOPS, Impliant Spine, NJ, USA), the Total Facet Arthroplasty System (TFAS, Archus Orthopedics, USA), the Dynamic Stabilization System (DSS, ParadigmSpine, NY, USA), and Stabilimax NZ (Applied Spine, USA) have been used as artificial facets; however, these constructs do not create an artificial facet joint and none has yielded optimal results. This article describes a simple method for replacing damaged facet joints.

## MATERIALS AND METHODS

### Patient population

Ten patients (five men and five women) ranging in age from 54 to 80 years (mean 70.1 years) underwent facet joint replacement surgery. Clinical data of the patients was summarized in Table 1. The major complaints were back and leg pain which was particularly intense, while walking in all of the patients. The treatment history of the patients included multiple

physiotherapy programs and injection treatments those had yielded no improvement. The patients' neurologic examinations were normal. T1- and T2-weighted magnetic resonance imaging (MRI) showed degenerative changes particularly unilateral facet joints and disc tissue at foraminal level in all patients. The most marked changes were a hypertrophied capsular ligament, increased joint distance, and effusion in the facet joint [Figure 1].

### Surgical technique

All the patients underwent a unilateral paravertebral muscle dissection and facet joint removal. The facet joints were totally removed and the nerve roots were dissected and decompressed with operating microscope. After decompression step, two hinged screws (Safinaz, Medicon Company, Turkey) were placed in pedicles of vertebra with the assistance of microscope and C-arm (Siemens, Erlangen, Germany). Then, a dynamic rod (BalanC, Medtronic Sofamor Danek, Memphis, TN, USA) was connected to the two screws and stabilization step was completed [Figure 2].

### Evaluation of surgical outcomes

The main postoperative follow-up period was 13.3 months (range, 12-16 months). All the patients were examined first

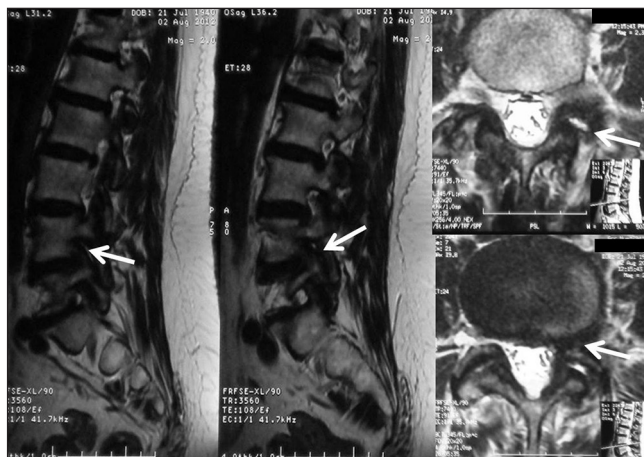

Figure 1: Sagittal and axial magnetic resonance images show severe degenerative changes in the left facet joint at L3-4 level. The arrows highlight the hypertrophic capsular ligament, increased joint distance, and joint effusion

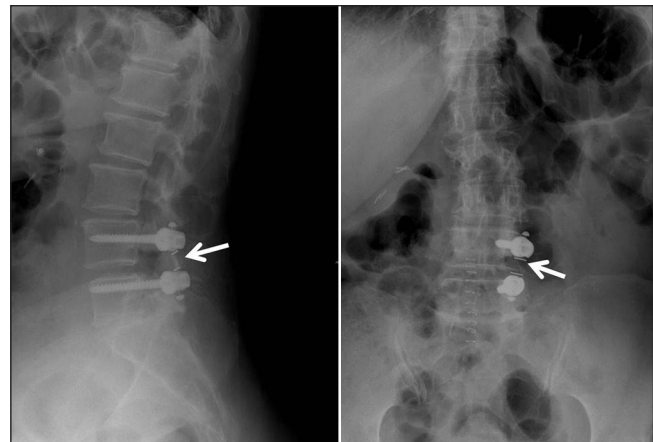


Figure 2: Lateral and posterior-anterior radio graphs show the screws and BalanC rod system replacing the left facet joint at L3-4

Table 1: Summary of patients' clinical data

Patient number	Age, y/sex	Level	Follow-up, months	VAS			ODI		
				Preop	6 months	12 months	Preop	6 months	12 months
1	61, F	L4-5	12	7	4	2	82	56	32
2	73, F	L4-5	12	8	3	1	68	48	16
3	74, F	L4-5	15	8	5	2	72	62	28
4	80, M	L4-5	16	7	5	3	64	46	36
5	63, M	L4-5	12	6	3	1	56	36	12
6	69, M	L4-5	14	8	4	2	64	28	8
7	78, M	L4-5	12	8	3	1	72	16	16
8	74, F	L4-5	13	7	3	2	68	28	26
9	75, F	L5-S1	15	8	5	3	76	20	10
10	54, M	L4-5	12	7	4	1	86	26	20
Mean	70, I		13,3	7,4	3,9	1,8	70,8	36,6	20,4

at 1 month and then 6 and 12 months after surgery. Clinical outcomes were assessed using visual analog scale (VAS) and Oswestry Disability Index (ODI) scores. Radiologic evaluation was performed with X-ray and computed tomography (CT).

## RESULTS

There were no surgery-related complications in none of the patients and all were discharged in very good neurological condition. Ten patients had marked improvement and able to walk without help at first examinations 1 month after surgery. The clinical outcome of all the patients was determined good or excellent at second and last follow-up controls using VAS and ODI scores [Table 1].

Radiographs and CT confirmed that the screws had good concordance with the vertebral bone and there was no pull-out or loosening of the screws.

## DISCUSSION

Facet joints play an important role in spinal function and are reported to provide 39% of the biomechanical stability of spinal segments.<sup>[1]</sup> Elimination of these joints from a functional spinal unit has negative effects on the intervertebral discs, the anterior longitudinal ligament, and the posterior longitudinal ligament.<sup>[2]</sup> Removal of one facet joint from a lumbar spinal segment is known to cause degeneration of the vertebral disc and the other facet joint of the segment.<sup>[3,4]</sup> When one or both of these joints are degenerated, the entire spinal unit eventually becomes painful and nonfunctional. As well, the center of rotation for the segment shifts away from where it exists when the facet joints are intact.<sup>[5]</sup>

Considering the functional importance of facet joints, when removal of a facet is required, it is important to apply an implant that will simulate the role of the facet joint. The literature describes numerous pioneered systems<sup>[5-8]</sup> for total facet replacement, including TOPS, DSS, TFAS, and Stabilimax NZ; but none of these has yielded satisfactory clinical results worldwide. Moreover, surgical application of TOPS is reported to be difficult, and DSS and Stabilimax NZ are originally complex dynamic systems. The rods in these systems are designed such that the constructs act as facet joints. In reviewing the literature there are a few article about TOPS, DSS, and Stabilimax NZ; but not enough clinical data is available to use these systems.

In previous cases at our clinic where unilateral facet removal has been required, we used a combination of dynamic screws and a rigid rod on the affected side only.<sup>[9]</sup> Hinged screws provide some degree of facet joint function and we have achieved some degree of clinical success with this type of construct, but the results have not been ideal. This system is more rigid than a healthy, natural facet joint because the rigid rod is not mobile. As well, there is always asymmetric movement in the functional segment because one side has a rigid rod in place,

whereas, the other side is a mobile facet joint. In contrast to our previous system, using a BalanCrod between two dynamic screws provides more natural facet joint motion. The construct of adynamic BalanC rod with hinged screws provides symmetric loading and places the screws under less stress.<sup>[10]</sup>

This technical note and report of 10 cases describe a simple procedure for treating foraminal stenosis caused by degenerative facet disease. Use of two hinged screws connected by a dynamicrod mimics the flexibility of a normal facet joint. The segmental flexibility provided by dynamic systems minimizes screw failure and breakage.<sup>[10]</sup> However, in cases where a bone graft is not incorporated, any dynamic construct that is applied must withstand constant loading and have long-term durability. The longer a screw is exposed to constant loading, the higher the probability that the screw will become loose. Therefore, screw loosening is considered a drawback of dynamic stabilization systems.<sup>[11]</sup> Our previous studies and the report of Schmoelz *et al.*,<sup>[10]</sup> demonstrated that the hinged dynamic screw requires less stress shielding than a standard rigid screw.<sup>[12-14]</sup> Hinged screws are used in dynamic systems to stabilize spinal segments in patients with painful black disc, degenerative spondylolisthesis, or recurrent disc herniation.<sup>[15-20]</sup> It has been reported that, during flexion, dynamic screw-rod fixation at a lumbar facet joint sustains approximately 40% less loading force than rigid screw-rod fixation.<sup>[10,12]</sup> In a previous biomechanical study, we demonstrated that if dynamic screws are used with rigid rods, this kind of construct caused less stress shielding than the rigid screw and if dynamic screws used with dynamic rods, in this kind of construct causes more stress shielding than previous construct.<sup>[13]</sup> Considering these factors, we believe that the hinged screws that we used in our patient carry less risk of implant loosening and failure than rigid screws.

The combination of dynamic screws and a dynamic rod simulate normal facet joint motion and address the problem of facet joint loss. In our opinion, there is no need to develop more complicated facet joint systems. This note describes surgical ease and clinical success with such a posterior dynamic stabilization system for facet joint removal. Unilateral application on the affected side is adequate and provides the flexibility needed to ensure a functional spinal unit. We believe that this technique is a good alternative to other approaches for facet replacement surgery.

## REFERENCES

1. Adams MA, Hutton WC. The mechanical function of the lumbar apophyseal joints. *Spine (Phila Pa 1976)* 1983;8:327-30.
2. Zander T, Rohlmann A, Klöckner C, Bergmann G. Influence of graded facetectomy and laminectomy on spinal biomechanics. *Eur Spine J* 2003;12:427-34.
3. Cusick JF, Yoganandan N, Pintar FA, Reinartz JM. Biomechanics of sequential posterior lumbar surgical alterations. *J Neurosurg* 1992;76:805-11.
4. Park JH, Bae CW, Jeon SR, Rhim SC, Kim CJ, Roh SW. Clinical and radiological outcomes of unilateral facetectomy and interbody fusion using expandable cages for lumbosacral foraminal stenosis. *J Korean Neurosurg Soc* 2010;48:496-500.
5. McAfee P, Khoo LT, Pimenta L, Capuccino A, Sengoz A, Coric D, *et al.* Treatment of lumbar spinal stenosis with a total posterior arthroplasty prosthesis

- Implant description, surgical technique, and a prospective report on 29 patients. *Neurosurg Focus* 2007;22:E13.
6. Panjabi MM. The stabilizing system of the spine. Part II. Neutral zone and instability hypothesis. *J Spinal Disord* 1992;5:390-7.
  7. Phillips FM, Tzermiadianos MN, Voronov LI, Havey RM, Carandang G, Renner SM, et al. Effect of the Total Facet Arthroplasty system after complete laminectomy-facetectomy on the biomechanics of implanted and adjacent segments. *Spine J* 2009;9:96-102.
  8. Sengupta D, Mulholland RC, Pimenta L. Prospective clinical study of dynamic stabilization with the DSS system in isolated activity related mechanical low back pain, with outcome at minimum 2-year follow-up. *Spine J* 2006;6:147.
  9. Bozkus H, Sasani M, Oktenoglu T, Aydin AL, Ozer AF. Unilateral dynamic stabilization for unilateral lumbar spinal pathologies; a new surgical concept. *Turk Neurosurg* 2012;22:718-23.
  10. Schmoelz W, Huber JF, Nydegger T, Dipl-Ing, Claes L, Wilke HJ. Dynamic stabilization of the lumbar spine and its effects on adjacent segments: An *in vitro* experiment. *J Spinal Disord Tech* 2003;16:418-23.
  11. Welch WC, Cheng BC, Awad TE, Davis R, Maxwell JH, Delamarter, et al. Clinical outcomes of the Dynesys dynamic neutralization system: 1-year preliminary results. *Neurosurg Focus* 2007;22:E8.
  12. Bozkus H, Şenoğlu M, Baek S, Sawa AG, Ozer AF, Sonntag VK, et al. Dynamic lumbar pedicle screw-rod stabilization: *In vitro* biomechanical comparison with standard rigid pedicle screw-rod stabilization. *J Neurosurg Spine* 2010;12:183-9.
  13. Erbulut DU, Kiapour A, Oktenoglu T, Ozer AF, Goel V. Kinematical and load sharing effect of a novel posterior dynamic stabilization system implanted in lumbar spine. Presented at American Society of Biomechanics, Gainesville, FL, USA; 2012.
  14. Erbulut DU, Oktenoglu T, Ozer AF, Lazoglu I, Goel V, Kaul V, et al. Biomechanical evaluation of posterior lumbar spine dynamic and rigid stabilization *in vitro*. Lumbar Spine Research Society, Chicago, USA; 2011.
  15. Anand N, Baron EM. Role of dynesys as pedicle-based nonfusion stabilization for degenerative disc disorders. *Adv Orthop* 2012;2012:218385.
  16. Kaner T, Ozer AF. Dynamic stabilization for challenging lumbar degenerative diseases of the spine: A review of the literature. *Adv Orthop* 2013;2013:753470.
  17. Kaner T, Sasani M, Oktenoglu T, Aydin AL, Ozer AF. Clinical outcomes of degenerative lumbar spinal stenosis treated with lumbar decompression and the Cosmic "semi-rigid" posterior system. *SAS J* 2010;4:99-106.
  18. Maleci A, Sambale RD, Schiavone M, Lamp F, Ozer F, von Stempel A. Nonfusion stabilization of the degenerative lumbar spine. *J Neurosurg Spine* 2011;15:151-8.
  19. Oktenoglu T, Ozer AF, Sasani M, Kaner T, Canbulat N, Ercelen O, et al. Posterior dynamic stabilization in the treatment of lumbar degenerative disc disease: 2-year follow-up. *Minim Invasive Neurosurg* 2010;53:112-6.
  20. Sengupta D, Bucklen B, Ingalhalikar A, Muzumdar A, Khalil S. Does semi-rigid instrumentation using both flexion and extension dampening spacers truly provide an intermediate level of stabilization. *Adv Orthop* 2013;2013:738252.

**How to cite this article:** Ozer AF, Suzer T, Sasani M, Oktenoglu T, Cezayirli P, Marandi HJ, Erbulut DU. Simple facet joint repair with dynamic pedicular system: Technical note and case series. *J Craniovert Jun Spine* 2015;6:65-8.

**Source of Support:** Nil, **Conflict of Interest:** None declared.