

## Original Article

# Lateral orbitotomy approach for removing hyperostosing en plaque sphenoid wing meningiomas. Description of surgical strategy and analysis of findings in a series of 88 patients with long-term follow up

Abbas Amirjamshidi, Kazem Abbasioun<sup>1</sup>, Rouzbeh Shams Amiri<sup>2</sup>, Ali Ardalan<sup>3</sup>,  
Seyyed Mahmood Ramak Hashemi<sup>4</sup>

Professor of Neurosurgery, Sina Hospital, <sup>1</sup>Professor of Neurosurgery, Arad Hospital, <sup>3</sup>Department of Epidemiology, Head Department of Health in Emergencies and Disasters, School of Public Health and Institute of Public Health Research, Tehran University of Medical Sciences, Tehran, <sup>2</sup>Assistant Professor of Neurosurgery, Sari University of Medical Sciences, Sari, <sup>4</sup>Assistant Professor of Neurosurgery, Firoosgar Hospital, Iran University of Medical Sciences, Iran

E-mail: \*Abbas Amirjamshidi - [abamirjamshidi@yahoo.com](mailto:abamirjamshidi@yahoo.com); Kazem Abbasioun - [dr.abbasioun@gmail.com](mailto:dr.abbasioun@gmail.com); Rouzbeh Shams Amiri - [rshamsa@gmail.com](mailto:rshamsa@gmail.com); Ali Ardalan - [aardalan@gmail.com](mailto:aardalan@gmail.com); Seyyed Mahmood Ramak Hashemi - [m.ramak.hashemi@gmail.com](mailto:m.ramak.hashemi@gmail.com)

\*Corresponding author

Received: 23 December 14 Accepted: 28 January 15 Published: 14 May 15

### This article may be cited as:

Amirjamshidi A, Abbasioun K, Amiri RS, Ardalan A, Hashemi SM. Lateral orbitotomy approach for removing hyperostosing en plaque sphenoid wing meningiomas. Description of surgical strategy and analysis of findings in a series of 88 patients with long-term follow up. *Surg Neurol Int* 2015;6:79.

Available FREE in open access from: <http://www.surgicalneurologyint.com/text.asp?2015/6/1/79/157074>

Copyright: © 2015 Amirjamshidi A. This is an open-access article distributed under the terms of the Creative Commons Attribution License, which permits unrestricted use, distribution, and reproduction in any medium, provided the original author and source are credited.

## Abstract

**Background:** Sphenoid wing meningiomas extending to the orbit (ePMSW) are currently removed through several transcranial approaches. Presenting the largest surgical cohort of hyperostosing ePMSW with the longest follow up period, we will provide data supporting unilateral orbitotomy with excellent exposure for wide resection of all compartments of the tumor.

**Methods:** A retrospective survival analysis is made of the data cumulated prospectively during a period of 34 years, including 88 cases of ePMSW with a mean follow up period of 136.4 months. The impact of preoperative variables upon different outcome measures is evaluated. Standard pterional craniotomy was performed in 12 patients (C) while the other 76 cases underwent the proposed modified lateral miniorbitotomy (LO).

**Results:** There were 31 men and 57 women. The age range varied between 12 and 70 years. Patients presented with unilateral exophthalmos (Uex) ranging between 3 and 16 mm. Duration of proptosis before operation varied between 6 months and 16 years. The status of visual acuity (VA) prior to operation was: no light perception (NLP) in 16, light perception (LP) up to 0.2 in 3, 0.3–0.5 in 22, 0.6–0.9 in 24, and full vision in 23 patients. Postoperatively, acceptable cosmetic appearance of the eyes was seen in 38 cases and in 46 mild inequality of < 2 mm was detected. Four cases had mild enophthalmos (En). Among those who had the worst VA, two improved and one became almost blind after operation. The cases with VA in the range of 0.3–0.5 improved. Among those with good VA (0.5 to full vision), 2 became blind, vision diminished in 10, and improved or remained full in the other 35 cases. Tumor recurrence occurred in 33.3% of group C and 10.5% of group LO ( $P = 0.05$ ). The major determinant of tumor regrowth was the technique of LO ( $P = 0.008$ ).

**Conclusion:** Using LO technique, the risky corners involved by the tumor is visualized from the latero-inferior side rather than from the latero-superior avenue.

### Access this article online

#### Website:

[www.surgicalneurologyint.com](http://www.surgicalneurologyint.com)

#### DOI:

10.4103/2152-7806.157074

#### Quick Response Code:



This is the crucial milestone to achieve aggressive removal of all the involved compartments of the lesion. Satisfactory cosmetic result is reported using mini LO technique after widely exposing and removing the hyperostotic bone down to the subtemporal fossa with only simple repair of the dura without cranioplasty.

**Key Words:** Lateral orbitotomy, meningioma, orbital tumors, proptosis, sphenoid wing meningioma, sphenoid-orbital meningioma, unilateral exophthalmos.

## INTRODUCTION

Sphenoid wing (SW) en plaque meningioma (ePM) is a subgroup of meningiomas defined by its specific character presenting with a rather thin sheath of soft tumor tissue accompanied by disproportionate and extensive bone hyperostosis. ePMs may occur anywhere along the central nervous system (CNS).<sup>[13,43]</sup> It comprises 2–9% of all meningiomas, which are located mainly along the SW.<sup>[5,20,45]</sup> Cushing and Eisenhardt<sup>[13]</sup> coined the term of “en plaque” for the first time to differentiate this type of tumor growth from those designated as “en mass” meningiomas. Hyperostosis of the greater and lesser wings of the sphenoid bone leading in progressive proptosis is the main characteristics of ePM in this location. Whether this hyperostosis is due to: (a) Tumor invasion, (b) reactive hyperostosis, or (c) a mixture of both types of affections, varies in different series and the concept of its development has not yet reached to a uniform consensus.<sup>[5,10,20,26,29,32,37,39]</sup>

In this retrospective analysis of a prospective acquisition of database including 88 consecutive cases of what is called ePM of the sphenoid wing (ePMSW), we will present and discuss: (i) The reasons for changing our attitude in surgical technique, (ii) analyze the impact of variants upon the long-term follow up results of the patients with the end point of focal tumor recurrence, and (iii) it will be hypothesized that the term of ‘ePMSW’ should only be specified for a single group of ‘ePM’ of the SW with specific characteristics.

## CLINICAL MATERIAL AND METHODS

### Inclusion criteria and patient population

Among all the patients undergoing surgical intervention with the diagnosis of unilateral exophthalmos (Uex) in the section of skull base surgery (451 cases) there were 88 patients who fulfilled the criteria to be included in this study. Close cooperation between different specialties joined in our skull base interdisciplinary team, which included neurosurgeons, neurologist, neuro-ophthalmologist, neuro-otologist, neuro-radiologist, and neuro-pathologist, and was the main reason that made this study a reasonable and watchful bench.

We included all the patients admitted with the diagnosis of Uex whose histopathology report was meningioma

with involvement of the sphenoid bone. There were two cases with multiple meningiomas/meningiomatosis and were excluded from this series.

The selection criteria were:

- Hyperostosis of the greater/lesser wing of the sphenoid bone. This usually involved the pterional synostosis, the lesser and the greater SWs above and below the superior orbital fissure (SOF) and could involve the elements of the ipsilateral clinoid process and optic foramen
- Enhancement of the soft tissue of the tumor is visible in postcontrast enhancing T1W magnetic resonance imaging (MRI), located mainly along the SW and around the orbital fissure. The soft tissue tumor could be visible within the cone and lateral compartment of the orbit and also extend underneath the temporalis muscle extracranially. Extension of tumor tail could also exist along the ipsilateral clinoid, in the subfrontal region over the roof of the orbit, toward the cavernous sinus and its lateral wall, enhancing the wall of the sphenoid or ethmoid sinuses, and ensheathing the dura of the subtemporal fossa extending toward the petrous surface
- If there were no hyperostosis of the elements of the SW, or the tumor mass was mainly located around the anterior clinoid process (ACP) or enrooted from within the cavernous sinus or was mainly a variant of optic nerve sheath tumor or was a pure meningioma of the lateral/mid 3<sup>rd</sup> of the SW, they were excluded.<sup>[35,37,39,45]</sup>

The study period was 34 years, from June 1979 to June 2013.

### Neurological and ophthalmological examination

All patients underwent complete pre- and postoperative neurological examinations and signs and symptoms denoting the duration of illness were recorded. Visual acuity (VA) (Snellen notation), visual field (VF) (Goldmann or Humphrey perimetry), and funduscopy were all performed by the neuro-ophthalmologist.

### Imaging evaluations

The preoperative neuroradiological evaluation was performed in all cases. MRI, computed tomography (CT) and 3-dimensional reconstruction CT scan (3DRCTS) were all reported by the neuro-radiologist.

Infiltration and enhancement of the periorbita, dura mater of the temporal fossa, cavernous sinus, and the extra-calvarial soft tissue were assessed on postcontrast MR images, while osseous extension was assessed on CT scans before and after contrast enhancement.

All of the ePMs in this series presented with the four radiological characteristics defined as: (a) Hyperostosis of the wings of the sphenoid, (b) enhancement of the soft tissue of the periorbita (pod 1), (c) variable enhancement of the dura of the temporal fossa (pod 2), and (d) enhancement of the soft tissue beneath the temporalis muscle highly suspicious for extra-calvarial involvement of the tumor (pod 3). According to the above findings, the nomination of 'tripodal meningioma' will be appropriated. Based on the different degrees of involvement of other compartments besides the above-mentioned structures, we selected the term of 'radiologically invasive ePM' (RIePM) for those cases [Table 1].

The cases with only tripodal enhancement in MRI were designated as 'low tumor infiltration.' Those with extension to the subfrontal and olfactory groove and along the cavernous sinus were designated as 'moderate tumor infiltration' and those with tumor extension or tail to the paranasal and sphenoid sinuses, to the extracranial parapharyngeal and subtemporal regions, crossing the midline in the anterior fossa are coined as 'high tumor infiltration' [Table 1].

**Table 1: Different types of ePMs presenting with Uex sub-divided according to the localization of the visible tumor in MRI at the time of referral**

Type of involvement	No.
Tripodal	65
Recurrent tripodal	5
Tripodal + extension to the olfactory groove	2
Tripodal + extension to sphenoid sinus	3
Invasive type	5
Tripodal + extension to the olfactory groove, sphenoid cell and petrous bone	1
Tripodal + extension to sphenoid and ethmoid cells	1
Tripodal + extension to the subtemporal region	1
Tripodal + extension to the cavernous sinus, subtemporal and petrous regions	1
Tripodal + clinoidal tumor	2
Tripodal + clinoidal tumor and extension to the olfactory groove	1
Tripodal + ipsilateral occipital AVM	1
Total	88

By 'Tripodal' we nominated the cases with: (a) enhancing soft tumor detectable as a sheath extending along the squamosa of the temporal bone underneath the temporalis muscle extracranially, (b) tumor along the SW extending to the parasellar region, and (c) tumor within the orbital cavity ('low tumor infiltration'). The others in the list were ('moderate tumor infiltration' or ('high tumor infiltration'). SW: Sphenoid wing, AVM: Arteriovenous malformation

## Clinical and radiological follow up

It was presumed that all patients undergo clinical follow-up with complete visual and neurological examinations and cerebral MR/CT imaging on a regular basis every 6–12 months after primary intervention. To analyze the extent of surgical tumor removal, operative notes were reevaluated regarding the amount of bone removal and resection of intradural or intraorbital tumors. The first and last clinical examination and imaging taken in the follow-up period were compared in this study and the clinical and radiologic findings were measured numerically and by observation of the variables [Table 2]. Regarding the long distances between the cities, travelling costs and other socio-economic problems in the third world, constant, regular, and matched follow up dates/data could not be extracted from the files. Patients and their close relatives were called to obtain further follow up data when necessary. The follow up period varied between 5 and 348 months (median = 141, mean = 136, SD = 107 months).

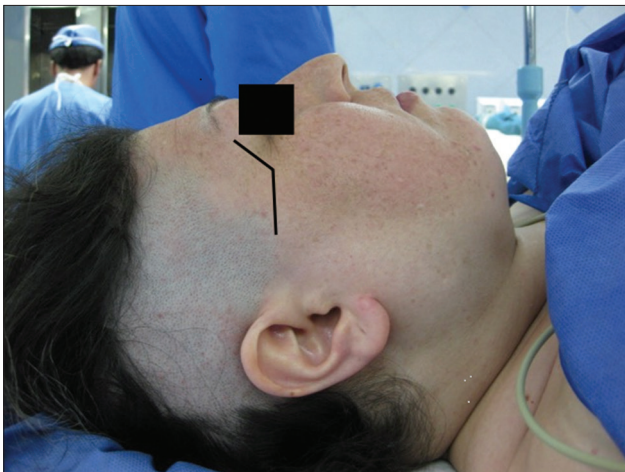## Surgical intervention

The patient's head is fixed in a 3-pin Mayfield head holder and is rotated 30° to 45° to the contralateral side. Brain relaxation and control of intraglobular pressure was maintained using dehydrating agents and moderate hyperventilation prior to and during surgery. A S-shaped skin incision is made starting from within the eyebrow, along the lateral 3<sup>rd</sup> and down to the extreme lateral end of the lateral canthus, and then turned horizontally along the zygomatic arch to a finger width distance in front of the tragus to prevent any damage to the frontal branch of the facial nerve [Figure 1]. A curved incision is then made through the periosteum of the frontozygomatic bone. The bulk of temporalis muscle filling up the temporal fossa is dissected subperiosteally, taking care to control the bleeding from the possibly hypertrophied meningeal branches and the tumor carpet infiltrating the periosteum of the temporal bone. Using a periosteal elevator, the periorbital fascia is shaved off the lateral wall of the orbit, which is usually a bulky and nonhomogenously ragged bone infiltrated by the tumor tissue and is adherent to the orbital fascia. This maneuver should be performed very carefully not to damage the periorbital fascia. A reciprocating saw is used to incise the lateral rim of the orbit just above the frontozygomatic suture line and to make another cut just above the horizontal part of the zygomatic arch, both in a converging oblique direction. An assistant must carefully protect the intraorbital contents with a malleable retractor inserted between the inner surface of the lateral wall of the orbit and the periorbital fascia. Then, a rongeur is used to grasp the rim of the orbit and break it from the greater wing of sphenoid. The hyperostotic bone starts usually from this point and can be rongeured along the greater wing of

**Table 2: The clinical status of the patients before and after surgical intervention**

Symptom	Preop. N (%)	Postop.	Results and complications
Uex. (proptosis)	88 (100)	Remission all cases	Normal=38, 3-4 mm=46, mild en, =4
Temporal swelling	88 (100)	disappeared	Atrophy of temporalis muscle=14
Visual acuity	NLP=16 LP-0.2=3 0.3-0.5=22 0.6-0.9=24 Full vision=23	LP=3 2=improved, 1=NLP 18=improved, 4=LP 2=NLP, 6=worsened, 16=improved 4=decreased to 0.5-0.6	All improved 0.1-0.2 during the follow up except those NLP at presentation
Painful proptosis	28 cases	No further pain	
Reddening of the sclera	4 cases	Improved gradually	
Optocilliary shunt	4 cases	No change	
Remarkable edema of the eyelids	2 cases	improved	
EOMP	0, except mild medial deviation of the globe	Improved=52 Lateral gaze paresis=21 Panophthalmoparesis=4 Panophthalmoplegia=1	OK Acceptably improved in all cases Acceptably improved in all cases No change
Tear production	Not affected	No change	No corneal damage even after radiotherapy
Epilepsy	1+ temporal lobe edema in MRI	1	No medication after 8 months
Papilledema	18 cases	Improved	
Atrophy of temporalis muscle	0, no obvious sign of Vth. N palsy	6 cases	Appeared in late follow up

NLP: No light perception, LP: Light perception, EOMP: Extraocular muscle palsy



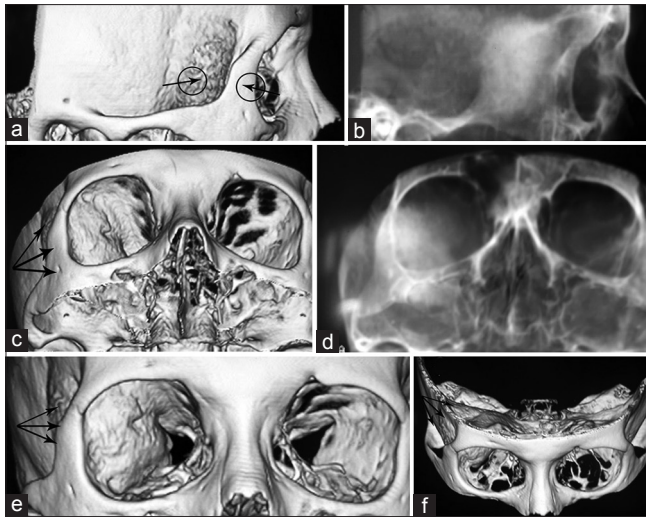
**Figure 1: Line of incision, before the patient was anesthetized and head fixed. Shaving the hair is not necessary**

the sphenoid. The bulk of the temporalis muscle should be kept retracted as much as possible to expose all the hyperostotic, out bulging lateral and down looking surface of the temporal bone with the out-merging tumor mass covering the outer surface of it. Using a high speed drill and a fine angled rongeur, the hyperostotic bone should be removed until the normal looking bone reached, that is, adjacent to the temporalis line upwards, above the ear backwards and along the floor of the temporal fossa over the roof of the subtemporal compartment. The thickened bone is often a kind of so called 'marble bone' and its drilling is time consuming. It may be very hypervascular in some cases and frequent application of

bone wax for hemostasis can be boring. Samples should be taken from all segments of this bone to look for tumor infiltration as a separate pathology specimen. Completion of bone work exposes: (a) The anterior temporal dura, most of the inferior temporal dura and all the adjacent normal looking dura mater in the frontal and low parietal region and posterior to the base of the tumor. In this stage, the pathology appears as antero-inferiorly based temporal ePM, similar to a convexity meningioma in gross exposure, (b) a good visualization of the periorbital fascia and retrobulbar contents is also achieved, (c) the surgeon looks at the greater and lesser wings of the sphenoid bone from an inferolateral direction so that the hypertrophied/sclerotic wings can be drilled as deep and down as necessary [Figure 2], (d) the SOF can be seen from above, lateral and below preserving the vital neural elements. Using microscopic dissection, one can eliminate as much of the tumor as possible [Figure 2], and (e) drilling the lesser wing in the depth and along the roof of the orbit under microscope can facilitate removing the lateral strut of the ACP and decompress the optic foramen in its superolateral aspect [Figure 3]. In the cases with visual impairment, decompression of the optic nerve has been performed extradurally in this series. It is not suggested to open the optic nerve sheath in any of the cases. If air cells are opened, they should be sealed up properly using autologous fat and muscle covered by Gelfoam, Surgicel, or glue.

The intradural component of the tumor can be removed solely by cutting the dura along the normal



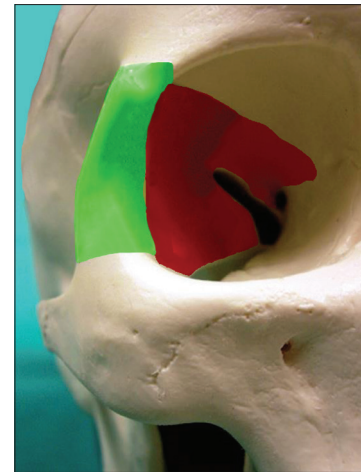

**Figure 2:** Three dimensional bone formatted CTS of the skull along with the skull X-ray adjusted for each, defining the gates through which the hyperostotic bone is visualized (a and b black arrows in the circles) and the avenues through which the instruments can better reach the depth to remove/decompress the involved/hyperostotic bone (black triple arrows in c, d and e), and the black triple arrows when approaching via standard/pterial craniotomy (f) the view when is operated through the traditional pterional approach

looking boundary of the tumor in all directions. Two points should be highlighted in this stage: (i) Delicate dissection of dura should be done around the SOF with careful coagulation of the dural folds infiltrated by the tumor to decrease the amount of residual tumor cells in the vicinity of the orbital fissure and (ii) the entire tumoral infiltration of the dura at the base of frontal lobe and over the roof of the orbit, the involved dura of the temporal fossa in its anterior, inferior, and medial or internal part located along the lateral wall of the cavernous sinus should be either removed or curetted and coagulated.

The orbital compartment of the tumor can either be seen or palpated at this stage. Extension of the tumor to the roof, along the most inferior part and toward the cone of the orbit, can be dissected and removed with this exposure. Reduction of the tumor mass can be achieved using either piece meal technique or using ultrasonic aspirator. It is better to leave tumor spicules behind especially in the cone of the orbit where the elements entering the orbit via SOF might be infiltrated by the tumor cells.

Dural repair can be done with a large patch of pericranial graft removed from the temporo-parietal region and sutured only in some points, and covered with Gelfoam or Surgicel. Neither the roof, the lateral wall of the orbit nor the defect of the temporal bone was reconstructed in any of our cases. The bone strut removed from the orbito-zygomatic arch is replaced and fixed in an appropriate and feasible way and periosteum sutured over it. Vacuum drain with moderate negative pressure is placed underneath the temporalis muscle for 48 h. Skin



**Figure 3:** The schematic drawing showing the rim of the orbit removed and refixed at the end (green shaded) and the segments of the hyperostotic bone, which is necessary to be drilled out in most of the cases to achieve complete excision of the possibly involved bony compartments around the SOF down to the inferior orbital fissure and to decompress the optic canal from the lateral side (red shaded)

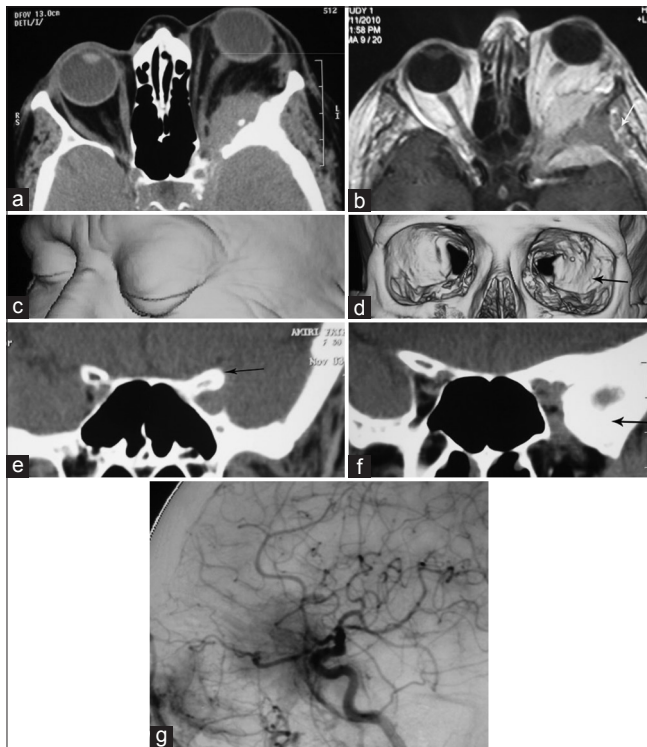
is sutured in subcuticular manner. Lumbar puncture is performed once or twice during the postoperative period to manage subgaleal cerebrospinal fluid (CSF) collection.

### Illustrative cases

#### Case 1

A 69-year-old female was admitted with progressive left Uex of more than 6 years duration. The exophthalmos (Ex) was 7 mm with inwards and downwards displacement. It was irreducible and nonpainful without any extraocular muscle palsy (EOMP). VA was 0.4 on Snellen notation with some restriction of VF on Humphrey perimeter. In funduscopy, optic disc was blurred and whitish discolored with no optociliary shunt. CT scan with 3D reconstruction identified hyperostotic greater and lesser SWs and part of the ACP in different views. The soft tumor tissue extended in a carpet fashion in the temporal fossa with a maximum thickness of 4–5 mm to the cavernous sinus but it did not infiltrate it. The intraorbital extension of the tumor was voluminous, compressing the optic nerve both within the optic foramen and the cone of the orbit. Weekly enhancing tumoral tissue was also present underneath the temporalis muscle. Another very thin enhancing carpet of tumor was also seen hanging from the lateral roof of the sphenoid sinus, which could be either tumor extension or congested mucosal coverage. Angiography performed in another center revealed moderate tumor blush fed through the branches of the external and internal carotid arteries [Figure 4]. A minilateral orbitotomy was performed as described above and a marble, hyperostotic bone rongeur/punched/drilled out so that the SOF released all. The ACP was removed using high speed fine diamond drill and small sharp curette until the

optic nerve sheath was exposed in the latero-superior aspect. Most of the nonhomogenous solid tumor was removed from within the orbit down to the cone but small pieces infiltrating the muscles had to be left alone. The tumor sheath infiltrating the external periosteum of the temporal bone was removed and the hyperostotic temporal bone excised until the normal looking bone could be detected all around. Samples were taken from all the bone layers for histopathological study. The tumoral dura was removed until a clean looking margin was evident. The dura infiltrated by the tumor around the SOF was cut from the superomedial and inferolateral margin of the SOF and coagulated. The tumor was also teased off the lateral aspect of the cavernous sinus. All the dural margins were coagulated with low voltage bipolar cautery. The postero-medial surface of the tumor had a fine and easily separable arachnoid membrane covering the temporal lobe. Two medium sized veins passed from the temporal cortex into the tumor and from there into the temporal sinusoids, which had to be



**Figure 4:** (a and b) contrast enhanced CTS and MRI showing the intraorbital, temporal intra- and extra-cranial (small white arrow) of the tumor, c and d) three dimensional imaging of the face demonstrating the pattern of EX in (c), and bony cavity of the orbits showing asymmetric orbital fissures and squeezing of the left orbital fissure by the hyperostotic lesser and greater wings of the sphenoid bone (black arrow) in (d). (e) is the coronal view mainly illustrating the hyperostotic ACP while (f) demonstrates hyperostosis of lesser and greater wings of the sphenoid bone and asymmetric orbital fissures. (g) is the lateral view of DSA showing the tumor blush located in the anterior temporal region. It is mainly fed through the meningeal branches of the ascending pharyngeal artery and the cavernous branches of the internal carotid artery and recurrent meningeal branches of the ophthalmic artery

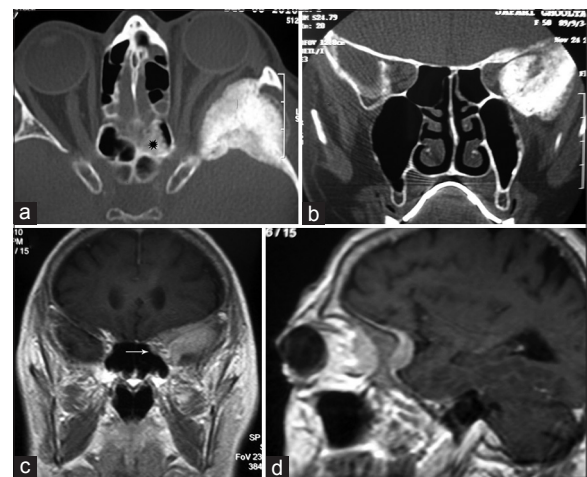
coagulated. The operation ended with ‘Simpson grade II tumor excision.’ The temporal dura was repaired using autologous pericranium covered with Surgicel and no cranioplasty performed. None of the bone samples taken from the superficial or deepest part of the hyperostotic bone contained any tumor cells. Her postoperative course was uneventful and when visited after 3 months, the eyes were almost symmetrical and VA improved to 0.7 with good VF. It was planned to deliver focal radiation therapy (FRT) after operation but she refused. There has been no sign of tumor recurrence during 3.5-year follow-up.

#### Case 2

This 56-year-old female was admitted with UeX of 4 years duration and VA of 0.6. Imaging showed remarkable hyperostosis of all the SW, normal looking ACP, and thin layer of enhancing soft tumoral tissue encasing the hyperostotic area. A very thin layer of soft tissue thickening was visible both in CT scan and MRI just in the vicinity of the mucosal layer of the sphenoid sinus [Figure 5]. The operation was done using the same minilateral orbitotomy and the same steps were undertaken. The bone was infiltrated by the meningioma cells in the superficial layers but the deeper hyperostotic areas were totally clean of tumor. There has been no sign of recurrence after 3.5 years.

#### Case 3

An 81-year-old male was admitted on June 2004 with left Uex. In May 1994 he underwent craniotomy in another center for SOM presenting with Uex and decreased vision secondary to a tumor mass arising from the left SW with hyperostosis visible in contrast



**Figure 5:** (a and b) horizontal and coronal views of CTS hyperostotic wings of the SW and temporal squamosal plate and asymmetric orbital fissures squeezed in the left side without affection of ACP, (c and d) contrast-enhanced MRI elucidating a thin layer of tumoral tissue enhancement along the SW and subfrontal dura, underneath the temporalis muscle and highly suspicious for extending into the orbit. There is a bright sclerotic thickening within the posterior ethmoid sinus in the left side (black star in a) and an enhancing soft tissue nodule located in rather the same area in the ethmoid region visible in MRI (c, white arrow)



enhanced CT scans. He did well after the first operation but vision decreased and Ex reappeared after 6 years. New imaging revealed hyperostosis of the SW and enhancing tumor mass within the lateral compartment of the orbit extending along the wall of the cavernous sinus to the temporal tip, and beneath the temporalis muscle [Figure 6]. He was operated for the second time after 10 years using a minilateral orbitotomy approach. This time the hyperostotic SW was removed deep to the ACP and inferior orbital fissure. The intradural tumor could be excised and shaved off the cavernous sinus but the intraorbital component was tightly adherent to the muscles and the scar of the previous operation, which could not be excised completely. Both Uex and VF improved after operation. Regarding tumor residue, a course of FRT was delivered. There was no sign of tumor recurrence when he last visited after 9 years. His cosmetic status was also satisfactory with no sign of atrophy of the temporalis muscle [Figure 6i and j].

## RESULTS

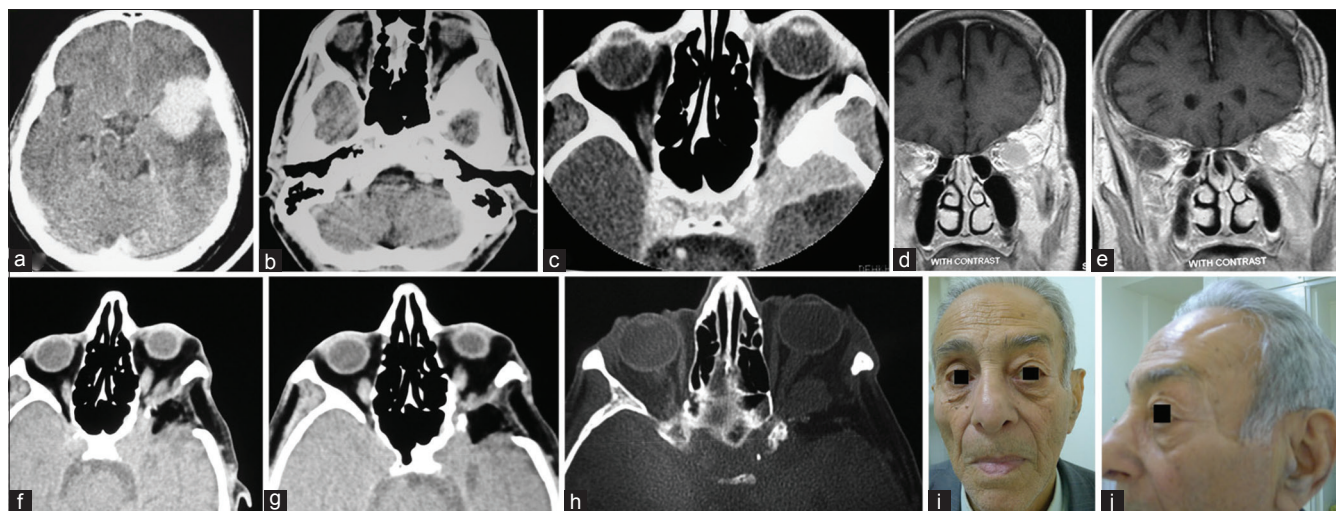
### Before operation

There were 88 cases including 31 men and 57 women (M/F ratio of 1:1.8). The symptoms at presentation are summarized in Table 2. The age range varied between 12 and 70 years (median = 47, mean = 45.8, SD = 13.5). All presented with Uex ranging between 3 and 16 mm (median = 7 mm, mean = 6 mm, SD = 2.3 mm) based on bedside standard exophthalmometry plus data extracted from MRI and/or CT scans. Proptosis occurred in the right side in 40 and in the left side in 48 patients. There was no case of bilateral

spheno-orbital meningioma (SOM) in this series. The duration of progression of proptosis prior to operation varied between 6 months up to 16 years (median = 3, mean = 3.6, SD = 3.3). Palpation of the eye could produce pain in 28 cases. The sclera was reddish in four and optociliary shunt could be detected in fundoscopy in other four cases. Papilledema was detected in 18 cases preoperatively on neuro-ophthalmological evaluation. The VA and VF of all the patients were measured before and after operation and were closely watched in the follow-up period. The status of VA before operation was: No light perception (NLP) in 16 patients, light perception (LP) up to 0.2 in 3, 0.3–0.5 in 22, 0.6–0.9 in 24, and full vision in 23 patients [Table 2]. EOMP was not a common finding in this series of patients even though mild downward and inward deviation of the globe was present almost in all cases. Cranial nerves III, IV, V, or any other one not seen in preoperative examination. History of epilepsy was present only in one patient who had moderate focal edema in ipsilateral temporal lobe in MRI.

### Outcome

Mild En occurred in the few postoperative days and usually disappeared after removing the surgical drain. Regarding remission of Uex, the difference between the two eyes up to 1 mm was considered as 'acceptable remission.' There were 38 cases with acceptable cosmetic appearance of the eyes regarding the location of the globes, 46 cases with mild inequality of <2mm and 4 with mild En 2–4 mm when visited for the first time almost 3 months following operation. This remained unchanged to their last visit. Previously noted swelling of the temporalis muscle was not detectable any more. Three of the patients who were blind preoperatively gained LP during follow up visits.



**Figure 6:** (a and b) contrast-enhanced CTS available from the first admission showing the hyperostotic SW the tumor mass in the temporal and subfrontal regions before craniotomy, (c) contrast enhanced CTS in the 2nd admission showing the remainder of the hyperostotic ridge, enhancing tumor and persisting EX, (d and e) contrast-enhancing TIW coronal MRI in the 2nd admission demonstrating the site of previous craniotomy and bulging SW involved by the tumor recurrence, (f and g) CTS performed after second intervention via the lateral approach showing appropriate bony decompression of the orbit and regression of EX, (h) MRI confirming tumor remnant within the cone of the orbit, and (i and j) face of the patient after long follow-up with good cosmetic features and no atrophy of the temporalis muscle

Among those who had a poor quality of vision, two improved and one became almost blind after operation with no further improvement. All the cases with VA in the range of 0.3–0.5 improved after operation. Among those with good VA (0.5 to full vision), 2 became blind, vision decreased in 10, and VA improved or remained unchanged in the other 35 cases [Table 2]. Local tenderness and pain of the eye and redness of the sclera improved gradually after operation but optociliary shunts were persistently detected by the ophthalmologists in follow-up studies. Remarkable edema of the eyelid happened in 2 cases, which improved after a month, but moderate atrophy of temporalis muscle was noted late in 14 cases.

On histopathological examination, the sphenoid bone was infiltrated by meningioma in 53 (60.3%) of the cases. There has been no early reoperation needed in this series. Tumor recurrence occurred in 12 cases but reoperation was needed in 2 cases.

### Radiotherapy

Focal radiation was delivered in the cases with (a) visible tumor residue or regrowth in follow-up imaging, (b) those with bone infiltration with tumor cells in pathological studies, and (c) patients with clinically evident Uex in the postop period (31 cases). No patient developed radiation-induced retinopathy or pituitary insufficiency.

### Statistical analysis

For statistical analysis, SPSS v 16.0 was used. To describe the study variables, descriptive statistical measures were calculated including frequency, percentile, mean, and standard deviation whenever appropriate. Independent *t*-test was applied to compare the mean of continuous variables between the two study groups. The association between two categorical variables was assessed using a Chi-square test. Whenever one or two of the study variables was ordinal in scale, the Chi-square for trend was applied. A multiple logistic regression was used to evaluate the determinants of the tumor recurrence as an outcome variable. For other two outcome variables, that is, improvement/cure of the Uex and improvement of VA, the multiple linear regression models was applied to assess the determinant factors. The *P* value less than 0.05 ( $P < 0.05$ ) was considered statistically significant.

### Output of the analysis

This 34-year follow-up study includes findings related to 88 cases of ePM including 12 cases (13.6%) who underwent craniotomy (C) and 76 cases (86.4%) who underwent lateral mini-orbitotomy (LO) approach. Radiotherapy was delivered to 8 cases (66.7%) in group C and to 23 cases (30.3%) in group LO. The mean follow-up period was 179 months ( $\pm 123.6$ ) in group C, and 129.6 months ( $\pm 103.0$ ) in group LO.

Tables 2 and 3 demonstrate the characteristics of the study subjects in terms of demographic variables, tumor characteristics, signs and symptoms, outcomes of surgery,

and complications both in categorical and numerical values.

### Demographic variables

Eleven (91.7%) patients in group C and 46 patients (60.5%) in group LO were female ( $P = 0.05$ ). Mean age of the cases in C and LO groups were 47.0 years ( $\pm 15.3$ ) and 45.6 ( $\pm 13.3$ ), respectively ( $P = 0.76$ ).

### Tumor characteristics

Five cases (41.7%) in group C and 37 cases (48.7%) in group LO had tumor in their right orbit ( $P = 0.65$ ). Invasion to bone was observed in 10 cases (83.3%) of group C and 43 cases (56.6%) of group LO ( $P = 0.11$ ). Among group C, low, medium, and high bone infiltration were observed in 6 (50.0%), 3 (25.0%), and 3 (25.0%) of cases, respectively. The frequencies of the grade of tumor invasion in the LO group were as follow: 66 low-grade cases (86.8%), 4 medium-grade cases (5.3%), and 6 high-grade cases (7.9%) [Table 3]. In general, the group LO had lower grade of tumor infiltration ( $P = 0.007$ ).

### Signs and symptoms

Duration of the symptoms prior to operation was 47.0 months ( $\pm 47.3$ ) in group C and 43.3 months ( $\pm 38.7$ ) in group LO ( $P = 0.80$ ). Five patients (41.7%)

**Table 3: Radiologic characteristics of the hyperostotic SW in this series**

Hyperostosis in the imaging	
Lesser wing	88
Greater wing	88
ACP	34*
Histopathology of the hyperostotic bone defined by tumor cell 'present +' or 'absent -' in the specimens from the SW in 88 cases	
+ in the specimens taken from the bone adjacent to the tumor and + in the specimens taken from the deeper hyperostotic region	31
+ in the specimens taken from the bone adjacent to the tumor and - in the specimens taken from the deeper hyperostotic region	43
- in the specimens taken from the bone adjacent to the tumor and - in the specimens taken from the deeper hyperostotic region	14
Histopathology of the hyperostotic bone defined by tumor cell 'present +' or 'absent -' in the specimens from the ACP in 12 cases only	
Positive +	4
Negative -	8

\*as reported in the available CT scans evaluated by one neuro-radiologist and two attending neurosurgeons. Definition of histopathological examination of the different layers of bone removed from the hyperostotic SW was: among the C (craniotomy) group, low, medium, and high bone infiltration were observed in 8 (66.7%), 4 (25.0%), and 1 (8.3%) of cases, respectively. The frequencies of the grade of bone infiltration in the lateral orbitotomy group were as follows: 23 low-grade cases (30.3%), 39 medium-grade cases (51.3%), and 14 high-grade cases (18.4%). Generally, the LO group had higher grade of bone reaction to tumor ( $P=0.03$ ). The rate of tumor infiltration to the specimens taken from ACPs of only 12 patients are also mentioned. SW: Sphenoid wing, CT: Computed tomography, LO: Lateral orbitotomy, ACP: Anterior clinoid process



in group C had pain, while that was experienced by 25 cases (32.9%) in group LO ( $P = 0.53$ ). Five patients (6.6%) in group LO had eye redness and retinal shunt. None of these symptoms were observed in patients of the group C.

The mean of the amount of Uex before operation was 5.6 mm ( $\pm 1.4$ ) in group C and 6.6 mm ( $\pm 2.4$ ) in group LO ( $P = 0.18$ ). The mean of VA before the operation was observed as 0.3 ( $\pm 0.3$ ) in group C, while this was 0.6 ( $\pm 0.3$ ) in group LO ( $P = 0.04$ ). Even though the differences between some of the variants were significant in this analysis but considering the design of our study, that is, changing the technique from C to LO and achieving more experience steadily, the clinical interpretation of the differences could be debated.

#### Outcome of surgery

The tumor recurrence was observed in four cases (33.3%) of the group C, and eight cases (10.5%) in group LO ( $P = 0.05$ ). The matter of increased

'expertise of the surgeon' could not be evaluated in this study because the follow up periods have not been equal between the more recent cases and those operated during the previous 5-year interval. The difference between Uex after operation compared to Uex prior to operation was 4.91 mm ( $\pm 1.3$ ) in group C and -5.2 mm ( $\pm 1.9$ ) in the group LO ( $P = 0.52$ ). The degree of improvement in VA noted after operation was 0.08 ( $\pm 0.2$ ) in group C and -0.02 ( $\pm 0.2$ ) in the group LO ( $P = 0.14$ ).

#### Complications of surgery

The frequency of neurological deficit was lower in group LO than the group C, that is, 25.0% vs. 75.0% ( $P = 0.001$ ). Tumor growth was also less frequent in the group LO compared with the group C (31.6% vs. 75.0%) ( $P = 0.008$ ). Enophthalmos (En) was noted in four cases (5.3%) who had LO surgery, while this problem was not observed in any case of group C.

**Table 4: Comparison of study variables between the two surgical techniques**

Variables	Craniotomy (n=12)	Lateral orbitotomy (n=76)	P value
<b>Demographic variables</b>			
Sex (female)	11 (91.7)	46 (60.5)	0.05
Age (year)	47.0 (15.3)	45.6 (13.3)	0.76
<b>Tumor characteristic</b>			
Tumor side (right)	5 (41.7)	37 (48.7)	0.65
Invasion to bone	10 (83.3)	43 (56.6)	0.03
Grade of tumor invasion			0.007
Low	6 (50.0)	66 (86.8)	
Medium	3 (25.0)	4 (5.3)	
High	3 (25.0)	6 (7.9)	
<b>Signs and symptoms</b>			
Duration of symptom (month)	47.0 (47.3)	43.3 (38.7)	0.80
Pain	5 (41.7)	25 (32.9)	0.53
Redness	0 (0)	5 (6.6)	1.0
Retinal shunt	0 (0)	5 (6.6)	1.0
Exophthalmos before operation (mm)	5.6 (1.4)	6.6 (2.4)	0.18
Visual acuity before operation (0 to 1)	0.3 (0.3)	0.6 (0.3)	0.04
<b>Surgery outcomes</b>			
Recurrence	4 (33.3)	89 (10.5)	0.05
Exophthalmos cure (mm)	-4.91 (1.3)	-5.2 (1.9)	0.52
Visual acuity improvement (0 to 1)	0.08 (0.2)	-0.02 (0.2)	0.14
<b>Surgery complications</b>			
Neurological deficit	9 (75.0)	19 (25.0)	0.001
Tumor growth	9 (75.0)	24 (31.6)	0.008
Enophthalmos	0 (0)	4 (5.3)	1.0

**Table 5: Determinants of the outcome variables**

Variables	B	SE	P value
<b>Tumor recurrence</b>			
Surgery technique	-0.74	0.83	0.37
Post operation radiotherapy	0.73	0.82	0.37
Sex	-0.82	0.90	0.92
Age	0.02	0.03	0.44
Tumor side	-0.15	0.70	0.82
Invasion to bone	1.98	1.13	0.08
Grade of tumor invasion	0.23	0.49	0.63
Duration of symptom (month)	-0.008	0.01	0.47
Duration of post-operation follow up	0.005	0.004	0.18
<b>Exophthalmos cure</b>			
Surgery technique	-0.39	0.63	0.54
Post operation radiotherapy	0.51	0.51	0.31
Sex	-0.44	0.47	0.34
Age	0.006	0.01	0.69
Tumor side	-0.04	0.40	0.92
Invasion to bone	-0.61	0.44	0.17
Grade of tumor invasion	0.44	0.36	0.22
Duration of symptom (month)	-0.008	0.006	0.17
Duration of post-operation follow up	0.002	0.002	0.47
<b>Visual acuity improvement</b>			
Surgery technique	-0.15	0.08	0.08
Post operation radiotherapy	-0.01	0.07	0.83
Sex	0.06	0.06	0.34
Age	0.001	0.002	0.81
Tumor side	-0.06	0.05	0.25
Invasion to bone	-0.02	0.06	0.74
Grade of tumor invasion	-0.02	0.04	0.58
Duration of symptom (month)	-0.001	0.001	0.15
Duration of post-operation follow up	8.796E-5	0.000	0.76
Exophthalmos cure	-0.001	0.01	0.96

B: Beta, as the regression coefficient indicating the strength of association. Positive B shows a positive association between dependent and independent variables, and negative B reveals a negative association. SE stands for standard error of B. SE: Standard error

Tumor growth after the operation correlated positively with tumor invasion to bone ( $P < 0.001$ ), as it occurred in 50.9% and 17.1% of cases with and without tumor invasion to bone according to the histopathological reports, respectively. It occurred in 88.9% of high-grade, 71.4% of medium-grade, and only 27.8% of low-grade bone infiltrations [Table 3].

#### Results of the multiple regression analyses

Table 5 demonstrates that the technique of surgery, adjusted for other variables, was not associated with any of the outcome variables significantly, however, as seen from [Table 6], the frequency of neurological deficit, which occurred in the cases operated by the LO technique, was lower ( $P < 0.006$ ). The intention to treat the cases using LO technique rather than C technique, and the learning ladder of surgeon gaining more expertise without equal follow-up period in all the cases, can make the clinical interpretation of these outputs difficult.

## DISCUSSION

### Epidemiology

Sex distribution in our series was 31 men and 57 women (M/F ratio of 1/1.8), which are remarkably different from other reports showing ratios between 1/3 and 1/15 with an average of 1/3 to 5.<sup>[11,20,21,32,39,44,46]</sup> We encountered only one similar report from China<sup>[26]</sup> with M/F ratio of 1/1.5. That might suggest that women with minimal symptomatology, that is, only asymmetric

eyes and bulging of the temporal region, which can be covered easily by the hair or scarf, come very late or even never for medical consultation. Another reason for such an increase of this subgroup of patients might be that other benign ossifying lesions such as fibrous dysplasia and osteoma have been diagnosed incorrectly and further precise investigations were not performed in such cases.

### The cause of hyperostosis

Hyperostosis frontalis interna, osteoma, focal erythroid hyperplasia, fibrous dysplasia, osteoblastic metastasis to the SW, sarcoidosis, and Paget disease are the main pathologies leading to hyperostosis in this region.<sup>[6,20]</sup> Looking for the thin layer of ePN enhancing after contrast material injection in CT and MRI have not been the main reason to differentiate various types of lesions in this location. Inward bulging of the hyperostotic SW into the orbit and raggedness of the postero-latero-temporal aspect of the SW just underneath the en plaque tumoral layer are another specific characteristic of ePM in this location.<sup>[5,9,12,20,25,28]</sup> We detected this finding in the imaging of all our cases. The diploic component of the hyperostotic bone had nonspecific characteristics both in CT scans and MRI that could not match the histopathologic findings in our cases, which is also suggested by others.<sup>[9,11,22,28,32,43-46]</sup> We tried to tabulate the type of tumor infiltration of the adjacent hyperostotic bone to 'high', 'medium', and 'no' infiltration according the different samples taken during surgery and submitted separately for histopathological examination but the differences were not of significance [Table 3].

### Imaging evaluation

Extensive neuroimaging assessments are necessary including: (a) High-resolution CT scans with contrast material injection to evaluate bone as well as soft tissue involvement. Thin-cut coronal bone CT scan were taken with 3-dimensional reconstruction (3D recon) not only to detect even a small amount of hyperostosis but also to simplify surgical planning, (b) good resolution MRI with gadolinium enhancement done with fat-suppression and other possible sequences to detect any soft tissue tumor infiltration. Different authors have classified hyperostosis of SWMs into four types: Homogeneous, periosteal, layered, and diploic.<sup>[22,32,41,43]</sup> No such a differentiation was possible in our series of 88 cases and we encountered soft tissue tumor enhancement in the temporal, intraorbital, para-pharyngeal, and extra-temporal fossae underneath the temporalis muscle. Considering the possible impact of these different types of tumor extension, we tried another simple practical grading of tumor infiltration mentioned in table 1.

### Symptoms and their oncologic pathogenesis

The most common clinical presentation of ePMSW is Uex. Their Ex is usually slowly progressing, nonpulsating,

**Table 6: Determinants of the surgery complications**

Variables	B	SE	P value
<b>Neurological deficit</b>			
Surgery technique	-2.25	0.82	0.006
Post operation radiotherapy	-0.45	0.63	0.94
Sex	-0.05	0.60	0.92
Age	-0.01	0.02	0.53
Tumor side	-0.57	0.52	0.27
Invasion to bone	0.31	0.57	0.58
Grade of tumor invasion	0.20	0.44	0.63
Duration of symptom (month)	0.01	0.007	0.12
Duration of post-operation follow up	-0.002	0.003	0.38
<b>Tumor growth</b>			
Surgery technique	-12.85	7080.71	0.99
Post operation radiotherapy	167.27	12507.78	0.99
Sex	-58.13	9918.82	0.99
Age	0.05	503.64	1.00
Tumor side	-52.77	5159.41	0.99
Invasion to bone	3.97	4759.40	0.99
Grade of tumor invasion	23.54	11092.49	0.99
Duration of symptom (month)	0.46	41.88	0.99
Duration of post-operation follow up	0.02	19.69	0.99

B: Beta, as the regression coefficient, SE: Standard error of B

irreducible, and painless. Hyperostosis of the elements of the SW, invasion of the tumor to the periorbita, intraorbital tumor extension, and venous stasis of both superior and inferior orbital veins are the main causes of these symptoms. Decreased vision, diplopia, ptosis, headache, and seizure may develop later in the course of the illness.<sup>[3,14,20,35]</sup> Decreased vision was present in 65 (75%) of our cases and the other complaints were less frequent [Table 2]. Unilateral visual loss is mostly due to narrowness of the optic foramen.<sup>[3,34]</sup> Compression of the optic nerve by the tumor both within the cone of the orbit and just besides the cranial side of the optic foramen without hyperostosis of ACP has been another factor in one-third of our cases. *There has been no significant relation between the amount of the soft tumor tissue and the degree of hyperostosis in these cases, as also reminded by others.*<sup>[3,34,42]</sup> The amount of tumor infiltration within the adjacent hyperostotic bone in our series [Tables 3 and 4] does not match and reflect those mentioned in the available literature.<sup>[14,20,21,27,32,41]</sup> We tried to collect all the specimens from wherever the hyperostotic bone was seen. The specimens from the lesser and the greater wings were studied both from the superficial portions besides the soft tumoral tissue and from the deeper hyperostotic bone separately. Of the 12 cases with clinoidal hyperostosis, 4 contained tumor cells and 8 did not [Table 3]. This finding is in contrary with other reports.<sup>[2,5,18,20,34,44]</sup> As mentioned by all master surgeons working in this area, collecting not enough amount of specimens from deeply located hyperostotic bone has been the main drawback for critical evaluation of this region.<sup>[3,35,39]</sup> *We have done our best to collect specimens step by step while drilling the deep bony structures in every layer.* Delicate sample collection made it possible to examine each layer of hyperostosis for possible tumor infiltration [Table 3]. Full decompression of the hyperostotic bone and soft tumoral tissue in our series led to subsidence of Ex in nearly all the patients (the difference between C and LO groups,  $P = 0.54$ , Table 5), and improvement of vision in 39 out of 65 cases (60%, Table 2) (the difference between C and LO,  $P = 0.08$ , Table 5).

All the tumors in our series were of meningotheliomatous type, WFNS grade I. Consequently, there were no potential relationship between histological features of these tumors and hyperostosis. We have only recently started to reexamine the specimens for immuno-histochemical staining and other growth labeling indices.

### Operative approach

Decompression of the SOF is important for correcting the symptoms of Uex in all such cases. In the cases with visual impairment, it is strongly recommended to decompress the optic canal too.<sup>[34]</sup> SW meningiomas with extension to the orbit currently are removed through several

transcranial approaches, including supra-orbital–pterial, frontotemporal–orbito-zygomatic, fronto–orbito–malar, and pterional.<sup>[2,6-8,11,14,15,21,26,27,30,32,35,38,41,44,45]</sup> Performing standard frontotemporal (pterial) craniotomy, *it is only possible* to remove the greater wing of the sphenoid ridge down to the lateral limit of the lesser wing and *not any deeper* in the medial direction. The hyperostotic lateral wall of the orbit, which is mainly composed of the greater SW, can be drilled out from above and lateral side *but the deeply located toughly ossified parts below the SOF, the floor of the temporal fossa, besides the cavernous sinus and in front of the foramen Ovale can be reached more easily when reached from the lateral side and from below in this mini approach* [Figure 2]. Accordingly, as in ‘deep lateral wall decompression’ technique performed in cases with Graves’ disease, the door lamb of the greater wing of the sphenoid and the basin of the inferior orbital fissure could be removed as much as needed [Figure 3].<sup>[3,4,17,27,28,40]</sup>

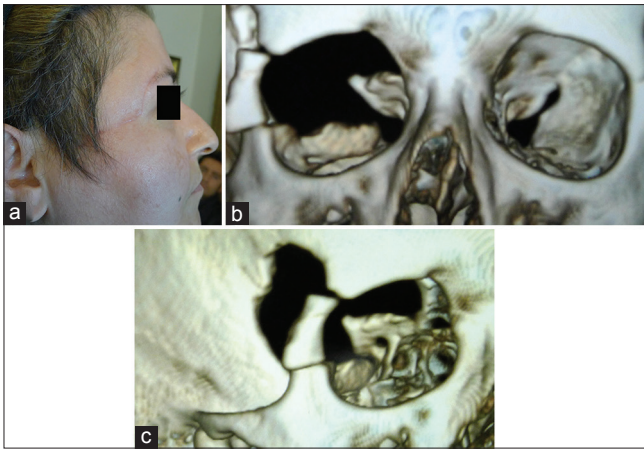
### Historical background and comparison of technical points

In our communication, we present a series of 88 patients harboring SW meningioma with extension into the lateral or superolateral orbital compartments. Seventy-six underwent tumor resection via LO approach coupled with extensive resection of all components of the hyperostotic SW, thus avoiding formal craniotomy.

In 1889, Kronlein first proposed a lateral approach to the orbit, and in 1953 he modified the lateral incision from a “horseshoe” osteoplastic type to a transverse one extending posteriorly from the lateral canthus for 30–35 mm. There have been some other modifications in these techniques.<sup>[23,28,30,35]</sup> We curved the incision superiorly up to the eyebrow [Figure 1] and have not transected the lateral canthal ligament or detached the lateral rectus muscle as advocated by others.<sup>[3,24,28]</sup> With this type of skin incision, the surgeon is able to approach tumors in the superior lateral, and inferior intraconal compartments, the apex of the orbit and posteriorly, the temporo-basal dura can be exposed up to the inferior frontal region. The hyperostotic bone located underneath the SOF cannot be drilled out from above and lateral aspect without changing the craniotomy to zygomatic or any variant of laterobasal approaches as mentioned by Dolence *et al.*<sup>[21,30]</sup> In our modified lateral approach, the hyperostotic lesser and greater wings, most of the hyperostotic clinoidal process, sufficient amount of the roof of the orbit and most of the involved bone back to the cavernous sinus, foramen Rotundum and Ovale can be drilled out under good visualization extradurally [Figure 7].

Even though complete bony decompression is achievable in this way and excision of the soft tumor tissue looks to be more precise using microdissection, (near to Simpson grade I in the tripod types in Table 1), but we did not proceed for removing the tumor infiltration from





**Figure 7: (a) Showing the minimal cosmetic effect of the incision on the face and (b and c) the amount of bone work performed deep to the skull base region without bone reconstruction in 3DRCTS. Minimal displacement of the bone strut did not produce any disfiguring**

within the dural leaflets of SOF in any one of our cases. Accordingly, we believe that all our cases ended with Simpson grade I to II level of tumor excision.<sup>[39]</sup>

### Reconstruction technique and cosmesis

Depending on the extent of resection of the wall and roof of the orbit, most authors who performed these variants of craniotomy procedures recommend firm reconstruction of the orbital walls to avoid pulsating En and diplopia.<sup>[16,19,25,30,38]</sup> We consider reconstruction of the hyperostotic lateral orbital wall and temporal bone to be unnecessary in nearly all the cases operated using lateral orbital mini-approach. The rate of improvement of Uex was good and the occurrence of En was nil even though statistically insignificant ( $P = 0.52$ , Table 4) [Figure 7].

By mini-approach, we do not intend to apply the term of “minimally invasive” technique. Removing as much bone to change the aspects of an ePMSW to a convexity meningioma, via the incision placed partly in the face is better not to be coined as “minimally invasive.”

Repairing the dura mater by autologous fascia, fat, and Gelfoam or Surgicel was sufficient in all of our cases and no disfiguring or pulsating En, fistula or meningocele were encountered in long-term follow up.

The issue of severe atrophy of the temporalis muscle occurred in 4/76 cases with LO mini-approach but 2/12 with C approach [Table 2]. To prevent such a complication, it is advised to: (a) Take care of the feeding arterial branches of the temporalis muscle and (b) release the traction applied upon the muscle while drilling the hyperostotic bone, microscopic fine excision of the ACP, and tumor excision is being done.

It looks disturbing that all or part of the scar is visible on the face and is not covered by hair. Half of the incision used for this approach is located within the eyebrow

and the other half (at most 3–3.5 cm) is located along the maxilla, which is best be sutured in a subcuticular manner.

### Role of adjuvant radiotherapy

Thirty-two of the cases in this series received adjuvant radiotherapy for control of tumor residue, which was resected to Simpson grade II level. FRT is an accepted modality of treatment in SOMs as suggested by different authors.<sup>[28,31,33,39,41]</sup> We delivered FRT by 40–50 (average 45) Gy in 1.8-Gy fractions only in the cases in whom the surgeon believed in invasive nature of the ePM either radiologically [Table 1], surgically, or in follow-up examinations. The low recurrence rate in our series suggest that on time postoperative radiotherapy may provide better control of tumor growth (Table 6,  $P = 0.99$ ).<sup>[1,16,18,36]</sup> No patient developed radiation-induced retinopathy or any pituitary insufficiency.

### Limitations

We could not evaluate the impact of increasing expertise of the surgeon in surgically handling the cases during specific periods of time regarding the inequality between the numbers of cases undergoing surgery each year and the differences in the exact follow-up intervals.

### CONCLUSION

Messages in this study can be:

- A smaller (mini-) LO approach without pterional or orbito-basal craniotomy can be promising and enough for removal of hyperostosing SW meningiomas with orbital involvement in most of the cases ( $P = 0.54$ )
- This approach may be nominated as ‘less invasive’ due to smaller skin incision with most of it hidden within the eyebrow. The tumor can be exposed as a convexity meningioma without fronto-parieto-temporal craniotomy. Hereby, only the involved/reactive bone is removed. *Bone should be excised as maximally as possible* both to decompress the orbit appropriately and to minimize the chance of tumor recurrence ( $P = 0.37$ )
- A selected group of SWMs with tumor extension in the anterior part of the temporal fossa and in the lateral or superomedial compartment of the orbital cavity and ACP can be successfully approached through LO approach, thus avoiding craniotomy. In these cases, this minimally invasive procedure allows removal of the tumor mass and the infiltrated bone, with good clinical and cosmetic result ( $P = 0.97$ ). Extension of the tumor mass medial to the axis of the optic nerve into the paranasal sinuses is considered *the cut-off point for further dissection regarding the benign nature of the pathology and acceptable tumor control interval*
- The thickened bone of the SW is not necessarily the origin of the tumor or infiltrated by the tumor (63%)

but it can be a reactive sclerosing bone (27%)

- This surgical technique is certainly not advised in cases with a large, carpet like dural tumor growth extending over the convexity or passing midline in the skull base region
- It is suggested that the RIePM should be excluded from the standard grading system of SOMs (ePM) in future classifications of mid skull base meningiomas.

## REFERENCES

- Abbott KH, Glass B. Pterional meningioma en plaque: Report of a case of thirty-six years' duration. *J Neurosurg* 1955;12:50-2.
- Al-Mefty O. Supraorbital-pterional approach to skull base lesions. *Neurosurgery* 1987;21:474-7.
- Arai H, Sato K, Katsuta T, Rhoton AL. Lateral approach to intraorbital lesions: Anatomic and surgical considerations. *Neurosurgery* 1996;39:1157-63.
- Baldeschi L, MacAndie K, Hintschich C, Wakelkamp IM, Prummel MF, Wiersinga WM. The removal of the deep lateral wall in orbital decompression: Its contribution to exophthalmos reduction and influence on consecutive diplopia. *Am J Ophthalmol* 2005;140:642-7.
- Bikmaz K, Mrak R, Al-Mefty O. Management of bone-invasive, hyperostotic sphenoid wing meningiomas. *J Neurosurg* 2007;107:905-12.
- Cannon PS, Rutherford SA, Richardson PL, King A, Leatherbarrow B. The surgical management and outcomes for sphenoid-orbital meningiomas. A 7-year review of multi-disciplinary practice. *Orbit* 2009;28:371-6.
- Carrizo A, Basso A. Current surgical treatment for sphenoid-orbital meningiomas. *Surg Neurol* 1998;50:574-8.
- Castellano F, Guidetti B, Olivecrona H. Pterional meningiomas en plaque. *J Neurosurg* 1952;9:188-96.
- Civit T, Coinat-Coulbois S, Freppel S. Orbital metastasis. *Neurochirurgie* 2010;56:148-51.
- Cophignon J, Lucena J, Clay C, Marchac D. Limits to radical treatment of sphenoid-orbital meningiomas. *Acta Neurochir Suppl (Wien)* 1979;28:375-80.
- Cristante L. Surgical treatment of meningiomas of the orbit and optic canal. A retrospective study with particular attention to the visual outcome. *Acta Neurochir (Wien)* 1994;126:27-32.
- Cushing H. The cranial hyperostosis produced by meningeal endotheliomas. *Arch Neurol Psychiatry* 1922;8:139-54.
- Cushing H, Eisenhardt L. *The Meningiomas: Their classification, regional behavior, life history, and surgical end results.* Springfield: Charles C. Thomas; 1938.
- De Jesus O, Toledo MM. Surgical management of meningioma en plaque of the sphenoid ridge. *Surg Neurol* 2001;55:265-9.
- Dolenc VV, Rogers L. Evolution from the classical pterional to the contemporary approach to the central skull base. In *Cavernous Sinus. Developments and Future Perspectives.* New York: Springer; 2009. p. 61-74.
- Gaillard S, Lejeune JP, Pellerin P, Pertuzon B, Dhellemmes P, Christiansen JL. Long-term results of the surgical treatment of sphenoid-orbital osteomeningioma. *Neurochirurgie* 1995;4:391-7.
- Goldberg RA, Kim AJ, Kerivan KM. The lacrimal keyhole, orbital door jamb and basin of the inferior orbital fissure. Three areas of deep bone in the lateral orbit. *Arch Ophthalmol* 1998;116:1618-24.
- Goldsmith BJ, Wara WM, Wilson CB, Larson DA. Postoperative irradiation for subtotally resected meningiomas. A retrospective analysis of 140 patients treated from 1967 to 1990. *J Neurosurg* 1994;80:195-201.
- Heufelder MJ, Sterker I, Trantakis C, Schneider JP, Meixensberger J, Hemprich A, et al. Reconstructive and ophthalmologic outcomes following resection of sphenoid-orbital meningiomas. *Ophthalmol Plast Reconstr Surg* 2009;5:223-6.
- Honeybul S, Neil-Dwyer G, Lang DA, Evans BT, Ellison DW. Sphenoid wing meningioma en plaque: A clinical review. *Acta Neurochir (Wien)* 2001;143:749-58.
- Honig S, Trantakis C, Frerich B, Sterker I, Schober R, Meixensberger J. Sphenoid-orbital meningiomas: Outcome after microsurgical treatment: A clinical review of 30 cases. *Neurol Res* 2010;32:314-25.
- Kim KS, Rogers LF, Goldblatt D. CT features of hyperostotic meningioma en plaque. *AJR Am J Roentgenol* 1987;149:1017-23.
- Kim JW, Yates BS, Goldberg RA. Total lateral orbitotomy. *Orbit* 2009;28:320-7.
- Langevin CJ, Hanasono MM, Riina HA, Stieg PE, Spinelli HM. Lateral transzygomatic approach to sphenoid wing meningiomas. *Neurosurgery* 2010;67 (2 Suppl Operative):377-84.
- Leake D, Gunnlaugsson C, Urban J, Marentette L. Reconstruction after resection of sphenoid wing meningiomas. *Arch Facial Plast Surg* 2005;7:99-103.
- Li Y, Shi JT, An YZ, Zhang TM, Fu JD, Zhang JL. Sphenoid wing meningioma en plaque: Report of 37 cases. *Chin Med J (Engl)* 2009;122:2423-7.
- Mariniello G, Maiuri F, de Divitis E, Bonavolonta G, Tranfa F, Iuliano A, et al. Lateral orbitotomy for removal of sphenoid wing meningiomas invading the orbit. *Neurosurgery* 2010;66 (6 Suppl Operative):S287-92.
- Mariniello G, Maiuri F, Strianese D, Donzelli R, Iuliano A, Tranfa F, et al. Sphenoid-orbital meningiomas: Surgical approaches and outcome according to the intraorbital tumor extent. *Zentralbl Neurochir* 2008;69:175-81.
- Maroon JC, Kennerdell JS, Vidovich DV, Aba A, Sternau L. Recurrent sphenoid-orbital meningioma. *J Neurosurg* 1994;80:202-8.
- McDermont MW, Durity FA, Rootman J, Woodhurst WVB. Surgical technique. Combined frontotemporo-orbitozygomatic approach for tumors of the sphenoid wing and orbit. *Neurosurgery* 1990;26:107-16.
- Miralbell R, Cella L, Weber D, Lomax A. Optimizing radiotherapy of orbital and paraorbital tumors: Intensity-modulated X-ray beams vs. intensity-modulated proton beams. *Int J Radiat Oncol Biol Phys* 2000;47:1111-9.
- Mirone G, Chibbaro S, Schiabello L, Tola S, George B. En plaque sphenoid wing meningiomas: Recurrence factors and surgical strategy in a series of 71 patients. *Neurosurgery* 2009;65 (6 Suppl):S100-9.
- Nicolato A, Ferraresi P, Foroni R, Pasqualin A, Piovan E, Severi F, et al. Gamma knife radiosurgery in skull base meningiomas. Preliminary experience with 50 cases. *Stereotact Funct Neurosurg* 1996;66 Suppl 1:112-20.
- Nozaki K, Kikuta K, Takagi Y, Mineharu Y, Takahashi JA, Hashimoto N. Effect of early optic canal unroofing on the outcome of visual functions in surgery for meningiomas of the tuberculum sellae and planum sphenoidale. *Neurosurgery* 2008;62:839-46.
- Oya S, Sade B, Lee JH. Sphenoid-orbital meningioma: Surgical technique and outcome. *Clinical article.* *J Neurosurg* 2011;114:1241-9.
- Peele KA, Kennerdell JS, Maroon JC, Kalnicki S, Kazim M, Gardner T, et al. The role of postoperative irradiation in the management of sphenoid wing meningiomas. A preliminary report. *Ophthalmology* 1996;103:1761-7.
- Pompili A, Derome PJ, Visot A, Guiot G. Hyperostotic meningiomas of the sphenoid ridge-clinical features, surgical therapy, and long-term observations: Review of 49 cases. *Surg Neurol* 1982;17:411-6.
- Ringel F, Cedzich C, Schramm J. Microsurgical technique and results of a series of 63 sphenoid-orbital meningiomas. *Neurosurgery* 2007;60 (4 Suppl 2):S214-21.
- Roser F, Nakamura M, Jacobs C, Vorkapic P, Samii M. Sphenoid wing meningiomas with osseous involvement. *Surg Neurol* 2005;64:37-43.
- Saeed P, van Furth WR, Tanck M, Freling N, van der Sprenkel JW, Stalpers LJ, et al. Surgical treatment of sphenoid-orbital meningiomas. *Br J Ophthalmol* 2011;95:996-1000.
- Sandalcioglu IE, Gasser T, Mohr C, Stolke D, Wiedemayer H. Sphenoid-orbital meningiomas: Interdisciplinary surgical approach, resectability and long-term results. *J Craniomaxillofac Surg* 2005;33:260-6.
- Scarone P, Leclercq D, Hexran F, Robert G. Long-term results with exophthalmos in a surgical series of 30 sphenoid-orbital meningiomas. *Clinical article.* *J Neurosurg* 2009;111:1069-77.
- Schick U, Bleyen J, Bani A, Hassler W. Management of meningiomas en plaque of the sphenoid wing. *J Neurosurg* 2006;104:208-14.
- Shrivastava RK, Sen C, Costantino PD, Della Rocca R. Sphenoid-orbital meningiomas: Surgical limitations and lessons learned in their long-term management. *J Neurosurg* 2005;103:491-7.
- Simas NM, Farias JP. Sphenoid wing en plaque meningiomas: Surgical results and recurrence rates. *Surg Neurol Int* 2013;4:86.
- Sincoff EH, Delashaw JB. Orbitosphenoid meningiomas. In: Lee JH, editor. *Meningiomas.* London: Springer-Verlag; 2008. p. 379-88.