

See discussions, stats, and author profiles for this publication at: <https://www.researchgate.net/publication/276129802>

Laser Therapy After Repair of the Distal Half of the Median Nerve; a Comparative Study

Article in Trauma Monthly · May 2015

DOI: 10.5812/traumamon.20(2)2015.23816

CITATIONS

READS

77

5 authors, including:



Seyedpezhman Madani
Iran University of Medical Sciences

15 PUBLICATIONS 109 CITATIONS

[SEE PROFILE](#)



Hamid Karimi
Iran University of Medical Sciences

88 PUBLICATIONS 510 CITATIONS

[SEE PROFILE](#)



Nazilla Seyed Forootan
Case Western Reserve University

9 PUBLICATIONS 14 CITATIONS

[SEE PROFILE](#)

Some of the authors of this publication are also working on these related projects:



comparison of early and late flap in high voltage electrical; injuries, results and complication [View project](#)



Burn registry program in Iran [View project](#)

Laser Therapy After Repair of the Distal Half of the Median Nerve; a Comparative Study

Kamal Seyed Forootan^{1,*}; Siamak Farokh Forghani¹; Seyed Pezhman Madani¹; Hamid Karimi Estahbanati¹; Nazilla Sadat Seyed Forootan²

¹Hazrate Fateme Hospital, Iran University of Medical Sciences, Tehran, IR Iran

²Biology Department, California State University, Northridge, United State of America

*Corresponding author: Kamal Seyed Forootan, Hazrate Fateme Hospital, Iran University of Medical Sciences, Tehran, IR Iran. Tel: +98-9121213716, E-mail: k_sforootan@yahoo.com, plasticsurgeons@yahoo.com

Received: September 22, 2014; **Revised:** December 27, 2014; **Accepted:** January 24, 2015

Background: Nerve injuries resulting from major or minor trauma often cause some disabilities for patients. Neurotmesis, characterized by complete anatomical rupture of the nerve, is the most severe form of the injury which will not recover without reconstructive surgery and nowadays such neural damages are improved by microsurgical procedures. Some studies have used low power laser for nerve cell growth in order to improve the rehabilitation results of peripheral nerves. Low power laser can complement the reformation of postsurgical nerve injuries.

Objectives: The current study aimed to assess the effects of laser therapy after repair of median nerve rupture in the distal third of the forearm and to compare the results with that of the standard method.

Patients and Methods: The current study was a case-control clinical trial of 36 patients with volar surface rupture of the distal third of forearm admitted to the emergency ward of Hazrat-e-Fateme Hospital within 72 hours of injury, they had anesthesia in the first, second, and third fingers as a result of Median Nerve Injury. Patients were divided into two groups. The first group included subjects treated with standard methods and the second group included those treated with low power laser therapy (LT) along with the standard method. The same surgeon operated the subjects in the two groups. The second group underwent 10 sessions of LT every other day. Clinical Examination, Electromyography and Nerve Conduction Velocity (NCV) were done after six months and the results were compared.

Results: In the two-point discrimination-test, there was no significant difference between the two groups in the thumbs but a significant improvement was observed in the index finger of the LT group. Improvement of muscular examinations such as opposition and thumb abduction supported the usage of laser in the second group. Regarding electromyography and NCV, significant statistical difference was observed in the motor part of the laser group and, to a great extent, was compatible with the physical examinations.

Conclusions: Accordingly, laser therapy in our protocol seemed to affect some of the nerve growth parameters, mostly on motor rather than sensory fibers.

Keywords: Low-Power Laser Therapy; Median Nerve; Electromyography

1. Background

Nerve injuries caused by major or minor traumas often cause some disabilities for patients. If such injuries are not managed properly, the results may be catastrophic. Appropriate repair of peripheral nerve injuries results in regaining the patient's function and maintaining an effective limb (1). Neurotmesis, characterized by complete anatomical nerve disruption, is the most severe form of this injury, which will not recover if not treated by reconstructive surgery. This injury is often observed after penetrating trauma or open wounds along with damages to adjacent structures such as tendons, muscles, bones, and blood vessels (1). Considering the importance of the hands and the undesirable effect of its nerve injuries on the patient's quality of life, physicians should aim to repaired them by microsurgical techniques (1). Only in 10% of the median nerve repairs, complete sensory and mo-

tor function is achieved (1), which indicates the need to improve this aspect. Recently, low power laser has been used to treat wounds, pain, myocardial and brain infarctions, and brain degenerative disorders; it also works on cellular and histological levels (2, 3). In some studies, the repair of peripheral nerve damage, administration of low power laser and its effect on nerve cell growth has shown beneficial effects complementing surgical repair (4). Studies also showed that laser therapy after inferior alveolar nerve-injuries caused by the extraction of the third molar and orthognathic surgery leads to better results in the treatment of sensory deficits (5, 6).

2. Objectives

This study aimed to assess the effects of laser administration after reconstructive surgery of median nerve dis-

ruption in the distal third of the forearm and compare the results with those of the standard method.

3. Patients and Methods

This study was a case-control clinical trial of 36 patients with volar surface rupture of the distal third of the forearm admitted to the emergency ward of Hazrat-e-Fate-meh Hospital within 72 hours of injury; on examination they had anesthesia of the first, second and third fingers as a result of median nerve injury. Excluding criteria were: age under 18 and over 60 years, simultaneous injury of ulnar or radial nerves, pregnancy, seizure, and prior trauma history. First, the subjects were informed about the surgery and the possibility of using either the standard method or combination with laser therapy. Then the subjects were randomly divided into two groups. All subjects underwent axillary anesthesia with 2% lidocaine. They received 1 g IV Cephalothin. A tourniquet was worn on the proximal arm with a pressure of 250 mm/Hg. After preparation with povidone iodide and draping, the wound was explored. First, the vascular and tendon injuries, if any, were repaired and then the two completely disrupted ends of the median nerve were trimmed with number 11 blade and epiperineural repair with 8-0 nylon under loupe magnification of 4.5 ×. Whenever the flexor retinaculum was open, it was repaired like a Z; then the skin was repaired with nylon 4-0. The skin of the area was marked with silk and the distance to the wrist crease was marked. A long brace was used on the dorsal side of hand and forearm. The wrist was fixed in 20 to 30 degrees of flexion, metacarpophalangeal joint in 70 to 80 degrees of flexion and the interphalangeal joint was fixed in extension. Then dressing applied. Subjects in the control group were discharged the day after. In the case group subjects, the dressing was undone and LT of the marked skin was done while the brace was still on. Then the subject was discharged, LT was done every other day for 10 sessions within a 20 day period. LT with a probe with a cross-section of 1cm², low power diode laser with an 810 nm wave length, 50 mw power, and 4 J energy was applied on the marked area for 30 seconds. The splint was used for three weeks in both the case and control groups; after that the subjects were referred for physiotherapy. After six months, the subjects were compared via the two-point discrimination test, (Nerve conduction velocity) NCV, (Electromyography) EMG, and muscular examinations. The two-point discrimination test had a classification of one to five as follows:

- 1) No point is perceived (No perception)
- 2) Only one point is perceived (Protective)
- 3) Perception of two points 11 to 15 mm of each other (poor perception)
- 4) Perception of two points 6 to 10 mm of each other (good perception)
- 5) Perception of two points at a distance of less than 6 mm (normal)

Muscular examinations such as opposition and thumb abduction-checkup were divided from zero to five grades based on the British Medical Research Council Rating System. Following these processes, the subjects were referred to a rehabilitation specialist for NCV and EMG tests; based on the physician's opinion, sensory and motor recovery were classified into four separate grades:

- 1) No Regeneration
- 2) Poor Regeneration
- 3) Fair Regeneration
- 4) Good Regeneration

There were 19 subjects in the control group and 17, in the case group.

4. Results

Out of the 19 subjects of the control group, six did not complete the research and 13 completed the whole process. On the other hand 14 out of 17 subjects of the laser group completed the study, 85% of the subjects were male and 15% were female and there was no significant statistical difference regarding gender distribution. Subjects in the laser group were between 18 and 47 years old with a mean of 26.19 ± 8.3 years and the control group subjects were between 18 and 44 years old with a mean of 30.71 ± 7.74. Age distribution of the two groups was compatible with the normal distribution and there was no statistical difference between the two groups regarding the subjects age (P value = 0.11), and 63% of the subjects had right hand and 36% left hand injury; 39% of the subjects underwent surgery within 24 hours of the injury, 42% within 48 hours, and 18% within 72 hours after the injury shown in Figure 1. Injury area in the laser group was in 10 - 60 mm proximal to the wrist crease with a mean of 26.25 mm ± 16.22 and in the control group it was in 10 - 70 mm proximal to the wrist crease with a mean of 34.12 mm ± 13.10, 66% of the subjects had been injured by glass, 21% by knife, and 12% by constructional and industrial equipment; 30% of the subjects had radial artery damage and none of them had ulnar nerve or artery damage. In the two-point discrimination-test of the thumb, there was no difference between the two groups. But a significant difference in the index finger was seen in the laser group in sensory recovery (P value = 0.04) shown in Table 1.

Table 1. Comparison Between Two Points in Laser And Control Groups^a

Finger	Grade		
	2	3	4
Thumb			
Laser	4 (28)	7 (50)	3 (21)
Control	6 (46)	6 (46)	1 (7.7)
Index			
Laser	5 (35)	6 (42)	3 (21)
Control	10 (58)	2 (15)	1 (7.7)

^a Data are presented as No. (%).

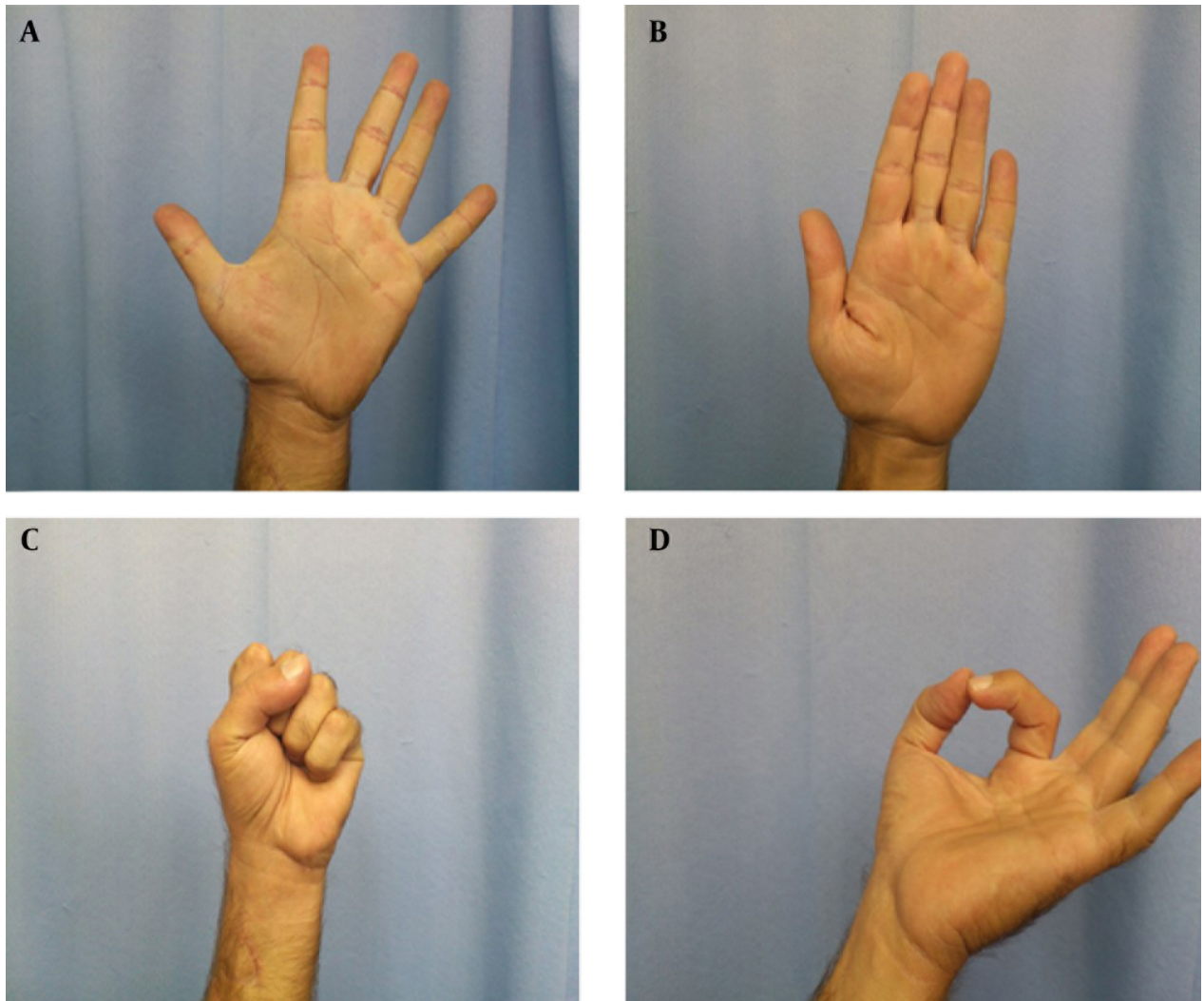


Figure 1. Different Modes of Hand flexion and extension

Table 2. Comparison Between Opposition and Abduction in Laser and Control Groups

Function	Grade				
	1	2	3	4	5
Opposition					
Laser	0	0	10	4	0
Control	1	1	11	0	0
Abduction					
Laser	0	0	0	6	8
Control	0	0	0	12	1

Regarding muscular examination tests, thumb opposition via the opponenspollicis muscle and abduction by abductor pollicisbrevis, recovery in laser group had significant statistical difference in comparison to that of the control group (P value = 0.001 and P value =

0.008) shown in Table 2.

NCV and EMG test results of the laser group were prominent concerning motor recovery (P value = 0.04). But it was not prominent in the control group with regard to sensory recovery (P value = 0.62) shown in Table 3.

Table 3. Comparison EMG-NCV Between Motor and Sensory in Laser and Control Groups ^{a, b}

EMG-NCV	Impression		
	Poor	Fair	Good
Motor			
Laser	0	4 (28)	10 (71)
Control	0	9 (69)	4 (30)
Sensory			
Laser	1 (7)	8 (57)	5 (35)
Control	2 (18)	7 (41)	4 (30)

^a Abbreviations: EMG-NCV, electromyography (nerve Conduction studies) - (nerve conduction velocity).

^b Data are presented as No. (%).

5. Discussion

Regarding the two-point discrimination test of the thumb showed no statistical difference between the two groups, unlike the study on inferior alveolar nerve by Ozen et al.(7). Regarding researches on rats for foot print recovery after laser therapy was effective on sciatic nerve (8-11) soleus muscle (5) and anterior tibialis muscle (6). These finding may be induced by increase in fiber diameters (5), numbers of axons (11), and growth speed (11). Also, there was a significant difference between the laser and control groups regarding NCV and EMG findings of motor nerves, and this result was compatible to that of animal study on rats by Medalha et al. (5) and Prathap et al. on diabetic neuropathy (12). Motor function recovery, to a great extent, was in sync with the physical exams of the current study. Considering the fact that complete recovery of the nerves takes at least two and a half years, future studies with more patients and longer periods can better show the effects of laser on other nerve recovery parameters, also supplementary researches on different types of lasers, different powers, number of usage and the duration of irradiation are advised. It seems that laser therapy based on the current study seems to affect the motor fibers more than the sensory ones. We recommend laser therapy in all patients after microsurgical reconstruction procedures of the peripheral nerves.

Acknowledgements

The authors express their thanks to everyone who helped with this study.

References

1. Winograd JM, Mackinnon SE. 181, Peripheral Nerve injuries Repair and Reconstruction. In: Mathes SJ editor. *Plastic surgery*. 2th ed. Philadelphia: Saunders Elsevier; 2006. pp. 471-514.
2. Khullar SM, Emami B, Westermark A, Haanaes HR. Effect of low-level laser treatment on neurosensory deficits subsequent to sagittal split ramus osteotomy. *Oral Surg Oral Med Oral Pathol Oral Radiol Endod*. 1996;**82**(2):132-8.
3. Khullar SM, Brodin P, Barkvold P, Haanaes HR. Preliminary study of low-level laser for treatment of long-standing sensory aberrations in the inferior alveolar nerve. *J Oral Maxillofac Surg*. 1996;**54**(1):2-7.
4. Yazdani SO, Golestaneh AF, Shafiee A, Hafizi M, Omrani HA, Soleimani M. Effects of low level laser therapy on proliferation and neurotrophic factor gene expression of human schwann cells in vitro. *J Photochem Photobiol B*. 2012;**107**:9-13.
5. Medalha CC, Di Gangi GC, Barbosa CB, Fernandes M, Aguiar O, Faloppa F, et al. Low-level laser therapy improves repair following complete resection of the sciatic nerve in rats. *Lasers Med Sci*. 2012;**27**(3):629-35.
6. Gigo-Benato D, Russo TL, Tanaka EH, Assis L, Salvini TF, Parizotto NA. Effects of 660 and 780 nm low-level laser therapy on neuromuscular recovery after crush injury in rat sciatic nerve. *Lasers Surg Med*. 2010;**42**(9):673-82.
7. Ozen T, Orhan K, Gorur I, Ozturk A. Efficacy of low level laser therapy on neurosensory recovery after injury to the inferior alveolar nerve. *Head Face Med*. 2006;**2**:3.
8. Yan W, Chow R, Armati PJ. Inhibitory effects of visible 650-nm and infrared 808-nm laser irradiation on somatosensory and compound muscle action potentials in rat sciatic nerve: implications for laser-induced analgesia. *J Peripher Nerv Syst*. 2011;**16**(2):130-5.
9. Barbosa RI, Marcolino AM, de Jesus Guirro RR, Mazzer N, Barbieri CH, de Cassia Registro Fonseca M. Comparative effects of wavelengths of low-power laser in regeneration of sciatic nerve in rats following crushing lesion. *Lasers Med Sci*. 2010;**25**(3):423-30.
10. Belchior AC, dos Reis FA, Nicolau RA, Silva IS, Perreira DM, de Carvalho Pde T. Influence of laser (660 nm) on functional recovery of the sciatic nerve in rats following crushing lesion. *Lasers Med Sci*. 2009;**24**(6):893-9.
11. Wu X, Dmitriev AE, Cardoso MJ, Viers-Costello AG, Borke RC, Streeter J, et al. 810 nm Wavelength light: an effective therapy for transected or contused rat spinal cord. *Lasers Surg Med*. 2009;**41**(1):36-41.
12. Prathap S, Maiya A, Saraswathi JD. Effect of low level laser irradiation on motor nerve conduction velocity of experimentally induced diabetic neuropathy in wistar rat. *J Pharm Biomed Sci*. 2011;**13**(30):629-35.