

See discussions, stats, and author profiles for this publication at: <https://www.researchgate.net/publication/271222952>

Pre-operative Rectal Indomethacin for Reduction of Postoperative Nausea and Vomiting after Laparoscopic Cholecystectomy: A Double-Blind Randomized Clinical Trial

Article in *Journal of the College of Physicians and Surgeons--Pakistan: JCPSP* · January 2015

Source: PubMed

CITATION

1

READS

80

6 authors, including:



Abdolreza Pazouki

Minimally Invasive Surgery Research center, Iran University of Medical Sciences

83 PUBLICATIONS 259 CITATIONS

[SEE PROFILE](#)



Fatemeh Jesmi

40 PUBLICATIONS 61 CITATIONS

[SEE PROFILE](#)



Ali Jangjoo

Mashhad University of Medical Sciences

72 PUBLICATIONS 550 CITATIONS

[SEE PROFILE](#)



Mohadeseh Pishgahroudsari

Iran University of Medical Sciences

23 PUBLICATIONS 94 CITATIONS

[SEE PROFILE](#)

Some of the authors of this publication are also working on these related projects:



In vitro analysis of T cells response induced by dendritic cells loaded with total mRNA of autologous cancer stem cells (CSCs) for immunotherapy of gastric cancer [View project](#)



Diabetes and obesity surgery [View project](#)



مرکز تحقیقات لاپاراسکوپی
دانشگاه علوم پزشکی شیراز

4th

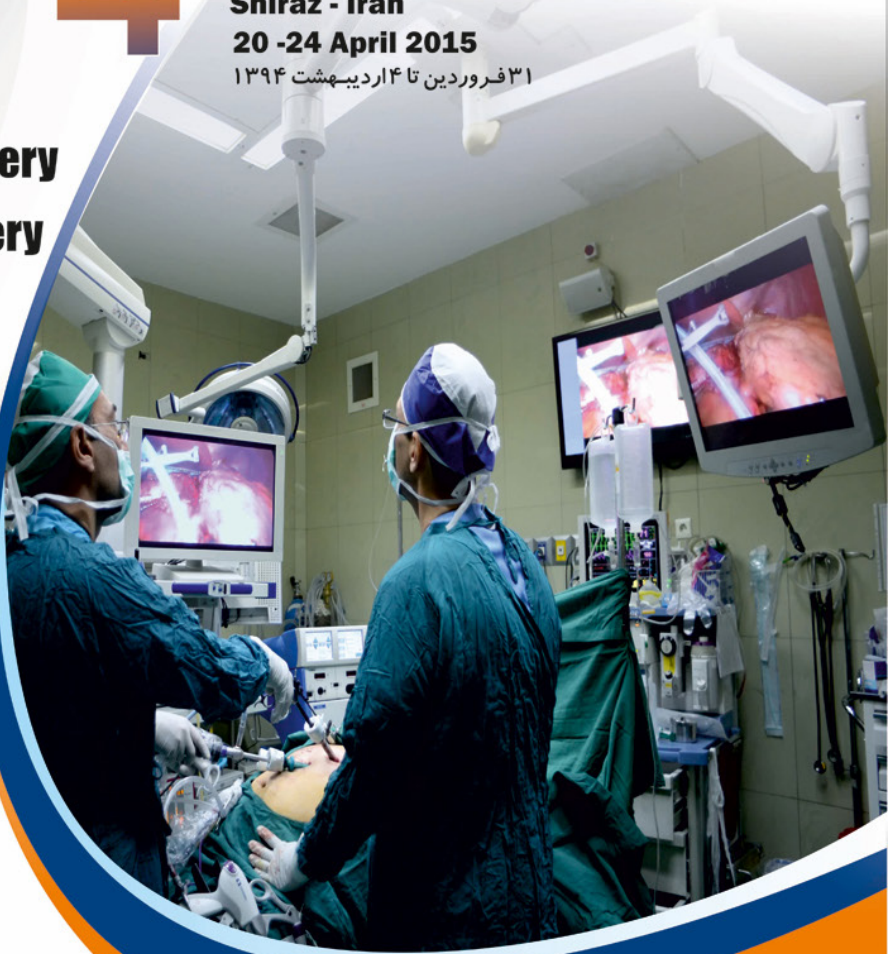International Congress of Minimally Invasive Surgery - IRAN

Shiraz - Iran

20 -24 April 2015

۳۱ فروردین تا ۴ اردیبهشت ۱۳۹۴

- **General and Colorectal Surgery**
- **Metabolic and Obesity Surgery**
- **Obstetrics and Gynecology**
- **Urology**
- **Pediatric Surgery**
- **Thoracic Surgery**
- **Cardiovascular Surgery**
- **ENT**
- **Neuro Surgery**
- **Radiology**



www.icmisi2015.com

Send Number **4** to **30005747** for more information



Scientific Secretariat:

Laparoscopy Research Center,
Mother and Child Hospital Ghadir,
Quran gate,
Shiraz,iran.

Web-site:lrc.sums.ac.ir
Tel-Fax:0713-2279711
E-mail:lrc@sums.ac.ir

Executive Secretariat:

No 1- 3rd floor - Rose Alley, North
Kargar Street
PO Box 1411986911
Tehran, Iran
Cell Phone: +98-9128175747

Tel: +98-21-88334436-8


Fax: +98-21-88634067

SMS: 30005747

Web-site: www.roxanco.com

E-mail: info@roxanco.com





In The Name of God

ABSTRACT BOOK

**4th International Congress of
Minimally Invasive Surgery-IRAN**

20-24 April, 2015

Shiraz, Iran

Magnetic Sphincter Augmentation in Patients with Severe Fecal Incontinence

Faramarz Pakravan

Abstract

Background: Fecal incontinence (FI) is a distressing condition that may lead to complete social isolation. If conservative treatment is unsuccessful, surgical intervention offers an alternative treatment option. This study examines the results of magnetic sphincter augmentation (MSA) in patients with severe FI.

Methods: Data were collected prospectively with the focus on changes in Cleveland Clinic Incontinence Score (CCIS) FI quality of life scores (FIQoL). Anorectal manometry and bowel diary information were also collected.

Results: Between January 2012 and October 2013, 18 patients (15 females), mean age of 69 (31-91) years with severe FI were implanted with MSA. Follow-up ranged from 353–738 days. Prior treatment consisted of peripheral nerve evaluation (PNE) test in 10 (56%) patients, 2 (11%) patients with prior permanent sacral nerve stimulation (SNS) and 1 (6%) prior implantation of an artificial bowel sphincter (ABS). Implantation was successful in 17/18 (94%) patients.

Five (29%) patients had post-operative pain and 5 (29%) patients had temporary swelling and erythema in both gluteal regions after the implantation. No devices were explanted during the follow-up. CCIS decreased from a mean of 17.5 (14-20) to 7.3 (0-12) and FIQoL improved in all 4 domains. Bowel diary results showed 76% of the implanted patients experienced a $\geq 50\%$ reduction in the number of FI episodes per week. Manometry done at 6 months post implantation showed increased mean resting and squeeze pressures.

Conclusion: Magnetic sphincter augmentation shows consistent results for the treatment of severe FI in this patient group. The surgical procedure is straight-forward as compared to other implantable devices. The safety profile is acceptable. MSA is a promising new treatment with the potential to become a first-line surgical therapy for severe FI.

Total Mesocolic Excision

Mir Jaafar Mousavi

Abstract

There have been many major improvements since the beginning of Mesorectal Excision (TME) for Rectal Cancer in the past 30 years. However, the improvements are still continuing to improve with more radical surgery for low rectal cancer. Pioneering work by leaders of rectal cancer surgery was initially ignored and it took the independent reproduction of the improved outcomes in single hospitals and small regional studies before large-scale regional and national training programmes. This led to major reductions in local recurrence, significant improvements in survival, and major financial savings occurred around the world.

Colon cancer accounts for around 70% of bowel cancer, and although the chance of survival has improved, it has not been to the same extent as that for rectal cancer, with substantial variation remaining between hospitals or operative cases. Historical reports have shown significantly improved survival in colon cancer following surgical standardisation, 2–4 and excellent results from Japan have largely been ignored.⁵ The rectal cancer story is repeating itself.

Colonic cancer resection in western countries, and may be in whole world, is unfortunately still viewed as a routine procedure with little concern surrounding these major variations in the outcome. Indeed, the focus was on laparoscopic surgery instead of the optimisation of the surgery.

A paper by Claus Anders Bertelsen and colleagues,⁶ and the debate that it should generate, is a key step to reproduce the benefits of optimum rectal cancer surgery in colon cancer. It also hints at what could be achievable by the routine adoption of high-quality surgery. In this detailed report, the researchers show that implementation of a complete mesocolic excision (CME) with central vascular ligation (CVL) results in a major improvement in the chance of survival. By simply visiting and adopting the methods of expert surgeons in Erlangen, led by Werner Hohenberger,⁴ and by quality controlling their surgery through mesocolic grading, routine specimen photography, and internal and external pathology audit,⁷ the researchers have independently reproduced results from Erlangen and Japan.

The improvement in the outcome described could be attributable to two specific variables; first, CME, which comprises the intact removal of the mesocolon and its lymphatic drainage within embryological planes. This procedure should be routine; it does not increase risks to the patient and might seem obvious since careful dissection following anatomical planes is a basic principle of surgery. Such planes were described in the early 20th century, but on close scrutiny surgical planes are very variable and must be improved.^{8,9} Second, but more controversially, is the role of CVL. This procedure entails more radical central dissection, with potential risk to major vessels, nerves, and organs such as the pancreas. In Erlangen, Japan, Hillerød, and now in Norway, such surgery seems to be safe, but several important questions remain. How much benefit does it convey in addition to mesocolic surgery? What is the learning curve and is this achievable for all surgeons? Can it be safely achieved laparoscopically?

Transanal Excision of a Rectal Mass-Retrosternal Gastroplasty for Caustic Injury of the Esophagus by Laparoscopic Approach

M Boubekeur, M.Z Kherrou, N. Chadli

Abstract

Plasty by retrosternal esophageal laparoscopic procedure has only been described in 2012 and 2013 by an Indian team. We have taken this innovative approach and will share our experience by presenting this work.

A 27-year-old patient, who accidentally ingested a strong base there 7 months, carrying a feeding jejunostomy, which benefited from gastrolysis and clothing of esophageal plasty by tubulisation of the stomach as well as tunneling in retrosternal path plasty by strictly laparoscopic approach.

Only the gastroesophageal anastomosis was done by the left cervicotomy.

Therefore, the patient has received all the benefits of laparoscopy.

Thoracoscopic Esophageal Atresia Repair: Report of 40 Cases

Mehran Hiradfar, Ghazaleh Azimzadeh
Khosravi, Farnaz Mirhosseini

Endoscopic And Minimally Invasive
Surgery Research Center,
Ghaem Hospital, Faculty of Medicine,
Mashhad University of Medical Sciences,
Mashhad, Iran

Abstract

Background: Minimally invasive surgery (MIS) is becoming more common in pediatric surgery. Neonatal MIS is a difficult part of this field and need much more experience. Esophageal atresia is one of the diseases in neonatal surgery that today we are able to correct the defect by MIS. The minimally invasive technique for surgical correction of esophageal atresia (EA) was first described by Lobe et al. From that time, it has been gaining acceptance among many pediatric endoscopic surgeons. The first successful thoracoscopic repair of EA was performed in 2000, but it was not popularized in the world until 2005. In this article we present our experience in thoracoscopic repair of EA in Mashhad University of Medical Sciences that was started from 2010.

Methods: From 2010-2015, 40 thoracoscopic attempts were performed to correct the EA-TEF in neonates in Pediatric Surgery Department of Dr. Sheikh Pediatric Hospital of Mashhad University of Medical Sciences. 23 cases were operated completely by thoracoscopic approach. From 2010 to 2012, 15 thoracoscopic attempts were performed. Of this number, conversion happened in 10 cases (66.6%). In 2013, the number of conversion dramatically dropped in 2 cases (14.2%) from 14 thoracoscopic attempts which declined up to 79% than the first 2 years. In 2014, this rate was increased again and reached to 5 cases (45.4%) from 11 thoracoscopic attempts. This increase was due to starting learning curve for two other pediatric surgeons who joined to our MIS team. Totally, conversion was required in 17 cases (42.5%) during these years. In all cases, procedure was performed through the right thoracic cavity with 4 ports. The length of first successful thoracoscopic repair was 5 hours, but with increasing experience, mean time of operation has been decreased up to 178 minutes in the last two years.

Results: Full thoracoscopic EA repair was performed in 57% of cases.

Conclusion: It seems that EA-TEF repair needs long time learning curve. The success rate has been improved with increased experience.

Pre-operative Rectal Indomethacin for Reduction of Postoperative Nausea and Vomiting after Laparoscopic Cholecystectomy: A Double-Blind Randomized Clinical Trial

Abdolreza Pazouki, Fatemeh Jesmi,
Roozbeh Cheraghali, Hossein
Saeedimotahhar, Mohadeseh
Pishgahroudsari

Minimally Invasive Surgery Research
Center, Iran University of Medical
Sciences, Tehran, Iran

Abstract

Background: To evaluate the effect of pre-operative indomethacin suppository on postoperative nausea and vomiting inpatients undergoing laparoscopic cholecystectomy.

Study Design: A double blind placebo-controlled randomized clinical trial.

Place and Duration of Study: Hazrat Rasoul Akram Hospital, Tehran, Iran, from February 2010 to September 2012.

Methods: One hundred and thirty patients, scheduled for laparoscopic cholecystectomy, were randomly divided into case and control groups. Sixty-five patients received indomethacin suppository and 70 patients received rectal placebo in the case and control groups respectively. All patients underwent the same protocol in laparoscopic surgery and anesthesia, then nausea and vomiting was recorded after 1, 6, 12 and 24 hours postoperatively and compared between the two groups. Independent-sample t test or Mann-Whitney tests were used for statistical analysis. Level of statistical significance was set at $P < 0.05$.

Results: Patients' nausea was statistically lower in the case group at the 1st hour (43.1 vs. 92.9%), 6th hour (20.0 vs. 68.6%) and 12th hour (7.7 vs. 24.3%) after surgery (for all periods, $P < 0.001$). Fewer patients in the case group experienced vomiting at the first (13.8 vs. 51.4%) and 6th hour (0 vs. 20%) after surgery (for both $P < 0.001$). The use of pethidine was also statistically less in the case group in the same hours after surgery (for all of them, $P < 0.001$).

Conclusion: Rectal indomethacin before laparoscopic cholecystectomy led to lower postoperative nausea and vomiting.

Laparoscopic Pyloro-Duodenal Minimal Invasive Surgeries in Neonates and Infants

O. Reinberg

Abstract

Pyloro-duodenal malformations or acquired obstructions require surgeries. Most of the procedures can be completed by minimally invasive surgical (MIS) techniques even in infants and neonates.

Laparoscopic pyloromyotomy for hypertrophic pyloric stenosis (HSP) was one of the first procedures performed in infants. It has been debated for years, whether it was beneficial with regard to open transumbilical approach. The transrectal approach being abandoned in most teams. It is performed with two instruments without ports. Even, if the procedure depends on the preferences of the attending surgeon, it is an excellent training procedure. It allows fewer complications (perforations), due to an improved visualization related to the magnification provided by laparoscopy, but more incomplete myotomies.

Congenital duodenal obstructions are common malformations in neonates, including duodenal atresia, duodenal stenosis, annular pancreas, and congenital intestinal malrotation. Opening the duodenum and re-suturing it (to perform a duodeno-duodenal anastomosis) to bypass and atresia or an annular pancreas (to resect a web) can be done by laparoscopy even in full-term neonates without anesthetic contraindications. The laparoscopic procedure is an important method of atraumatic diagnosing. The suture in a very narrow space can be assisted by suspension techniques.

Acquired pyloric or duodenal obstructions, usually encountered in older children, can benefit from a lap pyloroplasties according to Mikulicz, if indicated.

Pediatric Surgeon FMH, EBPS,
University Hospital of Lausanne,
Lausanne, Switzerland

Esophageal Replacements in Children

O. Reinberg

Abstract

The first esophageal replacement was performed in 1906 by a Swiss surgeon called César Roux on a 12-year-old child with caustic burn. Even today, the tradition of esophagoplasties continues in Lausanne, Switzerland.

Replacements of the esophagus are used in case of malformations, injuries or acquired conditions. The new esophagus should allow normal oral feeding, with little or no gastro-oesophageal reflux, and be able to operate for the lifetime of the patient. Many substitutes have been used since a century ago, such as segments of colon, entire stomachs, gastric tubes or parts of the small bowel. However, none of them is perfect and unable to operate as a normal esophagus.

Previously, esophageal replacements were done in several steps. We introduced the one-stage procedure in 1989, placing the transplant in the posterior mediastinum following a closed-chest esophagectomy. In 1993, we described a new anti-reflux procedure for esophageal replacements and in 2006, the laparoscopic transhiatal esophagectomy.

Esophageal replacements are demanding challenges for the surgeons. We shall review different techniques and the pitfalls related to these procedures based on our personal experience (more than 280 esophageal replacements in children since 1989), using either transverse colonic transplants or gastric tubes and some other techniques.

Pediatric Surgeon FMH, EBPS,
University Hospital of Lausanne,
Lausanne, Switzerland

Robotic Surgery in Russia

A.A. Popov, A.A. Fedorov, A.A. Koval,
K.V. Mironenko

Abstract

The surgical robot “Da Vinci” (DV, Intuitive Surgical, USA) is the biggest technological development of the recent decades. Currently, over 4000 robotic surgical systems in 54 developed countries have been used successfully. In Russia, the first surgery with a robot DV was performed in Ekaterinburg in November 2007. Today, there are 23 centres in eight cities (Moscow, St. Petersburg, Ekaterinburg, Khanty-Mansiysk, Novosibirsk, Vladivostok, Tuapse, and Rostov) equipped with robot DV. By the end of 2013, Pirogov National Surgical Institute (Moscow) was the technological leader in this area by performing 1000 operations in urology, gynaecology, oncology, abdominal, and thoracic surgery. In gynaecological surgery, the DV-robotic complex is used in six medical centres across the country. Below is a brief list of activities:

- Since 2009, 311 women were operated with various types of gynaecological interventions.
- Since 2011, 76 DV-assisted procedures have been performed in St. Petersburg. It included; 12 myomectomy, 64 endometriosis surgery, and 9 hysterectomy.
- Since 2011, 16 DV-assisted procedures have been performed in Khanty-Mansiysk that included 16 myomectomy and 6 hysterectomy.
- Since 2012, 12 DV-assisted procedures have been performed in Ekaterinburg, all of which were hysterectomy.
- Since 2013, 3 DV-assisted procedures have been performed in Clinic EMC (Moscow), all of which were hysterectomy.
- Since 2012, 71 DV-assisted procedures have been performed in Moscow Regional Scientific Research Institute of Obstetrics and Gynaecology. It included 58 SVP, 7 hysterectomy, 4 hysterectomy with lymphadenectomy, 1 myomectomy, and 1 cervical cerclage.
- Since 2009, 181 DV-assisted procedures have been performed in Pirogov National Surgical Institute (Moscow). It included 116 hysterectomy, 32 hysterectomy with lymphadenectomy, 2 hysterectomy with omentectomy, 64 myomectomy, 14 resection of rectovaginal endometriosis, 31 SVP, 8 peritoneal colpopoiesis, 2 simultaneous operations, and 4 others.

The DV surgical system allows going beyond the limitations of open and conventional laparoscopic surgery, expanding surgeon’s capacity (due to technical innovation) and improvement of visualization and manipulation in difficult surgical areas. The surgeon’s ergonomomy is also important.

Moscow Regional Scientific Research
Institute of Obstetrics and Gynaecology,
Moscow, Russia

Laparoscopy for Pelvic Relaxation

A.A. Popov, T.N. Manannikova, B.A. Slobodyanyuk, A.A. Fedorov, A.A. Koval, K.V. Mironenko, D Gumina

Abstract

Background: The problem of POP is still one of the most actual in urogynecology. New methods of surgical management are constantly developed and improved. TV mesh technologies are still widely spread; however, indications are limited according to the FDA recommendations. The number of sacrocolpopexy performed by laparoscopic approach has increased in the last few years.

The purpose of this study is to evaluate the efficiency of SCP-operations performed in Russian clinics, and to observe the frequency and types of complications, as well as to analyse simultaneous operations and the type of mesh used.

Methods: We analysed the number of conducted operations, the share of laparoscopic approach, the frequency of intra- and post-operative complications, and the favoured type of mesh. There were the estimated medical data from 15 clinics in Moscow, Saint Petersburg, Omsk, Krasnodar, Ekaterinburg, Ivanovo, and Kemerovo. There were more than 20 operations in each clinic.

Results: 1,338 operations (including 264 operations held in 2013) were evaluated since 1996. The most clinics (8 of 10 clinics) laparoscopic approach accounts for 90-100%. Laparotomic approach was prevalent in two clinics (90-100%). In two departments, 3.5% of operations performed using DaVinci robot. The intraoperative complication rate was 1.8%, including the injury of bladder (3.2%), of vena iliaca interna (0.08%), of ureter (0.2%), rectum (0.8%). The most common postoperative complications were vaginal erosions (2.8%) – in all cases hysterectomy was held; hematoma formation required reoperation (0.8%), ileus (0.8%), deep venous thrombosis (0.5%), spondylodiscitis formation (0.08%). The most common functional complications were de novo SUI (1.8%) and cystocele formation (1.2%).

Seven of 10 clinics preferred polypropylene mesh “GynemeshSoft” (GPSL) and considered it the material of choice for CSP. The most frequent simultaneous operations were supracervical hysterectomy (67%), trachelectomy (8%), hysterectomy, anterior and/or posterior colporrhaphy (12%); the anti-stress operations were TVT-O (82.5%), TVT suprapubic (11%) and burch colposuspension (6%).

Conclusion: Sacrocolpopexy becomes more popular in advanced-stage POP management in Russia, due to its safety and high efficiency. It is possible to restore the anatomy of all possible facial defects with the lowest risk of complications and better functional outcomes. Laparoscopy is the dominant approach in SCP in tertiary centres in Russia. This type of operations is suboptimal for high-grade cystocele, especially with different concomitant fascial defects (i.e. trapdoor cystocele). In this case, the optimal choice is still vaginal mesh in spite of FDA precautions.

Moscow Regional Scientific Research
Institute of Obstetrics and Gynaecology,
Moscow, Russia

Thoracoscopic Aortopexy for Severe Tracheomalacia

M.R. Vahdad¹, A. Semaan¹, T.M. Boemers¹, T. Klein¹, G. Cernaianu², R.B. Troebs², H.R. Foroutan³

¹Department of Pediatric Surgery and Pediatric Urology, Children's Hospital Cologne Germany;

²Department of Pediatric Surgery, Ruhr-University of Bochum, Germany;

³Department of Pediatric Surgery, Shiraz University of Medical Sciences, Namazi Hospital, Shiraz, Iran

Abstract

Background: Severe tracheomalacia presents a significant challenge for pediatricians and pediatric surgeons. The treatment of tracheomalacia is still controversial. Aortopexy is the most effective treatment for severe tracheomalacia associated with esophageal atresia. In the last decade, the thoracoscopic approach has been proposed as an alternative treatment. The aim of this study is to present our experience with open aortopexy and our initial experiences with thoracoscopic aortopexy.

Methods: A retrospective review of medical records was performed on patients undergoing aortopexy from January 2001 to January 2015. Patient demographics, indication, perioperative course, and long-term results (if available) were noted in three different pediatric surgery departments.

Results: Thirteen patients underwent a successful aortopexy (n=3, thoracoscopic) and no operation being converted. No morbidity or mortality was associated with the procedure. The length of postoperative stay ranged 2-4 days. Most patients were relieved of their symptoms, and one recurrence was noted.

Conclusion: Thoracoscopic aortopexy is a feasible and successful treatment for severe tracheomalacia. Thoracoscopic aortopexy seems to be as effective as open aortopexy. However, a larger and prospective study with a longer follow-up is required to confirm these preliminary results.

How can Adequate Instruments and Adhesion Prevention Support Gynecological Laparoscopic Surgery?

L. Mettler

Abstract

Background: Instruments and apparatuses are the key features that enable a skilled surgeon to perform optimal precise, good and really indicated surgical procedures without the production of inflammation, adhesions and complications.

Thanks to a good application, in our times, of common knowledge in military institutions, aviation, space technology, information technology, engineering, mathematics, biology, genetics, physiology, and medicine, wonderful instruments are available today. Of course, we have to know how to apply them.

Concerning adhesions, we performed a selective PubMed/MEDLINE search using “adhesions”, “laparoscopy”, and “prevention of adhesions” as keywords. Of all known methods, barriers appeared to be the most effective technology. In laparoscopy and hysteroscopy, the use of heated and moist gas definitely causes less adhesion. A continuous suction and irrigation at endoscopic procedures is also advisable.

Methods: Technical developments give us many choices today:

- The OR 1, Alpha Image Track
- Optics like the Endo-Eye, HDT, Endo-Cameleon
- Electronic insufflators with heated and moist gas
- Robi Instruments, articulated instruments, Kymerax
- Bipolar and thermofusion technology for haemostasis, ultrasound instruments, thunderbeat (a combination of US and thermofusion technology)
- Good needle holders, suturing skill, loops, cutting loops for subtotal hysterectomies
- Robotic and single port access

The first generation of barriers consisted of meshes like “Interceed”. Later, viscous solutions such as “Intergel” and “TISSUCOL” were propagated. In recent years, sprayable liquids as polyethylene glycols: PEG’s (SprayShield and Coseal), that polymerize to hydrogels with the addition of colorants and without colour, revealed 65-70% reduced adhesion formation.

Hydroflotation with liters of icodextrin solutions (4%) for rinsing and instillation at the end of surgery gave on the surgical site a significant adhesion reduction. HyaCorp endo gel (BioScience, Germany) is a product on hyaluronate basis that is applied by simple squeezing through an applicator. It has recently gained attraction again and appears to be effective. In second look laparoscopies is 70% reduction of adhesions could be observed (Mettler et al, MITAT, Early Online, 1-6, 2013).

Results: The exchange of knowledge in the different surgical fields as demonstrated in NESA and SLS finally enable us to perform the surgery we would like to achieve (video). As

Department of Obstetrics & Gynecology,
Schleswig-Holstein University Hospitals,
Kiel, Germany

adhesion barriers, for the time being we advise a combination of local coverage of defects with some hydro flotation.

Conclusion: The surgeon and the correct instruments guarantee success. The level of evidence of the currently available products in the market is limited. However, a combination of a site-specific spray or gel together with hydroflotation, and possible assistance by an anti-inflammatory medication seems promising.

Primary and Revisional Gastric Bypass after Failed Gastric Banding, Early and Late Outcomes

J.L. Bouillot¹, J. Thereaux¹, Ch. Poitou²,
S. Czernichow¹, J.M. Oppert²

Abstract

Despite their frequent use, the long-term results of adjustable gastric bands are variable and often disappointing. For patients with poor weight loss or secondary weight regain, the opportunity for a reoperation is challenging. As primary laparoscopic Roux-en-Y gastric bypass (LRYGB) provides good long-term results, several authors suggested that this procedure should be the reference for revisional surgery. Nevertheless, the short- and long-term data comparing primary LRYGB (pLRYGB) and revisional LRYGB (rLRYGB) for failed adjustable gastric banding are scarce.

The aim of the present study was to compare, in our prospective, database the early (30-day outcome) and late results (weight loss and change in obesity related comorbidities at 5 years of follow-up) of pLRYGB with rLRYGB.

During a ten year period (January 2004 to June 2013), we performed 1008 LRYGB: 831 had a primary procedure and 177 had a revisional procedure. Overall, 78% were female, mean age was 42 years, and mean body mass index was 47 kg/m². In order to evaluate the patients with a 5-year follow-up, we matched 45 patients undergoing rLRYGB with 45 undergoing pLRYGB operated from 2004 to 2008. The two groups were similar for age, sex ratio, BMI, and comorbidities.

The rates of major adverse outcomes during the 30-day post-operative period were similar in the primary and revisional groups (7.8% vs. 8.5%). Mortality at 30-day was 0.5%, with no difference between the two groups. At 5-year, weight loss (40 kg vs. 31 kg), percentage of weight loss (31% vs. 25%) and percentage of excess weight loss (68% vs. 56%) were higher in pLRYGB than for rLRYGB.

Conclusion: The 30-day major adverse outcome rates are similar for pLRYGB as well as rLRYGB and revisional surgery after adjustable gastric banding is a safe procedure. After 5-year of follow-up, weight loss was higher after pLRYGB than for rLRYGB. Nevertheless, obesity is a chronic disease and the patients may require several operations during their life. Banding could be seen as the initial procedure of a sequential surgical program.

¹University Versailles, Assistance
Publique-Hôpitaux de Paris, Versailles,
France;

²University Paris VI, Assistance
Publique-Hôpitaux de Paris, Paris,
France

Laparoscopic Total Gastrectomy and D2 Lymphadenectomy for Gastric Cancer

B. Ghavami

Visceral Surgeon, Hirslanden Hospital
Group, Lausanne, Switzerland

Abstract

Background: Laparoscopic approach to total gastrectomy has advantages compared with open surgery. This is evidenced by shortened hospital stay, less blood loss, quicker post-operative recovery, and earlier return of transit. The presence of occult micrometastases in lymph nodes left behind by a D1 lymphadenectomy may influence the prognosis of treatment and necessitates a type D2 lymphadenectomy. This study reports on the feasibility of such interventions.

Methods: 26 patients with cardial, subcardial or isolated cell gastric carcinoma underwent total gastrectomy and D2 lymphadenectomy by laparoscopy. All three procedures were performed with the assistance of the DaVinci® robot. Anastomoses were mechanical 21 times and five were manual.

Results: Intervention time averaged 220 minutes, ranging between 180 and 300 minutes. The number of lymph nodes harvested ranged from 21-53 (mean 36). 24 patients were R0, and 2 patients R1. A patient with anastomotic leakage had to be reoperated several times. The average hospital length of stay was 10 days.

Conclusion: Total gastrectomy by laparoscopy with D2 lymphadenectomy is feasible.

The video shows a laparoscopic total gastrectomy and D2 lymphadenectomy.

Minimally Invasive Procedures for Esophageal Atresias

O. Reinberg

Abstract

Advances in techniques and instruments in pediatric minimally invasive surgical (MIS) techniques have allowed to perform the most complex procedures even in neonates. The thoracoscopic cure of an esophageal atresia (EA) in a neonate, with or without tracheoesophageal, was a symbolic challenge for pediatric surgeons who had to face many problems. We first realized neonatal cures by a video-assisted thoracoscopic surgery (VATS) procedure in 1997, as we did not know enough about the neonatal tolerance to pneumothorax. In 2000, during the same time period, three teams successfully performed an EA by thoracoscopy in neonates; Lobe and Rothenberg (Denver, USA). Yeung (Hong Kong) and Reinberg (Lausanne, Switzerland). After 15 years, this procedure has become a good repair practice.

A careful anesthetic evaluation must be done since more than 50% of the patients have cardiac anomalies. The child is placed in a near prone position. At the beginning of our experience, we developed techniques for right lung exclusions, however, we then learnt to work without it. The procedure is done with two, 3 mm trocars and one 5 mm trocar with 30° for the telescope. An intermittent pneumothorax is inflated at 5 mmHg. The fistula is found under the azygos vein and ligated with a transfixiant suture along the posterior face of the trachea. Then, the two edges of the atresia are approximated and sutured. We often use temporary transthoracic traction threads to release tension while performing the anastomosis. Before ending the suture, a nasogastric tube is placed down to the stomach under view control, so that the following day the baby is fed through it. An upper gastrointestinal (UGI) is done between D7 and D10 according to the tension on the suture. Should a leak be present, the oral feeding is postponed.

Thoracoscopic EA repair has proved to be an effective and safe technique. It gives the surgeon a microsurgical view of the structures and anastomosis. The evolution of the technique has resulted in fewer complications while avoiding significant short- and long-term morbidity associated with thoracotomies in neonates. Moreover, previously unsolved problem of the right aortic arch is outdated.

Pediatric Surgeon FMH, EBPS,
University Hospital of Lausanne,
Lausanne, Switzerland

Advantages and Disadvantages of Single-Port Laparoscopy

S.V. Hosseini, A. Bananzadeh, L. Ghahramani, M. Amini

Abstract

Laparoscopic techniques have allowed surgeons to perform complicated intra-abdominal surgery with minimal trauma. Single-port laparoscopic surgery (SPLS) was developed with the aim of reducing the invasiveness of conventional laparoscopy. Ever since the first attempt of SPLS hysterectomy in 1992, SPLS was adopted by other surgeons in procedures such as appendectomy, cholecystectomy, splenectomy, adrenalectomy, nephrectomy, and sleeve gastrectomy. Colorectal surgeons were also eager to deploy the novel SPLS technique in right hemicolectomy, sigmoidectomy, and total colectomy. The spectrum of SPLS applications has extended from benign diseases to malignant cancers and the safety and feasibility of SPLS in surgery is supported by many reports and comparative studies.

Most of the SPLS procedures have been carried out at Shiraz University of Medical Sciences during the last four years. There have been 94 cholecystectomy, 54 sleeve gastrectomy, 23 partial colectomy and few nephrectomy, hysterectomy, splenectomy and even total colectomy.

Single-port laparoscopic surgery has clear-cut benefits in terms of cosmesis, reduced bleeding and reduced wound morbidity. SPLS is particularly useful in operations that are aimed at more than two target organs in different quadrants; for the umbilicus provides a shortcut to reach all intra-abdominal organs.

There are some disadvantages such as expensive instruments, longer operation time, technical difficulties, and a slow learning curve.

The technical difficulties have been overcome by novel concepts and maneuvers, including the concept of inverse triangulation and the maneuvers of pivoting, spreading out dissection, hanging suture, and transluminal traction.

Laparoscopic Research Center, Shiraz
University of Medical Sciences, Shiraz,
Iran

Management of Post Sleeve Gastrectomy Leakage

Masood Amini^{1,2}, Hadi Hadavi^{1,2},
Masood Sepehrimanesh³

¹Laparoscopy Research Center, Shiraz University of Medical Sciences, Shiraz, Iran;

²Obesity Specialized Clinic, Ghadir Mother and Child Subspecialized Hospital, Shiraz University of Medical Sciences, Shiraz, Iran;

³Gastroenterohepatology Research Center, Shiraz University of Medical Sciences, Shiraz, Iran

Abstract

Incidence of leak in Roux-en-y – Gastric bypass is 1/4%, and this incidence in sleeve gastrectomy is higher than laparoscopic Roux-En-Y gastric bypass (has been reported at 2.2 % from 24 studies).

It's Etiology are classified to:

- 1) Technique related
 - A. poor technique in anastomosis
 - B. excessive tension
 - C. staple line bleeding
 - D. tissue ischemia,
- 2) patient related
 - A. Poor nutrition
 - B. smoking
 - C. liver cirrhosis
 - D. renal failure

In this case series study we studied 227 (59 male) consequent cases underwent laparoscopic sleeve gastrectomy in 1 center by one team during 2012 to 2014.

Of 227 sleeve cases 5 patients labeled as gastric leakage. All of them presented in first 5 post operative weeks (early leakage). One of them presented with dyspnea and abdominal pain which managed percutaneously (drainage with pigtail catheter) and 4 cases developed gasterocutaneous fistula. All of them treated with percutaneous drainage and conservative management. In early leak (2-6 post operative weeks) we managed all of our cases none surgically with CT guided percutaneous radiologic intervention.

Management of post sleeve gastric leakage depends on:

- 1- timing of presentation
- 2- extent of disruption
- 3- site of leakage

Laparoscopic Ovarian Drilling

Saghar Salehpour

Abstract

Laparoscopic ovarian surgery (LOS) applies diathermy or laser for ovarian drilling aimed at restoring ovulation and achieving pregnancy. The main indication for LOS in patients with PCOS is resistance to clomiphene citrate.

LOS can achieve single ovulation without the risk for ovarian hyperstimulation or multiple pregnancies. Following LOS, regular monitoring of follicular development is not required.

This method is an alternative option to gonadotropin administration in anovulatory patients with PCOS who are resistant to clomiphene citrate. LOS is particularly indicated in patients in whom regular monitoring with ultrasound is not feasible. With current technical advances, the intervention is completed in a single session. The risks of LOS are small and include laparoscopy per se, the development of adhesions and the destruction of normal ovarian tissue. The damage to the ovaries should be limited as much as possible. Irrigation with specific solvents might be useful for the reduction of risk for development of adhesions.

The chance of achieving a continuing pregnancy within 6 months is less than with carefully conducted ovulation induction with gonadotrophins but, if adjuvant ovulation induction agents are used in those who do not initially respond, the 12-month pregnancy rates are similar.

Intrauterine Synechiae after Myomectomy; Laparotomy versus Laparoscopy

Zahra Asgari¹, Leili Hafizi², Rayhaneh Hosseini¹, Atiyeh Javaheri³, Hathis Rastad⁴

¹Department of Gynecologic Laparoscopy, Arash Women's Hospital, Faculty of Medicine, Tehran University of Medical Sciences, Tehran, Iran;

²Department of Obstetrics and Gynecology, Imam Reza Hospital, Faculty of Medicine, Mashhad University of Medical Sciences, Mashhad, Iran;

³Department of Obstetrics and Gynecology, Faculty of Medicine, Shahid Sadoughi Hospital, Shahid Sadoughi University of Medical Sciences, Yazd, Iran;

⁴Research Development Center, Arash Women's Hospital, Faculty of Medicine, Tehran University of Medical Sciences, Tehran, Iran

Corresponding author:

Leili Hafizi,
Ebnesina Street, Imam Reza Hospital,
Department of Obstetrics and
Gynecology, Faculty of Medicine,
Mashhad University of Medical Sciences,
Mashhad, Iran

Tel: +98 513 8022608

Fax: +98513 8525305

Email: hafizil@mums.ac.ir

Abstract

Background: Leiomyomata is the most frequent gynecological neoplasm. One of the major complications of myomectomy is intrauterine adhesion (synechiae).

Objective: To evaluate and compare the rate and severity of synechiae formation after myomectomy by laparotomy and laparoscopy.

Methods: In this non-randomized interventional trial, hysteroscopy was performed in all married fertile women who had undergone myomectomy (type 3-6 interamural and subserosal fibroids) via laparotomy and laparoscopy in Tehran's Arash Hospital from 2010 to 2013. Three months after the operation, the occurrence rate and severity of intrauterine synechiae, and its relationship with type, number and location of myomas were investigated and compared in both groups.

Results: Forty patients (19 laparoscopy and 21 laparotomy cases) were studied. Both groups were similar regarding the size, type (subserosal or intramural), number and location of myoma. The occurrence rate of synechiae in the laparoscopy and laparotomy group was 21% and 19%, respectively; showing no significant difference ($P=0.99$). Among all patients, no significant relationship was found between the endometrial opening ($P=0.92$), location ($P=0.14$) and type of myoma ($P=0.08$) with the occurrence rate of synechiae. However, a significant relationship was observed between myoma's size ($P=0.01$) and the location of the largest myoma with the occurrence of synechiae ($P=0.02$).

Conclusion: With favorable suturing methods, the outcome of intrauterine synechiae formation after myomectomy, either performed by laparotomy or laparoscopy, is similar. In all cases of myomectomy in reproductive-aged women, postoperative hysteroscopy is highly recommended to better screen intrauterine synechiae.

Prospect of Endovascular Surgery: Kissing Stent, a Novel Approach for Aortoiliac Occlusive Disease

M. H. Modagheh, J. Jalili

Abstract

Background: In the recent past there were limited indications for endovascular interventions. However, with improvements in technology, it began to expand widely, such that nowadays a great deal of surgical operations are done in this way. It also provides a new solution for some vascular diseases that were assumed untreatable in the past, such as vascular malformations and below the knee vascular obstructions. As there is little surgical risk in endovascular surgery for patients and since there is the possibility of open surgery for failures, there is a trend to treat vascular obstructions which are in TASCII C and D groups, and it has interesting clinical results. There is also a trend to treat bilateral aortoiliac obstructive disease via the endovascular approach.

Methods: We reviewed the early and midterm results of kissing stent technique for infrarenal aortoiliac obstructive disease retrospectively. From April 2014 to March 2015, we performed nine consecutive aortoiliac stentings for obstructive disease. We compared clinical exam and ABI before and after stenting.

Results: All patients were in the TASCII D group. Three patients had critical limb ischemia and the remaining complained of severe claudication. In five of the nine patients there were no femoral pulses bilaterally before intervention. The range of ABI was from 0.2 to 0.96 before intervention and from 0.41 to 1.0 after the intervention. In all of the patients except one, we had a good distal pulse in the extremities after the intervention. The access was from brachial artery in one patient and from common femoral artery in the others. There was a significant improvement in the quality of life of the patients after intervention. From technical view there was no thrombosis or significant restenosis at the early postoperative follow up visit. In all of the interventions the procedure was done successfully and there was no technical failure.

Conclusion: The kissing stent technique is a safe approach for infrarenal aortic obstructive disease and provides satisfactory results. There was no increase in complications, which makes it an alternative for aortoiliac or aortic bifurcation bypass surgery.

Vascular and Endovascular Surgery
Research Center, Emam Reza Hospital,
Mashhad University of Medical Sciences,
Mashhad, Iran

Laparoscopic Proctectomy in Rectal Cancer with Prolapse Technique: Our Experience in 40 Patients

Abbas Abdollahi¹, Alireza Tavasoli²,
Ali Jangjoo¹, Reza Roshan Ravan²

¹Surgical Oncology Research Center,
Mashhad University of Medical Sciences,
Mashhad, Iran;

²Endoscopic and Minimally Invasive
Surgery Research Center, Mashhad
University of Medical Sciences,
Mashhad, Iran

Abstract

Background: Laparoscopic resection of rectal cancer is identical to open surgery regarding the safe margin of resection and lymph node dissection. This technique requires protective ostomy. This study aimed to evaluate results of laparoscopic proctectomy in patients using the prolapse technique.

Methods: Forty patients who underwent laparoscopic proctectomy during the year 2014 were included in the study. Transanal rectal excision and prolapse technique were performed in this procedure. This procedure does not require protective ostomy.

Results: The operative time was 160-210 minutes. Failure of coloanal anastomosis occurred in 13 patients which were managed with relaparoscopy (four patients) or laparotomy (one patient) and ostomy (13 patients). Early or late obstruction was observed in three patients who each required relaparoscopy (two patients) or laparotomy (one patient). One patient with excessive bleeding was laparoscopically re-operated. We had no perioperative mortality.

Conclusion: Laparoscopic proctectomy with prolapse technique can be a good procedure necessitating no protective ostomy. Further prospective studies are required to evaluate surgical result of prolapse technique.

Ergonomic Steps for TLH and SLH in Benign Gynecological Surgery

L. Mettler

Abstract

In gynaecologic endoscopic surgery, endoscopic hysterectomies have been performed since 1990. It has reached an acceptable success rate (with single port entry, multiple port entry, or with robotic assistance) with few side effects.

Laparoscopic total hysterectomy (TLH) in benign cases consists of four steps:

1. Recognition of anatomy and separation of the uterus from the pelvic sidewall and from its vascular supply

2. Intrafascial dissection out of the vagina by conservation of pelvic fascial compartments, like sacro-uterine ligaments

Prevention of descent of pelvic floor and douglascele by fixation of the sacro-uterine ligaments to the vaginal stump

Vaginal extraction and closing of vagina by a continuous suture

In detail, the patient is prepared in the trendelenburg position and by vaginal access the uterine manipulator is placed. In addition, a transurethral pelvic catheter (Folley catheter) is situated. The arms of the patient are naturally fixed along the body to give the first and second surgeons optimal space for surgery. The first surgeon stands on the left-side of the patient and the second surgeon on the right-side. An assistant is sitting between the legs of the patient and can manipulate the uterus with the uterine manipulator. The operation starts by positioning the Verress Canula, which is later being replaced by a 10 mm optic trocar. After introducing the HDTV video optic, an exploration of the entire abdominal cavity, literally focussing on the minor pelvis, is performed. The bladder, rectum, pelvic vessels, and ureters are identified and demonstrated.

Department of Obstetrics & Gynecology,
Schleswig-Holstein University Hospitals,
Kiel, Germany

Laparoscopic Treatment of Common Bile Duct Stones in a Prospective Series of 560 patients; Technique Indications and Results

J.Ch. Berthou¹, B. Dron², Ph. Charbonneau¹, K. Moussalier², L. Pellissier¹, F. Drouard²

Abstract

Background: The aim of this prospective study was to evaluate laparoscopic treatment of common bile duct stones (CBDS).

Methods: 560 patients who underwent a laparoscopic treatment of CBDS from October 1990 to December 2008 were all included in a prospective study. The mean age of the patients was 63 years (range 19-93). Among these, 461 patients were classified as ASA I and ASA II and 99 patients as ASA III and ASA IV. CBDS were suspected or diagnosed preoperatively in 361 patients (65%) and diagnosed at intraoperative cholangiography (IOC) in 199 patients (25%). A transcystic duct extraction (TCDE) was attempted in 282 patients (50.4%) and a primary choledochotomy in 278 patients (49.6%). Biliary drainage after choledochotomy was used in 162 cases (48.7%).

Results: TCDE was successful in 216 cases (77%). The failures (n=66) were managed in 56 cases by laparoscopic choledochotomy and in 10 cases by endoscopic sphincterotomy (ES). A choledochotomy was thus performed in 334 patients and was successful in 325 cases (97.3%). The 9 failures were managed by 6 conversions into laparotomy (2%) and 3 postoperative ES. The overall success rate of laparoscopic treatment was 96.2%. The morbidity rate was 8% with 5% of local complications and 3% of general complications. The mortality rate was 0.9%. There were 14 residual stones (2.5%) which were managed by a second laparoscopy in 1 case and by ES in 13 cases with 5 failures managed by laparotomy in 1 case and laparoscopy in 4 cases. Late complications (median follow-up of 10 years) occurred in 9 cases (1.4%).

Conclusion: Laparoscopic treatment of CBDS was effective in more than 96% of cases and particularly safe in ASA I and ASA II patients. It has an advantage over ES followed by laparoscopic cholecystectomy (LS) to be a one-stage procedure.

¹Clinique Chirurgicale Mutualiste, 56324 Lorient Cedex, France;

²Centre Hospitalier, Chirurgie Digestive, 02321 Saint-Quentin, France

The State of the Art in New Advanced Surgical Technology

Mehdi Asgari

Assistant Professor of General Surgery,
Ahvaz Jundishapur University of Medical
Sciences, Ahvaz, Iran

Abstract

According to the definition, art is an intellectual use of skill and ingenious thoughts. At first view, it seems that the usage of advanced technologies such as using stapler instead of hand anastomosis or using tools and materials which control bleeding including ligature and homeostatic materials ruins the artistic space of surgeon task in performing anastomosis, tying knots, dissection, and precise homeostasis. Therefore, the beauty of surgery has changed to some simple technical arts by using advanced instruments or technology.

However, in our point of view, although it seems that advanced technologies execution has briefed the preliminary motions and has shortened the procedure time, it has developed different levels of interaction in task, that the elements of skill and ingenuity haven't been eliminated. Accordingly, not only the need for reiteration and experience to gain skill has perfectly increased but also the surgeon must be well precise to identify the challenges and to perform the surgery safety.

Consequently the need for art in surgery has become more tangible and it is inevitable to generate an appropriate result at a new level.

Embolization of Vascular Lesions to Decrease Intraoperative Bleeding

Ali Reza Rasekhi

Abstract

Endovascular embolization can decrease bleeding at the time of surgery.

Sometimes the tumor cannot be resected or operated and embolization can play a therapeutic role specially in vascular lesions like AVM and aneurysms.

Embolization is performed by angiographic seldinger method. The catheter or microcatheter are guided to the tumor feeding vessels.

There are various types of embolic materials including particles (PVA, microspheres, and gelfome), liquid agents (glue, onyx) and coils. Each one has advantages and limitations.

Meningiomas, hemangiopericytoma, angiofibroma and paraganglioma are tumors in which embolization helps treatment. Complications are minor and self limiting like fever and pain.

Some complications are major like unwanted embolization, hemiparesis, blindness etc.

In conclusion, vascular lesions always have high risk of bleeding during surgery, but the degree of bleeding can be reduced by pre-op embolization.

Biopsy and FNA by Image Guide

Ali Reza Rasekhi

Abstract

Percutaneous needle biopsy has been the mainstay of oncologic diagnosis and can be applied for any part of the body. Still in some parts like the breast and brain, excisional biopsy is more appropriate.

Advantages of image guided biopsy over surgical excisional biopsy are:

- Low cost
- By local anesthesia
- Fewer complications

Localization will be performed by imaging like ct and sonography.

After prep and drape under local anesthesia the needle is advanced to the lesion and multiple samples are taken. The larger the needle the better the specimen - but more pain and higher complication rate is probable.

For fine needle aspiration 21 G needle is appropriate. To and fro is done in the lesion while aspirating by syringe and drawing on slides and sent to lab.

For biopsy the specimen is gone to lab in formalin.

Common sites for biopsy are adrenal gland, bone, liver, kidneys, thoracic, pancreas.... With high sensitivity and specificity.

In conclusion percutaneous image guided biopsy is a practical and easy way to diagnose type of tumors with low degree complications.

Biliary Interventions

H. Saberi

Abstract

Biliary strictures have a relatively wide spectrum of causes from benign to malignant. Endoscopic interventions, percutaneous interventions & surgery could be selected by multidisciplinary teams for the treatment of these patients.

Ultrasound, CT, MRI, ERCP & PTCD is used for diagnosis of type of stricture, localization and also staging of malignant causes.

In this lecture we discuss about image guided percutaneous methods like external biliary drainagr, high pressure balloons, and external-internal biliary drainage for benign biliary stenosis, as well as stenting and external-internal biliary drainage with brachytherapy for malignant causes like Klatskin tumors.

In the case of malignant causes the most cause is cholangiocarcinoma (Klatskin tumor) which most times is non-operable, but other tumors like adenocarcinoma of gallbladder, stomach... can invade extra or intrahepatic bile ducts directly.

We can perform the same protocol including external-internal biliary drainage and then brachytherapy for these tumors.

Sometimes metastatic lymphadenopathies in hillum of liver cause biliary stenosis due to compression of CBD. In these cases we only do biliary drainage or stenting for decreasing of bilirubin and let possibility of chemotherapy.

In benign causes, the most frequent cause is ligation or traumatization of CBD, CHD or RHD in open or laparoscopic cholecystectomy. Inevitable hepatojejunostomy or choledocojejunostomy are needed in these patients and the most frequent complication of this surgery is the narrowing of anastomosis and then rising of bilirubin & LFT.

Intervention of choice in these complications is PTC and ballooning. We have a study from 5 years ago with high pressure balloon, and more than 90% of patients are symptom free in this study.

Radiologist, Interventionist

A Review of Ethical and Jurisprudential Issues in Minimally Invasive Surgeries, and an Examination of a few Complaints & Defenses of Physicians within Courts of Law

Seyed Hossein Fattahi Masoom

Abstract

Background: Islam, as the last and most comprehensive divine religion, classifies the establishment of justice and equality among the people of society as an absolutely essential practice, and the formation of a judicial system with the aim of establishing justice is a prerequisite to that. In an Islamic Society, the conditions for judgment have been set out in such a way so that the lives, wealth, and families of people do not fall in the wrong hands, and that the individual and societal rights are not sacrificed for the demands and personal biases of corrupt people or groups who seek their own benefits. It is worth noting that Islam, more than anything else, invites people away from conflict and tensions, as Imam Ali (a.s.) says regarding this issue:

«إِيَّاكُمْ وَ الْمِرَاءَ وَ الْخُصُومَةَ فَإِنَّهُمَا يُمْرِضَانِ الْقُلُوبَ عَلَى الْإِخْوَانِ وَ يَنْبُتُ عَلَيْهِمَا النِّفَاقَ»

»Stay away from controversy and conflict, because conflict makes the hearts of brothers in religion diseased against each other, and grows the thorns of hypocrisy within them«.

The religion of Islam also finds necessary the existence of qualified and competent judges in order to resolve individual and societal problems. Imam Ali (a.s.) says in this regard:

«خَيْرُ النَّاسِ قِضَاءُ الْحَقِّ»

“The best of people are those who judge fairly”.

The Medical Council was established in the Islamic Republic and given certain powers by the law makers such that it became the official center for the analysis and responsiveness to the violations within the medical community. This is one of the most important and fundamental issues in society and requires righteous and competent people within the district courts, tribunal committees, the appeal courts, and higher courts so that they can rightfully defend both the rights of the people and the rights of the medical community. Now we briefly discuss some legal and judicial issues related to the subject of the congress.

1. The relationship between the doctor and the judicial authority is in 3 ways:

a) Expert b) witness c) defendant

2. Crime (criminal intent and verb intent) has been proposed in three ways within the law:

a) Intentional b) quasi-intentional c) pure error

3. Types of medical malpractice from the legal viewpoint.

a) Carelessness b) neglectfulness c) lack of skills (material or spiritual) d) lack of observance of state laws

“**Carelessness**”: the physician, surgeon or others have taken

Professor of Mashhad University of
Medical Sciences, former Attorney
General of Mashhad Medical Council
Court, Mashhad, Iran

certain measures where, due to their carelessness and lack of focus, they have made a mistake which has resulted in damage to the patient (they have done things which shouldn't have been done).

“Neglectfulness”: The doctor has neglected to take measures which in regards to the patient and illness, are classified as accepted and critical measures, meaning they have not done things which they should have done.

“Lack of skills”: In legal terminology means the lack of knowledge regarding the scientific and technical fundamentals and details of a specific work, and/or the lack of the required information regarding a specific profession.

- Spiritual: the doctor does not have the education, knowledge or expertise required.

- Material: The doctor does not have the required physical strength, agility and dexterity required.

In general, lack of skills means doing something which the person spiritually or physically is incompetent for.

“Lack of observance of state laws”: This includes the law and regulations of the Medical Council, and the guidelines of the Ministry of Health and Medical Education, and the resolutions of educational and treatment centers, and any sort of law, statute, regulation, resolution or instructions which are from the legislatures or competent authorities in medical matters.

Authorized centers which address medical malpractice:

- a) Judicial authorities (Ministry of Justice, State Coroner)
- b) Medical council (Disciplinary and professional authorities)

But the main discussion of this article is about how to prevent medical violations and malpractices.

Prevention: The possibility of the production of conditions which lead to the patient filing a complaint exist at each of the following stages:

1. Reception
2. Diagnosis
3. Treatment
4. Follow Up

The three main causes of the dissatisfaction of the patient with the physician or surgeon, which therefore results in complaints, are:

1. Failure of the doctor to establish the correct relationship with the patient.

2. Failure to achieve the desired outcome, or achieving unexpected or undesired outcomes.

3. Real malpractice which includes one of: carelessness, neglectfulness, lack of skill and lack of observance of state laws.

Other causes for complaints, which are less probable than the above are:

High costs and the expensiveness of the equipment for minimally invasive surgery, taking measures which were not required, lack of the required truthfulness in dealing with the patient and not gaining their trust, inappropriate treatment of medical staff and agitating other doctors.

An important question to the physician or surgeon is that

what ethical duty do you have towards the patient at the time of occurrence of a medical malpractice?

If you commit a medical malpractice, do you inform the patient of the issue or not?

You know that patients and the society look towards doctors, especially surgeons, trustfully, and in order to safeguard their health and achieve well being, they place their body and life in the hands of the doctor, and reveal confidential secrets to them which they would never reveal to even the most closest of friends and family. The medical community, through honesty in words and actions, is responsible for and committed to preserve and elevate this trust. And any damage to this trust has been and will be itself a source of complaints.

God Willing, presented during the congress are: The answers to questions and detailed explanations of the above issues, as well as 14 cases of complaints against doctors who have performed minimally invasive surgeries, which 9 are related to gall bladder surgery, 3 related to women's surgery, 1 related to gastric surgery (gastric binding), and one related to renal surgery.

Conclusion: In order to prevent medical malpractice, a proper relationship with the patient based on scientific, ethical and legal principles is the key to success.

A Retrovesical Approach for Laparoscopic Repair of Vesicouterine Fistula

Alireza Aminsharifi

Department of Urology, Laparoscopy
Research Center , Shiraz University of
Medical Sciences, Shiraz, Iran

Abstract

Background: To report our initial experience with laparoscopic repair of vesicouterine fistula (VUF), a rare but troublesome complication of caesarean delivery. This minimally invasive procedure obviates the need for another open surgery. We used a retrovesical approach to minimize the manipulation of the bladder.

Methods: During the study period 2 patients with a prior history of multiple caesarean deliveries were found to have VUF confirmed by cystography and cystoscopy. The fistula was repaired in both patients with transperitoneal laparoscopy via a retrovesical approach. An omental flap was interposed between the bladder and uterus.

Results: Operative times were 160 min in one woman and 180 min in the other. Excellent laparoscopic visualization and magnification together with the presence of a catheter in the fistula tract allowed meticulous dissection in the retrovesical space between the bladder and uterus, and resection of the fistula tract with minimal manipulation of the bladder without the need for a large cystotomy. Postoperative cystogram at 4 weeks showed complete resolution of VUF in both patients. There was no recurrence of fistula and the patients had no lower urinary tract symptoms during the follow-up period.

Conclusion: Laparoscopic repair of VUF with a retrovesical approach is an effective technique with a successful outcome. This approach provides excellent exposure to a poorly exposed area of the retrovesical space. Whether laparoscopy can be considered a method of choice for managing VUF has yet to be proven. Longer follow-up periods are needed to evaluate the likelihood of recurrence with this technique.

A Review of 1057 Patients with Endometriosis in a Six Year Period

Saeed Alborzi, Azam Hosseini
Nohadani, Madihe Amini

Shiraz University of Medical Sciences,
Shiraz, Iran

Abstract

Background: Endometriosis is one of the most common gynecologic diseases, with high incidence of non-gynecologic organ involvement. Our unit was the referral center for patients with endometriosis in Iran, with facilities for the diagnosis and management of this disease.

Methods: In this study we evaluated 1057 patients with endometriosis in a six years period that underwent operative laparoscopy for evaluation of different stage of endometriosis. The main symptoms were pain and or infertility. Patients were evaluated for endometrioma and deep infiltrative endometriosis (DIE). Regarding DIEs, different anatomic locations were evaluated and treated.

Results: The mean of patients' age was 31.16 (15-53) years. 752 (71.14%) of patients had endometrioma and 804 (76.06%) of patients had DIE. Unilateral endometrioma was more common than bilateral (64.23% vs. 35.77%) and the incidence was more on the left side (56.94% vs 45.06%). The most common site of DIEs was the uterosacral ligaments (42.35%). Incidence of GI involvement was 11.65% and urinary tract involvement was 7.49%. Patients' improvement was more 90 %, especially with pain symptoms. The incidence of a major complication was 0.28%.

Conclusion: Operative laparoscopy is very effective in treatment of advance endometriosis especially in those with pain symptoms, with low incidence of complication in experienced hands.

Transgastric Laparoscopic Surgery

Alireza Tavassoli¹, Abbas Abdollahi²

¹Endoscopic and Minimally Invasive Surgery Research Center, Ghaem Hospital, Faculty of Medicine, Mashhad University of Medical Sciences, Mashhad, Iran;

²Surgical Oncology Research Center, Imam Reza Hospital, Faculty of Medicine, Mashhad University of Medical Sciences, Mashhad, Iran

Abstract

The development of laparoscopic surgery has suggested new technical procedures for the treatment of several pathologies. Transgastric surgery is a laparoscopic procedure used to treat gastric lesions such as polyps and carcinoma in situ. We achieved successful results with this procedure in five cases. There were no intra- and postoperative complications. The technique reproduces that used in conventional surgery but with a transgastric approach and the advantages of minimally invasive surgery are maintained. This laparoscopic approach may be considered as an alternative strategy for surgical treatment of benign tumors of the stomach. For all patients, there was no recurrence during the follow-up period (up to 2 years). The important points of this approach are confirmation of the location of the tumor by both gastroendoscopy and laparoscopy, proper selection of the trocar site for insertion of the instruments, and secure grasping and lifting of the gastric wall, including the tumor. We conclude that this procedure is technically feasible, safe, and useful for benign lesions and nonepithelial gastric tumors.

Laparoscopic Rectal Surgery: Challenges and New Techniques

Mohammad Reza Kalbassi

Abstract

Laparoscopic rectal surgery has revolutionized rectal cancer surgery with better views and increasing accuracy in dissection. Total mesorectal excision (TME) has been the gold standard for rectal cancer surgery. Multidisciplinary team meetings (MDT) and the use of CT and MRI scans have lead to detailed staging of cancers and correct decision to either proceed to surgery or neoadjuvant treatment.

Challenges are quality of surgery, quality of TME, correct treatment decision at the time of MDT, polyp cancers, sphincter saving surgery, postoperative function, stapling the rectum below the cancer in low rectal cancer and Laparoscopic rectal surgery training. New techniques such as TAMIS have reduced risk of positive margins due to difficult stapling. It also allows for better a operative specimen which is important for oncology.

More recently units around the world are working on Robotic assisted rectal surgery which increases the accuracy of dissection. Unfortunately, there is a steep learning curve and the operation set up takes time adding to overall duration of the operation.

Minimal Invasive Surgery–Complications

Guedes Schiappa

Abstract

As in any other type of Surgery – or medical treatment – complications may arise in Minimally Invasive Surgery.

Besides, all surgeons can be faced, during their practice with such problems. It is necessary, during training and formal surgical education, to understand why these problems may happen and, by doing so, realising that some measures can be taken in order to prevent, or at least, to minimise, such events.

During this presentation, all this points are approached, and examples are given on complications; in an interactive way, there will be discussion with the audience, regarding these examples and finding out solutions for the problems presented.

Systematically, the examples are seen, carefully, comments from the audience are evaluated, and tips on surgical acting to avoid it are also discussed and shown.

How to Manage Bile Leak after Laparoscopic Hydatid Cyst Resection

Mohammad Eidy

Minimally Invasive and Bariatric Surgeon,
Kashan University of Medical Science,
Kashan, Iran

Abstract

The gold standard treatment for hydatid disease is surgery and it can be done by different techniques, either open or laparoscopic.

One of the major problems in this operation is that, these cysts could be connected with biliary tree and consequently it could cause bile leakage if not manage correctly.

For reducing this problem, initially, after cystic drainage by the standard technique, we look up, the cystic cavity with 30-degree camera and then use a white sponge to find the bile stain. If we find the leakage during the operation, we close it with suture. At the end of the operation, we use Foley drain and keep it in place for some days. If we do not have leakage, we extract it, but if we see leakage, this is what we would like to discuss it in this lecture.

Types and Prevention of the Biliary Duct Injuries

Hossein Saeidi Motahar

Abstract

Biliary injury is the most common severe complication of cholecystectomy. It is always morbid, increases cost, and often leads to litigation. Injury may occur during laparoscopic cholecystectomy, planned open cholecystectomy, or after conversion from laparoscopic to open cholecystectomy. Injury rates have decreased from the levels encountered in the early 1990s. However, injury rates are probably still higher than those in the era of open cholecystectomy, although accurate data are unavailable. The causes of injury are increasingly better understood, and improvements in strategies for preventing injury have occurred. When injury occurs, a high rate of permanent cure is possible using advanced techniques of reconstruction in specialized centers. ERCP is a very valuable tool in the diagnosis and treatment of bile duct injuries. Recently, MRCP emerged as a valuable diagnostic tool. The treatment and outcome of biliary injuries vary considerably and are dependent on the type of injury, its location, and the time of its diagnosis.

There are different types of bile duct injuries; the anatomic classification of Bismuth has been adopted widely for the classification of biliary tract injuries. In the Bismuth classification, five stricture types are recognized that reflect the location with respect to the confluence of the hepatic duct (types I-IV) or the involvement of an aberrant right sectorial hepatic duct with or without a concomitant hepatic duct stricture (type V).

This classification was later further broadened by Strasberg et al. Injuries are classified as type A to type E. Type A injuries are bile leaks from minor ducts that are still in continuity with the CBD. Type B injuries involve occlusion of part of the biliary tree. Type C injuries occur when the duct is transected without ligation. Type D injuries are lateral to an extra hepatic bile duct, which is similar to a type A injury in that the extra hepatic biliary tree remains in continuity, but is classified separately to underscore the greater severity and potential need for major reconstruction. Type E injuries are biliary strictures and are further subdivided into 5 categories, E₁ to E₅, which are based on the Bismuth classification.

Laparoscopic Surgeon, Iran University of
Medical Sciences, Tehran, Iran

Laparoscopic Gastric Plication

Mohammad Talebpour

Prof of Tehran University of Medical
Sciences, Sina Hospital, Tehran, Iran

Abstract

Laparoscopic gastric plication (LGP) is a new restrictive bariatric surgery with 14 years experience in the world introduced by the author.

“Standard steps of LGP” has mentioned to facilitate its training. The main strategy in LGP is to preserve physiology and anatomy of the body. Decrease of the gastric volume by inversion of greater curvature into the stomach (Gastric plication) up to 50 cc is a safe, cost benefit, physiologic and conservative method. Postoperative hospital stay, cost and acceptance of patients is with meaningful difference to other methods. Protein mapping after LGP has shown dramatic change in level of different proteins including Ghrelin, saying hormonal effect after LGP as well.

Long term follow up of patients show acceptable results in compare to others: 60% EWL after 6 months and 75% after 12 months. 15% regain after 4 years and 35% after 10 years. The efficacy of restrictive effect of LGP like other restrictive methods is about 4 years and prevention of regain is mainly based on change of life style by the patient. The plan of regain surgery in this group can include replication (or sleeve) and gastric bypass safely. Plication in regain cases is loose and possibility to do each bariatric surgery is practical due to enough tissue at lesser curvature.

Postoperative complications after LGP is less than 1% (11/1400 cases) including leakage, obstruction and emboli.

LGP is the best restrictive method in obesity class 2 and is acceptable method in class 3.

Two important blind prospective clinical studies comparing LGP to sleeve and gastric bypass have been carried out in Sina Hospital with comparable results.

Post Operative Leakage in Bariatric Surgery

Majid Sadat Mansouri

Abstract

One of the most serious complications after bariatric surgery is anastomosis leakage. It is an abdominal catastrophe in morbidly obese patients and has a high rate of mortality. Surgical leakage may occur in early post operative surgery or late or intermediate. In subclinical cases, anastomotic leak may be local, without spillage and dissemination to abdominal cavity. Whereas in clinical type, great diffuse of GI contents in abdominal cavity has happened. The most common leakage in bariatric surgery is seen in sleeve gastrectomy at the angle of the Hiss.

Diabetes, HTN, sleep apnea, impaired healing in immunodeficient patients, and ages of more than 55 years are risk factors of leakage at stapling line.

Clinical presentations are variant from asymptomatic radiographic findings to diffused peritonitis. The earliest symptom is tachycardia and other signs and symptoms consist of fever, tachypnea, abdominal or retrosternal chest pain, nausea and vomiting.

Diagnosis is based on radiologic assessment, abdominopelvic CT Scan, and endoscopy.

Early diagnosis and treatment is emphasizezely important to worst-case scenario. The treatment is based on emergent exploration, irrigation with good drainage and feeding enterostomy in obvious leakage cases with diffused peritonitis. In local or suspicious leakage, CT guided percutaneous drainage may be treated successfully. In nonsurgical management, adequate laparoscopic drainage and suitable nutrition and antibiotics, high doze PPI, endoscopic stenting or clipping and finally remedy of any stenosis or stricture are considered.

General Surgeon & Laparoscopist

Sacral Nerve Stimulation for the Treatment of Anorectal Dysfunctions

Klaus E. Matzel

Abstract

Sacral nerve stimulation (SNS) aims to recruit residual function of an insufficient organ system by electrostimulation of its peripheral nerve supply, i.e. the sacral spinal nerves. Since its first application for fecal incontinence in 1994, the techniques and spectrum of indication have evolved remarkably. SNS has become a minimally invasive and low morbidity technique with broad clinical use. The surgical technique is two-staged; patients are uniformly selected for operative implantation of a permanent neurostimulation device based on clinical improvement during test stimulation. In this stage, percutaneous nerve evaluation (PNE) is used to confirm a satisfactory nerve response and then to evaluate the clinical effect of stimulation. This therapeutic trial stimulation is performed for a time-period, sufficient to prove its therapeutic effect; commonly considered if the symptom improvement documented by bowel-habit diary is alleviated by at least 50%. If successful, the second stage is the implantation of a permanent electrode positioned close to the sacral spinal nerve and subcutaneously placed pulse generator.

The test-stimulation is highly predictive of the outcome of permanent stimulation. Thus, a pragmatic, trial and error approach is evolved for patient selection. Test stimulation is indicated, not by an underlying physiologic condition, but by the existence of an anal sphincter with reduced or absent voluntary squeeze function and existing reflex activity.

Today, SNS is effective in various conditions leading to fecal incontinence. Its therapeutic effect has been repeatedly proven. Success, defined as an improvement of symptoms of at least 50%, ranges around 75%; around 50% of the patients gain full continence. The clinical effect is maintained over a follow-up of more than 10 years. The symptomatic benefit in FI results in a significant improvement of life quality.

Clinical observations prompted the use of SNS in patients with constipation unresponsive to conservative treatment. In constipation, SNS can result in a symptom improvement such as increase of bowel emptying, decrease of the need to strain for bowel emptying, and reduced need for digitation. These changes have a beneficial effect on the quality of life. Experience with this new indication for SNS is limited, however, the relevance of selecting patients for SNS on the basis of their response to trial stimulation has repeatedly been demonstrated, as has a persistent reduction in symptoms of constipation with chronic low frequency SNS.

New indications for SNS are evolving, such as its application in irritable bowel syndrome and ulcerative colitis.

The understanding of the mechanism of action is growing. Physiological changes appear not to be limited to the bowel and

Section Coloproctology Department of
Surgery, University Erlangen, Erlangen,
Germany

anal sphincters. Changes in the central nervous system have been observed. The complex findings of clinical and physiological studies indicate that the effect is likely based on multiple physiologic functions, that various neural pathways are involved, and that these can be modified by SNS. As the underlying causes for anorectal dysfunction are manifold and often heterogeneous, it must be hypothesized that SNS may work in different ways depending on the underlying pathophysiological condition.

The future challenges would be to improve our understanding of SNS in current and novel indications, its role in the treatment algorithm of the various anorectal dysfunctions, and its underlying mechanism of action.

The Quality of Life after Roux-en-y Gastric Bypass Surgery

Sina Safamanesh, B. Mohammad Ali Pour

Abstract

Background: Morbid obesity and its comorbidities have a negative effect on the quality of life, and a good reason that leads patients to bariatric surgery. However, the quality of life after bariatric surgery is not always as expected by patients. The aim of this study is to compare four aspects of life quality, before and after laparoscopic Roux-en-y gastric bypass in morbidly obese patients.

Methods: 85 morbid obese patients treated by Roux-en-y gastric bypass surgery. The average BMI was about 45 and the average age was 34 years. Fifteen patients had one or two comorbidities and the quality of life was assessed before the surgery and about two years (1.3-3) after surgery. We compared the physical activity, self-esteem, social problems, and working problems. We used the impact of weight on the quality of life questionnaire (IWQOL) to assess the quality of life and compared the scaling before and after the surgery.

Results: Average excess weight loss was about 68%. The physical activity score, self-esteem, and social problems scores improved significantly ($P < 0.001$), however, there were no significant changes in working problems.

Conclusion: It seems that bariatric surgery can improve the quality of life in a short time period after surgery, but it needs more follow up.

Minimal Invasive Surgery: Complications

Guedes Schiappa

Abstract

As in any other type of surgery or medical treatment, complications may arise in minimally invasive surgery.

Besides, all surgeons can face such problems during their practice. Therefore, it is necessary, during training and formal surgical education, to understand why these problems may occur and to realize that some measures can be taken in order to prevent, or at least, to minimize such events.

During this presentation, all these items are addressed and examples are given on complications in an interactive way. There will be a discussion with the audience, regarding these examples to explore solutions for the presented problems.

Systematically, the examples are presented, comments from the audience are carefully evaluated, and tips on surgical action to avoid such issues are discussed and shown.

Incisional Hernia Repair Using an Open Sublay Approach with Retromuscular Mesh Placement

Jean-Luc Bouillot, Tigran Poghosyan,
David Moszkowicz, Karina
Vychnevskaja

Abstract

Background: Incisional hernia (IH) which occurs about 5-25% after laparotomy is a serious complication that can endanger the health of patients and have a significant negative socio-economic impact on their lives. Their repair still remains a major challenge for surgeons.

The aim of this study was to evaluate the outcomes of midline and lateral IH repair by a retromuscular standardized procedure.

Methods: From June 2000 to December 2014, 982 patients were operated for ventral hernia by the same surgical team and culled prospectively. In order to have a long follow-up, we limited the study period from 2000 to 2007. During this period, 322 retromuscular mesh repair (RMR) were performed: 261 for midline IH and 61 for lateral IH.

Results: There was no postoperative mortality. Overall, early morbidity, including medical and surgical complications was observed in 45 patients (14%). The mesh was removed for early infection in 2 patients (0.6%). The most significant factor in terms of operative time, hospital stay, and early complication rate was the size of the abdominal wall defect. The average follow-up was 58 months (± 36). The overall recurrence rate was 3.4% (n=11). No significant difference was found in terms of recurrence between the different types and sizes of IH. A significant difference in terms of recurrence was found between sepsis group versus non-sepsis group: (100% vs 2.3%; P=0.001).

Conclusion: The RMR for IH is a safe treatment with low recurrence rate even in large IH wider than 10 cm. Prosthetic infections remain the main factor for hernia recurrence. Absolute respect of asepsis is a cardinal in the incorporation of prosthetic material. The EHS ventral hernia classification appears to be very useful to classify and compare different ventral incisional hernias and for preoperative detection of subgroups having a higher postoperative morbidity rate in the aim of optimizing their perioperative care.

Ambroise Paré Hospital,
AP-HP, Boulogne-Billancourt and
Université de Versailles St-Quentin-en-
Yvelines, France

Exercise and Bariatric Surgery

Seyed Vahid Mojab

Specialist Sport Medicine, Assistant
Professor of Shiraz University of Medical
Sciences, Shiraz, Iran

Abstract

All the authorities of health affairs are aware of obesity as a souvenir of modern society and its importance as a health risk.

Non invasive surgery could be regarded as a lifesaving strategy, if it is accompanied simultaneously by a change in lifestyle and then surgery. This transformation is based on three fundamental bases including nutrition, exercise and psychological problem. However, physicians, especially surgeons' unfamiliarity with the proper way of prescribing scientific exercise, often leads to similar and non-normative recommendations to obese patients after surgery.

In this case, the intervention of a specialist in sport medicine is necessary. In the present paper, through the latest scientific achievements in the world and experiences gained in the clinic, we tried to provide an appropriate training for a scientific exercise prescription to be recommended to patients.

Complications of Ureteroscopy and TUL

Mohammad Mehdi Hosseini

Abstract

Ureteroscopy is a relatively complication-free procedure. However, if complications do occur they may be related to the anesthesia or the procedure itself, which may be catastrophic.

1. Anesthesia complications:

Spinal anesthesia - Headache, low blood pressure, infections, like meningitis. However these are rare and unusual complications.

- General anesthesia - Reaction to drug, nausea and vomiting, drowsiness, throat or chest infections.

2. Procedural complications:

- Difficulty in entering the ureter – Occasionally, due to swelling or stenosis of the ureteric orifice. In such a case usually a stent is left and the procedure is tried after a few days to weeks.

Stone migration into the kidney – stone may run up into the kidney. In such an event ESWL is required to break the stone.

Small mucosal tear of the wall of the ureter – This is usually a minor problem.

Small perforation of the wall of the ureter – This may occur when the stone is either sharp or stuck in one location. In most situations a temporary stent can tide over the problem. A major perforation may require surgical repair or re-implant of the ureter.

Avulsion of the ureter – this is a major complication and requires exploration and replacement of the ureter with part of intestine or autotransplantation.

- Stricture of the ureter – In long – term follow up, some patients may develop a narrowing of the ureter. This may be related to the stone or due to the use of the ureteroscope or due to thermal injury caused by a laser probe.

Endourology Division of Urology
Department, Shiraz University of Medical
Sciences, Shiraz, Iran

Robotic Camera Real Time Controller for Minimally Invasive Surgery

Alireza Moravej¹, Fatemeh Katibeh¹,
Hamid Reza Foroutan²

¹Medical Robotics Group, Robotics
Interdisciplinary Association, Shiraz
University, Shiraz, Iran;

²Laparoscopy Research Center, Shiraz
University of Medical Sciences, Shira,
Iran

Abstract

Background: Since 1902 after the first laparoscopic procedure, this approach has become a good method of choice for many types of surgeries. Also in 1985 for the first time robots can get positions in the operating rooms with the PUMA 560. □ Nowadays, after many experiences in using robots in surgeries we can trust them and use robotic devices commercially in many parts of surgeries.

Methods: In all traditional laparoscopic surgeries we should make some incisions for injecting graspers and other similar instruments, in addition to making at least one incision for injecting the camera into the patient's body. In general methods, we have to have an assistant for holding the camera and to control it with his hands, meaning that the surgeon can't control the camera directly. But in our method we want to solve this problem robotically. We designed a robotic arm for controlling the camera with detecting and capturing surgeon movements. We can set this robot beside the operating room's bed and fix it above the field of surgery. Eyes movements' detection, joystick control and speech recognition methods are our choices for controlling the robot directly by the surgeon.

Results: Real time decision making and real time movement tracking help us to sync camera movements with surgeons. Additionally, by using this camera controller we can improve the quality and speed of the operations.

Overview of Results of Bariatric Surgery in Shiraz

Alimohammad Banzadeh¹, Leila Ghahramani², Seyed Vahid Hosseini²

¹Laparoscopy Research Center, Shiraz University of Medical Sciences, Shiraz, Iran;

²Colorectal Research Center, Shiraz University of Medical Sciences, Shiraz, Iran

Abstract

Background: Laparoscopic sleeve gastrectomy (LSG) is gaining acceptance among bariatric surgeons as an option for the management of morbidly obese patients. We describe results of a single center's experience with LSG.

Methods: LSG was performed in 732 consecutive patients from August 2008 to December 2014. A technique is described where all operations were performed with attention to avoiding strictures at the incisura angularis and stapling close to the esophagus at the angle of His. A retrospective chart review was conducted to determine the occurrence of complications.

Results: A total complication rate of 3 % was observed. The most common complications were leakage and bleeding. There were 11 cases (1.5%) with leak and 7 cases (1%) with bleeding. The mortality rate was 1% (4 patients).

Conclusion: The LSG is a safe method, and the results of our practice are the same as other centers.

TAPP Laparoscopic Hernia Repair without Mesh Fixation; Introduction of a New Method in a Prospective Randomized Trial

Behrooz Keleidari, Mohsen
Mahmoudieh, Gholamreza Mohajeri,
Masoud Sayadi Shahraki, Amir Masood
Rafie Manzelat, Kimia Ghaderi

Abstract

Background: Mesh fixation is a critical step in Transabdominal Preperitoneal (TAPP) laparoscopic hernia repair because Tacker Mesh Fixation (TMF) used for this purpose is associated with possible neuralgia and chronic groin pain (CGP) and other complications; otherwise, a few trials supported TMF as a method to decline hernia recurrence. Since TMF is still controversial, the aim of this study was to analysis the rate of recurrence, chronic groin pain, and postoperative complications among patients undergoing two different methods of Laparoscopic Inguinal Hernia Repair (LIHR), namely TMF and no-mesh fixation (NMF)
Methods: Among 120 individuals undergoing LIHR during January 2012 and July 2014, two groups of 20 patients were randomized from each method of LIHR (i.e. TMF and NMF). These patients were interviewed about CGP in 10/10 scale, hernia recurrence, and complications after surgery. The results were analyzed by SPSS software version-20.

Results: The most frequent complication in both groups was chronic pain. Patients in NMF group had less complain of chronic pain in contrast to TMF group ($P=0.045$). However, in comparison with other complications, including infection, urogenital side effect and anesthesia, there were no significant differences ($P=0.289$). Furthermore, the risk of hernia recurrence was the same ($P=2.111$).

Conclusion: TMF in TAPP laparoscopic hernia repair has increased the incidence of chronic pain in patients undergoing this procedure. However, NMF not only does not increase the recurrence rate of hernia, but also it has less chronic pain ratio. According to these results, NMF may be preferred as a safer technique for the treatment of inguinal hernia.

Keywords • Inguinal Hernia • Hernia Repair • Laparoscopic Surgery • Neuralgia • Seroma

Department of Surgery, School of
Medicine, Isfahan University of Medical
Sciences, Isfahan, Iran

Diet-induced Dyslipidemia Improved by Saffron Petals in Obese Rats

Reyhane Hoshyar¹, Zabihollah
Mohaghegh², Mahdiyeh Hosseini¹,
Zahra Amini³, Sara Jamali¹

¹Department of Biochemistry, Faculty of
Medicine, Birjand University of Medical
Sciences, Birjand, Iran;

²Department of Medical Lab Technology,
Birjand University of Medical Sciences,
Birjand, Iran;

³Department of Biochemistry, Payame
Noor University, Mashhad, Iran

Abstract

Background: Obesity is becoming a major public health issue; being a risk factor for diabetes mellitus, cardiovascular disease, and osteoarthritis. Herbs such as saffron containing biologically active compounds have shown antioxidant, anti-inflammatory, and dyslipidemia-improving properties. The aim of the present study was to evaluate the protective effects of saffron petals on dyslipidemia induced by high fat diet in obese rats.

Methods: In this study, 25 male Wistar albino rats were purchased from the animal house of Birjand University of Medical Sciences (five rats per each cage). One group received normal food and the others received high fat diet (100 grams normal food, 100 grams sugar, and 200 grams corn oil) for 8 weeks. Then, two groups of rats were gavaged with saffron petals (40 and 80 mg/kg) daily for 3 weeks. At the end of the study, blood samples from the rats' heart were collected in sterile vial without anticoagulant for serum separation. Sera samples were analyzed for biochemical parameters such as total cholesterol (TC), total triglyceride (TG), low-density lipoprotein (LDL), high-density lipoprotein (HDL) using standard commercial kits.

Results: The serum levels of TC, TG, and LDL-C significantly increased while the serum levels of HDL-C decreased in obese rats. After treating obese rats by saffron petals (80 mg/kg), TC, TG, and LDL-C decreased (95 ± 12 , 105 ± 11 , 32 ± 1.6 respectively) and HDL-C increased (63 ± 1.9) close to the normal levels.

Conclusion: Our results illustrated that saffron petals modulated serum TC, TG, LDL, and HDL levels in high-fat diet-induced obesity. The petals with 80 mg/kg dose showed a higher effective impact on lipid profile. In conclusion, saffron might be considered as a novel therapy for obesity.

Keywords • Obesity • Saffron • Dyslipidemia • Rat

Laparoscopic Gastric Plication in Morbidly Obese Adolescents: A Prospective Study

Reza Heidari, Atefeh Zeinoddini,
Mohammad Talebpour

Laparoscopic ward, Sina Hospital,
Tehran University of Medical Sciences,
Tehran, Iran

Abstract

Background: The prevalence of obesity has increased rapidly among adolescents. Bariatric surgery is associated with significant weight loss and improvement in obesity related co-morbidities, but may be associated with serious complications. Therefore, attempts at finding a safe and effective bariatric procedure for adolescents are ongoing. The objective of this study was to evaluate the safety and efficacy of Laparoscopic Gastric Plication (LGP) on adolescents.

Methods: A prospective study was performed on adolescents who underwent LGP from 2007 to 2013. Measured parameters included the percentage of excess weight (%EWL), percentage of body mass index loss (%BMIL), obesity related co-morbidities, operative time, and the length of hospitalization and complications.

Results: LGP was performed in 12 adolescents (9 female and 3 male). Mean (SD) age of the patients was 13.8 ± 1 year. Mean preoperative weight and BMI were 112.4 ± 19.7 kg and 46.0 ± 4 kg/m², respectively. Mean (SD) %EWL and %BMIL after two years were $68.2 \pm 9.9\%$ and $79.0 \pm 9.0\%$, respectively. All medical co-morbidities were improved after LGP. There were no deaths. One patient required replication 4 days postoperatively due to obstruction at the site of the last knot. No other major complications were observed. No patient required rehospitalization.

Conclusion: LGP has the potential of being an ideal weight loss surgery for adolescents, resulting in excellent weight loss and minimal psychological disruption. It is associated with a minimal risk of leakage, bleeding, and nutritional deficiency. However, large well-designed studies with long-term follow-up are needed.

Management of Complete Staghorn Renal Stone by Percutaneous Versus Laparoscopic Versus Open Surgery: A Comparative Analysis of Clinical Efficacy and Intermediate-Term Functional Outcome

Alireza Aminsharifi^{1,2}, Dariush Irani¹, Mansour Masoumi¹, Bahman Goshtasbi¹, Reza Mohammadian¹

¹Department of Urology, Shiraz University of Medical Sciences, Shiraz, Iran;

²Laparoscopy Research Center, Shiraz University of Medical Sciences, Shiraz, Iran

Abstract

Background: The main objective of the present study was to analyze the outcome of Percutaneous Nephrolithotomy (PCNL), laparoscopic and open Anatomic Nephrolithotomy (AN) for the management of patients with complete staghorn renal stones.

Methods: We analyzed the perioperative parameters, overall treatment costs and the changes in the target renal function on technetium-99 dimercaptosuccinic acid scintigraphy (99Tc-DMSA) renal scan. This was carried out before the operation and at the last follow-up visit, in 30 adults who underwent PCNL (n=11) versus laparoscopic (n=10) versus open AN (n=9) for complete staghorn renal stones.

Results: All three groups had statistically similar preoperative characteristics, including target renal function on 99Tc-DMSA renal scan. On the discharge day, the PCNL group had the lowest stone-free rate (36.4%) compared with the laparoscopic (80%) and open AN groups (88.9%) (P=0.039). After a mean follow up period of 12 months, the decrease in the target renal function was greatest in the open AN group (-8.8±6.3) compared with the laparoscopic AN (-7.5±6.6) and PCNL group (-2.9±2.4) (P=0.04). The need for ancillary procedures to manage residual stones was greatest in the PCNL group and lowest in the open AN group. A similar trend was seen in overall treatment costs (P=0.001).

Conclusion: For the management of complete staghorn renal stones, the more invasive the procedure is, the higher the one-session stone-free rate and the lower the need for ancillary procedures; however, greater renal functional loss can be anticipated. The need for ancillary procedures is a major determining factor in the overall cost of treatment, which was highest in the PCNL group.

Keywords • Percutaneous nephrolithotomy • Laparoscopy • Nephrolithotomy • Anatomic nephrolithotomy • Staghorn renal stone

Laparoscopic Splenectomy Results from Al-Zahra Hospital, Isfahan

Mohsen Mahmoudieh, Behrooz Keleidari, Gholamreza Mohajeri, Masoud Sayadi Shahraki, Shadi Yousefvand, Faranak Baharami

Abstract

Background: Today, 25 years after the first laparoscopic splenectomy, this approach has become the method of choice in non-emergency conditions. This is despite the fact that the selection of appropriate candidates for this procedure, the method for spleen resection and removal from abdomen, post-operative complications, and the impact of this procedure on patients' costs is still a matter for discussion.

Methods: During 2012-2013, 27 patients who were candidates for splenectomy underwent laparoscopic splenectomy at Al-Zahra hospital. After adequate administration of general anesthesia, two 10-mm port for 30 degrees lens and two 5-mm ports for devices were inserted. Carbon dioxide insufflation commenced and splenectomy was done using cautery, harmonic or ligasure and large vessel ligated with clips or vascular stapler and the spleen was removed with endo-bag.

Results: There were 8 males and 19 females (15-77 years old). In most cases (70%), the reason for splenectomy was due to ITP, blood diseases (including thalassemia and hereditary spherocytosis) and lymphoproliferative diseases, respectively. In three cases (11%), conversion to open surgery was done and one patient died. In patients with spherocytosis, laparoscopic cholecystectomy was performed at the same time. After the surgery, three patients developed post-operative infection at the site of camera port; two patients had collection under the left diaphragm who were treated by percutaneous drainage; one patient with port site infection returned with hernia in this location that was repaired with surgery and one patient needed resurgery because of accessory spleen.

Conclusion: Laparoscopic splenectomy can be the method of choice in most cases of elective splenectomy.

Keywords • Laparoscopic splenectomy • Splenectomy

Department of Surgery, School of Medicine, Isfahan University of Medical Sciences, Isfahan, Iran

Complete Video-Assisted Thoracoscopic Surgery (VATS) for Thymoma with Pure Red Cell Aplasia (PRCA); A Case Report

Gholamreza Mohajeri¹, Masoud Sayadi Shahraki¹, Mohsen Mahmoudieh¹, Behrouz Keleidary¹, Noushin Afshar Moghaddam², Ebrahim Nourian¹

¹Department of Surgery, School of Medicine, Isfahan University of Medical Sciences, Isfahan, Iran;

²Department of Pathology, School of Medicine, Isfahan University of Medical Sciences, Isfahan, Iran

Abstract

Background: Although thymoma is the most common anterior mediastinal tumor, only 5% of thymoma cases develop pure red cell aplasia (PRCA).

Case Presentation: In this article, we report the case of a 59-year-old man with a large (10 cm diameter) anterior mediastinal mass and severe anemia, for which thymoma and pure red cell aplasia were demonstrated by histopathological and hematological examinations. Despite the large mass, a complete video-assisted thoracoscopic surgery (VATS) thymectomy and combinational medical therapy were successfully performed. Aplasia remission occurred six months after thymectomy and his hemoglobin level reached to 13 g/dL.

Conclusion: We believe that a complete resection in combination with medical therapy is necessary to achieve total remission of PRCA symptoms. It is concluded that VATS thymectomy is an effective and technically feasible procedure for surgery without any contraindications about the size of the thymoma in such patients.

Keywords • Thymoma • Pure red cell aplasia • VATS thymectomy

Laparoscopic Myomectomy, New Technique for Myometrial Closure

Hossein Asefjah

Abstract

Uterine leiomyomata (UL), also known as fibroids, are benign tumors of the uterus and the leading cause of hysterectomy in the United States, accounting for \$1.2 billion in hospital expenditures annually. Most women develop myomas during their lifetimes; however, 80% are asymptomatic. When symptoms are determined to be caused by myomas, a number of management options exist that include “watchful waiting”, medical therapy, surgery, or more recently uterine artery embolization and focused ultrasound. Uterine myoma is a common gynecologic disorder occurring in 20% to 50% of women of late reproductive age, when the preservation of fertility is the primary concern. The first lesson physicians must learn is that if the patient is asymptomatic, no treatment is necessary. The presence of an abdominal mass is not an indication for hysterectomy or myomectomy unless it is of significant concern to the patient.

Symptoms vary in severity and include pelvic pain, abnormal menstrual bleeding, and pregnancy complications. The etiology of UL is poorly understood. Increasing incidence of diagnosed UL during reproductive years and decreased incidence with menopause, suggest the role of sex steroid hormones. Recently, laparoscopic myomectomy has been advocated because of its small operative wound, short hospital stay, quicker recovery, and outcome comparable to traditional laparotomy.

Myomectomy, either abdominal or laparoscopic, is an approach particularly suited for those women who wish future fertility. It seems clear that, in well-trained and experienced hands, well-selected patients can have myomectomy performed under laparoscopic direction. Very large myomas are not that suitable for the laparoscopic approach, but laparoscopic myomectomy up to 20 cm has been reported in the literature, which solely depends on surgeon’s ability. There are no universally accepted criteria regarding the number and size of myoma to be removed laparoscopically. However, as our techniques, especially suturing techniques and instruments for laparoscopy advances, our ability to do more complicated laparoscopic myomectomy cases also increases. Before laparoscopic myomectomy uterine mapping is mandatory, because the surgeon does not have a sense of palpation during the procedure, in order to have successful laparoscopic myomectomy the surgeon should answer the following questions before surgery:

- How many myomas are there?
- Where are the exact locations of myomas?
- How is the distance of myoma from cavity?
- Is uterine cavity distorted?
- Are we able to perform the operation?

Laparoscopic myomectomy is a challenging procedure and the most challenging part of this procedure is suturing. The goal of suturing is to restore myometrial integrity, prevent hematoma formation, prevention of defect and dehiscence in myometrium and adhesion prevention. If any one of these goals were not met during the procedure, the future pregnancy would be in danger. The skill of a surgeon is the most important factor for a successful operation.

In a video clip, the new technique for myometrial closure will be displayed.

Obstetrician and Gynecologist

Minimally Invasive Surgical Interventions in the Treatment of Primary Persistent Hyperinsulinemic Hypoglycemia of Infancy

Mohammadreza Abdolhosseini,
Fahimeh Soheilipour, Abdolreza
Pazouki

Minimally Invasive Surgery Research
Center, Iran University of Medical
Sciences, Tehran, Iran

Abstract

Hyperinsulinemia, diagnosed by laboratory tests, should be diagnosed and treated as soon as possible to prevent fatal complications, such as neurologic damages. The patients who are resistant to medical therapy should be treated surgically. Minimally invasive surgery, a newly developed approach in surgery, is a good choice among the surgical procedures to avoid unnecessary extensive pancreatectomy.

Here, we present a 12-year-old boy with a diagnosis of hyperinsulinemic hypoglycemia who had recurrent attacks of hypoglycemia and seizure from infancy. Because of his unresponsiveness to medical therapy and his family's preference, he underwent laparoscopic pancreatectomy in an extent of less than near total. Postsurgical follow up after one year revealed normoglycemic state.

Prevalence of Constipation in Morbid Obese Patients before and after Bariatric Surgery

Abdolreza Pazouki, Sara Akbarnejad,
Mohadeseh Pishgahroudsari,
Somayyeh Mokhber, Fatemeh Jesmi,
Mohsen Masoodi

Minimally Invasive Surgery Research
Center, Iran University of Medical
Sciences, Tehran, Iran

Abstract

Background: The prevalence of obesity is increasing in the developed and developing countries. Surgical approach is the only effective choice for morbid obese patients to achieve their optimal weight. Overweight and obesity, aside from other factors, affect functional defecation disorders, such as constipation. As far as few studies have evaluated the effect of bariatric surgery on patients' constipation, we have designed this study to address this important issue.

Methods: During this analytic cross sectional study, 250 morbid obese patients, candidates for bariatric surgery (Roux-en-Y gastric bypass (RYGB), mini-gastric bypass (MGB), and sleeve gastrectomy) at Rasool Akram Hospital during 2012-2014, were enrolled in our study. Wexner questionnaire was filled by all patients before and 6 months after surgery to evaluate constipation. Data including sex, age, level of education, BMI, past medical history, previous anorectal surgery and obstetric history were collected.

Results: Among the 250 patients enrolled in this study, 109 patients (43.6%) underwent MGB, 128 (51.2%) RYGB, and 13 (5.2%) sleeve gastrectomy. Mean value of BMI was 46.4 before the surgery, which was reduced to 37.8 after the surgery ($P<0.001$). Prior to the study, 104 patients had constipation, which was reduced to 51 patients 6-month after surgery ($P<0.001$).

Conclusion: The present study showed that bariatric surgery reduces the frequency of constipation and improves the quality of life in morbid obese patients.

Keywords • Constipation • Bariatric surgery • Morbid obesity

Laparoscopic Proctectomy in Rectal Cancer with Prolapse Technique: Our Experience in 40 Patients

Abbas Abdollahi¹, Alireza Tavasoli², Ali Jangjoo¹, Reza Roshan Ravan²

¹Surgical Oncology Research Center, Mashhad University of Medical Sciences, Mashhad, Iran;

²Endoscopic and Minimally Invasive Surgery Research Center, Mashhad University of Medical Sciences, Mashhad, Iran

Abstract

Background: Laparoscopic resection of rectal cancer is identical to open surgery regarding the safe margin of resection and lymph node dissection. This technique requires protective ostomy. This study aimed to evaluate the results of laparoscopic proctectomy in patients with prolapse technique.

Methods: Forty patients who underwent laparoscopic proctectomy during 2014 were included in the study. Transanal rectal excision and prolapse technique were performed during this procedure. This procedure does not require protective ostomy.

Results: The operative time was 160-210 minutes. Failure of coloanal anastomosis occurred in 13 patients, which were managed with relaparoscopy (4 patients) or laparotomy (1 patient) and ostomy (13 patients). The early or late obstruction was observed in three patients each required relaparoscopy (2 patients) or laparotomy (1 patient). One patient with excessive bleeding was laparoscopically reoperated. We had no perioperative mortality.

Conclusion: Laparoscopic proctectomy with prolapse technique can be a good procedure necessitating no protective ostomy. Further prospective studies are required to evaluate the surgical result of prolapse technique.

Keywords • Rectal cancer • Prolapse technique • Laparoscopic proctectomy

Treatment of Esophageal Achalasia with Laparoscopic Heller Myotomy and Dor Fundoplication: Prospective Evaluation of 30 Consecutive Patients

Gholamreza Mohajeri¹, Mohsen Mahmoudieh², Behrouz Keleidari², Masoud Sayadi Shahraki², Shahab Shahabi³

¹Thoracic Surgeon, Fellowship of Minimally Invasive Surgery, Isfahan University of Medical Sciences and Health Services, Isfahan, Iran;

²General Surgeon, Fellowship of Minimally Invasive and Obesity Surgery, Isfahan University of Medical Sciences and Health Services, Isfahan, Iran;

³Resident of General Surgery, Isfahan University of Medical Sciences and Health Services, Isfahan, Iran

Abstract

Background: Prospective studies evaluating the outcome of laparoscopic Heller myotomy and Dor fundoplication for esophageal achalasia are lacking among the Asian people. The aim of this study was to evaluate the results with laparoscopic cardiomyotomy and partial fundoplication for achalasia.

Methods: Thirty patients who underwent Heller myotomy for achalasia, via laparoscopy in Alzahra Hospital (Isfahan, Iran) during 2009-2013 were recorded prospectively. Median follow-up was 18 months. Symptom including dysphagia, regurgitation, chest pain, and weight loss were recorded before and after operation. In addition, previous treatment for achalasia such as endoscopic pneumatic dilatations and intrasphincteric injection of botulinum toxin or other component, duration of symptoms as well as duration and complication of operation was recorded.

Results: Among 30 patients, there were 13 (43.3%) females and 17 (57.7%) males, and the mean age was 40.8 years (range: 20-68). The operation was completed laparoscopically in all patients, with a median operative duration of 135 minutes. In the last ten patients, the operating time ranged from 105 to 145 minutes. Mean operative duration was 137±36.2 minutes. Additionally, difficulties in dissection were encountered in patients who had a history of ethanolamine or botulinum toxin injection.

The median duration of symptoms was 30 months before being referred for surgery. Mean hospital stay was 2.45 days. At a median follow-up of 18 months, dysphagia was alleviated in all except for two patients (93.4%), and regurgitation in all patients ($P<0.001$). Chest pain and heartburn improved significantly ($P<0.01$) as well. Two (6.6%) patients had residual dysphagia but not sever as before surgery.

The mucosa in two (6.6%) patients was perforated on the gastric end of the myotomy. The perforations were repaired laparoscopically without postoperative leak.

Conclusion: Our study showed that laparoscopic Heller myotomy with Dor fundoplication results in significant relief of dysphagia. Overall, clinical symptoms indicate improvement in patient functional status during the 18-month follow-up.

Keywords • Esophageal achalasia • Laparoscopic myotomy • Dor fundoplication

Bariatric Surgery in Mental Retard Patients; a Case Report

Somayyeh Mokhber, Abdolreza Pazouki, Zeinab Tamannaie

Abstract

Mental retardation (MR) is characterized by low intelligence or mental activity. Because of insufficient compliance for diet and exercise therapy in MR patients, the optimal treatment for morbid obesity in MR patients remains controversial.

Although bariatric surgery is contraindicated for MR, this operation will change the quality of life of such patients and improve their health.

We report on two morbid obese patients suffering from MR, who referred for bariatric surgery to our center, both with good familial support.

The first case was a married 43-year-old woman, mother of three children, with mild MR with body mass index (BMI) of 63.8 kg/m², sleep apnea and hyperlipidemia, who underwent laparoscopic Roux-en-Y Gastric Bypass. After 24 months, she lost 37.4 kg and her sleep apnea and hyperlipidemia were resolved.

The second case was a 16-year-old boy with moderate to severe MR and BMI of 49.8 kg/m² nonalcoholic steatohepatitis (NASH) and hyperlipidemia before surgery. He underwent laparoscopic sleeve gastrectomy. After 27 months, his weight dropped to 91.9, which was 88% of his excessive weight loss. His comorbidities (NASH and hyperlipidemia) were also resolved.

As no major complication was observed in both cases, although MR is the contraindication of bariatric surgery, more studies need to be done to assess the quality of life of MR patients after bariatric surgery, which may change the view on this subject.

Keywords • Mental retardation • Intellectual disability • Obesity • Bariatric surgery

Minimally Invasive Surgery Research Center, Iran University of Medical Sciences, Tehran, Iran

Comparison of Traditional Laparoscopic Roux–en–Y Gastric Bypass versus Laparoscopic Mini Gastric Bypass on Resolution of Diabetes (type II) in Morbid Obese Patients

Peyman Alibeigi, Abdolreza Pazouki, Ommolbanin Abed, Mohammadreza Abdolhosseini, Ali Kabir, Fatemeh Jesmi, Leila Janani, Sajedeh Riazi

Minimally Invasive Surgery Research Center, Iran University of Medical Sciences, Tehran, Iran

Abstract

Background: Obesity and diabetes type II are one of the most common diseases in the developed and developing countries. Weight loss procedures are the main treatment for morbid obesity and related comorbidities like diabetes. Roux-en-Y gastric bypass is the gold standard treatment of morbid obesity. Laparoscopic mini-gastric bypass has been introduced since 1997 and considered as effective as laparoscopic RYGB in the treatment of morbid obesity and its comorbidities. However, it is technically a safer and less challenging procedure, especially in obese patients with diabetes.

Methods: All diabetic obese patients, aged between 16- and 60-year-old, referring to Hazrat Rasul Akram obesity clinic from April 2010 to March 2013, who underwent two methods of bariatric surgery RYGB or LMGB, were included. Preoperative parameters measured, including glycosylated hemoglobin (HbA1c), fasting plasma glucose (FPG), body mass index (BMI), and diabetes medication were extracted from the database and recorded. Preoperative and postoperative data were compared 3-month after the procedure.

Results: Out of 95 patients, 50 patients in the LMGB group and 45 patients in the LRYGB group were included. The groups were similar in gender, mean age, weight, BMI, and FPG, however, the mean of HbA1C was relatively higher in the LRYGB group. The rate of complete resolution was significantly higher in the LMGB group than the LRYGB group after 3-month follow-up (64.0% vs. 31.1 %, respectively).

Conclusion: Regarding the comparable results of standard LRYGB to LMGB in this survey, the authors suggest considering the LMGB as an effective bariatric surgery in obese diabetic patients.

Keywords • Gastric bypass • Roux-en-Y • Diabetes mellitus • Type 2

Increased CA-125 Serum Level Predict Severity of Ovarian Endometrioma and DIE Nearly the Same

Khadijeh Shadjoo, Arash Mohazzab,
Roya Padmehr, Parvin Jaberi-Pour,
Roxana Kargar, Azam-Sadat Mahdavi

Reproductive Immunology Research
Center, Avicenna Research Institute,
ACECR, Tehran, Iran;
Endometriosis and Pelvic Pain Clinic,
Avicenna Infertility Clinic, Avicenna
Research Institute, ACECR, Tehran, Iran

Abstract

Background: This study was carried out to compare CA-125 level between ovarian endometrioma (OMA) and deep infiltrative endometriosis (DIE).

Methods: In a cross-sectional study performed in Avicenna endometriosis clinic during 2012-2014, 254 patients were included in the survey. All patients underwent laparoscopic surgery and diagnosis was confirmed by pathology. CA-125 serum level was measured preoperatively by electrochemiluminescence. The normal cutoff value of CA-125 was 35 unit/ml. Patients were categorized by endometriosis involvement (+,-) and the type of the disease (OMA and DIE). rASRM endometriosis score and its component were considered as severity of each type of lesions. Statistical analysis was done by χ^2 test, independent sample t-test and bivariate correlation using SPSS software version 18.

Results: From 183 patients diagnosed as endometriosis, 110 patients (60.1%) were involved by both DIE and OMA, 38 patients (20.7%) by OMA, and 35 patients (19.1%) by DIE. 71 patients were categorized in non-endometriosis groups. χ^2 test showed a significant statistical relationship of CA-125 with endometriosis, DIE and OMA ($P < 0.001$). Sensitivity, specificity, PPV and NPV of CA-125 were 53.5, 71.42, 74.5, and 50.3 for the diagnosis of DIE and 60.4, 83.1, 85.2, 56.4 for OMA, respectively. Independent sample t-test showed significant statistical difference between OMA(+) and OMA(-) patients (77.75 ± 106.68 vs. 23.17 ± 26.7 , $P < 0.001$) and also between DIE(+) and DIE(-) patients (69.79 ± 103.61 vs. 36.77 ± 55.75 , $P = 0.006$). Significant Pearson correlation coefficients were calculated as; $R = 0.472$ between CA-125 and DIE component of rASRM in DIE only group and $R = 0.523$ between CA-125 and OMA components of rASRM in OMA.

Conclusion: Regarding specificity and sensitivity of CA-125 test for the diagnosis of OMA and DIE and their correlation coefficients, it seems that CA-125 test predicted OMA slightly better than DIE.

Keywords • Ca-125 • Deep infiltrating endometriosis • Endometrioma • Endometriosis

Flexible Ureteroscopy with Holmium Laser Lithotripsy Versus Extracorporeal Shockwave Lithotripsy (ESWL) in the Treatment of Upper Ureteral Stones

Sadrollah Mehrabi

Abstract

Background: Our goal in this study was to compare the efficacy and complications of transurethral lithotripsy (TUL) with Holmium laser versus extracorporeal shockwave lithotripsy (ESWL) in the treatment of upper ureteral stones.

Methods: Patients with upper ureteral stones with sizes of 5-15 mm that were referred to Shahid Beheshti hospital of Yasuj and were candidates for Lithotripsy, after taking informed consent and the approval of the ethics committee, were randomly assigned in two groups.

In the first group ESWL was done in the supine position with Dornier Delta 2 machine with ultrasound shockwaves by standard methods. After lithotripsy, patients were observed for two hours and patient's satisfaction was checked by Beck scale. Then, in absence of any complications, patients were discharged with medication order and outpatient follow up.

In the second group, after anesthesia by standard methods, patients were situated in the lithotomy position and lithotripsy was done with flexible ureteroscopy and Holmium laser with fluoroscopic guidance by standard methods.

After operation, patients were admitted and the next day in absence of any complications they discharged with medication and outpatient follow up. In both groups, patients visited again two weeks later and KUB with ultrasonography was performed in order to assess the efficacy and complications of the operations and the data was recorded.

Results: In this study the mean age of women was 45.25 ± 14.5 years and 43.7 ± 15.5 in men,

meaning there was no difference between them. The mean size of stone in women was 10.95 ± 3.7 mm 9.44 ± 2.8 in men, with again no difference between them.

Regarding efficacy and complications there was no significant difference between the two groups.

Conclusion: The efficiency and complications of transurethral lithotripsy (TUL) with Holmium laser versus ESWL has no significant difference and this modality can be used as a safe and efficient option in the treatment of upper ureteral stones.

Keywords • Ureteral stone • Treatment • ESWL • TUL

Department of Urology, Yasuj University
of Medical Sciences, Yasuj, Iran

Laparoscopic Radical Nephrectomy in Treatment of Renal Cell Carcinoma: A Single Center Experience

M. Aslzare, M. Darabi Mahboub, A. Asadpour, J. Sadidi, A. Ghoreifi

Abstract

Background: Laparoscopic radical nephrectomy in recent years has been widely used for treatment of non metastatic renal tumors. The advantages of this method compared to classic open surgery in treatment of kidney tumors have been discussed in the literature. The aim of this study was to evaluate the results of our referral center experience in laparoscopic radical nephrectomy.

Methods: We retrospectively evaluated the data from patients with primary diagnosis of non metastatic renal cell carcinoma (according to their imaging studies) who underwent laparoscopic radical nephrectomy in Ghaem Academic Hospital from April 2010 to March 2014. All patients underwent laparoscopy with lateral trans-peritoneal method by the same surgeon. Duration of surgery, intra-operative and post-operative amount of bleeding, blood transfusion requirement, duration of hospitalization and the need for analgesics have been checked and analyzed and then compared with the results of classic open radical nephrectomy which has been reported in the literature.

Results: Among the total of 112 patients (mean age 50.9 years), tumors have been located on the right side in 66 patients (58.9%) and on the left side in 46 (41.07%). The mean duration of surgery was 109.4 minutes (min 90 and max 160) and was the same in both sides. The patients were 77 males and 35 females and duration of surgery was the same in both sexes. The average tumor size was 6.5 cm (min 3.5 and max 11.5) and there was a direct relationship between duration of surgery and the tumor size. Average blood loss was 58.8 mL and peri-operative requirement for transfusion of packed cells was seen in 16 patients (14.28%). The mean use of post-operative analgesics was 1.7 times (max: 4) and the mean duration of hospitalization was 60±20 hours (range 36-120).

Conclusion: Our results showed that although the overall operation time is longer in laparoscopic radical nephrectomy, the amount of blood loss, duration of hospital stay and need for analgesics are less compared with open radical nephrectomy. Therefore, laparoscopic radical nephrectomy can be used as a safe and feasible treatment for patients with localized renal cell carcinoma.

Keywords • Laparoscopy • Nephrectomy • Kidney neoplasms • Surgery

Department of Urology, Mashhad
University of Medical Sciences,
Mashhad, Iran

Percutaneous Nephrolithotomy (PCNL) in the Pediatric Age Group

Mohammad Mehdi Hosseini¹, Alireza Aminsharifi^{1,2}, Dariush Irani¹, Abdo-Reza Haghpanah^{1,2}, Alireza Yousefi³, Reza Inaloo³, Mohammad Zaki-Abassi⁴

¹Endourology Unit, Department of Urology, Shiraz University of Medical Sciences, Shiraz, Iran;

²Laparoscopy Research Center, Shiraz University of Medical Sciences, Shiraz, Iran;

³Department of Urology, Jahrom University of Medical Sciences, Jahrom, Iran;

⁴Department of Urology, Boushehr University of Medical Sciences, Boushehr, Iran

Abstract

Background: Nowadays, Renal calculi are a common problem in children. Extracorporeal shock wave lithotripsy (ESWL) is the first choice in this age group, but sometimes other interventions may be indicated. In such cases PCNL seems a less invasive and more safe option than open surgery. We evaluated the results and complications of the pediatric PCNL in our referral training center.

Methods: Between September 2002 and December 2014, 167 children underwent PCNL. The procedure was done under general anesthesia, in prone position, with ureteral catheter 3 or 4 F, diluted contrast injection and fluoroscopic or ultrasound guided nephrostomy by Chiba needle 18G. Tract dilation performed with Alken telescopic dilators. Nephroscopy were done with adult size 24 Fr nephroscopes in 85, pediatric in 48 and semirigid ureteroscope in 34 cases. Lithotripsy was done with pneumatic lithoclast and saline solution used as irrigation. Nephrostomy tube was inserted in 35 with ureteral stent, tubeless (No nephrostomy) in 113 and totally tubeless in 29. Ureteral stent and Foley catheter were removed 12-24 hours after operation.

Results: Of a total 167 patients with renal stone >20mm, 96 were boys and 71 were girls, with a mean age of 8.5 years (9 months-15 years). The mean operation time was 75 minutes (40-105) and mean radiation time was 0.6 minutes (0.3-1.9). Five patients had residual fragments less than 5mm which were passed spontaneously 2 weeks after operation. 7 patients underwent second look nephroscopy, and 3 underwent ureteroscopy for migrated stone fragments to distal ureter. Postoperatively, 19 patients developed fever, 2 had sepsis, 7 underwent transfusion, and 5 had a rising of normal creatinine which improved with conservative management.

Conclusion: PCNL seems a good option for treatment of nephrolithiasis in children.

Thoracoscopic Resection of Anterior Mediastinal Masses

Gholamreza Mohajeri; Mohsen Mahmoudieh; Behrooz Koleydari; Masoud Sayadi

Abstract

Background: Thoracoscopic resection plays an increasing role in anterior mediastinal mass. A variety of tumors may occur in this compartment in which thymoma is the most common tumor. A successful surgery heavily depends on the size of the tumor and without spread into the surrounding tissue.

Methods: 17 patients with anterior mediastinal mass underwent thoracoscopic resection during 2009-2013 at Al-Zahra Hospital (Isfahan, Iran). The surgery was performed on the same side as the tumor was leaning toward. Under general anesthesia with double-lumen tube in partial lateral positions, one 10-mm port for 30 degrees lens and two 5-mm ports for devices were laid in upside down triangle formation. Dissection was performed under CO₂ gas pressure at 8-10 mmHg and with the aid of hook and sometime harmonic such that the whole tumor and thymus resect were removed after placement in endo-bag. For the removal of tumor, one 5-mm port was increased to 10-mm.

Results: There were 11 male and 6 female patients with the mean age of 43.9 (22-73) and symptoms duration of 1-12 months. The patients were presented with myasthenia gravis, chest pain, cough, or breathlessness. Tumor sizes were between 2cm to 10 cm. In one myasthenic patient, without thymoma diagnosis prior to the operation, the surgical approach was bilateral thoracoscopy; however, for all other patients it was one-sided. Total operating time was 70 to 150 minutes. Only two cases of major bleeding occurred in a thymic vein branch that was controlled by a clip or suture. In a case of a 14-cm thymoma, due to the invasion of the lung and pericardium, open surgery was adopted right at the beginning of the operation. Significant morbidity or mortality did not occur.

For the last 12 patients chest tube was not used, 6 patients were directly transferred to the ward and other patients spent 1-2 night at ICU and were then transferred to the ward for 1-2 nights. According to the pathology report, there were 13 thymoma cases, where two cases were benign teratoma and one case was thymic cyst. One patient, after chemotherapy, had a malignant germ cell tumor in which there was no residue after resection. Among thymoma cases, type B₁ (n=4) and B₂ (n=5) had the largest number of individuals.

Conclusion: Thoracoscopic resection of anterior non-invasive mediastinal masses could be performed safely and successfully.

Department of Surgery, Isfahan University of Medical Sciences, Isfahan, Iran

Thoracoscopic Congenital Diaphragmatic Hernia repair in neonate: The First Experience of Iranian Group

Mehran Hiradfar, Reza Shojaeian,
Reza Nazarzadeh, Marjan Joodi,
Ghazaleh Azimzadeh Khosravi, Farnaz
Mirhosseini

Endoscopic & Minimally Invasive Surgery
Research Center, Ghaem Hospital,
Faculty of Medicine, Mashhad University
of Medical Sciences, Mashhad, Iran

Abstract

Background: Congenital diaphragmatic hernia (CDH) consists of a posterolateral defect of the diaphragm, generally located on the left side (85-90%) that allows passage of the abdominal viscera into the thorax. The first successful repair of CDH returns to 1905 by Heidenhain. Until 1995, the standard method for treatment of CDH was performed by open surgery through the abdomen or thoracic cavity. Minimally invasive approach via thoracoscopy or laparoscopy is applicable for treatment of CDH from 1995. Now, thoracoscopic repair of CDH (T'Scopy CDH) was performed in many centers. In this paper, we present the first experience of T'Scopy CDH repair from Iran.

Methods: from 2011 to January 2015, 74 patients with CDH were admitted to Pediatric Surgery Department of Dr. Sheikh (Sarvar) Pediatric Hospital. 21 patients (28%) met selection criteria and underwent T'Scopy CDH repair. The median age at the time of repair was 5 days (2-days-old to 4-years-old patients). Including criteria was weight over 2 kg and stable hemodynamic and arterial blood gas. 14 cases were intubated at the time of referring to operating room. In all cases, the defect was in the left side except in two. In 8 cases, we used thoracic wall as a part of repair. Also, mesh support was utilized in 8 cases even in those that we were able to perform primary repair of diaphragm for reinforcing the repair (5 cases). Of these 8 cases, in 3 patients, whole repair was accomplished by mesh due to large defect.

Results: The mean time of operation was 80 minutes (40-230 minutes). Intraoperative mortality was zero. In hospital, mortality occurred in two cases due to septicemia in one case, and hypercapnia, inability to stabilize the case and finally respiratory and cardiac failure in other one. Conversion to open surgery was required in 6 cases. In one case, simultaneous presence of sequestration was found. In-hospital, recurrence occurs in 2 cases that were managed by open surgery. Late recurrence was observed in 2 cases. The mean age of follow up was 14.6 months (3-36 months).

Conclusion: It seems that case selection and liberal use of thoracic wall as a part of repair and prosthetic use of mesh as a support of primary repair may cause better results and decreased chance of early and late recurrence.

Laparoscopic Hypertrophic Pyloric Stenosis

Mehran Hiradfar, Marjan Joodi,
Reza Shojaeian, Reza Nazarzadeh,
Ghazaleh Azimzadeh Khosravi, Farnaz
Mirhosseini

Endoscopic & Minimally Invasive Surgery
Research Center, Ghaem Hospital,
Faculty of Medicine, Mashhad University
of Medical Sciences, Mashhad, Iran

Abstract

Background: Hypertrophic Pyloric Stenosis (HPS) is a gastric outlet obstruction which characterized by thickening of the circular muscle of the pylorus. The prevalence of this condition is reported to be approximately three per 1000 live births. Boys are affected four times more often than girls and between the ages of 6 to 8 weeks.

Methods: In this review, we study 62 patients with HPS who referred to Dr. Sheikh (Sarvar) Pediatric Hospital from 2011 to 2015. Of these patients, in 19 cases we were able to accomplish the procedure completely by laparoscopic approach except in one case with incomplete myotomy who underwent open surgery 2 days later. So, the success rate of laparoscopic HPS is approximately 94%. The ratio of male to female was 15 to 4. The length of surgery was 30 minutes. The first open port was inserted five mm above the umbilicus. Two three mm stab wounds were made in right upper quadrant (RUQ) and midline of supra-umbilical. Gas insufflation started with 8 mmHg pressure and flow rate of 5 L/min. First, olive was exposed and its surface cauterized. Then, Ramstedt's pyloromyotomy was performed by specific laparoscopic grasper.

Results: The results show no perforation, mortality, morbidity and severe bleeding. Moreover, cosmetic result was excellent.

Comparison of Early Results and Complications in Multiport Sleeve Gastrectomy and Single Port Sleeve Gastrectomy

Ahmed Mohammed Ali Hussein
Al-Haery, Seyed Ali Hosseini, Hajar
Khazraei, Ali Reza Safarpour, Fahimeh
Haj Hosseini, Zinab Rahimi

Colorectal Research Center, Shiraz
University of Medical Sciences, Shiraz,
Iran

Abstract

Background: Laparoscopic sleeve gastrectomy (LSG) has taken the bariatric surgical scene by storm over the past 5 to 10 years. The purpose of this study is to compare the early results and complications between multiple sleeve gastrectomy (MPSG) and single port sleeve gastrectomy (SPSG).

Methods: In this study, obese patients medically indicated to LSG were divided into two groups. 50 patients were placed in group A and underwent SPSG, and 50 were placed in group B and underwent MPSG. BMI, gender, age, and length of hospital stay were measured. Intraoperative and early postoperative complications at one month and 6 months after surgery were recorded and evaluated. All surgeries were performed in Shahid Faghihi Hospital, Shiraz, Iran. The same medical team, in a standardized manner, performed all surgeries.

Results: In group A there were 5 males and 45 females and in group B there were 15 males and 35 females. The mean BMI in group A was 42.8 ± 0.7 and 45.3 ± 1.1 in group B. Mean of intraoperative blood volume loss in group A was 133.4 ± 38.3 cc and in group B was 208.7 ± 76.2 cc. Mean length of hospital stay in group A was 3.47 days and in group B was 3.8 days. Only one patient in group A had bleeding as an early complication and 5 patients in group B had bleeding. 3 patients in group A had leakage and one patient had obstruction after the surgery. There was not any significant difference between the two groups.

Conclusion: According to these results, multi-port sleeve gastrectomy seems to be safer and we believe that SPSG can be more feasible and safe if newer devices like spider system and endo eye laparoscopes are used.

Keywords • SPSG • MPSG • Bleeding • BMI

Oncology Result in Open versus Laparoscopic Right Hemicolectomy

Lila Ghahramani, Ahmad Izadpanah,
Ali Mohammad Bananzadeh, Ali Reza
Safarpour, Fateme Enjavi Amiri

Abstract

Background: The laparoscopic approach for colon cancer especial in right side has been accepted. However, tumor size, number of lymph nodes harvested, length of proximal and distal resection margins have remained a subject of debate in view of oncologic results.

Methods: 25 patients were included in this study between 2010 and 2015. Inclusion criteria were: Carcinoma of the ascending and hepatic flexure confirmed by pathologic reports, and elective surgery. Operations were performed by colorectal or laparoscopic surgeons. Exclusion criteria were: the need for emergency operation, CT finding revealed extra luminal involvement, previous colon surgery, IBD, FAP. Laparoscopy versus open right or extended right hemicolectomy was performed on the patients. In the laparoscopic method, material to lateral approach was done, with extracorporeal anastomosis.

Results: There were 10 female and 15 male patients included in this study. The mean age was 56.95. The maximum age was 84 year-old and the minimum age was 27-year-old. 10 patients underwent the open surgical approach and 13 underwent the laparoscopic approach. In 2 cases conversion was done. There was significant change in number of lymph node harvesting between the laparoscopic and open approach (16 versus 9, $P=0.02$). There was no significant change in staging of tumor in two groups.

Conclusion: Total meso colon excision in right or extended right hemicolectomy seems performed completely in laparoscopy more than open surgical. Therefore, laparoscopic approach would be effective in survive.

When, Where, How and by Who Laparoscopic Approach is Best Used in Management of Adnexal Mass?

Maliheh Arab¹, Zahra Honarvar²

¹Preventative Gynecology Research Center (PGRC), Shahid Beheshti University of Medical Sciences, Tehran, Iran;

²Department of Gyneco-Oncology, Kerman University of Medical Sciences, Kerman, Iran

Abstract

Background: This study is to response the main questions of when, where, how and who are best to manage adnexal masses. Base of the study is malignancy probability of the individual ovarian mass.

Methods: Ovarian malignancy probability score (OMPS1) with high sensitivity based on sonographic findings and OMPS2 with more specificity (based on OMPS1+ serum CA125 measurement) are used to plan a decision making algorithm.

Result: OMPS1 of less than 2.3 is operated on anywhere with any approach, preferably by laparoscopy. In score of more than 3.65, referral to tertiary hospital is recommended. Scores of 2.3-3.65 is individualized based on OMPS2 score.

Conclusion: when, where, how and by how laparoscopic approach is best used, is individualized by malignancy probability, surgeon competency and available setting.

Air Embolism during Operative Hysteroscopy for Severe Asherman's Syndrome

Behnaz Nouri

Department of Gynecology, Shahid
Beheshti University of Medical Sciences,
Tehran, Iran

Abstract

Introduction: Air embolism is an uncommon, but potentially catastrophic event that occurs as a consequence of the entry of air into the vasculature.

Gas embolism appears to occur frequently in patients undergoing operative hysteroscopy, but few patients experience clinically significant cardiac or pulmonary complications.

Case Report: A multiparous 27 year old patient with a history of severe Asherman's Syndrome underwent the operative hysteroscopy and laparoscopy contemporary.

About the end of surgery was found that the media was finished at least 60-70 seconds duration.

During laparoscopy air bubbles were seen in the Pmpeniform veins.

Air embolism resulted in cardiovascular collapse. Supportive cares were performed and the patient was discharged after 10 days.

Normal menstruation was restored, and the patient did not have any prominent sequels.

Conclusion: Air embolism may occur in patients undergoing operative hysteroscopy and results in a catastrophic event.

We must regard the preventive steps for gas embolism.

Keywords • Air embolism • Hysteroscopy

Comparison of Modified Open Entry versus Direct Disposable Trocar Entry in Laparoscopic Surgeries

Behnaz Nouri

Abstract

Background: The purpose of the study was comparison of safety, ease of use, and efficacy of modified open entry compared with direct disposable trocar entry in gynecologic laparoscopy (345 patients) and laparoscopic appendectomy, cholecystectomy, and hernioraphy (305 patients).

Methods: The design was Quasi experimental in the setting of two educational hospitals. 650 patients underwent different laparoscopic surgeries from 21st March 2007 – 21st July 2014. We used modified open entry [without Hasson trocar or MO] in 300 patients (46.3%) and direct disposable shielded trocar entry (DTI) in 350 patients (53.7%) all performed by one surgeon [the author]. The patients with previous abdominal surgeries have been included.

Results: The intra-operative complications were one major vascular injury [bifurcation of Aorta] (0.2%) with bowel injury in one patient (0.2%) occurred in direct trocar entry group versus 0% in the open group. The post-operative complications were two cases of port-site infection (0.6%) and a small trocar site hematoma occurred in the open entry group (0.3%).

The mean access times were 445.47 seconds (SD 160.584) in the open group, being significantly longer than 44.84 seconds (SD 67.527) observed in the direct entry group ($P < 0.0001$).

The mean abdominal pressure for the creation of the pneumoperitoneum was 15 mmHg in both groups. There were 2 entry failures in the DTI group.

Conclusion: Modified open entry reduces the risk of major vascular injury, but it has longer mean entry times than the direct entry method.

Department of Gynecology, Shahid
Beheshti University of Medical Sciences,
Tehran, Iran
Email: b.nouri1376@gmail.com

Different Method in Management of Fecal Incontinence

Neda Najibpour, Leila Ghahramani, Ali Reza Safarpour, Fateme Enjavi Amiri

Colorectal Research Center, Shiraz
University of Medical Sciences, Shiraz,
Iran

Abstract

Fecal incontinence is common, and though it may not be life threatening, it can cause morbidity. There have been several advances in the understanding and management of fecal incontinence in the past 10 years. Importantly, surgical correction is reserved for patients who have a mechanical disruption of the sphincter mechanism. Its use has therefore declined, having largely been replaced by neuromodulation in many centers, which includes stimulation of the sacral nerve (SNS) and tibial or pudendal nerves or the dorsal nerve of the clitoris. SNS is reserved for those who have failed conservative treatment.

Most surgeons are of the view that a patient with a cloacal injury or a defect in the sphincter ring of more than 90 degrees is better treated by an initial surgical repair. If this is unsuccessful, then sacromodulation is still available as a secondary treatment. Sacral nerve stimulations are unlikely to be beneficial in a patient with a complete spinal cord injury. Additional absolute contraindications include pregnancy, untreated pilonidal disease, and patients with severe immunodeficiency.

Seven patients from 2013 to 2015 underwent PNE that finally 4 patients had SNS implantation. In one patient, wound infection led to chronic discharge and the equipment was removed because of packing abscess formation. Each patient had an improvement of more than 80%.

Laparoscopic Resection of Extra-gastrointestinal Stromal Tumors (EGISTs)

Behnaz Nouri

Abstract

Background: Stromal or mesenchymal neoplasm affects the GI tract [1%]. They are most often located in the stomach and proximal small intestine but can occur in the omentum, mesentery and peritoneum.

Tumors lacking any association with the bowel wall have been referred to as EGISTs. A large gastrointestinal **stromal** tumor (GIST) [>10 cm] that is located extra-gastrointestinal is very rare.

Case Report: A 22 year old virgin patient, with history of sudden abdominal pain, who was referred from Lorestan.

Clinical Evaluation: A 5×5 cm cystic mass and 8×6 cm solid cystic mass in the midline part of the abdomen & CA125=49.

The patient underwent laparoscopic resection. We found a large solid cystic mass (18×15 cm) with extensive necrotic parts which had several adhesions to bowels; omentum; uterus and anterior abdominal wall. Extensive adhesions were released. The mass was sent to the frozen section, but the pathologist did not give a definitive diagnose.

After 1 month the definite diagnosis with immunohistologic and pathologic approaches was GIST.

Conclusion: Surgery is the definitive therapy. Laparoscopic resection is safe and effective.

Keywords • GISTS • Surgery • Laparoscopy

Department of Gynecology, Shahid
Beheshti University of Medical Sciences,
Tehran, Iran

Comparison of Anti-Müllerian Hormone Level in Non-Endometriotic Benign Ovarian Cyst before and after Laparoscopic Cystectomy

Sedigheh Amooee, Maryam Ghariblaki

Abstract

Background: Benign ovarian cysts are common among both pre- and postmenstrual women. Surgical intervention for excision of an ovarian cyst is mandated when it's symptomatic, or when the chance for malignancy is high. The damaging effect of surgical ovarian cystectomy on the ovarian reserve is debated in recent studies. In the present study we investigated serum level of anti-Müllerian hormone as an indicator of the ovarian reserve before and after surgical cystectomy.

Methods: In 60 women with 3 types of benign ovarian cysts, including dermoid cyst, serous cystadenoma and mucinous cystadenoma, who underwent surgical ovarian cystectomy, serum anti-Müllerian hormone was measured before the operation and in 1 and 3 month intervals after the operation.

Results: Serum anti-Müllerian hormone level declined significantly after the surgery which recovered to 65% of its baseline value 3 months later.

Conclusion: We detected significant decrease in serum AMH after ovarian cystectomy in all cases of studied benign ovarian cysts. Considering the similarity of the results of this study with previous ones with the same surgical technique, we can contribute the damage asserted to ovarian reserve to bipolar cauterization and heat damage to the healthy ovarian cortical zone during the surgery.

Keywords • Dermoid cyst • Ovarian cyst • Anti-Müllerian hormone • Cystadenoma • Mucinous • Serous

Infertility Research Center, Shiraz
University of Medical Sciences, Shiraz,
Iran

Ileal Interposition with Sleeve Gastrectomy for the Treatment of Type 2 Diabetes Mellitus

Z. Zarghamifard

Abstract

Background: Resolution of type 2 diabetes mellitus (T2DM) following metabolic surgery in morbidly obese patients suggests the efficacy of these surgeries in non-morbidly obese patients (body mass index [BMI] < 35). In this article the technique, mechanisms of action and results of ileal interposition and sleeve gastrectomy (II+SG) in the resolution of T2DM is reviewed.

Methods: This literature review examined research articles due to II+SG since 2003 (the first time that this procedure has been done by de Paula) up to now. There are two techniques for this type of surgery. In the standard method after sleeve gastrectomy, 170cm of distal ileum is interposed into the proximal duodenum and in the second type of operation interposition of 170cm of distal ileum into the proximal jejunum plus sleeve gastrectomy is performed.

Results: Mechanisms of action for resolution of T2DM were caloric restriction, weight loss, neurohormonal effects – especially the effects of decreased ghrelin after sleeve gastrectomy and increased GLP1 (glucagon-like protein) which is secreted mostly by the terminal ileum. Most of the patients achieved adequate glycemic control without anti-diabetic medication, and hypertension and hyperlipidemia was treated in most patients. Approximately all patients experienced significant weight loss.

Conclusion: Adequate glycemic control, control of hypertension and hyperlipidemia, adjustable weight loss and absence of nutritional deficiencies were the main benefits of II+SG. But additional long term RCT studies are necessary.

Keywords • Ileal interposition • Sleeve gastrectomy • Type 2 diabetes mellitus • Metabolic surgery

MIS Research Center, Iran University of Medical Sciences, Tehran, Iran

Laparoscopic Metroplasty in Bicornuate and Didelphic Uteri: Feasibility and Outcome

Saeed Alborzi¹, Hossein Asefjah²,
Madihe Amini³, Homeira Vafaei⁴,
Gooya Madadi⁵, Negar Chubak⁶, Zohre
Tavana³

¹Head of the Gynecologic Endoscopy
Division, Laparoscopy Research
Center, Department of Obstetrics and
Gynecology, School of Medicine, Shiraz
University of Medical Sciences, Shiraz,
Iran;

²Obstetrician and Gynecologist, Parsian
Hospital, Tehran, Iran;

³Division of Gynecologic Endoscopy,
Department of Obstetrics and
Gynecology, School of Medicine, Shiraz
University of Medical Sciences, Shiraz,
Iran;

⁴Department of Obstetrics and
Gynecology, School of Medicine, Shiraz
University of Medical Sciences, Shiraz,
Iran;

⁵Division of Infertility, Infertility Research
Center, Department of Obstetrics and
Gynecology, School of Medicine, Shiraz
University of Medical Sciences, Shiraz,
Iran;

⁶Obstetrician and gynecologist, Dena
Hospital, Shiraz, Iran

Abstract

Background: To report the outcomes of laparoscopic metroplasty in bicornuate and didelphic uteri.

Methods: This observational study includes 26 women with double uterine cavities (22 bicornuate and 4 didelphic uteri) with history of recurrent pregnancy loss undergoing laparoscopic metroplasty, second-look laparoscopy and hysteroscopy between 2008 and 2013 in University and Private hospital (Shiraz, Iran). The feasibility of laparoscopic metroplasty, appropriateness of the uterine cavity upon secondlook laparoscopy, pregnancy outcome and live birth rate (within at least 12 month follow-up) were evaluated.

Results: All patients had a unified and acceptable uterine cavity in second-look operation. Minimal pelvic adhesions in eight cases and subseptum of uterus in seven patients were detected which were removed by laparoscopy and resectoscopy, respectively. Out of 14 patients who could be followed for one year for pregnancy occurrence 12 patients had conception. Out of them nine term pregnancies with normal pregnancy and delivery outcomes were reported. These women delivered nine live neonates through the cesarean section. Three patients had pregnancy loss (2 early pregnancy losses and one with preterm delivery). Two patients decided to postpone conception due to personal reasons.

Conclusion: Laparoscopic metroplasty by developing single uterine cavity with a suitable volume and minimal adhesion formation can be a substitute for laparotomy technique. However, more long-term studies should be done on larger sample size to confirm its positive effects on the pregnancy outcomes.

Keywords • Laparoscopic metroplasty • Pregnancy outcomes
• Bicornuate uterus • Didelphic uterus

Hysteroscopic Resection of Vaginal Septum in Didylphis Uterus With Hemiobstructed Vagina

Saeed Alborzi, Zohreh Tavana, Madihe Amini

Laparoscopy Research Center,
Department of Obstetrics and
Gynecology, Shiraz University of Medical
Sciences, Shiraz, Iran

Corresponding author:
Zohreh Tavana,
Laparoscopy Research Center,
Qadir Hospital,
Quran Avenue,
Shiraz, Iran
Tel: +98-9173144462
Email: zotavana27@yahoo.com

Abstract

Background: Uterus didelphys with imperforate hemivagina is a rare Müllerian anomaly occurring between the 12th and 16th weeks of gestation. Currently the excision of the vaginal septum is considered the treatment of choice for obstructed hemivagina, conventionally performed using scissors and scalpel. The hysteroscopic excision of vaginal septum in those with uterus didelphys has several advantages including feasibility, availability, effectiveness and preservation of virginity.

Objectives: We aimed to report the benefits of hysteroscopic resection of vaginal septum in patients with uterus didelphys and obstructed hemivagina.

Methods: This cross-sectional study was performed in Shiraz University of Medical Sciences including 11 patients with uterus didelphys and obstructed hemivagina. Hysteroscopic resection of vaginal septum was performed for all patients and the outcomes were observed.

Results: The mean age of the patients was 14.73 ± 2.3 (range 13-16) years. The most common symptom was cyclic dysmenorrhea. The vaginal septum was resected safely in all of the patients. The symptoms including cyclic dysmenorrhea and hematometra resolved after 3 months.

Conclusion: Hysteroscopic resection of the vaginal septum is an available, feasible, convenient, and effective tool in the management of uterus didelphys plus obstructed hemivagina which enables the surgeon to preserve the hymen integrity.

Keywords • Adolescent • Female • Humans

Introducing Common Marmoset Monkey as a Very Useful Animal Model in Preclinical Research

Bentolhoda Fereydouni

PhD in Biology at George-August
University of Goettingen, Germany
Email: b.fereydouni@gmail.com

Abstract

Aim: The aim of this article is to introduce the common marmoset monkey (*Callithrix jacchus*) as a very useful animal model in medical research and to discuss why medical research requires monkeys.

Background: The common marmoset monkey (*Callithrix jacchus*) is a new world monkey which is native to Brazil. The body size is small compared to other primates and is only around 25 cm in length (excluding the tail). The body weight is around 300-450 g. These characteristics make marmoset monkeys an easy-to-handle animal model. High reproductive success and absence of reproductive seasonality are key characteristics making marmoset monkeys a very valuable model to study non-human primate reproductive physiology and stem cells.

My previous studies also introduce the marmoset monkey as a non-human primate model to experimentally study aspects of primate primitive gonad development, follicle assembly, and germ cell biology *in vivo*.

Conclusion: Common marmoset monkeys are super animal models for preclinical research.

Keywords • Common marmoset monkey • Medical research • Non-human primates

The Link between Fetal Malnutrition and Childhood Obesity in the Future

Faezeh Askari

Faculty of Nutrition and Food
Technology, Shahid Beheshti University
of Medical Sciences, Tehran, Iran

Abstract

Background: Obesity prevalence is highly elevated during the last five decades and is on the rise. We observe an increase in child obesity worldwide, including Iran; being among the top seven countries with the most child obesity. Consequently, Iranian scientists and policy makers are looking for a way to resolve this by tackling the problem during the childhood period. Unfortunately, the cause of such elevated prevalence is not clearly known. This study aims at finding the link between fetal malnutrition and childhood obesity in the future.

Methods: A systematic review was conducted using PubMed, ProQuest, ScienceDirect, Google Scholar, ISI Web of Knowledge, and IranMedex using keywords such as obesity, fetal malnutrition, leptin, insulin resistance, childhood nutrition and pregnancy nutrition.

Results: The most known theories explaining the cause of obesity include (i) obesity due to wrong behaviors, (ii) obesity due to genetics and (iii) obesity due to leptin disorder. The first theory would explain most of the usual obesities but not the obesity in all cases such as young children. However, leptin disorder could clarify this issue.

Conclusion: Both leptin deficiency and resistance can lead to obesity. Insulin resistance and fetal malnutrition could lead to leptin resistance and in turn cause obesity.

Keywords • Obesity • Fetal malnutrition • Leptin

Laparoscopy and Anorectal Malformations

M. Mollaeian, F. Skandari, A. Mollaeian

Abstract

Anorectal Malformations in Male: Anorectal malformations in male patients have been repaired all over the world for the last 25 years with a posterior sagittal incision. Ninety percent of all anorectal malformations in male patients can be repaired through this incision. Ten percent of male patients with anorectal malformations traditionally have required a laparotomy, an operation that opens up the abdomen, to reach a rectum that is located very high in the abdomen.

When laparoscopy was introduced, it became obvious that the 10% of patients who required a laparotomy could potentially benefit from laparoscopy, thereby avoiding the disease potential related to the opening of the abdominal wall.

Some surgeons are using laparoscopy to repair ARM that normally does not require entering the abdomen. However, this is a controversial issue. Using the posterior sagittal approach, this group of ARMs can be repaired with an incision without opening the abdomen, in an operation that takes between 2 and 4 hours. The patients stay in the hospital for 24-48 hours, experience very little pain, and are able to eat the same day of the surgery. For this particular group, laparoscopy would require entering the abdomen, albeit with small incisions.

When these ARMs are repaired using a posterior sagittal approach, the surgeon only mobilizes the necessary part of the rectum to reach the skin. In laparoscopic approach, an unnecessarily extended dissection of the rectum is required, and the functional prognosis in these patients is not good. These surgeons justify their approach by saying that they divide less sphincter than the posterior sagittal approach. However, the PS approach is of no consequence and does not interfere with bowel control.

In the laparoscopic technique, the method of avoiding prolapse is to suture the rectum to the pelvic floor. It remains to be seen whether that maneuver keeps the incidence of prolapse low.

During the laparoscopic procedure, the surgeon must use a sharp surgical instrument to insert a drainage tube from the perineum into the abdomen. This is done while watching through the laparoscope and if not done properly can potentially lead to injuries to the urinary tract. The essence of the PS approach is a good visualization of all structures and no blind maneuvers.

In ARMs, some of the very high prostatic fistula could be approached more easily laparoscopically, particularly if the surgeon does not have experience with PS approach. For a bulbar fistula, the rectum is reachable through a PS incision and we believe that the laparoscopic approach is not ideal.

Repair of ARMs in Females: Females born with ARMs have different anatomic defects than males. The most benign form is called rectoperineal fistula. This defect can be treated through

Bahrami Children's Hospital, Tehran
University of Medical Sciences, Tehran,
Iran

a very small incision in the perineum, which takes about 1 hour. Laparoscopy would not be an appropriate method to treat this defect.

Laparoscopy also is not applicable for rectovestibular fistula. For both rectoperineal and rectovestibular fistula, the distal rectum already reaches the perineum: it is just in the wrong location, either too far or too close to the vagina.

The next malformation is called cloaca, a complex malformation that involves a fusion of rectal, vaginal, and urinary channels to a single common channel. There are a few published studies about attempts to repair cloacal malformations laparoscopically, but they describe only the rectal component of the malformation, with the vagina and urethra left together as a single channel (urogenital sinus).

The repair of cloaca requires an extensive dissection between the common wall of the rectum and the genitourinary tract. In the lower type, the urogenital component can be repaired which is called total urogenital mobilization. There is no need for a laparoscopic approach in this kind of malformation.

The repair of cloaca requires an extensive dissection between the common wall of the rectum and genitourinary tract. As technology advances, it is likely that surgical instruments will be more refined and eventually we will be able to laparoscopically separate the three structures that are abnormally attached in a cloacal malformation (bladder, rectum, and vagina).

Laparoscopic procedures applied to the surgical treatment of ARMs are not free of complications. A high incidence of rectal prolapse is being reported as a consequence of laparoscopic procedures. It is important to distinguish between a laparoscopic minimally invasive operation and a laparoscopic maximally invasive procedure. In the case of a rectourethral bulbar fistula, laparoscopy could be considered more invasive.

The Effects of Nutrition Education and Diet Therapy on Glycemic and Lipidemic Control in Patients with Type 2 Diabetes

F. Askari, R. Rastmanesh

Abstract

Background: Being aware of healthy food and making appropriate choices is an important factor in the management of type 2 diabetes (T2DM). The current study investigated the effects of nutrition education and adherence to a healthy diet on glycemic and lipidemic control in Iranian patients with T2DM.

Methods: This randomized controlled trial was conducted on 494 patients with T2DM, aged 14-87 years for both genders. The patients were recruited from Ali Ebne Abi Taleb hospital in Ghom by easy method sampling. Information on medications, psychological factors, diet, and physical activity level was obtained from responses to a questionnaire. Fasting blood samples were collected to measure FBS, 2hpG, HbA1c, cholesterol and triglyceride. The participants were randomly divided into two groups, each 247 individuals, and were age matched. The intervention group was debriefed on healthier food choices and given an appropriate diet based on their adjusted ideal body weight. After 2 months, biochemical parameters were measured again. Independent t-test, Mann-Whitney, and Chi-square test were used to compare the differences between the groups. Wilcoxon tests were used to compare changes before and after intervention.

Results: There were no significant differences between the two groups in terms of sex, energy intake, physical activity, and psychological factors. The mean FBS, 2hpg, cholesterol and triglyceride after intervention were significantly lower than before the study ($P < 0.05$). The mean of differences in biochemical variables in the intervention group were significantly more than the control group ($P < 0.05$).

Conclusion: Adherence to a healthy diet and awareness of healthy food choices are effective on glycemic and lipidemic control in T2DM.

Keywords • Diabet • Glycemic index • Lipidemic index

Faculty of Nutrition and Food
Technology, Shahid Beheshti University
of Medical Sciences, Tehran, Iran

Hysteroscopic Metroplasty of the Complete Uterine Septum, Duplicate Cervix, and Vaginal Septum

Mohammad Ebrahim Parsanezhad¹,
Tahereh Pourdast¹, Saeed Alborzi¹,
Afsoun Zarei¹, Sedigheh Dehbashi¹,
Lila Ghasempour Shirazi¹, Abdolreza
Rajaefard¹, Ernst Hienrich Schmidt²

¹Referral GYN Endoscopy Centers,
Department of Obstetrics and
Gynecology, Medical School, Shiraz
University of Medical Sciences, Shiraz,
Iran;

²GYN Endoscopy Division, Diako
Teaching Center, Gotingen University,
Bremen, Germany

Abstract

Objective: To determine if sectioning of the cervical septum in hysteroscopic metroplasty of the complete uterine septum is associated with intraoperative bleeding, cervical incompetence, and secondary infertility.

Design: Multicenter, randomized, controlled clinical trial.

Patients: Twenty-eight women with a diagnosis of complete uterine septum who had a history of pregnancy wastage or infertility. They were randomized into two groups: group A underwent metroplasty including section of the cervical septum; group B underwent the same procedure with preservation of the cervical septum.

Interventions: Hysteroscopic metroplasty was performed for all patients in the two groups.

Main Outcome Measures: Operating time, distending media deficit, total distending media used, intraoperative bleeding, complications, and reproductive outcome.

Results: Operating times were 36.40 +/- 10.67 minutes and 73 +/- 14.40 minutes in group A and group B, respectively. Distending media deficit was 456.66 +/- 165.68 mL in group A, while in group B it was 673.84 +/- 220.36. Two cases of pulmonary edema and three cases of significant bleeding (> 150 mL) were seen in group B. The cesarean section rate was significantly higher in group B. There were no significant differences in the reproductive outcome in the two groups.

Conclusion: Resection of the cervical septum during hysteroscopic metroplasty of complete uterine septum makes the procedure safer, easier, and less complicated than the procedure with preservation of the cervical septum. This procedure is recommended for all cases of complete uterine septum.

Hysteroscopic Resection of Vaginal Septum in Didylphis Uterus With Hemiobstructed Vagina

Saeed Alborzi, Zohreh Tavana, Madihe Amini

Laparoscopy Research Center,
Department of Obstetrics and
Gynecology, Shiraz University of Medical
Sciences, Shiraz, Iran

Corresponding author:

Zohreh Tavana,
Laparoscopy Research Center,
Qadir Hospital, Quran Avenue,
Shiraz, Iran
Tel: +98 9173144462
Email: zotavana27@yahoo.com

Abstract

Background: Uterus didelphys with imperforate hemivagina is a rare Müllerian anomaly occurring between the 12th and 16th weeks of gestation. Currently the excision of the vaginal septum is considered the treatment of choice for obstructed hemivagina, conventionally performed using scissors and scalpel. The hysteroscopic excision of vaginal septum in those with uterus didelphys has several advantages including feasibility, availability, effectiveness and preservation of virginity.

Objectives: We aimed to report the benefits of hysteroscopic resection of vaginal septum in patients with uterus didelphys and obstructed hemivagina.

Patients and Methods: This cross-sectional study was performed in Shiraz University of Medical Sciences including 11 patients with uterus didelphys and obstructed hemivagina. Hysteroscopic resection of vaginal septum was performed for all patients and the outcomes were observed.

Results: The mean age of the patients was 14.73 ± 2.3 (range 13-16) years. The most common symptom was cyclic dysmenorrhea. The vaginal septum was resected safely in all of the patients. The symptoms including cyclic dysmenorrhea and hematometra resolved after 3 months.

Conclusions: Hysteroscopic resection of the vaginal septum is an available, feasible, convenient, and effective tool in the management of uterus didelphys plus obstructed hemivagina which enables the surgeon to preserve the hymen integrity.

Keywords • Adolescent • Female • Humans

Intrauterine Administration of Recombinant Human Chorionic Gonadotropin before Embryo Transfer on Outcome of in Vitro Fertilization/ Intracytoplasmic Sperm Injection: A Randomized Clinical Trial

Afsoon Zarei¹, Mohammad Ebrahim Parsanezhad², Masoumeh Younesi³, Saeed Alborzi¹, Jaleh Zolghadri¹, Alamtaj Samsami¹, Sedigheh Amooee¹, Shahintaj Aramesh¹

¹Infertility Research Center, Shiraz University of Medical Sciences, Shiraz, Iran;

²Department of Obstetrics and Gynecology, Shiraz University of Medical Sciences, Shiraz, Iran;

³Student Research Committee, Shiraz University of Medical Sciences, Shiraz, Iran

Corresponding author:

Masoumeh Younesi,
Infertility Research Center,
Qadir Hospital,
Quran Gate,
P.O. Box: 71345-1818, Shiraz, Iran
Tel: +98 71 32279726
Email: younesi.dr@gmail.com

Abstract

Background: The direct effect of hCG on the human endometrium was studied several times.

Objective: The objectives of this study were to evaluate the effectiveness of intrauterine injection of recombinant human chorionic gonadotropin (rhCG) before embryo transfer (ET).

Methods: In this randomized placebo-controlled clinical trial, a total number of 182 infertile patients undergoing their first in vitro fertilization/ intracytoplasmic sperm injection (IVF-ICSI) cycles were randomly assigned to receive 250µg intrauterine rhCG (n=84) or placebo (n=98) before ET. The implantation and pregnancy rates were compared between groups.

Results: Patients who received intrauterine rhCG before ET had significantly higher implantation (36.9% vs. 22.4%; P=0.035), clinical pregnancy rates (34.5% vs. 20.4%; P=0.044) and ongoing pregnancy rate (32.1% vs. 18.4%; P=0.032) when compared to those who received placebo. The abortion (2.4% vs. 2.0%; P=0.929) and ectopic pregnancy rates (1.2% vs. 1.0%; P=0.976) were comparable between groups of rhCG and placebo, respectively.

Conclusion: Intrauterine injection of 250µg of rhCG before ET significantly improves the implantation and pregnancy rates in IVF/ICSI cycles.

Keywords • Recombinant human chorionic gonadotropin (rhCG) • Intracytoplasmic sperm injection (ICSI) • In vitro fertilization (IVF) • Implantation rate • Pregnancy rate

Laparoscopic Gonadectomy in Patients with Androgen Insensitivity Syndrome: Case Series

Afsoon Zarei¹, Mohammad Ebrahim Parsanezhad², Masoumeh Younesi³, Saeed Alborzi¹, Jaleh Zolghadri¹, Alamtaj Samsami¹, Sedigheh Amooee¹, Shahintaj Aramesh¹

¹Infertility Research Center, Shiraz University of Medical Sciences, Shiraz, Iran;

²Department of Obstetrics and Gynecology, Shiraz University of Medical Sciences, Shiraz, Iran;

³Student Research Committee, Shiraz University of Medical Sciences, Shiraz, Iran

Corresponding author:

Masoumeh Younesi,
Infertility Research Center,
Qadir Hospital,
Quran Gate,
P.O. Box: 71345-1818, Shiraz, Iran
Tel: +98 71 32279726
Email: younesi.dr@gmail.com

Abstract

Background: The gonadectomy in patients with androgen insensitivity syndrome (AIS) has been conventionally performed using laparotomic techniques. But currently several reports have suggested laparoscopic gonadectomy in these patients because of shorter hospital stay and minimal postoperative pain and hemorrhage.

Objectives: To report the laparoscopic gonadectomy in 11 patients suffering from androgen insensitivity syndrome.

Methods: This study is a case series of 11 patients with AIS aged between 17 and 20 years who were referred to the Shiraz University of Medical Sciences affiliated clinics and private hospitals from February 2006 to December 2012 and underwent bilateral laparoscopic gonadectomy. The patient's outcome and results were reported in this study.

Results: Overall we operated 11 patients suffering from AIS with mean age of 18.6 ± 3.8 (17-20) years. All of the patients presented with primary amenorrhea. The serum levels of testosterone were in normal range of male population. All the patients had an uneventful laparoscopic gonadectomy and no complications occurred during the operation and in the postoperative period. The mean operation duration was 40.3 ± 5.9 (range 35 to 55) minutes. The hospital stay duration was 1.6 ± 0.9 days. All of the patients were followed for at least 6 months after operation.

Conclusion: Laparoscopic gonadectomy is a safe, simple and effective procedure for the removal of the testis in patients with AIS. We recommend utilizing this method for gonadectomy in patients with AIS where facilities are available.

Keywords • Laparoscopy • Androgen Insensitivity • Testicular Feminization

Laparoscopic Metroplasty in Bicornuate and Didelphic Uteri: Feasibility and Outcome

Saeed Alborzi¹; Hossein Asefjah²;
Madihe Amini³; Homeira Vafaei⁴;
Gooya Madadi⁵; Negar Chubak⁶; Zohre
Tavana³

¹Department of Biochemistry, Faculty of
Medicine, Birjand University of Medical
Sciences, Birjand, Iran;

²Department of Medical Lab Technology,
Birjand University of Medical Sciences,
Birjand, Iran;

³Department of Biochemistry, Payame
Noor University, Mashhad, Iran

Abstract

Background: To report the outcomes of laparoscopic metroplasty in bicornuate and didelphic uteri.

Methods: This observational study includes 26 women with double uterine cavities (22 bicornuate and 4 didelphic uteri) with history of recurrent pregnancy loss undergoing laparoscopic metroplasty, second-look laparoscopy and hysteroscopy between 2008 and 2013 in University and Private hospital (Shiraz, Iran). The feasibility of laparoscopic metroplasty, appropriateness of the uterine cavity upon second-look laparoscopy, pregnancy outcome and live birth rate (within at least 12 month follow-up) were evaluated.

Results: All patients had a unified and acceptable uterine cavity in second-look operation. Minimal pelvic adhesions in eight cases and subseptum of uterus in seven patients were detected which were removed by laparoscopy and resectoscopy, respectively. Out of 14 patients who could be followed for one year for pregnancy occurrence 12 patients had conception. Out of them nine term pregnancies with normal pregnancy and delivery outcomes were reported. These women delivered nine live neonates through the cesarean section. Three patients had pregnancy loss (2 early pregnancy losses and one with preterm delivery). Two patients decided to postpone conception due to personal reasons.

Conclusion: Laparoscopic metroplasty by developing single uterine cavity with a suitable volume and minimal adhesion formation can be a substitute for laparotomy technique. However, more long-term studies should be done on larger sample size to confirm its positive effects on the pregnancy outcomes.

Keywords • Laparoscopic metroplasty • Pregnancy outcomes • Bicornuate uterus • Didelphic uterus

Management of an Abdominal Pregnancy by Laparoscopy: A Case Report and Review of the Literature

Saeed Alborzi¹; Nasrin Asadi²; Armin Attar³; Mohsen Khosravi Maharlooee³; Soroush Alborzi⁴

¹Laparoscopy Research Center, Shiraz University of Medical Sciences, Shiraz, Iran;

²Department of Obstetrics and Gynecology, Shiraz University of Medical Sciences, Shiraz, Iran;

³Shiraz University of Medical Sciences, Shiraz, Iran;

⁴Department of Cardiology, Shiraz University of Medical Sciences, Shiraz, Iran

Corresponding author:

Nasrin Asadi,
Department of Obstetrics and Gynecology,
Shiraz University of Medical Sciences,
Shiraz, Iran

Tel: +98 9173137810

Fax: +98 71 38210844

Email: nasadi2012@yahoo.com

Abstract

Since abdominal pregnancies are mostly complicated, they are usually managed by laparotomy, but laparoscopy is an alternative method which some surgeons perform instead of laparotomy; especially in advanced pregnancy. We reported a 31 year old woman with last menstrual period of 18 weeks who had supra pubic pain and vaginal bleeding. After sonographic evaluations, abdominal pregnancy was diagnosed and the patient underwent laparoscopic surgery for termination of pregnancy. One year after this successful operation, the patient experienced a normal intrauterine pregnancy. Laparoscopy is a successful alternative method of surgery for abdominal pregnancies which can be done by experienced surgeons especially at gestational age of 18 weeks.

Keywords • Pregnancy • Abdominal • Laparoscopy • Pregnancy Trimester • Second trimester

Metformin versus Chromium Picolinate in Clomiphene Citrate-Resistant Patients with PCOs: A Double-Blind Randomized Clinical Trial

Sedigheh Amooee, Mohammad Ebrahim Parsanezhad, Maryam Ravanbod Shirazi, Saeed Alborzi, Alamtaj Samsami

Department of Obstetrics and Gynecology, Shahid Faghihi Hospital, Shiraz University of Medical Sciences, Shiraz, Iran

Corresponding author:

Sedigheh Amooee,
Department of Obstetrics and Gynecology,
Shahid Faghihi Hospital,
Zand Ave., Shiraz, Iran
Tel/Fax: +98 9177111318
Email: sedighehamooee@gmail.com

Abstract

Background: Chromium picolinate could be effective in clomiphene citrate resistant PCOS patients.

Objective: To compare the effects of chromium picolinate vs. metformin in clomiphene citrate resistant PCOS patients. **Materials and Methods:** The present randomized clinical trial was performed on 92 women with clomiphene citrate-resistant PCOS at the clinics which were affiliated to Shiraz University of Medical Sciences, Shiraz, Iran. The subjects were randomly assigned to two groups receiving either chromium picolinate (200 µg daily) or Metformin (1500 mg daily) for 3 months. Anthropometric and hormonal profile were measured and compared both before and after the treatment. Ovulation and pregnancy rate was measured in the two study groups, as well.

Results: Chromium picolinate significantly decreased fasting blood sugar (FBS) after 3 months of treatment ($P=0.042$). In the same way, the serum levels of fasting insulin had significantly decreased leading to an increase in insulin sensitivity as measured by QUICKI index ($P=0.014$). In comparison to the patients who received chromium picolinate, those who received metformin had significantly lower levels of testosterone ($P=0.001$) and free testosterone ($P=0.001$) after 3 months of treatment. Nevertheless, no significant difference was found between the two study groups regarding ovulation ($P=0.417$) and pregnancy rates ($P=0.500$).

Conclusion: Chromium picolinate decreased FBS and insulin levels and, thus, increased insulin sensitivity in clomiphene citrate-resistance PCOS women. These effects were comparable with metformin; however, metformin treatment was associated with decreased hyperandrogenism. Overall, chromium picolinate was better tolerated compared to metformin; nonetheless, the two study groups were not significantly different regarding ovulation and pregnancy rates.

Keywords • Chromium picolinate • Metformin • Polycystic ovary Syndrome (PCOS) • Clomiphene resistant

Thalidomide Affects Experimental Endometriosis: A Randomized Controlled Study in the Rat

Afshin Azimirad^{1,2,3}, Saeed Alborzi^{1,3},
Perikala Vijayananda Kumar⁴, Jaleh
Zolghadri³, Afsoon Zarei¹, Zohreh
Tavana¹, Mina Azimirad⁵

¹Laparoscopy Research Center,
Department of Obstetrics and
Gynecology, Shiraz University of Medical
Sciences, Shiraz, Iran;

²Student Research Committee, Shiraz
University of Medical Sciences, Shiraz,
Iran;

³Infertility Research Center, Shiraz
University of Medical Sciences, Shiraz,
Iran;

⁴Department of Pathology, Shiraz
University of Medical Sciences, Shiraz,
Iran;

⁵Shariati Hospital, Tehran University of
Medical Sciences, Tehran, Iran

Abstract

Background: This study aimed to assess the efficacy of thalidomide for treatment of experimental endometriosis.

Methods: This study was a parallel-group, double-blind, stratified, randomized controlled animal trial with 1:1 allocation ratio. Endometriosis was induced experimentally in 23 mature, nulligravid, female Sprague–Dawley rats, weighing approximately 200 g and aged 2 months. A checkpoint surgery was performed 6 weeks later. Then, the rats were randomly allocated into the thalidomide (22 mg/day p.o.) and control (0.5 mL saline 0.9%/day p.o.) groups of nine. After 6 weeks, they were killed. Before each laparotomy, blood for leukocyte and lymphocyte counts and during them, implants for histopathology and peritoneal fluid for interleukin (IL)-6, tumorecrosis factor- α and vascular endothelial growth factor (VEGF)-A concentrations (by enzyme-linked immunoassay) were collected. Allocation and stratified randomization were done using a computer, based on the obtained histopathology scores of the implants of the checkpoint surgery.

Results: The histopathology scores (the main outcome measure) were 2.00 ± 1.55 versus 0.44 ± 1.01 ($P=0.035$). The comparisons of after-treatment counts of leukocytes, lymphocytes, VEGF-A and IL-6 between the two groups were statistically significant.

Conclusion: The results of this study are in favor of therapeutic implication of thalidomide in experimental endometriosis in rats. This is the first time thalidomide has been evaluated on endometriosis in an animal model.

Keywords • Animal model • Endometriosis • Immunology • Randomized controlled trial • Thalidomide

Colposcopy as a Minimally Invasive Surgery in Diagnosis for Treatment of Pre-invasive Cervical Cancer

Soheila Amini Moghadam

Abstract

The main indication of colposcopy is follow up of the abnormal pap smear. After pap smear of ASC-H, LSIL, HSIL, SCC, atypical glandular cell NOS or endocervical or endometrial type, favor neoplasia, and adenocarcinoma, colposcopy is performed. Genital warts in female patients (or her husband), abnormal cervix, recurrent infection, post coital bleeding, and in cervical conization for diagnosis and treatment of pre-invasive disease of cervix is another indication of colposcopy.

Not an absolute contraindication, but in infection in the upper genital tract, treatment is advised and after cessation of bleeding is done easier.

One complication of colposcopy is bleeding that can be stopped with packing, silver nitrate, Monsel's solution or suturing.

In pregnancy, colposcopy is done but biopsy is done in suspicious high-grade lesion or cancer.

Solution normal saline, acid acetic 3-5%, logol 25% is used in colposcopy.

Vulvar, vaginal, cervical colposcopy can be done.

With green filter abnormal vessel as a hallmark of invasive cervical cancer could be seen.

With colposcopy, the need for big biopsy such conization can be ignored, thus a minimally invasive surgery.

Keywords • Colposcopy • Pap smear • Conization • Bleeding

Laparoscopic Proctocolectomy with Ileal Pouch Anal Anastomosis without Ostomy

Abbas Abdollahi¹, Alireza Tavasoli², Ali Jangjoo¹, Reza Roshan Ravan^{**}

¹Surgical Oncology Research Center, Mashhad University of Medical Sciences, Mashhad, Iran;

²Endoscopic and Minimally Invasive Surgery Research Center, Mashhad University of Medical Sciences, Mashhad, Iran

Abstract

Background: Laparoscopic proctocolectomy with ileal pouch in all patients requires protective ostomy. This technique does not necessitate diverting ostomy and patients receive a transanal tube. This study aimed to evaluate results of laparoscopic proctocolectomy in patients who received a transanal tube.

Methods: Ten patients who underwent laparoscopic proctocolectomy with ileal pouch between the years 2013 and 2015 were included in the study. We attempted transanal tube insertion in this procedure. The patients were followed for a mean of 11 months.

Results: The operative time was 160-240 minutes. Failure of anal pouch-anastomosis occurred in one patient which was managed with ostomy. The partial obstruction which was observed in one patient was treated medically. No perioperative mortality occurred.

Conclusion: Laparoscopic proctocolectomy with transanal tube ostomy can be a safe and good procedure necessitating no protective ostomy.

Keywords • Laparoscopic proctocolectomy • Protective ostomy • Transanal tube ostomy

Surgical Intervention in a Rare Case of Mixed Gonadal Dysgenesis with Mosaicism 45, X/46, X, +mar

Fahimeh Soheilipour, Abdolreza Pazouki, Babak Behnam, Ommolbanin Abed

Minimally Invasive Surgery Research Center, Rasool-e-Akram Hospital, Iran University of Medical Sciences (IUMS), Tehran, Iran

Abstract

Introduction: We present a case of a ten-year-old boy with a disorder of sex development (DSD) of mixed gonadal dysgenesis with a new pattern of chromosome in the karyotype, 45, X/46, X, +Mar(Y).

Presentation of Case: A ten-year-old boy presented with ambiguous genitalia. Two cell lines, (45, X), [46, X, +mar (Y)] were observed utilizing cytogenetic and fluorescence *in situ* hybridization (FISH) investigations which were carried out on his peripheral lymphocytes. A significantly higher percentage (75%) of Y-containing cells was observed in the blood, which could be considered the major reason why the case did not have distinct ambiguous genitalia.

Discussion: A complete and sufficiently careful medical evaluation and genetics counseling of neonates is highly recommended in order to avoid any delayed insufficient diagnostic, conservative, and therapeutic care in children with guardians rather than their biological parents. Both molecular and cytogenetic studies are recommended in some DSDs to help early diagnosis of the disease, which is important for further essential surgical approaches.

Conclusion: Cytogenetic studies followed by a laparoscopic exploratory and surgical survey are helpful tools for unraveling the mosaicism involving sex chromosomes and the complicated process in mixed gonadal dysgenesis patients.

Keywords • Mixed Gonadal dysgenesis • Karyotype • Laparoscopic surgery

External Validation of Endometriosis Fertility Index (EFI) by Spontaneous Pregnancy Outcome of Infertile Patients in Avicenna Endometriosis Clinic During Years of 2012-2014

Roya Padmehr, Arash Mohazzab, Khadijeh Shadjoo, Parvin Jaberipour, Azam-Sadat Mahdavi, Shaheen Khazali

Reproductive Immunology Research Center, Avicenna Research Institute, ACECR, Tehran, Iran; Endometriosis and Pelvic Pain Clinic, Avicenna Infertility Clinic, Avicenna Research Institute, ACECR, Tehran, Iran

Abstract

Background: To evaluate reproducibility of EFI score of endometriosis patients to predict pregnancy chance after utmost 2 years of follow up

Methods: In this historical cohort study from 168 endometriosis patients diagnosed in Avicenna endometriosis clinic between years of 2012-2014, 93 patients were complaint from infertility. The endometriosis lesion was resected laparoscopically, the EFI was calculated for each patient and the EFI was categorized in three groups. Patients were suggested for non ART conception (natural intercourse, ovulation induction, intrauterine insemination) and followed for pregnancy event. The Kaplan-Meier analysis was done for EFI factor during the time of follow up. Subjects were censored when they were lost to follow-up or got pregnant. All statistical analysis was operated by SPSS software version 13.

Results: From 93 cases, 76 patients were followed for pregnancy and 17 patients (22.4%) became pregnant spontaneously during the study. The mean follow up period was 15.37 ± 7.8 months for non-pregnant patients and 8.7 ± 6.4 for pregnant patients. The Kaplan Meier analysis showed significant relevance between EFI score of patients and fertility chance with Berslow (generalized Wilcoxon) P value of 0.05. The cumulative pregnancy rate was 34.8% for EFI=8-10, 20% for EFI=6-7, and 15.7% for EFI=1-5. There was no statistical significance for age of the two groups of patients ($P=0.298$).

Conclusion: The study showed EFI score has considerable predictive value to estimate pregnancy chance of endometriosis patients. It showed that most pregnancy events happened during first year after surgery.

Sclerotherapy for Recurrent Endometrioma

Saeed Alborzi¹, Bahya Namavar
Jahromi²

Abstract

Background: Endometrioma is a benign, cystic, estrogen dependent disease in women of the reproductive age that may present with dysmenorrhea, pain, and infertility. Traditionally, endometrioma has been managed by surgical cystectomy. However, the development of complications such as pelvic adhesions and decreased ovarian reserve after cystectomy has pushed practitioners to look for less invasive treatment modalities. Sclerotherapy by ethanol under ultrasound guide is suggested as a new method of management for endometriomas. In this study, we planned to perform sclerotherapy for women who had previously undergone laparoscopic cystectomy for endometrioma and presented with recurrence of the disease.

Methods: In this study, 22 women were enrolled. All were cases of recurrent endometriomas after previous laparoscopic cystectomies. Aspiration of the thick chocolate material of the cysts was performed under ultrasound guide for all women in the first step, and then the cysts were irrigated and washed clean by sodium chloride 9%. Then, the cyst cavity was irrigated by 96% ethanol and aspirated after 5 minutes. Finally, ethanol was infused and left in the cyst with a volume equivalent to 50-70% of the original cyst volume. The patients were followed and reevaluated at 1-, 3-, 6- and 12-month after the procedure for their pain, antral follicular count, and recurrence of the disease. In addition, serum levels for CA-125, AMH, FSH, and estradiol were measured and compared.

Results: The mean age of the women in this study was 30.8±1.94 years (range 28-35). The mean FSH declined from 9.10±0.71 to 8.73±0.78 from the third to the twelve months (P=0.001). AMH mildly increased from 1.523±0.34 to 1.573±0.29, which was not statistically significant (P=0.155). The mean antral follicular count increased from 6.27±1.48 to 7.45±1.80 (P=0.002). Their pain score reduced to 1/10 in the third month (P=0.005). The mean estradiol increased from 70.52±51.2 to 74.09±46.7 (P=0.033). CA-125 reduced during the study period; however, the value was not statistically significant. Eleven women are followed up to date, and their cyst sizes decreased up to the third month and slowly increased thereafter. The values were not statistically significant. Four women became pregnant and three had spontaneous pregnancy, one of which through IVF.

Conclusion: Sclerotherapy with ethanol can be considered as a safe and effective method for the management of recurrent endometriomas with acceptable results.

¹Laparoscopy Research Center, Infertility Research Center, Department of OB-GYN, School of Medicine, Shiraz University of Medical Sciences, Shiraz, Iran;

²Infertility Research Center, Maternal-fetal Medicine Research Center, Department of OB-GYN, School of Medicine, Shiraz University of Medical Sciences, Shiraz, Iran

Laparoscopic Pyelolithotomy: Is it A Good Alternative for PCNL and Open Surgery?

Mohammad Mehdi Hosseini¹, Alireza Aminsharifi^{1,2}, Dariush Irani¹, Abdo-Reza Haghpanah^{1,2}, Ali Eslahi^{1,2}, Alireza Yousefi³, Reza Inaloo³, Mohammad Zaki-Abassi⁴

¹Endourology Unit, Urology Department, Shiraz University of Medical Sciences, Shiraz, Iran;

²Laparoscopy Research Center, Shiraz University of Medical Sciences, Shiraz, Iran;

³Urology Department, Jahrom University of Medical Sciences, Jahrom, Iran;

⁴Urology Department, Boushehr University of Medical Sciences, Boushehr, Iran

Abstract

Background: Patients with complex renal stones for which extracorporeal shock wave lithotripsy (ESWL) is not indicated should undergo other modalities, with percutaneous nephrolithotomy (PCNL) being the gold standard. Laparoscopy seems a good alternative for staghorn stones. We evaluated the feasibility, safety and efficacy of laparoscopic pyelolithotomy in our center.

Methods: Between September 2010 and April 2014, 59 cases of staghorn renal stone underwent laparoscopic removal. The procedure was performed in flank position, under general anesthesia, where the colon was mobilized, and the pedicle and renal pelvis were explored. Stone was extracted through pyelotomy incision and ureteral stent was put. The incision was repaired and hemovac drain was inserted. Stone was removed from the extended port which was placed lateral to the rectus muscle.

Results: Our patients included 38 men and 21 women, with a mean age of 42 (26-71). The mean operation time was 115 minutes (95-160), and mean hospital stay was 2.5 days (2-4). Six patients received a blood transfusion. Three patients had residual stone in calices who underwent ESWL. Fever was seen in 9 patients and was well controlled with antipyretics.

Conclusion: Laparoscopic pyelolithotomy is a good alternative method in selected cases.

Mini Percutaneous Nephrolithotomy (MPCNL) in Children

M. M. Hosseini, D. Irani,
A.R.Aminsharifi, A.R.Haghpanah,
A.Eslahi, A. Farokhi

Laparoscopy Research Center, Shiraz
University of Medical Sciences, Shiraz,
Iran

Abstract

Background: Today nephrolithiasis is common in children, and due to its recurrent nature, it requires a good approach in diagnosis, treatment and prevention. Extracorporeal shock wave lithotripsy (ESWL) is the best modality for renal stone in children, but in some circumstances other interventions may be indicated. In such cases, percutaneous nephrolithotomy (PCNL) seems the less invasive and safest method. We evaluated Mini-perc nephrolithotomy with semirigid ureteroscope.

Methods: Thirty Four children (23 boys and 13 girls) with a mean age of 3.2 years (9mo-15y) who had renal stone >20mm, underwent PCNL. The procedure was done under general anesthesia, with ureteral catheter 3-4 F, diluted contrast injection and fluoroscopic guided nephrostomy by Chiba needle 18G. Tract dilation performed with Alken telescopic dilators up to 18F, which the last (18F) hold instead of Amplatz sheath in collecting system. Nephroscopy and lithotripsy done with semirigid ureteroscope and pneumatic lithoclast and removed. Saline solution was used as irrigation for the prevention of hyponatremia. No nephrostomy (tubeless) and ureteral catheter removed 12-24 hours after operation.

Results: Mean operation time was 60 minutes (40-85) and radiation 0.6 minutes (0.3-1.9). One patient had residual fragment 5mm in upper pole calyx that passed spontaneously 2 weeks after operation. There were no intra or postoperative complications.

Conclusion: We suggest Miniperc as a good alternative method to standard PCNL for children.

Percutaneous Nephrolithotomy (PCNL): Experience with Over 12,000 Cases in 12 Years

Mohammad Mehdi Hosseini¹, Alireza Aminsharifi^{1,2}, Dariush Irani¹, Abdo-Reza Haghpanah^{1,2}, Alireza Yousefi³, Reza Inaloo³, Mohammad Zaki-Abassi⁴

¹Endourology Unit, Urology Department, Shiraz University of Medical Sciences, Shiraz, Iran;

²Laparoscopy Research Center, Shiraz University of Medical Sciences, Shiraz, Iran;

³Urology Department, Jahrom University of Medical Sciences, Jahrom, Iran;

⁴Urology Department, Boushehr University of Medical Sciences, Boushehr, Iran

Abstract

Background: Currently, percutaneous nephrolithotomy (PCNL) is the modality of choice for treatment of large, complex renal stones. However, such an open surgery has its complications. We investigated the results and complications of PCNL in our high volume training and referral center.

Methods: Between September 2002 and December 2014, a total of 12,379 PCNL procedures were done in our center; 7127 men and 5252 women, mean age 38.6 year (18-82) and mean stone size 25.5mm (17-71). They underwent PCNL by experienced, training urologists (fellowships) and residents. PCNL was done in standard, No Nephrostomy and totally tubeless methods. Fluoroscopy and ultrasound were used for access. General, epidural, and spinal were the methods of anesthesia. We recorded the results and complications of our patients.

Results: Early stone-free rate was 88.14% and after 3 weeks with ancillary procedures (URS, SWL) 92.6%. Complications according to Clavein classification:

-Grade I (746): Fever >38.3 C 236, Bleeding 271, Hyponatremia (PCNL Sx.) 18, PCS perforation 154, Pneumo/hydro/hemothorax 46, Renal failure 21;

-Grade II (334): Transfusion 245, UTI 28, ileus 47, pneumonia 14;

-Grade III (571): Access failure 95, Clot retention 37, late hematuria 108, Conversion to open 28, Visceral injury 15, Perinephric collection 32, Chest tube 17, Scapular fracture 1, Re-PCNL 238;

-Grade IV (153): Renal failure requiring dialysis (17), Kidney exploration and repair (18), Heart failure (24), Arrhythmia requiring ICU (29), Sepsis (9), Myocardial infarction (52);

-Grade V (18): sepsis 5, MI 12, unknown 1.

Although some of the minor and major complications were managed by referring physicians which did not report to us.

Conclusion: PCNL seems the best treatment option for large renal stones and is a less invasive method; we should consider minor and major complications of such an open surgery and manage them appropriately.

Comparative, Double-Blind, Randomized, Placebo-Controlled Trial of Intraperitoneal Of Bupivacaine and Lidocaine for Pain Control After Diagnostic Laparoscopy

Mohammad Ebrahim Parsanezhad¹,
Fatemeh Sadat Najib¹, Masoud
Lahsaee¹, Saeed Alborzi¹, Homayra
Vafaei¹, Ernst Heinrich Schmidt²

¹Department of Obstetrics and
Gynecology, School of Medicine, Shiraz
University of Medical Sciences, Shiraz,
Iran;
²Göttingen University, Bremen, Germany

Abstract

Study Objective: To compare the effect of intraperitoneal bupivacaine and lidocaine on reducing pain after diagnostic laparoscopy.

Design: Randomized, double-blind, placebo-controlled study (Canadian Task Force classification I).

Setting: University teaching hospital.

Patients: One hundred thirty-four women with unexplained infertility.

Intervention: Diagnostic laparoscopy with intraperitoneal administration of bupivacaine or lidocaine.

Measurements and Main Results: Patients were randomized into one of four groups. In group A, at the end of laparoscopy 0.125% bupivacaine 30 ml was instilled into the pelvic cavity and the same dose was instilled over the diaphragmatic vault. Groups B and C received the same volume of 5% lidocaine and normal saline, respectively. Group D received no intraperitoneal agent. The verbal pain scale questionnaire was used to assess postoperative pain. Pain scores 2 and 24 hours postoperatively were significantly lower for group A than for groups B and C (P=0.0001). Scores in group B were also significantly lower than those in groups C and D (P=0.0001). Women in group A required less additional analgesia than those in the other groups.

Conclusion: Compared with lidocaine and placebo, intraperitoneal bupivacaine significantly decreased postoperative pain, and this effect was long lasting.

Prevalence of Constipation in Morbid Obese Patients Before and After Bariatric Surgery

Abdolreza Pazouki, Sara Akbarnejad,
Mohadeseh Pishgahroudsari,
Somayyeh Mokhber, Fatemeh Jesmi,
Mohsen Masoodi

Minimally Invasive Surgery Research
Center, Iran University of Medical
Sciences, Tehran, Iran

Abstract

Background: The prevalence of obesity is increasing in developed and developing countries. Surgical approach is the only effective choice for morbid obese patients to achieve their optimal weight. Being overweight or obese, aside from other factors, affect functional defaecatory disorders, such as constipation. Since there have been few studies which have evaluated the effect of bariatric surgery on patients' constipation, we have designed this study to concern this important issue.

Methods: During this analytic cross sectional study, between 2012 and 2014, 250 morbidly obese patient who were candidates for bariatric surgery (Roux-en-Y gastric bypass (RYGB), minigastric bypass (MGB), and sleeve gastrectomy) at Rasool-e-Akram Hospital were enrolled to our study. Wexner questionnaire was filled by all patients before and 6 months after surgery to evaluate constipation. Data including sex, age, level of education, BMI, past medical history, previous anorectal surgery and obstetric history were collected.

Results: Among 250 patients enrolled in our study, 109 patients (43.6%) underwent MGB, 128 (51.2%) underwent RYGB, and 13 (5.2%) underwent sleeve gastrectomy. The mean value of BMI was 46.4 before surgery, being reduced to 37.8 after surgery ($P<0.001$). Before the study, 104 patients had constipation, being reduced to 51 patients six months after surgery ($P<0.001$).

Conclusion: The present study showed that bariatric surgery reduces the frequency of constipation and improves the quality of life in morbidly obese patients.

Keywords • Constipation • Bariatric surgery • Morbid obesity

Laparoscopic Management of Hydatid Spleen: A Case Report

Khairallah Muzhir Gabash¹, Ahmed Shubber²

¹FRCS General & Laparoscopic surgery, Assistant. Prof., Medicine College, Wasit university Kut city, Iraq;
²CABS Radiology, Al-Karama Teaching Hospital

Abstract

Hydatid disease is a common in Iraq. The spleen is involved in 2.5%. Open splenectomy was the standard procedure for its surgical treatment until early 1970s. since then, increased awareness of asplenia - related life threatening complications has led to preservation of spleen as the new surgical approach, hand assisted laparoscopic splenectomy has been reported once. Herein we report a 46 yr.old female patient who presented with hydatid spleen managed successfully by laparoscopic hydatid cystectomy with preservation of the spleen. The post operative course was smooth, and monthly follow up revealed no evidence of recurrence.

Conclusion: Laparoscopic management of hydatid spleen is a feasible and efficacious method in selected cases.

Mid-Term Results of Laparoscopic Adjustable Gastric Banding for the Treatment of Morbid Obesity

Mohsen Mahmoudieh, Behrouz Keleidari, Gholamreza Mohajeri, Masoud Sayadi Shahraki, Mahsa Gharzi, Hossein Bahrami Samani

Department of Surgery, School of Medicine, Isfahan University of Medical Sciences, Isfahan, Iran

Abstract

Background: The World Health Organization (WHO) describes obesity as the greatest threat of human life. The prevalence of obesity is increasing in both developed and non developed countries. Laparoscopic adjustable gastric banding as the least invasive bariatric surgery widely used for treating morbid obesity. Although reversibility and improving some disorders such as preexisting GERD are several advantages of this method, recent studies have shown high complication rates after surgery. The aim of this study was to examine our experiences with gastric banding in our surgery center.

Methods: We reviewed retrospective data of 56 patients who underwent laparoscopic adjustable gastric banding between 2011 and 2014 at a single institution. Patients' demographic data, weight loss, complications and requirement of reoperation were analyzed.

Results: 56 laparoscopic adjustable gastric bands placed between 2010 and 2014 were examined in our study. The average age (mean±SD) and women's percentage were 32.30±9.70 years and 82.4% respectively. The mean weight and body mass index for patients before surgery were 101.00±16.32 kg and 36.90±3.79 kg/m² respectively. The mean of duration hospitalization was 1.12±0.38 days and 37.5 % of patients displayed complications after surgery. 35.7% of patients required reoperation after gastric banding and 30.4% of patients underwent port removal surgery.

Conclusion: Laparoscopic adjustable gastric banding was initially popularized as a minimally invasive gastric-restrictive procedure that had low morbidity. Our study showed a 37.5% complication rate. Port infection was the most common complication after this surgery and port revision was the earliest co-morbidity which led to reoperation after gastric banding. The total rate of reoperation was 35.7% and 85.15% of this reoperations led to port removal surgery. High rate of complications and reoperations after gastric banding have caused this surgical method to be used less than before, and have suggested the requirement for new studies to modify this technique such that the weight loss occurs without high reoperation and complication rates.

Keywords • Morbid obesity • Laparoscopy • Laparoscopic adjustable gastric banding

Small Intestine Obstruction due to Laparoscopic Adjustable Gastric Banding and (LAGB) Migration

Mohsen Mahmoudieh¹, Behrouz Keleidari¹, Gholamreza Mohajeri¹, Masoud Sayadi Shahraki^{1*}, Shervin Badihian², Mahsa Gharzi², Samira Davashi², Faranak Baharami¹

¹Department of Surgery, Isfahan University of Medical Sciences, Isfahan, Iran;

²Isfahan Medical Students Research Center, Isfahan University of Medical Sciences, Isfahan, Iran

Abstract

Background: LAGB is the most common method among various surgical methods for obesity treatment, performed around the world and provides a significant weight loss. Despite its benefits, as a method that requires the least intervention, complications such as gastric prolapse, stoma stenosis and migration band may also occur. These complications rarely result in mortality, but usually the only treatment for patients is surgery.

Case Presentation: We report a rare complication of this procedure, which caused small intestine obstruction.

Conclusion: Small intestine obstruction caused by band migration is a rare complication and must be considered as a differential diagnosis in patients with small intestine obstruction symptoms. Correct surgical methods must be adopted for its treatment, in order to avoid surgeons being misled during the operation and allow them to perform the treatment correctly.

Keywords • Small intestine obstruction • Gastric band migration • Adjustable gastric band

Axial Lumar Interbody Approach for Discectomy and Fusion

Babak Babapour

Neurosurgery Erfan Tehran

Abstract

Interbody fusion is getting more popular among spine surgeons. AxiaLIF is a minimal invasive surgery (MIS) procedure that utilizes the percutaneous presacral approach to the lumbosacral spine developed by Cragg et al, first introduced in 2003, and allows vertical access to the anterior lumbosacral spine to perform Discectomy and interbody fusion of L4/L5 and L5/S1 Disc spaces.

Indications and patient evaluations, risks and complications are compared with open approaches in this study.

Different Methods of Laparoscopic Ovarian Transposition and Cryopreservation before Chemoradiation Therapy

Behnaz Nouri

Department of Gynecology, Shahid
Beheshti University of Medical Sciences,
Tehran, Iran
Tel: +98 21 77430483
Email: b.nouri1376@gmail.com

Abstract

Background: Ovarian radiation can result in atrophy and decreased follicle number. Ovarian Transposition secures the ovary in a fixed position and far from its normal position. Transposition and cryopreservation can be performed laparoscopically just before the start of radiation therapy.

Methods: When the radiation field had been planned by the radiation oncologist, the laparoscopic ovarian transposition was performed with or without tubal cutting. The ovaries were mobilized by dividing the utero-ovarian ligaments near to the uterus and incising the peritoneum along the infundibulopelvic ligament. The ovaries were then brought out of the pelvis to the paracolic gutters ideally at least 3 cm from the upper border of the radiation field and were fixed with non-absorbable sutures. A part of ovarian tissue was removed for frozen section and cryopreservation.

Results: Advantages of cryopreservation are:
1-The immature oocytes are matured in vitro 2- Continue to produce hormone after implantation but is still largely considered an experimental procedure. Ovarian transposition reduces the effects of scatter radiation.

Keywords • Laparoscopic ovarian transposition • cryopreservation
• Radiation

Influence of Laparoscopic Gastric Plication Surgery on Dietary Intake in Morbidly Obese Patients

M. Hasani, M. Mirahmadian, E. Taheri,
M. Qorbani, M. Talebpour, S. Hosseini

Abstract

Background: The present study was performed to assess the nutritional status among morbidly obese patients who are candidates for laparoscopic gastric plication (LGP) surgery, before and after surgery.

Methods: This study was conducted on 19 subjects with extreme obesity, aged 18 to 65 years, who were scheduled for LGP surgery. Dietary intakes were assessed using a 24-hour recall questionnaire for 3 days at baseline and 3 months after surgery. The mean daily intake of energy, micronutrients and macronutrients was determined at each time and compared to DRI. Dietary intake was analyzed after data processing using Nutritionist 4 software package.

Results: The mean excess weight loss of patients was $44.45 \pm 9.78\%$. The mean daily energy intake decreases from 1876.22 ± 621.33 at baseline to 666.49 ± 339.09 kcal/day at 3 months after surgery. The percent of energy from fat and carbohydrates were lower and from protein was higher from pre to postoperation, but was lower than DRI. All of the patients had a low intake of vitamin A, D and folic acid before and after LGP. More than 60% of patients had low intakes of vitamin B1, B2, B3, B6, calcium and iron after the surgery.

Conclusion: Our results demonstrated dietary deficiencies, including inadequate protein and some of the micronutrients at 3 months after LGP surgery. It appears that some of these dietary deficiencies were pre-surgery and persisted or worsened after the surgery. Therefore, dietary counseling and appropriate supplementation must be emphasized in pre and post surgery patient care.

Keywords • Dietary intake • Macronutrients • Micronutrients • Bariatric surgery

Prevalence of Common Polymorphisms of ARID1A and eNOS in Patients with Endometriosis Compared to Control Group

Zohreh Tavana, Azadeh Khalili

Abstract

Background: Endometriosis is a common gynecologic disorder defined as ectopic presence of endometrial tissue in extra-uterine sites. Higher stages of endometriosis are associated with infertility and higher risk of malignancy. Identification of genetic factors responsible for development and malignant transformation of endometriosis can improve therapeutic approaches. In the present study we investigated association of ARID1A and eNOS polymorphisms with endometriosis and staging of the disease.

Methods: 100 women with laparoscopy confirmed diagnosis of endometriosis were included and compared with 100 non-endometriosis women as the control group. Genotypes of patients regarding Gln920Ter polymorphism of ARID1A gene and Glu298Asp polymorphism of eNOS gene were determined by PCR techniques on blood samples from the study population. Prevalence of each genotype in endometriosis patients was compared with healthy controls using Chi-Square test.

Results: Significantly higher prevalence of non-CC genotype for ARID1A Gln920Ter polymorphism and non-GG genotype for G894T polymorphism of eNOS gene was detected in endometriosis group. There was no significant relationship between these polymorphisms and staging of endometriosis.

Conclusion: Significant variation of prevalence of Gln920Ter polymorphism of ARID1A gene and Glu298Asp polymorphism of eNOS gene among the two groups can be indicative of a causative effect of these genetic alterations on the development of endometriosis.

Keywords • Human BAF250 protein • Human ARID1A protein
• Endometriosis • Human eNOS protein

Shiraz University of Medical Sciences,
Shiraz, Iran

Predictors of Weight Loss After Laparoscopic Gastric Plication: A Prospective Study

R Heidari, A Zeinoddini, M Talebpour, A Talebpour

Abstract

Laparoscopic gastric plication (LGP) is a bariatric procedure for the treatment of morbid obesity that has recently increased in popularity. Herein, the predictors of weight loss following LGP are investigated. Patients and Methods: This prospective study was performed on cases performed by a single surgeon between 2000 and 2011. The association between nine independent variables and ideal weight loss (percentage of excess weight loss [%EWL] $\geq 80\%$) at 24 months postoperatively was assessed in 330 patients who underwent LGP. The studied variables were as follows: age at surgery, gender, preoperative body mass index, preoperative comorbidities, marital status (single versus married), employment status (employed versus unemployed), family support in helping the patient to engage in physical activities and continue on a healthy diet (never/a little versus sometimes/a lot), the experience of pain or gastroesophageal reflux during or after eating (yes or no), and participation in support groups following LGP (yes or no). Results: Ideal weight loss (%EWL $\geq 80\%$) was achieved in 60 patients, and %EWL $< 80\%$ (suboptimal weight loss) occurred in 270 patients. Being single, female, and of younger age and participation in group meetings were significantly associated with experiencing ideal weight loss at 24 months, postoperatively. However, no significant difference was observed between the two groups in terms of preoperative body mass index, comorbidities, employment, a relative being a coworker, and the experience of pain or gastroesophageal reflux after eating. Conclusions: This study identified predictor factors positively associated with ideal weight loss. These results would aid surgeons in better patient selection and identification of patients requiring more careful follow-up. In addition, it provides patients with more realistic assessment of potential outcome of the procedure.

Laparoscopic Ward, Sina Hospital,
Tehran University of Medical Sciences,
Tehran, Iran

Laparoscopic Ventral and Incisional Hernia Repair: Seven Years' Experience with 81 Consecutive Hernia

A. Chetibi, M. Ghazali, S. Kadri, M.L. Abbou, N. Meddad, M. Saidani

Abstract

Background: This study aims to evaluate the results for ventral and incisional hernia repair by laparoscopic intra-peritoneal prosthesis. The principal objective was the rate of the recurrences.

Methods: From November 2009 to January 2015, 81 consecutive ventral and incisional hernias repairs are treated by laparoscopy. The average age of patients was 43.2 years (19 -74 years).

Main criteria were recurrence. Others were postoperative morbidity and mortality, duration of hospitalization and intervention, quality of life of patients and postoperative complications.

Results: Three quarters of patients were followed in two years; a recurrence was observed (3.7%). No death occurred. Most of our patients have postoperative pain acceptable to moderate (87%). The average duration of hospitalization was 1.15 days. Duration of intervention is estimated at 115 minutes. 16, 4% minor postoperative complications occurred. The rate of conversion to laparotomy is zero.

Conclusion: The treatment of ventral and incisional hernia repair is treated by laparoscopy is safe, effective and reproducible, providing very satisfactory results, but requires rigor and discipline surgery.

Keywords • Incisional Hernia • Ventral Hernia • Laparoscopic • Intra-Peritoneal Prosthesis • Results

Service De Chirurgie Générale, CHU:
Beni-Messous

The Impact of Laparoscopic Cystectomy on Ovarian Reserve in Patients with Unilateral and Bilateral Endometriomas

Saeed Alborzi, Pegah Keramati,
Masoomah Younesi, Alamtaj Samsami,
Nasrin Dadras

Department of Obstetrics and
Gynecology, Infertility Research Center,
Shiraz University of Medical Sciences,
Shiraz, Iran

Abstract

Objective: To evaluate the effects of laparoscopic cystectomy on ovarian reserve in patients with endometriomas.

Design: Prospective study.

Setting: Private and university hospitals.

Patients: A total of 193 patients with endometriomas undergoing laparoscopic cystectomy.

Interventions: Serum levels of antimüllerian hormone (AMH), FSH, and E2, as well as antral follicle count (AFC) were measured preoperatively and 1 week, 3 and 9 months postoperatively for AMH, and 3 months for other values.

Main Outcome Measures: Ovarian reserve based on the comparison of AMH alterations. The secondary end points are changes in FSH, E2, and AFC.

Results: Serum AMH level decreased significantly from the baseline (3.86_3.58 ng/mL) to 1 week (1.66_1.92 ng/mL), 3 months (2.06_2.5 ng/mL), and 9 months (1.77_1.76 ng/mL) postoperatively. Those patients with bilateral endometriomas had significantly lower levels of AMH, 1 week, 3 and 9 months after operation. Also, patients older than 38 years had lower postoperative AMH levels. The FSH levels increased significantly from baseline to 3 months postoperatively. The AFC level increased significantly from baseline to 3 months after operation.

Conclusion: The AMH level decreased and the FSH level increased after laparoscopic cystectomy for endometriomas, especially in older patients and those with bilateral cysts. (Fertil Steril_ 2014;101:427–34. _2014 by American Society for Reproductive Medicine.)

Keywords • Laparoscopic cystectomy • Endometrioma • Ovarian reserve

The Effects of Endometrial Injury on Intrauterine Insemination Outcome: A Randomized Clinical Trial

Afsoon Zarei, Saeed Alborzi, Nasrin Dadras, Ghazal Azadi

Department of Obstetrics and Gynecology, Shiraz University of Medical Sciences, Shiraz, Iran

Corresponding author:
Nasrin Dadras,
Department of Obstetrics and Gynecology,
Shiraz University of Medical Sciences,
P. O. Box: 71449-95377, Shiraz, Iran
Tel: +98 71 32279705
Email: dadras.nasrin@gmail.com

Abstract

Background: Implantation is considered as the rate-limiting step in success of assisted reproduction techniques, and intrauterine insemination cycles. It might be affected by ovarian superovulation and endometrial local scratching.

Objective: This study aims to investigate the effect of local endometrial injury on the outcome of IUI cycles.

Methods: In this randomized clinical trial 144 women with unexplained infertility, mild male factor, and mild endometriosis randomly divided into two study groups through block randomization. The patients were randomly assigned to undergo endometrial biopsy between days 6 -8 of the previous menstrual cycle before IUI (n=72, IUI cycles=126) or receive no interventions (n=72, IUI cycles=105).

Results: The pregnancy rate per patient was 17 (23.6%) and 14 (19.4%) in endometrial biopsy and control groups, respectively (P=0.686). The pregnancy rate per cycle was 17/126 (13.5%) and 14/105 (13.3%) in endometrial biopsy and control groups, respectively (P=0.389). The abortion rate was comparable between the two groups (6.9% vs. 9.7%; P=0.764). The ongoing pregnancy rate was found to be comparable between the two study groups, as well (16.7% vs. 9.7%; P=0.325). Endometrial thickness (P=0.609) was comparable between the groups; however ER2R was significantly lower in the endometrial biopsy group (P<0.001).

Conclusion: Application of local endometrial injury in the cycle before the IUI cycles is not associated with increased pregnancy rate per patient and per cycle, decreased abortion, and increased endometrial thickness.

Keywords • 16TInfertility • Female • Endometrial injury • Pregnancy • Intrauterine Insemination (IUI)

Middle East Experience with Transanal Endoscopic Microsurgery (TEM)

Ali Reza Safarpour¹, Seyed Vahid Hosseini¹, Reza Roshanravan¹, Salar Rahimikazerooni¹, Mastoureh Mohammadipour², Ali Saberi², Hossein Shabahang³, Leila Ghahramani¹, Masoumeh Rahimi¹, Zahra Zabangeir¹, Hajar Khazraei¹

¹Colorectal Research Center, Shiraz University of Medical Sciences, Shiraz, Iran;

²Department of Colorectal Surgery, Shiraz University of Medical Sciences, Shiraz, Iran;

³Department of Colorectal Surgery, Mashhad University of Medical Sciences, Mashhad, Iran

Corresponding author:

Salar Rahimikazerooni,
Colorectal Research Center,
Shiraz University of Medical Sciences,
Shiraz, Iran

Tel: +98 71 32306972

Fax: +98 71 32330724

Email: rahimiks@sums.ac.ir
colorectal92@yahoo.com

Abstract

Background: Transanal Endoscopic Microsurgery (TEM) has been a new method of micro invasive surgery for management of special conditions. Big deal of this procedure is avoiding of open abdominal surgeries or better exposure in transanal approaches.

Objectives: The purpose of this study was to present a single institutional experience in Shiraz, Iran regarding the application of Transanal Endoscopic Microsurgery (TEM). To our knowledge this is the first report from the Middle East.

Methods: Between 2009 and 2012, thirty patients underwent TEM in our center. We assessed complications and recurrence rate. Patients with fewer than six months of follow-up were excluded.

Results: Patients included 17 men and 13 women with a mean age of 44.4 years (ranged 17-80). The mean tumor distance from the anal verge was 9.8 cm. One patient with adenomatous polyp experienced recurrence 14 months postoperatively. Regarding procedure-related complications, one case developed hemorrhage and another case fever and infection in the site of operation. Two patients experienced incontinence for about 3 weeks after TEM surgery.

Conclusions: Considering the cultural and religious context of the Middle East, we recommend TEM procedure in specialized centers in this region of the world.

Keywords • Rectal neoplasms • Colorectal surgery • Microsurgery • Endoscopy • Therapeutics

Thalidomide Affects Experimental Endometriosis: A Randomized Controlled Study in the Rat

Afshin Azimirad^{1,2,3}, Saeed Alborzi^{1,3},
Perikala Vijayananda Kumar⁴, Jaleh
Zolghadri³, Afsoon Zarei¹, Zohreh
Tavana¹, Mina Azimirad⁵

¹Laparoscopy Research Center,
Department of Obstetrics and
Gynecology, Shiraz University of Medical
Sciences, Shiraz, Iran;

²Student Research Committee, Shiraz
University of Medical Sciences, Shiraz,
Iran;

³Infertility Research Center, Shiraz
University of Medical Sciences, Shiraz,
Iran;

⁴Department of Pathology, Shiraz
University of Medical Sciences, Shiraz,
Iran;

⁵Shariati Hospital, Tehran University of
Medical Sciences, Tehran, Iran

Abstract

Background: This study aimed to assess the efficacy of thalidomide for treatment of experimental endometriosis.

Methods: This study was a parallel-group, double-blind, stratified, randomized controlled animal trial with 1:1 allocation ratio. Endometriosis was induced experimentally in 23 mature, nulligravid, female Sprague–Dawley rats, weighing approximately 200 g and aged 2 months. A checkpoint surgery was performed 6 weeks later. Then, the rats were randomly allocated into the thalidomide (22 mg/day p.o.) and control (0.5 mL saline 0.9%/day p.o.) groups of nine. After 6 weeks, they were killed. Before each laparotomy, blood for leukocyte and lymphocyte counts and during them, implants for histopathology and peritoneal fluid for interleukin (IL)-6, tumor necrosis factor- α and vascular endothelial growth factor (VEGF)-A concentrations (by enzyme-linked immunoassay) were collected. Allocation and stratified randomization were done using a computer, based on the obtained histopathology scores of the implants of the checkpoint surgery.

Results: The histopathology scores (the main outcome measure) were 2.00 ± 1.55 versus 0.44 ± 1.01 ($P=0.035$). The comparisons of after-treatment counts of leukocytes, lymphocytes, VEGF-A and IL-6 between the two groups were statistically significant.

Conclusion: The results of this study are in favor of therapeutic implication of thalidomide in experimental endometriosis in rats. This is the first time thalidomide has been evaluated on endometriosis in an animal model.

Keywords • Animal model • Endometriosis • Immunology • Randomized controlled trial • Thalidomide

The Effects of Levamisole on Experimental Endometriosis: A Randomized Controlled Trial in a Rat Model

Afshin Azimirad¹, Saeed Alborzi²,
Perikala Vijayananda Kumar³, Afsoon
Zarei², Mina Azimirad⁴

¹Student Research Committee, Infertility Research Center, Laparoscopy Research Center, Shiraz University of Medical Sciences, Shiraz, Iran;

²Infertility Research Center, Laparoscopy Research Center, Shiraz University of Medical Sciences, Shiraz, Iran;

³Department of Pathology, Shiraz University of Medical Sciences, Shiraz, Iran;

⁴Shariati Hospital, Tehran University of Medical Sciences, Tehran, Iran

Corresponding author:

Afshin Azimirad;
Student Research Committee,
Infertility Research Center,
Laparoscopy Research Center,
Shiraz University of Medical Sciences,
Shiraz, Iran

Email: tafshina@gmail.com

Abstract

Background: To assess the effects of levamisole on experimental endometriosis in rats through the histopathology of the implants, the blood leukocyte and lymphocyte counts and the concentrations of interleukin-6, vascular endothelial growth factor-A and tumor necrosis factor-alpha in the peritoneal environment at the three healthy, endometriotic and post-treatment milestones.

Methods: Twenty-two 8-week-old Sprague-Dawley rats with normal estrus cycles were recruited in a prospective, parallel-group, placebo-controlled, double-blind, stratified-randomized animal trial with the equal allocation ratio of 1:1 challenging the efficacy of levamisole. Endometriosis was induced. After 6 weeks, laparotomy was performed to randomly excise one implant for histopathology assessment. Based on the results, they were stratified randomized and allocated (by software) to two groups of nine: levamisole (5 mg/rat/day) or placebo. After 6 weeks, necropsy was done. Two days before each laparotomy, blood samples and during the procedure, peritoneal wash were collected for ELISA.

Results: Seven rats showed success in treatment in the levamisole group, while three did in the other group. The histopathology results descriptively revealed a drop in the levamisole group, which was not meaningful statistically (0.66 ± 1.32 vs. 2.00 ± 1.50 , $P=0.065$). The comparisons of the post-treatment leukocytes and lymphocytes in the groups showed significant differences (11088.88 ± 5869.50 vs. 4677.77 ± 3476.98 , $P=0.008$, and 8588.88 ± 5721.32 vs. 3511.11 ± 2835.24 , $P=0.014$, respectively). The results of the cytokines were mostly, but not completely, in favor of the efficacy of levamisole.

Conclusion: This study indicates a possible successful role for levamisole in the treatment of experimental endometriosis. Further studies to assess the effects of high dose levamisole on endometriosis are recommended.

Keywords • Animal model • Endometriosis • Immunomodulation • Levamisole • Randomized controlled trial • Sprague–Dawley

Evaluation of Mediastinal Width in Supine Chest Radiography and Computed Tomography of the Referred Patients to Shahid Rajaei Trauma Center (Shiraz, Spring 2014)

H. Malek Jamshidi¹, R. Rouhezamin²,
A.R. Shakibafard³, H.R. Abbasi¹,
S. Paydar¹, P. Ravanfar¹, Sh.
Boland-Parvaz¹

¹Trauma Research Center, Shahid Rajaei Trauma, Shiraz University of Medical Sciences, Shiraz, Iran;

²Department of Radiology, Shahid Faghihi Hospital, Shiraz University of Medical Sciences, Shiraz, Iran;

³Department of Radiology, Shahid Rajaei Trauma, Shiraz University of Medical Sciences, Shiraz, Iran

Abstract

Background: Mediastinal widening is a serious radiologic sign in patients with chest trauma, which is caused by potentially life threatening conditions such as traumatic transection of aorta or bleeding from other mediastinal vessels. The gold standard method for diagnosis of the condition is chest CT scan, which is not applicable in many cases due to the high dose of radiation, high-cost and emergency settings. One of the most practical and cost-effective diagnostic methods is supine chest X-ray. In this study, the diagnostic value of supine chest radiography for mediastinal widening is evaluated by comparing the mediastinal width in supine chest X-ray and chest CT scan (gold standard method) in patients with blunt chest trauma.

Methods: In this prospective study, conducted in Rajaei trauma referral center (affiliated with Shiraz University of Medical Sciences), multi-detector chest CT scan was performed for patients with blunt chest trauma, who had abnormal supine chest X-ray or suspicious clinical findings. Mediastinal width was compared in CXR and CT scan in each patient for the determination of accuracy of supine chest X-ray in the diagnosis of mediastinal widening.

Results: The sensitivity, specificity, positive predictive value, and negative predictive value of supine chest radiography were calculated as 16.6%, 97.5%, 57.1%, and 85.5%, respectively.

Conclusion: The results showed that a normal supine chest X-ray could be highly suggestive for exclusion of mediastinal widening. CT scan remains the gold standard diagnostic method in patients with high clinical suspicion of mediastinal widening.

Keywords • Radiography • Mediastinal widening • CT scan • Chest Trauma

Investigating the Satisfaction and Complications after Hemorrhoidopexy Surgery Compared with Hemorrhoidectomy in Patients with Hemorrhoids

M. Mirshahi, M. Fardin-Far, F. Ebrahimi,
Z. Tahmouresi, F. Hosseinzade

Nursing Case Unit, Razavi Hospital,
Mashhad, Iran

Abstract

Background: Hemorrhoidopexy is the treatment of hemorrhoids using stapler device in which hemorrhoid removal is not the goal and if done properly, mucosal or hemorrhoids tissue would not be removed. Given the extent of the effectiveness and benefits of this procedure as well as its impact on reducing side effects in comparison with hemorrhoidectomy, the present study was carried out at Razavi Hospital (Mashhad, Iran) in 2014.

Methods: During this analytical cross sectional study, 30 patients who underwent hemorrhoidopexy and hemorrhoidectomy surgeries at Razavi Hospital were included. The patients, based on case study and interview, were evaluated and divided into two groups; namely the case group (n=20) and the control group (n=10). Data were analyzed by the SPSS software, using Chi-square, one-way analysis of variance and Pearson correlation coefficient methods.

Results and Conclusion: There were no statistically significant differences in bleeding between the groups. The hemorrhoidopexy group was better in terms of pain, infection, activities of daily living (ADL), defecation, and self-reliance.

Keywords • Hemorrhoidopexy • Hemorrhoidectomy • Stapling

Regional Anaesthesia in PCNL

S. Mehrabi

Abstract

Background: Percutaneous lithotripsy is the treatment of choice in Stone burden >2cm, Staghorn stones, Multiple stones, Abnormal renal anatomy, Calyceal diverticulum, Lower pole stones >10 -15 mm and resistant stone (Cystine, brushite, COM).

Many centers prefer General anesthesia for percutaneous nephrolithotomy (PCNL) and believe it has best airway protection in prone position and Allows suspension of respiratory excursions (hold at end expiration). Regional anesthesia (spinal, epidural, unilateral, combined spinal epidural anesthesia) and Local anesthesia with adjunctive intravenous sedation is an option in some patients. The prone position is the most commonly used position for percutaneous endourologic procedures. It is usually combined with general anesthesia. But in high-risk patients, this approach can lead to circulatory and respiratory compromises.

Literature review: Operating on patients candidate for PCNL in a full lateral or supine position will minimize the hemodynamic and respiratory risks and—if combined with spinal anesthesia will increase patient satisfaction (El-Husseiny, et al. Journal of Endourology. 2009).

Another study compared PCNL under combined spinal-epidural anesthesia (CSEA) with PCNL under general anesthesia (GA), where the researcher conclude that PCNL under CSEA is as effective and safe as PCNL under GA. Patients who undergo PCNL under CSEA require a lower analgesic dose and have a shorter hospital stay (Singh et al *Urol Int* 2011).

Also, Kuzgunbay conclude that combined spinal-regional anesthesia is a feasible technique in PCNL operations (Kuzgunbay *endouro J* 2009). In one study we evaluated the impact of spinal anesthesia on intraoperative and postoperative outcome in patients undergoing PCNL. Our data showed that spinal anesthesia combined with sedation could be an attractive method of anesthesia for PCNL with trivial pain and blood loss and without major complications. Thus, it will be a good alternative for performing PCNL in adult patients (Mehrabi et al, *Urol J.* 2010; 7).

In another study we compared the efficacy and complications of spinal anesthesia versus general anesthesia in percutaneous nephrolithotomy.

Spinal anesthesia was done by injecting bupivacaine and fentanyl in spinal space L4 in sitting position. Although Intraoperative hypotension, postoperative headache and lower back pain in the spinal group were more than in the general group, but all of them were minor. No neurologic complications were observed in either group (Mehrabi et al, accepted for publish *Urol J* 2012). In our study the need for narcotic drugs in the operative day (D0) in the general group was 12.4±3.1, and in the spinal group it was 7.8±2.3 milligrams equivalent to

Department of Urology, Yasuj University
of Medical sciences, Yasuj, Iran

morphine sulphate (P=0.03).

Cost of anesthesia: Martin S et al compared the costs of regional anesthesia with general anesthesia in orthopedic and trauma patients. They found that costs of spinal anesthesia in comparison to general anesthesia were between 5 to 19 percent according to time of operation. Also Christopher G et al (2011) found that costs of spinal anesthesia has about 40 % less than general anesthesia in orthopedic surgeries. Also, in our study the cost of spinal anesthesia was significantly lower than general anesthesia.

Conclusion: Spinal anesthesia is a safe and low risk technique with suitable efficacy and costs in comparison to general anesthesia for PCNL operation in adult patients with kidney and upper ureteral stones.

The Prevalence of Difficult Intubation in Obese Patients who Performed a Laparoscopic Gastric Sleeve Surgery

Ali Karami¹, Zeinabsadat Fattahisaravi¹,
Malak Ali²

Abstract

Background: Difficult intubation in morbid obese patient was always a challenge for anesthesiologists in all parts of the world. However, there are no established predictors for the addressing of difficult intubation in obese patients. The aim of this study is to determine the prevalence and risk factors associated with difficult intubation in obese patients who underwent sleeve gastrectomy

Methods: 402 anesthetic sheets of morbid obese patients who underwent sleeve gastrectomy from 2012 to 2014 were evaluated. The patients' intubations were carried out by fiberoptic bronchoscopy and sheets with incomplete data were excluded. All the patients had BMI more than 35 and 3 times anesthesiologist attempt of intubation were defined as difficult intubations. Difficult intubation was predictable in patients with abnormal thyromental distance, Mallampati class 4, limited jaw mobility and history of difficult direct laryngoscopy or fiberoptic intubation. All surgeries were performed in Shahid Faghihi hospital and Mother and child sub specialized hospital, Shiraz, Iran.

Result: There was one patient in which intubation failed and the operation was postponed. The prevalence of difficult intubation is higher in morbidly obese patients in comparison to the normal population. In this study, we have shown anesthesiologists anticipated 4.2% of difficult intubation in the population we selected. BMI > 40, short neck measuring less than 6 cm (anatomical and functional), upper chest wall bulging, airway size decrement due to increased amounts of adipose tissue in oral and pharyngeal tissues lead to difficult intubation in 58.8% of patients who had difficult intubation. Increased Mallampati class which was considered to be more than class 2 in this study lead to difficult intubation in 82.4% of patients who had difficult intubation. While for patients who had limited jaw movement the Odds Ratio was 6.66 which means that the chance of developing with difficult intubation in patients with limited motion of jaw is 6.66 times more than the patients who had normal jaw motion.

Conclusion: The prevalence of difficult intubation in bariatric surgeries seems greater than that of the normal population. Anesthesiologists need to pay more attention to some factors such as BMI, neck and chest anatomy, and airway evaluation. and has special experience in airway management and difficult intubation in bariatric surgery.

¹Shiraz Anesthesiology and Critical Care Research Center, Shiraz University of Medical Sciences Shiraz, Iran;
²Medical Student, Shiraz University of Medical Sciences, Shiraz, Iran

Comparing the Effect of Spreader Graft and Mattress Suture Technique on Rhinoplasty in Patients with Nasal Hump Smaller Than 3mm

Zahra Sarafraz¹, Mohammad Hossein Azaraein², Saeid Atighechi³

¹Resident of Otolaryngology, Department of Otolaryngology, Shahid Sadoughi University of Medical Sciences, Yazd, Iran;

²Student Research Committee, Shahid Sadoughi University of Medical Sciences, Yazd, Iran;

³Assistant professor of Otolaryngology, Department of Otolaryngology, Shahid Sadoughi University of Medical Sciences, Yazd, Iran

Abstract

Background: Rhinoplasty is a common plastic surgery potentially has some complications such as postoperative deformities and breathing problems. A humpy nose is one of the main reasons for rhinoplasty. Nasal valve collapse may occur after nasal hump removal. Spreader graft is essential after more than 3mm nasal hump removal. But the value of this graft is not recognized for patients with nasal hump smaller than 3mm. Mattress suture is another technique for widening the nasal valve angle.

This study compares the effects of spreader graft and mattress suture technique on postoperative deformity and nasal valve patency in patients with nasal hump smaller than 3 mm.

Methods: Clinical trial study was carried out in rhinoplasty patients with two different techniques. This study was performed in the Shahid Sadoughi Hospital, Yazd, between 2012 and 2013. Patients' data were gathered by subjective (questionnaire) and objective (clinical examination, rhinomanometry and photography) methods before and after rhinoplasty, and analyzed using *t* test by SPSS version 18.

Results: In this study, 50 patients were enrolled. In the spreader graft group, 19 men (76%) and 6 women (24%) and in the mattress suture group 17 men (68%) and 8 women (32%) participated. Statistically, nasal obstruction had no significant difference before and after rhinoplasty and no significant difference was observed between surgical techniques ($P>0.05$). Mild inverted V deformity was seen in 2 patients in the spreader graft group.

Conclusion: In this study the results of nasal valve patency of two techniques were similar. Because of several considerations in the spreader graft technique such as secondary deformities (supratip bulging) and the need for septoplasty even in patients without septal deviation that causes longer surgical duration, excessive blood loss, it is recommended to use mattress suture in patients with nasal hump smaller than 3mm.

Keywords • Rhinoplasty • Spreader graft • Mattress suture

Entrapment and Cutting of Nasogastric Tube Instapler Line During Laparoscopic Sleeve Gastrectomy

Amini Masoud, Chabi Mehrsa

Abstract

The incidence of obesity is steadily rising in recent years. Obesity, should be controlled by physical exercise and changes in dietary habits; and surgical treatment is indicated when clinical measures are inefficient. Recently laparoscopic sleeve gastrectomy (LSG) is gaining popularity for the treatment of morbid obesity. It is a simple, low-cost procedure resulting in significant weight loss within a short period of time. Last but not the least LSG is a safe procedure with a low complication rate. Although it is important to note that the most significant complications are staple-line bleeding, stricture, and staple-line leak.

A rare complication of laparoscopic sleeve gastrectomy is introduced in the following medical case. A 39 year old diabetes woman who suffered from obesity underwent laparoscopic sleeve gastrectomy. After extraction of the specimen a foreign body was palpated which was found to be a part of nasogastric tube. The entrapped part of nasogastric tube in stapler line of remained part of stomach was removed with a small normal surrounding tissue, the nasogastric tube was pulled up, the created defect was repaired in one layer with endostich. drain was inserted. Leak test was performed intra operative and repeated one day later which was negative.

The purpose of this paper is to avoid the above complication. It is appropriate that anesthesiologist technicians do not change during a solitary operation. Moreover we can eliminate the nasogastric tube and just use the standard sizer for gastric decompression and then for leak test.

Keywords • Sleeve gastrectomy • Nasogastric tube • Complication • Obesity • Surgery

Laparoscopy Research Center, Shiraz
University of Medical Sciences, Shiraz,
Iran

Experience with 100 Cases of Pituitary Adenomectomy

A. Saffarian

Department of Neurosurgery,
Shiraz University of Medical Sciences,
Shiraz, Iran

Abstract

Background: Endoscopic approach for pituitary adenomectomy as a less invasive procedure is accepted as a substitute for traditional microscopic trans-septal approach. We therefore used this approach for surgical treatment of 100 cases of pituitary adenoma during the last two years (2013 -2015) in Chamran Hospital, Shiraz, Iran.

Methods: 100 cases of pituitary adenoma candidates for surgical resection were selected between 2013 and 2015. In the supine position, under general anesthesia, and by using endoscope, anterior sphenoidotomy was performed by ENT man, sellar floor drilling and tumor exposure and resection, performed using straight and angled endoscope.

Results: Endoscope provided a more closer vision to vital anatomic structures such as carotid artery and optic nerve and also a more wider view for this structures accompanied with panoramic vision comparing to microscopic trans-septal approach. Less trauma to soft tissue also was another benefit of the endoscopic approach.

Conclusion: Due to panoramic, wide, closer and angled vision (causing potentially less morbid complications) provided by endoscope and also less soft tissue injury, it seems that this approach could be accepted as a better substitute for the traditional microscopic trans-septal approach.

Evaluating the Function of Laparoscopic Splenectomy Starting From Splenic Hill vs. Short Gastric Vessels

Abbas Abdollahi¹, Alireza Tavassoli²,
Hossein Shabahang³, Asieh Sadat
Fattahi⁴, Zahra Rajai⁵

¹Associate Professor of Surgery, Surgical Oncology Research Center, Imam Reza Hospital, Faculty of Medicine, Mashhad University of Medical Sciences, Mashhad, Iran;

²Professor of General Surgery, Endoscopic & Minimally Invasive Surgery Research Center, Ghaem Hospital, Faculty of Medicine, Mashhad University of Medical Sciences, Mashhad, Iran;

³Associate Professor of Surgery, Endoscopic & Minimally Invasive Surgery Research Center, Ghaem Hospital, Faculty of Medicine, Mashhad University of Medical Sciences, Mashhad, Iran;

⁴Associate Professor of Surgery, Endoscopic & Minimally Invasive Surgery Research Center, Ghaem Hospital, Faculty of Medicine, Mashhad University of Medical Sciences, Mashhad, Iran;

⁵Endoscopic & Minimally Invasive Surgery Research Center, Ghaem Hospital, Faculty of Medicine, Mashhad University of Medical Sciences, Mashhad, Iran

Corresponding author:

Zahra Rajai,
Endoscopic & Minimally Invasive Surgery
Research Center, Ghaem Hospital,
Faculty of Medicine, Mashhad University
of Medical Sciences, Mashhad, Iran

Tel: +98 0915316-6441

Fax: +98 511 8409612

Email: emis@mums.ac.ir

Abstract

Background: Recently, advantages in medical technology have led to increase in minimally invasive surgeries. The surgical procedure of laparoscopic splenectomy (LS) using different methods of minimally invasive surgery has been well performed. Starting the operation by dissecting the hilum vessels is the most common technique in this surgery. In this study, a new approach is provided to perform this surgery by starting the operation by ligating the short gastric vessels. So, we face the blood-free surgical field which needs lesser suction times, more speed and a better exposure of the area.

Methods: 39 patients who were candidates for laparoscopic splenectomy with a mean age of 41.36 ± 19.5 years (68% female and 32% male) were divided into two random groups; the short gastric and hilar groups. We applied a modified approach in which we start the laparoscopic splenectomy with total ligation of short gastric vessels via LigaSure system in the short gastric group while normal lateral approach was applied among patients of the hilar group. Data was analyzed using SPSS statistical software version 16.5. Due to low preoperative platelet levels in the short gastric group (206×10^9 vs. 303×10^9), the short gastric group needed more platelet transfusion (7.7 vs. 2.18) compared with the hilar group. This finding reveals more serious disorder in the short gastric group.

Results: Our modified approach in the short gastric group was associated with shorter operative time (130 vs. 163 min), shorter hospital stay (18.3 vs. 19.6 days), higher postoperative hemoglobin level (11.4 vs. 10.7) and less transfused packed cell (3.6 vs. 3.8) and more surgeon satisfaction compared to the Hilar group.

Conclusion: We strongly recommend using of this modified approach for laparoscopic splenectomy due to its shorter operative time, shorter hospital stay, higher postoperative hemoglobin level, less transfused packed cell and more surgeon satisfaction compared to the normal lateral approach. Using LigaSure vessel sealing system during LS is safe and time saving and also helps the surgeon to control bleeding in the operation field.

Keywords • Splenectomy • Laparoscopy • Short gastric vessels
• Splenic hilum

Laparoscopic Gastric Plication versus Mini-Gastric Bypass Surgery in The Treatment Of Morbid Obesity: A Randomized Clinical Trial

S. Darabi, M. Talebpour, A. Zeinoddini,
R. Heidari

Abstract

Background: Laparoscopic gastric plication (LGP) is emerging as a safe and effective bariatric procedure. However, there are no reports on the comparison between the efficacy and complications of LGP and laparoscopic mini-gastric bypass (LMGB), which is still an investigational bariatric procedure. The objective of this study was to compare safety and efficacy of LGP and LMGB in the treatment of morbid obesity in a one-year follow-up study.

Methods: Forty patients who met the National Institute of Health criteria were randomly assigned to receive either LGP (n=20) or LMGB (n=20) by a block randomization method. Early and late complications, body mass index (BMI), excess weight loss, and obesity-related co-morbidities were determined during the 1-year follow-up.

Results: Operative time and mean length of hospitalization were shorter in the LGP group (71.0 minutes versus 125.0 minutes, $P<0.001$, and 1.6 days versus 5.2 days; $P<0.001$, respectively). The mean percentage of excess weight loss (%EWL) at 12 months follow-up was 66.9% in the LMGB group and 60.8% in the LGP group ($P=0.34$). Improvement was observed in all co-morbidities in both groups, with the exception of hyperlipidemia, which remained unresolved in 4 patients. Lower incidence of iron deficiency occurred in the LGP group ($P=0.035$). Re-hospitalization and reoperation were not required in any cases. Considering the cost of instruments used in the LMGB procedure and operative time, LGP saved approximately \$2,500 per case compared with LMGB.

Conclusion: Both LGP and LMGB are effective weight loss procedures. LGP proved to be a simpler and less costly procedure compared with LMGB with a lower risk of iron deficiency during a 1-year follow-up study.

Minimally Invasive Surgery Aspect: Comparative Advantage

F. Vizeshfar

PhD Candidate of Nursing Education
Department of Nursing, School of
Nursing and Midwifery, Shiraz University
of Medical Sciences, Shiraz, Iran

Abstract

Background: Minimally invasive techniques are available in most surgical specialties, including operations on the abdomen, chest, pelvis and spine. Minimally invasive surgery (MIS) employs new technologies to perform operations through several small incisions in the skin. A camera, or videoscope, and specialized instruments are inserted through these tiny openings, eliminating the need for a large, conventional incision.

Methods: A search of Medline, Science Direct and Cochrane Library was conducted to retrieve literature published from January 2010 until August 2014 and the related articles were analyzed.

Results: These findings, along with the documented benefits of less blood loss and less operative time, and a shorter length of hospital stay make MIS more appealing compared to the open approach. Nursing interventions in this method that decrease pain, stress, and mood disturbance, and are known to improve immune status—such as massage relaxation therapy and biofeedback, and improve the quality of life.

Conclusion: Now that a significant amount of data has emerged on the safety and efficacy of MICS across a range of surgical operations, there is evidence to support the widespread adaptation of such techniques. In the future, there will likely be a greater request for MIS approaches by patients seeking surgical options with reduced surgical trauma that allow for a faster return to normal activities and improved quality of life.

Symptomatic Simple Renal Cyst: Aspiration or Laparoscopic Excision?

M. M. Hosseini, A.R. Aminsharifi, A.R. Haghpanah, A. Farokhi

Laparoscopy Research Center, Shiraz
University of Medical Sciences, Shiraz,
Iran

Abstract

Background: Simple renal cyst is a benign disease that may need intervention when it becomes symptomatic. Treatment options include aspiration and injection of sclerosing agents or excision.

Our objective was to evaluate and compare the efficacy and safety of aspiration/injection and laparoscopic excision in the management of the symptomatic simple renal cyst.

Methods: Between September 2007 and December 2014, a total of 117 patients (69 women, 48 men) were treated for symptomatic simple renal cyst. The mean patient age was 45 years (27 to 68), and mean cyst diameter was 66 mm (50-102). They were randomly assigned into two groups. Group A (n=54) underwent aspiration and ethanol injection and group B (n=63) underwent laparoscopic excision. All cases were followed for post-operation pain, fever, infection, analgesic requirement, and recurrence.

Results: After the procedure patients were followed 3 days for early complications (fever, pain, infection), and then on 6, 12, 24, and 36 weeks ultrasound was done to check for any recurrence of disease. Early complications were more common in group B (32 vs. 16), but the recurrence rate was higher in group A (14 vs. 6).

Conclusion: Symptomatic renal cysts are managed better with excision than aspiration, however, it requires hospitalization, anesthesia and early post-op analgesic administration.

The Comparison of Sonohystrogram and Hystroscopy in Menopausal Women with Abnormal Endometrium

Maryam Kasraeian, Homeira Vafaei,
Nasrin Asadi

Maternal-Fetal Medicine Research
Center, Shiraz University of Medical
Sciences, Shiraz, Iran

Abstract

Background: Our objective was to investigate whether in menopausal women referring with abnormal endometrium, performing sonohysterogram before diagnostic hysteroscopy is helpful.

Methods: A prospective study was performed on menopausal patients who required hysteroscopy because of vaginal bleeding or abnormal endometrium assessed in sonography. Before hysteroscopy, patients underwent sonohysterogram to evaluate the endometrium. Age, the reason of referral, the diagnosis by ultrasound, sonohysterogram and hysteroscopy, result of pathology, the cost, pain, and stress were investigated.

Results: Sixty five menopausal women underwent diagnostic hysteroscopy in one year. The mean age was 55 ± 6 years. The reason of referral was: 57% due to abnormal endometrium in ultrasound, and 43% for abnormal vaginal bleeding or spotting. Fifty nine patients underwent sonohysterogram before hysteroscopy. 82% of sonohysterogram and hysteroscopy results were compatible. By sonohysterogram, the main lesion which was not detected was proliferative endometrium (60%). In the pathologic results, fifty two patients had proliferative endometrium, 44 patients had endometrial polyp, 12 patients had atrophic and 2 patients had malignancy of endometrium.

Conclusion: The primary outcome showed performing sonohystrogram before hysteroscopy for menopausal women for the evaluation of the endometrium is neither helpful nor cost effective.

Keywords • Sonohystrogram • Menopausal • Hystroscopy

Outcome of Laparoscopic Splenectomy for Hematologic Disorders

Abbas Abdollahi¹, Asieh Sadat Fattahi²,
Alireza Tavassoli², Hossein Rahimi²,
Iman Abdollahi²

¹Surgical Oncology Research
Center, Imam Reza Hospital, Faculty of
Medicine, Mashhad University of Medical
Sciences, Mashhad, Iran;

²Endoscopic&Minimally Invasive Surgery
Research Center, Ghaem Hospital,
Faculty of Medicine, Mashhad University
of Medical Sciences, Mashhad ,Iran;

Corresponding author:

Abbas Abdollahi,
Surgical Oncology Research
Center, Imam Reza Hospital, Faculty of
Medicine, Mashhad University of Medical
Sciences, Mashhad, Iran

Tel/Fax: +98 511 8409612

Email: emis@mums.ac.ir

Abstract

Background: Doing laparoscopic splenectomy(LS) is increasing for hematologic disorders. Although feasibility and safety of this method has been discussed, less data available, concerning the results base on the hematologic indications. We report our experience with (LS), outcome and complications.

Methods: This was a retrospective study we include all laparoscopic splenectomies between 2006 to 2011 for nontraumatic disorders in Ghaem hospital. Mashhad, Iran

We reviewed patients' demographic data, indication for operation, morbidity, mortality and clinical outcomes.

Results: 44 patients enrolled in the study. The mean age was 30 years old. Indications for surgery were idiopathic thrombocytopenic purpura (ITP) in 37 patients and other hematologic disorders in 7 patients. 75% were female and 25% were male. Median operating time was 121 minute.

Median hospital stay was 3.1 days. Mean spleen weight was 201 gr. We had no mortality.

We had 1 conversion to open procedure, 1 splenic vein thrombosis,1 patients needed reoperation.

Our study showed 83.3% complete response in ITP patients and 88.6% for other hematologic disorders.

Conclusion: Laparoscopic splenectomy is safe and effective method in hematologic disease such as ITP with low complications and is a good alternative to open procedure with short hospital stay.

Keywords • Splenectomy • Laparoscopy • Hematologic disorder

Predictors of Weight Loss After Laparoscopic Gastric Plication: A Prospective Study

R. Heidari, A. Zeinoddini, M. Talebpour,
A. Talebpour

Laparoscopic Ward, Sina Hospital,
Tehran University of Medical Sciences,
Tehran, Iran

Abstract

Background: Laparoscopic gastric plication (LGP) is a bariatric procedure for the treatment of morbid obesity that has recently increased in popularity. Herein, the predictors of weight loss following LGP are investigated.

Methods: This prospective study was performed on cases by a single surgeon between 2000 and 2011. The association between nine independent variables and ideal weight loss (percentage of excess weight loss [%EWL] $\geq 80\%$) at 24 months postoperatively was assessed in 330 patients who underwent LGP. The studied variables were as follows: age at surgery, gender, preoperative body mass index, preoperative co-morbidities, marital status (single versus married), employment status (employed versus unemployed), family support in helping the patient to engage in physical activities and continue on a healthy diet (never/a little versus sometimes/a lot), the experience of pain or gastroesophageal reflux during or after eating (yes or no), and participation in support groups following LGP (yes or no).

Results: Ideal weight loss (%EWL $\geq 80\%$) was achieved in 60 patients, and %EWL $< 80\%$ (suboptimal weight loss) occurred in 270 patients. Being single, female, and of younger age and participation in group meetings were significantly associated with experiencing ideal weight loss at 24 months, postoperatively. However, no significant difference was observed between the two groups in terms of preoperative body mass index, co-morbidities, employment, a relative being a coworker, and the experience of pain or gastroesophageal reflux after eating.

Conclusion: This study identified predictor factors positively associated with ideal weight loss. These results would aid surgeons in better patient selection and identification of patients requiring more careful follow-up. In addition, it provides patients with more realistic assessment of potential outcome of the procedure.

Propranolol has a Preventive Effect on Bleeding during Gastric Bypass Surgery; A Multi-Center Survey

Abdolreza Pazouki

Abstract

Background: Obesity is a prevalent disease in the developed and developing countries, which grossly affects the lifestyle. Bariatric surgery is nowadays widely used for the treatment of severe obesity to reduce its mortality and morbidity.

Although the performed surgeries extensively subside patient's comorbidities, it may accompany various complications during the operation. One of the most important complications during surgery is bleeding, which increases the surgical time and may cause reoperation. Propranolol has been proven effective in other surgeries, but not in bariatric surgery.

Method: 82 patients were randomized to receive 40 mg propranolol or placebo twice daily, two weeks before the surgery in a double-blind RCT, in which only the assigned nurse knew the difference. Then, all patients underwent gastric bypass surgery. The bleeding sites, which needed hemostasis and the bleeding volume, were evaluated during the operation.

Results: Among the patients, 24.4% were male and 75.6 females. Mean BMI in the case group was 44.1 ± 4.2 and 44.07 ± 3.5 in the control group with no statistical difference. Mean bleeding spots were 2.13 ± 0.84 in the case and 2.5 ± 1.03 in the control groups with no significant statistical difference. The required time for hemostasis was 7.96 ± 3.85 in the case and 9.67 ± 5.01 in the control groups with no statistical difference. The vessels from artery were in 96.3% and 3.7% from veins with no difference between the groups. The mean hemoglobin was 13.6 ± 1.8 before and 12.9 ± 1.5 after the surgery with no difference between the two groups.

Conclusion: As the results show, propranolol can be effective in reducing the bleeding parameters in gastric bypass surgery in this survey.

Minimally Invasive Surgery Research
Center, Iran University of Medical
Sciences, Tehran, Iran

Evaluation of Combined Electro Cutter with Cold Knife in the Intractable Anterior Urethral Stricture

Ali Asghar Ketabchi

Abstract

Background: Sachse cold knife is conventionally used for optical internal urethrotomy for management of urethral strictures. In this procedure, the complications and recurrent rates are relatively high. Therefore, we now suggest combined electro cutter and cold knife as a successful alternative in the management of intractable anterior urethral strictures.

Methods: Included in this prospective study were 87 male patients aged 18 or over, diagnosed with intractable urethral stricture (≥ 2 time recurrence) and admitted for internal optical urethrotomy between May 2010 and June 2013. The patients were randomized into two groups by using computer generated random numbers. In group A (electro cutter - cold knife group=45), internal urethrotomy was done with combined electro cutter with cold knife and in group B (Cold knife group=42), Sachse cold knife was used. Patients were followed up for 6 months after surgery in outpatient department on 15, 30 and 180 post-operative days. At each follow up visit, physical examination and uroflowmetry were performed along with noting any patient complaints.

Results: The success rates in group A and B were 46.6% (21 out of 45 patients) and 23.80% (10 out of 42 patients) respectively ($P < 0.05$). Complications were seen in 11% of patients in group A and 45% of those in group B. Peak flow rates (PFR) were compared between the two groups on each follow up. At 180 days (6 month interval) the difference between the mean of PFR for electro cutter – cold knife group and Cold knife group was statistically significant ($P < 0.01$).

Conclusion: combined electro cutter with cold knife urethrotomy modality are effective than conventional cold knife urethrotomy in providing immediate relief in recurrent urethral strictures and had lesser complications in patients with intractable and recurrent urethral strictures.

Keywords • Urethrotomy • Intractable • Urethral stricture • Electro cutter

Urologist, Kerman Medical Sciences
University, Kerman, Iran
Tel: +98 34 32114348
Fax: +98 34 32239188
Email: dr.ketabchi@gmail.com

Flank Position Ultrasonography Guided Percutaneous Nephrolithotomy (PCNL) for Challenging Multiple Renal Stones: As an Attractive Alternative Technique

Samad Zare, Roya Rahimian

Abstract

Background: To evaluate the safety and efficacy of flank position ultrasonography-guided PCNL for the management of multiple renal calculi in challenging situations.

Methods: Between October 2013 and January 2015, a total of 150 patients (79 men, 71 women) with challenging renal stone underwent ultrasonography-guided PCNL in flank position. Patients with uncontrolled coagulopathy and active urinary tract infection were excluded from the study. The intra and post operative surgical outcomes were evaluated.

Results: The mean age of the patients was 41.0 ± 12.4 years. Mean stone size was 3.9 ± 1.2 cm. Mean access and operative time were 12.1 ± 3.1 and 75 ± 12.2 minutes respectively. Superior calyx was selected for access in 47% of patients. The patients were categorized in following groups; history of more than one section previously open stone surgery (40%), horseshoe kidney (8%), major lumbosacral deformity (18%), failed standard PCNL (18%), children under 10 years old (10%), and pregnant (6%). The primary complete stone free rate was 68%, and after ancillary procedures (URS, SWL), the figure was raised to 84%.

The mean hemoglobin drop was 2.1 ± 1.0 gr/dl. Transfusion was needed in 6 patients. Significant prolonged or delay hemorrhage was not shown in any cases. Pneumothorax was detected in one patient who was managed with chest tube insertion. Visceral or solid abdominal organ injury did not occur.

Conclusion: With some attention, the outcomes of ultrasonography-guided PCNL for challenging renal stones are comparable with standard fluoroscopic approach, and in some situations, flank position contain benefits rather than the standard prone position.

Department of Urology, Shahid
Rahnemon Hospital, Shahid Sadoughi
University of Medical Sciences, Yazd,
Iran

Reporting of Laparoscopic Colectomy Results in Patients with Colorectal Cancer Operated in a 6-Month Period in Firoozgar University Hospital, Tehran, Mar To Oct 2014

Saeed Safari¹, Alireza Sadr², Amir Saraei², Mahdi Alemrajabi³

Abstract

Background: Laparoscopic surgery has become a well known technique for the treatment of colorectal cancers in many centers worldwide. Fortunately, we see that the rate of using this technique for colorectal cancers in Iran's referral centers has increased significantly in recent years.

Methods: The aim of this descriptive study was to present the preliminary data of 33 cases of laparoscopic colectomy for the treatment of cancer during a 6-month period in Firoozgar University Hospital.

Results: The mean age of the patients was 53 (22-74) years old. 15 patients (45%) were male and 18 (55%) were female. Anatomically, 14 cases (42%) had cancer in the rectum and 19 cases (58%) had cancer in their colon; colon cancers were located in the right side in 7 cases (21%), in the left side in 11 cases (33%) and one case had 2 simultaneous cancers in the transverse and sigmoid colons (3%).

The mean time of surgery was 140 (105-195) minutes and a conversion to open surgery occurred in two (6%) patients. The average length of hospital stay was 4.6 days post-operatively and 3 patients (9%) were re-hospitalized in the first 14 days after surgery. Three patients underwent re-operation.

All patients had pathologically confirmed adenocarcinoma, 45% of them were well-differentiated (15 cases).

The mean number of lymph nodes resected was 10.4 (5.6 for rectal cancers and 14 for colon cancers). Peri-neural invasion and peri-vascular invasions were seen in 12% (4 cases) and 9% (3 cases) of patients respectively. Except for the patients in stage T4, all other cases had free margins of resection.

Regarding to TNM staging system, 6 patients (18%) were in stage 1 of disease, 7 patients (21%) were in stage 2, 13 (39%) were in stage 3 and 4 patients (12%) were in stage 4. Complete response to neoadjuvant therapy was seen in 3 patients (21%) of rectal cancers.

Complications of surgery were bleeding in one patient (3%), leak of anastomosis in 2 patients (6%), incisional hernia in 2 cases (6%) and wound infection in 3 patients (9%). There were no complications related to nerve or ureter injuries in this case series.

The mortality rate was 3% (1 case) secondary to leakage of anastomosis in one patient with rectal cancer. In the 7-month follow-up period we found one death in another patient due to the progression of his cancer.

Conclusion: The laparoscopic approach could be an appropriate method for surgical treatment of colorectal malignancies.

¹General Surgeon, Iran University of Medical Sciences, Iran;

²Resident of General Surgery, Iran University of Medical Sciences, Iran;

³Colorectal Surgeon, Iran University of Medical Sciences, Iran

Is There a Double Gall Bladder? A Case Report with Opposite Findings

Masood Amini^{1,2}, Hadi Hadavi^{1,2},
Masood Sepehrimanesh³, Masoumeh
Kherad²

¹Laparoscopy Research Center, Shiraz
University of Medical Sciences, Shiraz,
Iran;

²Obesity Specialized Clinic, Ghadir
Mother and Child Subspecialized
Hospital, Shiraz University of Medical
Sciences, Shiraz, Iran;

³Gastroenterohepatology Research
Center, Shiraz University of Medical
Sciences, Shiraz, Iran

Abstract

Cystic duct and gallbladder (GB) shows high different anatomical variations. However, report about existence of another GB after cholecystectomy is scarce. Duplication of gallbladder with two separate cavities and two separate cystic ducts has an incidence of about one in every 4000 persons. A 31-year-old Iranian woman underwent laparoscopic cholecystectomy due to symptomatic gall stone, uneventfully. About 5 months later, she referred to gynecologist for her gynecological problems. Her doctor ordered for abdominopelvic sonography which showed 3-4 gall stones in GB, each measuring about 4-6 mm and some lobulated hypoechoic materials. For better diagnosis and differentiation, the operation films were reviewed with no abnormal finding, so MRI of the abdomen without and with gadolinium was performed. A round cystic lesion measuring about 5 cm in the GB bed at the site of cholecystectomy was appeared. A few filling defects were also demonstrated in it which can be represented of sludge inside the bile collection. She was followed for 5 months and remained asymptomatic. The collection was absorbed completely without any complications in follow up sonography. Our evidences and experiences cleared that this is most probably a bile collection from Luschka. This collection may be biloma contained some sludge. Our findings and conclusion represented a Luschka which lead to bile leak and creating this structure. However, we advise to record and review the operation films, and perform abdominal MRI or CT in similar cases before any surgical decision.

Keywords • Double gall bladder • Sonography • Cholecystectomy
• Laparoscopy • Luschka • Biloma