

Original Article

Peripapillary nerve fiber layer thickness changes after macular photocoagulation for clinically significant diabetic macular edema



Khalil Ghasemi Falavarjani*, Ali Khoshmadi, Naveed Nilforushan

Abstract

Purpose: To evaluate the effect of macular photocoagulation (MPC) on peripapillary nerve fiber layer (PNFL) thickness measurement in patients with clinically significant diabetic macular edema (CSME).

Methods: This study was a prospective interventional case series. Patients with CSME underwent MPC. Optical coherence tomography (OCT) was used to measure the PNFL and central macular thicknesses before and 3 months after MPC.

Results: Thirty-three eyes of 25 patients with a mean age of 59.4 ± 7.2 years were included. There was no statistically significant difference between pre- and post-MPC mean best corrected visual acuity (0.35 ± 0.29 and 0.40 ± 0.23 LogMAR, respectively, $P = 0.2$). Mean baseline and 3 months central macular subfield thickness was 305.9 ± 90.7 and 317.5 ± 112.4 microns, respectively ($P = 0.1$). Peripapillary nerve fiber layer thickness was 105.7 ± 10.0 before and 106.1 ± 9.9 three months after MPC ($P = 0.7$). No significant differences were found between pre and post MPC measurements in temporal, nasal, inferior and superior nerve fiber layer thickness in each quadrant around optic nerve head ($P > 0.05$).

Conclusions: Macular photocoagulation has no statistically significant effect on PNFL thickness measurements in patients with CSME.

Keywords: Macular photocoagulation, Clinically significant macular edema, Nerve fiber layer

© 2014 The Authors. Production and hosting by Elsevier B.V. on behalf of Saudi Ophthalmological Society, King Saud University. This is an open access article under the CC BY-NC-ND license (<http://creativecommons.org/licenses/by-nc-nd/3.0/>).
<http://dx.doi.org/10.1016/j.sjopt.2014.10.002>

Introduction

Macular edema is one of the most common causes of visual impairment in patients with diabetic retinopathy.¹ Early Treatment Diabetic Retinopathy Study (ETDRS) demonstrated the benefit of macular photocoagulation (MPC) treatment on reducing the risk of moderate visual loss in eyes with clinically significant macular edema (CSME).² Although significant changes have occurred in the management of diabetic retinopathy, recent studies have shown the efficacy of focal/grid laser alone in eyes with non-center involved CSME or as an adjunct to intravitreal pharmacotherapy.^{3–5}

Despite beneficial effect of MPC, it may be associated with considerable side effects, such as atrophic scarring causing paracentral dense scotomas, generalized loss of the visual field sensitivity, choroidal neovascularization, and subfoveal fibrosis.^{6–11} Significant changes have been reported in the visual field of patients with CSME after MPC.^{9–11} Since testing the visual field is one of the main parts of the diagnosis and management of glaucoma, the field defects after MPC may erroneously affect the decisions.

Optical coherence tomography (OCT) has become an integral part of the diagnosis and management of glaucoma and retinal disease. Measurement of peripapillary nerve fiber

Received 14 August 2014; accepted 1 October 2014; available online 8 October 2014.

Eye Research Center, Rassoul Akram Hospital, Iran University of Medical Sciences, Tehran, Iran

* Corresponding author at: Eye Research Center, Rassoul Akram Hospital, Sattarkhan-Niyesh Street, Tehran 14456-13131, Iran. Tel.: +98 9121725850; fax: +98 2166509162.

e-mail address: drghasemi@yahoo.com (K.G. Falavarjani).



Peer review under responsibility of Saudi Ophthalmological Society, King Saud University



Production and hosting by Elsevier

Access this article online:
www.saudiophthaljournal.com
www.sciencedirect.com

layer (PNFL) thickness can detect objectively and noninvasively glaucomatous nerve changes and disease progression.¹²⁻¹⁴ Although previous studies using OCT reported the changes in the PNFL thickness measurements in eyes with diabetic retinopathy with and without CSME, the effect of MPC on PNFL thickness has not been evaluated.^{15,16} The aim of this study was to evaluate the effect of MPC on PNFL thickness measurements in patients with CSME.

Subjects and methods

In this prospective interventional case series, from May to October 2012, all patients with clinically significant diabetic macular edema (according to EDTRS classification)² who underwent MPC were included. We considered MPC for eyes with non-center involving macular edema. Patients who were eligible for intravitreal anti-vascular endothelial growth factor (VEGF) therapy but rejected the injections were also

considered for MPC treatment. The study protocol was approved by the Rasoul Akram Hospital Eye Research Center Ethics Committee. Informed consents were obtained.

Exclusion criteria were history of intraocular surgery or laser photocoagulation during the last 8 months, high refractive errors (>6 diopters of sphere or >3 diopters of cylinder), media opacity affecting visual acuity and OCT measurements, history of glaucoma, ischemic or inflammatory optic neuropathy, uveitis, retinal vascular occlusion, disk shape abnormalities or large peripapillary atrophy, intraocular pressure more than 22 mmHg, vitreomacular interface disorders and the need for panretinal photocoagulation or anti-VEGF therapy during follow up. Both eyes of each participant were enrolled if both eyes met the inclusion criteria.

Baseline examinations included best corrected visual acuity measurement (BCVA) using a standard Snellen chart (converted to Log MAR), slit lamp and dilated fundus examinations, tonometry with a calibrated Goldmann

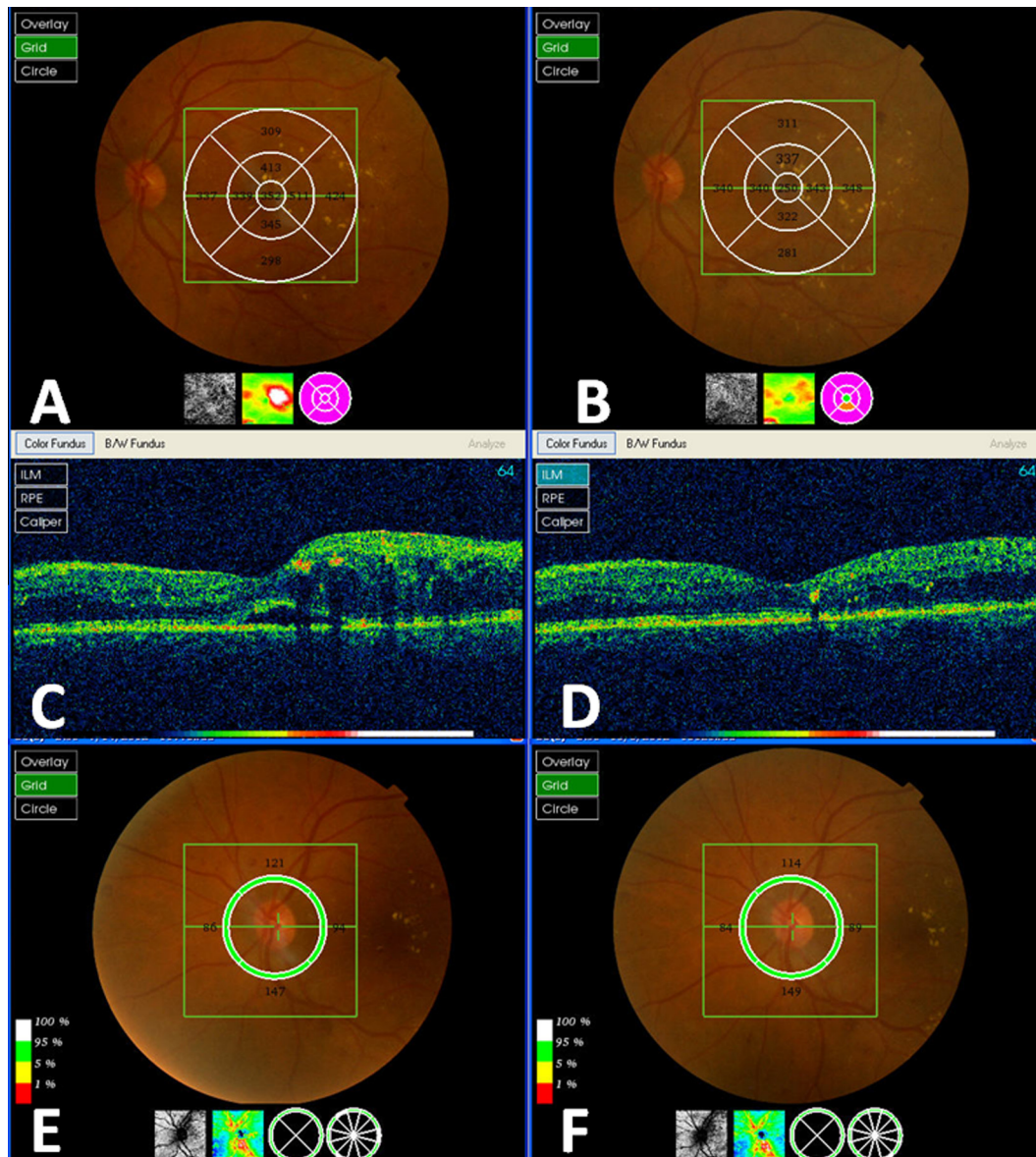


Figure 1. Pre- and post-laser treatment optical coherence tomography of a patient with center involving clinically significant diabetic macular edema. Central subfield thickness of 352 microns (A) improved to 250 microns (B). Subretinal fluid (C) resolved completely (D). Total peripapillary nerve fiber layer thickness was 112 microns before (E) and 109 microns (F) after laser treatment.

applanation tonometer, fluorescein angiography (FA) and OCT measurements. Peripapillary nerve fiber layer and macular thickness measurements were performed with a 3D spectral domain OCT-1000 device (software version 3.32.003.04, Topcon corporation, Tokyo, Japan). A 3D Scan 512 × 128 protocol, covering 6 × 6 mm² centered on optic disk or fovea was used for all measurements. Using a 3.4 mm diameter circle around the ONH, the measurements were automatically averaged to yield 12 clock-hour thicknesses, four quadrant thicknesses, and a global average PNFL thickness measurement. This device has shown good intra- and interobserver reproducibility in PNFL measurements.¹⁷

Good quality scans had to have focused images from the ocular fundus, adequate quality factor (>45), and the presence of a centered circular ring around the optic disk. Images with discontinuity, misalignment, involuntary saccade or blinking artifacts were excluded. OCT imaging was performed immediately before and 3 months after MPC by one expert technician.

A modified EDTRS protocol was used for laser photocoagulation.¹⁸ Briefly, barely visible, 50 micron size argon laser burns, with a duration of 0.1 s and 2 visible burn widths apart were placed for grid treatment in all areas of retinal thickening. In addition, focal non-bleaching laser treatment of microaneurysms was performed in all eyes. Baseline examinations except for FA, were repeated at 3 months post treatment visit. All laser treatments were performed by one retina specialist (A.K.).

Sample size of 32 eyes was calculated to find a difference of 5 microns in PNFL measurements with a study power of 80%.

All Statistical analyses were performed with SPSS software (version 15, SPSS Inc. Chicago, IL) and paired *t* test was used for analysis. *P* < 0.05 was considered significant.

Results

Thirty-three eyes of 25 patients with type 2 diabetes including 13 females and 12 males with a mean age of 59.4 ± 7.2 years were studied. The mean duration of diabetes was 11.7 ± 4.8 years and 16 patients had history of hypertension. Macular edema was foveal center involving in 24 eyes (72.7%). Among 9 eyes without center involvement, macular edema was present in all quadrants in 5 eyes, in 2 quadrants in 2 eyes and in 1 quadrant in 2 other eyes. Mean retinal thickness in central subfield, temporal, nasal, superior and inferior 3 mm ETDRS quadrants was 305.9 ± 90.7, 355.7 ± 59.9, 336.9 ± 45.9, 357.6 ± 57.7 and 343.9 ± 54 microns, respectively.

Mean total laser spot number was 198.9 ± 69 and mean laser spot number in temporal, nasal, superior and inferior quadrants was 79.9 ± 40.1, 15.7 ± 15.4, 63.7 ± 37.4 and 45.6 ± 38.3.

Mean BCVA was 0.35 ± 0.29 LogMAR at baseline (range 20/400–20/25 Snellen acuity) and 0.40 ± 0.23 LogMAR at 3 months after MPC (*P* = 0.2). Visual acuity improvement of at least one line was observed in 6 eyes (18.1%). In 8 eyes (24.2%) the visual acuity remained at the baseline level. Mean baseline and 3 months central macular subfield thickness was 305.9 ± 90.7 and 317.5 ± 112.4 microns, respectively (Fig. 1A–D, *P* = 0.1). Five eyes (15.1%) had a decrease in central subfield thickness of ≥25 microns.

Table 1. Peripapillary nerve fiber layer measurement before and after macular photocoagulation for clinically significant macular edema.

	Baseline measurements	3 months measurements	^a <i>P</i>
Average peripapillary nerve fiber layer thickness (μ)	105.7 ± 10.0	106.1 ± 9.9	0.7
Nasal peripapillary nerve fiber layer thickness (μ)	89.7 ± 18.2	91.5 ± 17.2	0.7
Temporal peripapillary nerve fiber layer thickness (μ)	85.6 ± 16.9	86.2 ± 18.1	0.4
Inferior peripapillary nerve fiber layer thickness (μ)	124.6 ± 23.8	125.6 ± 16.7	0.7
Superior peripapillary nerve fiber layer thickness (μ)	122.8 ± 16.8	123.0 ± 18.7	0.9

^a Paired *t* test.

The average and 4 quadrant PNFL measurements are shown in Table 1. No significant differences were found between pre and post laser treatment PNFL measurements (Fig. 1E and F).

Discussion

Results of the ETDRS showed focal MPC of eyes with CSME reduced the risk of moderate visual acuity loss (defined as a loss of ≥3 or more lines) by approximately 50% (from 24% to 12%) three years after initiation of treatment.² Although new treatment strategies including intravitreal injection of anti-VEGF agents and steroids have been shown to be highly effective in the treatment of diabetic macular edema, MPC remained a widely used treatment for non-center involved CSME and showed to be able to stabilize the visual acuity.³ It is also used as an adjunct to intravitreal injection of anti-VEGF drugs for naive eyes or eyes with persistence diffuse CSME.^{4,5}

Our results showed that 18% of eyes had a visual improvement of ≥1 line and 15% had a decrease in central subfield thickness of ≥25 microns. These are in accordance with a recent study from Diabetic Retinopathy Clinical Research Network that reported a 19% of visual improvement of ≥1 line and 18% of reduction in central subfield thickness of ≥25 microns.³

Patients with diabetic retinopathy are at risk of developing glaucoma.¹⁹ The measurement of visual field in eyes with glaucoma and coexisting diabetic retinopathy often is affected by retinal hemorrhage, exudates, and diabetes-associated retinal nerve fiber loss.²⁰ Previous studies have shown that MPC results in visual field defects in automated perimetry in a significant number of patients.^{9–11} Although optic nerve head assessment has been reported to have higher diagnostic value in glaucoma screening and management in patients with diabetic retinopathy, the effect of MPC on PNFL measurements has not been reported.¹⁵ Our results showed that no significant changes occurred after MPC in total PNFL measurements. Also, nerve fiber layer measurements remained the same for each quadrant around the optic nerve head. Based on these results, the PNFL measurements may be considered reliable in the screening and management of patients with CSME after MPC.

Previous studies have shown that the inner retinal layers appear damaged after laser photocoagulation.²¹ Retinal lesions have been shown to stabilize by 60 days in rats.²² So, we considered that 3 months is enough for repeating

the OCT measurements to assess the effect of laser photocoagulation.

Our study has some limitations. We did not compare our findings with normal controls. We did not perform the visual field perimetry in our patients. Considering a control group of patients with coexisting glaucoma and CSME, with the same method of treatment, may further confirm the stability of PNFL measurements after MPC. Also, patients with different protocols of laser photocoagulation may show different results. Although patients with severe CSME are usually treated with intravitreal anti-VEGF agents, the macular laser treatment may be needed and the effect of laser treatment on retinal layers may be different. Since our patients had mild to moderate CSME, our results may not be applicable to this subset of patients.

In conclusion, MPC does not change the PNFL measurements. This finding may be considered valuable for the diagnosis and management of glaucoma in patients with CSME treated with MPC. Future studies with larger sample size, longer follow up and a control group are needed to confirm our results.

Conflict of interest

The authors declared that there is no conflict of interest.

References

- Lange GE. Diabetic macular edema. *Ophthalmologica* 2012;**227**(Suppl. 1):21–9.
- Early Treatment Diabetic Retinopathy Study Research Group. Photocoagulation for diabetic macular edema. Early Treatment Diabetic Retinopathy Study report number 1. *Arch Ophthalmol* 1985;**103**(12):1796–806.
- Scott IU, Danis RP, Bressler SB, Bressler NM, Browning DJ, Qin H. Diabetic Retinopathy Clinical Research Network. Effect of focal/grid photocoagulation on visual acuity and retinal thickening in eyes with non-center-involved diabetic macular edema. *Retina* 2009;**29**(8):613–7.
- Diabetic Retinopathy Clinical Research Network, Elman MJ, Aiello LP, Beck RW, Bressler NM, Bressler SB, et al. Randomized trial evaluating ranibizumab plus prompt or deferred laser or triamcinolone plus prompt laser for diabetic macular edema. *Ophthalmology* 2010;**117**(6):1064–77.
- Nguyen QD, Shah SM, Khwaja AA, Channa R, Hafez E, Do DV, et al. READ-2 study group. Two-year outcomes of the ranibizumab for edema of the macula in diabetes (READ-2) study. *Ophthalmology* 2010;**117**(11):2146–51.
- Figueira J, Khan J, Nunes S, Sivaprasad S, Rosa A, de Abreu JF, et al. Prospective randomised controlled trial comparing sub-threshold micropulse diode laser photocoagulation and conventional green laser for clinically significant diabetic macular oedema. *Br J Ophthalmol* 2009;**93**(10):1341–4.
- Shah GK. Photodynamic therapy for choroidal neovascularization after thermal laser photocoagulation for diabetic macular edema. *Am J Ophthalmol* 2003;**135**(1):114–6.
- Schatz H, Yannuzzi LA, Gitter KA. Subretinal neovascularization following argon laser photocoagulation treatment for central serous chorioretinopathy: complication or misdiagnosis? 1975. *Retina* 2012;**32**(Suppl. 1):OP893–906.
- Sims LM, Stoessel K, Thompson JT, Hirsch J. Assessment of visual field changes before and after focal photocoagulation for clinically significant diabetic macular edema. *Ophthalmologica* 1990;**200**:133–41.
- Strieth GG, Hart Jr WM, Olk RJ. Modified grid laser photocoagulation for diabetic macular edema: the effect on the central visual field. *Ophthalmology* 1988;**95**(12):1673–9.
- Hudson C, Flanagan JG, Turner GS, Chen HC, Young LB, McLeod D. Influence of laser photocoagulation for clinically significant diabetic macular edema (DMO) on short-wavelength and conventional automated perimetry. *Diabetologia* 1998;**41**(8):1283–92.
- Grewal DS, Tanna AP. Diagnosis of glaucoma and detection of glaucoma progression using spectral domain optical coherence tomography. *Curr Opin Ophthalmol* 2013;**24**(2):150–61.
- Medeiros FA, Zangwill LM, Bowd C, Vessani RM, Susanna Jr R, Weinreb RN. Evaluation of retinal nerve fiber layer, optic nerve head, and macular thickness measurements for glaucoma detection using optical coherence tomography. *Am J Ophthalmol* 2005;**139**(1):44–55.
- Hirashima T, Hangai M, Nukada M, Nakano N, Morooka S, Akagi T, et al. Frequency-doubling technology and retinal measurements with spectral-domain optical coherence tomography in preperimetric glaucoma. *Graefes Arch Clin Exp Ophthalmol* 2013;**251**(1):129–37.
- Takahashi H, Chihara E. Impact of diabetic retinopathy on quantitative retinal nerve fiber layer measurement and glaucoma screening. *Invest Ophthalmol Vis Sci* 2008;**49**(2):687–92.
- Lim MC, Tanimoto SA, Furlani BA, Lum B, Pinto LM, Eliason D, et al. Effect of diabetic retinopathy and panretinal photocoagulation on retinal nerve fiber layer and optic nerve appearance. *Arch Ophthalmol* 2009;**127**(7):857–62.
- Menke MN, Knecht P, Sturm V, Dabov S, Funk J. Reproducibility of nerve fiber layer thickness measurements using 3D Fourier-domain OCT. *Invest Ophthalmol Vis Sci* 2008;**49**(12):5386–91.
- Writing Committee for the Diabetic Retinopathy Clinical Research Network. Comparison of the modified early treatment diabetic retinopathy study and mild macular grid laser photocoagulation strategies for diabetic macular edema. *Arch Ophthalmol* 2007;**125**(4):469–80.
- Nakamura M, Kanamori A, Negi A. Diabetes mellitus as a risk factor for glaucomatous optic neuropathy. *Ophthalmologica* 2005;**219**(1):1–10.
- Henricsson M, Heijl A. Visual fields at different stages of diabetic retinopathy. *Acta Ophthalmol (Copenh)* 1994;**72**(5):560–9.
- Paulus YM, Jain A, Gariano RF, Stanzel BV, Marmor M, Blumenkranz MS, et al. Healing of retinal photocoagulation lesions. *Invest Ophthalmol Vis Sci* 2008;**49**(12):5540–5.
- Ben-Shlomo G, Belokopytov M, Rosner M, Dubinsky G, Belkin M, Epstein Y, et al. Functional deficits resulting from laser-induced damage in the rat retina. *Lasers Surg Med* 2006;**38**(7):689–94.