



# Tumoral calcinosis of the foot: An unusual differential diagnosis of calcaneal mass



Amir Sobhani Eraghi<sup>a</sup>, Babak Athari<sup>a</sup>, Parnian Kheirkhah Rahimabad<sup>b,\*</sup>

<sup>a</sup> Department of Orthopedics, Rasoul Akram Hospital, Iran University of Medical Sciences, Tehran, Iran

<sup>b</sup> Rasoul Akram Hospital, Iran University of Medical Sciences, Tehran, Iran

## ARTICLE INFO

### Article history:

Received 20 January 2015

Received in revised form 20 March 2015

Accepted 3 April 2015

Available online 8 April 2015

### Keywords:

Tumoral calcinosis

Foot

Calcification

## ABSTRACT

**INTRODUCTION:** Tumoral calcinosis (TC) is a rare disorder characterized by the development of calcified masses within the periarticular soft tissues of large joints. It commonly involves the hip, shoulders, and elbows. TC rarely involves the feet.

**CASE PRESENTATION:** In this report, we describe an unusual case of primary TC of the foot in a 76-year-old female and discuss the pathophysiology, diagnosis, and therapeutic interventions of the condition.

**DISCUSSION:** Due to the wide range of conditions mimicking TC, its diagnosis could be challenging. Diagnosis of TC is mainly based on the radiographic findings, the patient's biochemical profile, and the medical history plus differentiating the condition from its mimics.

**CONCLUSION:** TC should be considered in the differential diagnosis of any soft tissue calcification.

© 2015 Published by Elsevier Ltd. on behalf of Surgical Associates Ltd. This is an open access article under the CC BY-NC-ND license (<http://creativecommons.org/licenses/by-nc-nd/4.0/>).

## 1. Introduction

Tumoral calcinosis (TC) is a rare benign condition characterized by extensive nonosseous calcification within the periarticular soft tissues of large joints, such as hip, elbows, shoulders, and rarely foot [1–3].

TC has a primary idiopathic form, but can also be found in a variety of disorders such as end-stage renal disease, hyperparathyroidism, vitamin D toxicity, and scleroderma [2]. TC can affect all the age groups, but is most commonly found in adolescence [4]. It mainly manifests as painless, firm, and mobile mass in periarticular soft tissue that may interfere with joint function when large [5].

TC can be mistaken for osteosarcoma, chondrosarcoma, myositis ossificans, and other conditions [2,4]. As this case demonstrates, TC should be considered in the differential diagnosis of any soft tissue calcification. In this report, we present a rare case of primary TC of the foot in a 76-year-old female. We obtained written informed consent for publication of the case report from the patient.

## 2. Presentation of case

A 76-year-old Caucasian female patient was referred for evaluation of a massive enlargement over her left heel progressing from past 10 years. She reported minor pain and discharge of a milk-like fluid from the mass. She had no constitutional symptom

including weight loss, fever, chills, fatigue, decreased appetite, or night sweats.

There was no history of trauma, renal, or rheumatologic diseases. She was referred to a rheumatologist, who found no underlying rheumatologic diseases. Her family history was negative for similar complaints. On physical examination, her heel was swollen, warm, erythematous, and moderately tender. No neurovascular deficit and involvement of lymph nodes were seen. There was a discharging ulcer on the dome of the mass. Bacterial culture of the aspirated fluid revealed growth of penicillin-resistant *Staphylococcus aureus*.

Laboratory investigation showed: serum calcium 8.4 mg/dl (normal range: 8.6–10.6), serum phosphate 3.3 mg/dl (normal range: 2.5–5), and parathyroid hormone (PTH) 38 pg/ml (normal range: 10.4–65). No abnormality of renal or hepatic function was detected.

Radiography revealed a well-defined multilobulated calcification in the juxta-articular area of calcaneus with no evidence of bony erosion or fracture (Fig. 1).

Based on the clinical and radiologic findings, a diagnosis of tumoral calcinosis was made. The patient underwent excisional biopsy. A direct plantar incision was used. Through the incision of the superficial fascia, the mass was seen surrounded by a fibrous capsule. Excision revealed a multilobulated yellowish mass and led to extrusion of a thick, pus-like fluid (Fig. 2).

Pathology report confirmed the initial diagnosis of TC. The mass was divided by dense fibrous septa and consisted of nodules containing calcified material and giant cells. After the surgery, she was admitted for empirical antibiotic therapy. After 7 days of short leg

\* Corresponding author. Tel.: +98 2164352264; fax: +98 66507059.  
E-mail address: [parniankheirkhah@gmail.com](mailto:parniankheirkhah@gmail.com) (P. Kheirkhah Rahimabad).

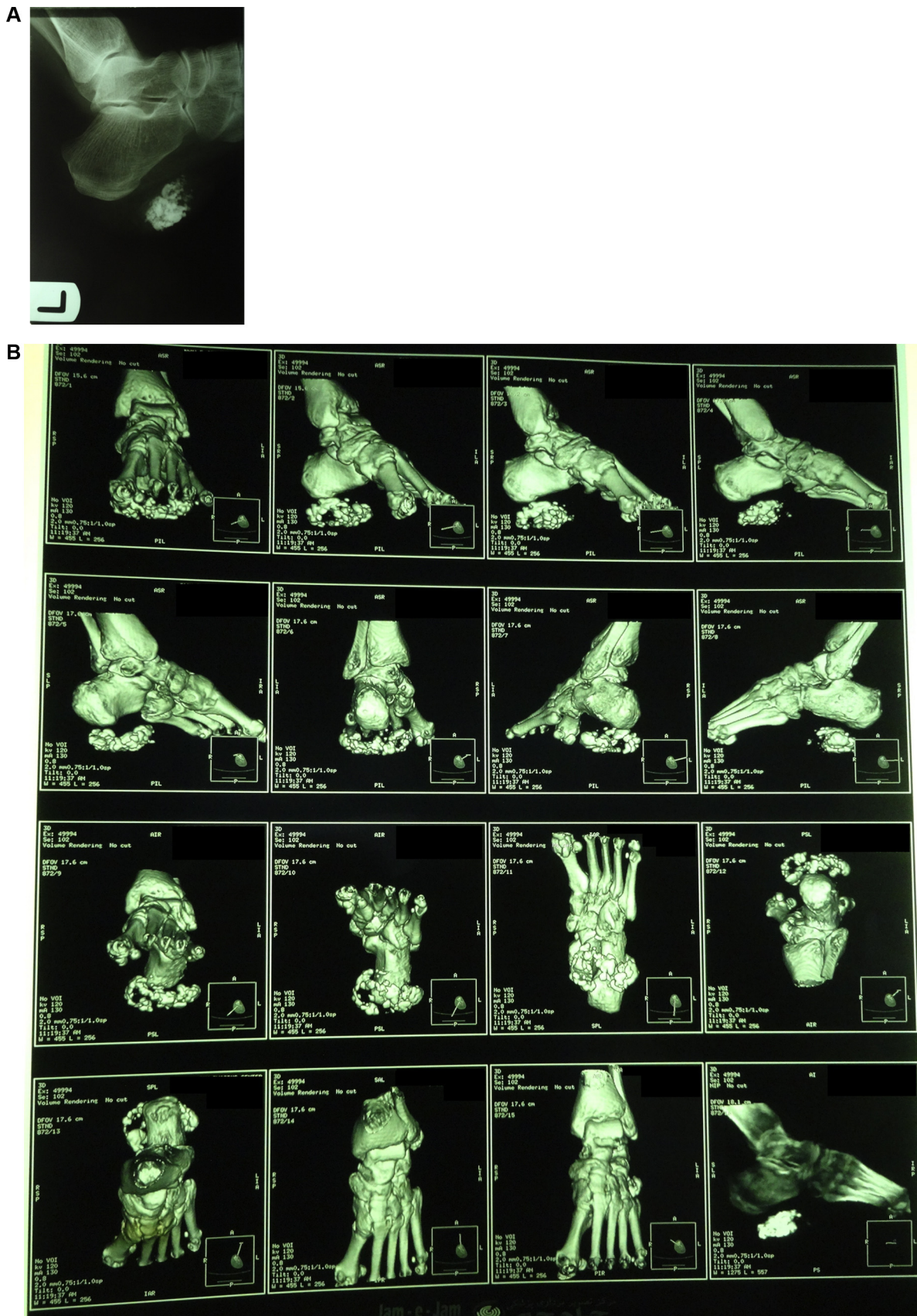
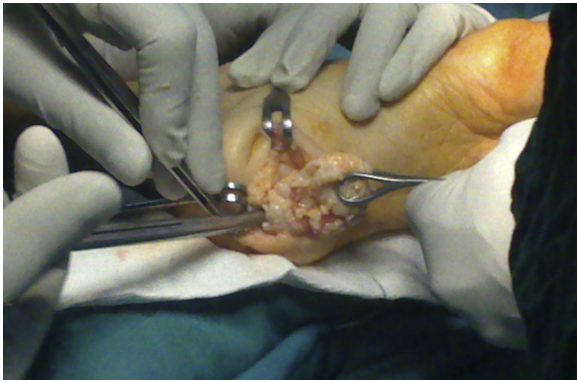


Fig. 1. Plain radiography (A) and 3D computed tomography, (B) showing a calcified nodular mass in the juxta-articular region of calcaneus.



**Fig. 2.** Intraoperative image, the yellowish multinodular mass is visualized.

splinting, range of motion (ROM) exercises and protected weight bearing were started. The patient achieved full ROM and weight bearing in 2 weeks. She was followed up for 6 months postoperatively without any complications.

### 3. Discussion

TC is a rare form of extraosseous calcification occurring mainly in the periarticular soft tissue regions of major joints [1,2]. It commonly involves the hip, shoulders, and elbows. Hands, feet, scalp, and eyelids are rarely involved [4]. Complications of TC include pain, ulceration, infection, cosmetic disfigurement, and limited joint mobility [4].

TC is classified into primary hyperphosphatemic, primary normophosphatemic, and secondary varieties. Primary hyperphosphatemic TC is an autosomal recessive disorder usually affecting young African men [6]. This type is represented by mutations in *FGF23*, *GALNT3* or *KL* genes [7]. Dysfunction of any one of these proteins leads to enhanced renal phosphate reabsorption [4]. These patients have elevated serum phosphate and normal serum calcium levels [2]. Patients with primary normophosphatemic TC are usually young and have no known disorder of phosphate or calcium metabolism [2,6]. In a review by Farzan and Farhoud, patients with primary TC ranged from 2 to 67 years old. Hips and elbows were the most common sites involved in primary TC [8].

Secondary TC is associated with disorders capable of causing soft tissue calcification such as hyperparathyroidism, end-stage renal disease, vitamin D toxicity, milk-alkali syndrome, and osteolysis [2,4,7].

Before making a diagnosis of primary TC, such diseases should be ruled out by history and laboratory findings [9]. A review by Fathi and Sakr suggest the exclusion of collagen vascular disorders in TC by evaluating serum levels of anti-scleroderma, antinuclear, anti-Smith, and anticentromere antibodies [7].

In our case, the patient had normal levels of serum PTH, calcium, and phosphorus with no evidence of an underlying disorder causing calcification. Our findings suggest that our patient belongs to primary normophosphatemic TC category.

TC also appears to be triggered by repeated microtrauma especially in normophosphatemic patients [3,7]. Hemorrhage in the periarticular connective tissue initiates histiocyte aggregation leading to calcium deposition at the site [2,3,7]. A previous report of 64 patients suggests the causative role of repeated microtrauma in TC in postmenopausal women involved in household chores as in our patient [10]. The presence of lesions and pigments around the mass supports the possible causative role of repeated microtrauma for development of TC in our patient.

With a wide range of differential diagnosis of soft tissue calcification, TC can be easily misdiagnosed. Diagnosis of TC is mainly

based on the radiographic findings, the patient's biochemical profile, and the medical history plus differentiating the condition from its mimics [7,8]. Plain radiographs are often diagnostic. They show the typical appearance of amorphous, multilobulated calcification, which is termed as "chicken-wire" pattern [6–8].

Treatment of TC consist of excision, phosphate deprivation, or a combination of both [6]. Excision of the mass is considered for primary normophosphatemic TC [8]. Complete removal of the mass is necessary to prevent its recurrence [11]. Other indications for surgical approach include pain, ulcering, recurring infection, and functional impairment [7,8].

In primary hyperphosphatemic TC, medical treatment could be considered before the surgical approach. Medical treatment consists of lowering the phosphate level with calcium and phosphorus-restricted diets, phosphate-binding antacids, and induction of phosphaturia by acetazolamide [5,7,8,12].

In view of the high recurrence rate and postoperative complications, treatment of secondary TC is mainly medical [7,8]. Due to the underlying secondary or tertiary hyperparathyroidism in most of these patients, subtotal or total parathyroidectomy is considered when medical treatment fails [7,8].

### 4. Conclusion

Due to the wide range of conditions mimicking TC, its diagnosis could be challenging. Hence, TC should be considered in the differential diagnosis of any soft tissue calcification.

### Conflicts of interest

Authors have no conflict of interest.

### Sources of funding

None.

### Ethical approval

Ethical approval was obtained from Iran University of medical sciences.

### Consent

Written consent was obtained from the patient.

### Author contribution

All authors have made substantial contributions to all of the following: (1) acquisition of data, analysis and interpretation of data, (2) revising it critically for important intellectual content, and (3) final approval of the version to be submitted.

### Guarantor

None.

### References

- [1] S. Kannan, L. Ravikumar, S. Mahadevan, et al., Tumoral calcinosis with vitamin D deficiency, *Saudi J. Kidney Dis. Transpl.* 19 (November (6)) (2008) 960–963.
- [2] S. Mohamed, J. Jong-Hun, K. Weon-Yoo, Tumoral calcinosis of the foot with unusual presentation in an 11-year-old boy: a case report and review of literature, *J. Postgrad. Med.* 53 (October–December (4)) (2007) 247–249.
- [3] J.J. Jeong, J.H. Ji, M. Shafi, J.K. Lee, Hallux valgus deformity of foot with tumoral calcinosis: an unusual presentation, *Foot Ankle Surg.* 20 (March (1)) (2014) e15–e18.

- [4] G.K. Tharini, D. Prabhavathy, N. Hema, S. Jayakumar, Idiopathic sporadic tumoral calcinosis in an Indian girl, *Indian J. Dermatol. Venereol. Leprol.* 77 (July–August (4)) (2011) 536.
- [5] A.Z. Alkhoody, Medical treatment for tumoral calcinosis with eight years of follow-up: a report of four cases, *J. Orthop. Surg. (Hong Kong)* 17 (December (3)) (2009) 379–382.
- [6] Y.Y. Leung, R. Lai, Tumoral calcinosis: a case report, *J. Orthop. Surg. (Hong Kong)* 19 (April (1)) (2011) 108–112.
- [7] I. Fathi, M. Sakr, Review of tumoral calcinosis: a rare clinico-pathological entity, *World J. Clin. Cases* 2 (September 16, (9)) (2014) 409–414.
- [8] M. Farzan, A.R. Farhoud, Tumoral calcinosis: what is the treatment? Report of two cases of different types and review of the literature, *Am. J. Orthop. (Belle Mead NJ)* 40 (September (9)) (2011) E170–E176.
- [9] S. Chaabane, M. Chelli-Bouaziz, H. Jelassi, K. Mrad, M. Smida, M.F. Ladeb, Idiopathic tumoral calcinosis, *Acta Orthop. Belg.* 74 (December (6)) (2008) 837–845.
- [10] T. Shet, P. Rajasekharan, J. Deshpande, Tumoral calcinosis in postmenopausal women in urban India: an etiopathologic evaluation of 64 cases, *Indian J. Pathol. Microbiol.* 50 (April (2)) (2007) 274–278.
- [11] G.I. Henry, C.M. Teven, CASE REPORT idiopathic tumoral calcinosis of the nontraumatic thumb, *Eplasty* 12 (2012) e29.
- [12] M.C. Janssen, R.G. de Sevaux, Tumoral calcinosis, *J. Inherit. Metab. Dis.* 33 (February (1)) (2010) 91–92.

#### Open Access

This article is published Open Access at [scimedirect.com](http://scimedirect.com). It is distributed under the [IJSCR Supplemental terms and conditions](#), which permits unrestricted non commercial use, distribution, and reproduction in any medium, provided the original authors and source are credited.