

## Case Report

# Descemet's Membrane Detachment Management Following Trabeculectomy

Farideh Sharifipour<sup>1</sup>, MD; Saman Nassiri<sup>1</sup>, MD; Aida Idan<sup>2</sup>, MD

<sup>1</sup>Department of Ophthalmology, Imam Khomeini Hospital, Ahvaz Jundishapur University of Medical Sciences, Ahvaz, Iran

<sup>2</sup>School of Medicine, Iran University of Medical Sciences, Tehran, Iran

### Abstract

**Purpose:** To present a case of total Descemet's membrane detachment (DMD) after trabeculectomy and its surgical management.

**Case Report:** A 68-year-old woman presented with large DMD and corneal edema one day after trabeculectomy. Intracameral air injection on day 3 was not effective. Choroidal effusion complicated the clinical picture with Descemet's membrane (DM) touching the lens. Choroidal tap with air injection on day 6 resulted in DM attachment and totally clear cornea on the next day. However, on day 12 the same scenario was repeated with choroidal effusion, shallow anterior chamber (AC), and DM touching the lens. The third surgery included transconjunctival closure of the scleral flap with 10/0 nylon sutures, choroidal tap, and intracameral injection of 20% sulfur hexafluoride. After the third surgery, DM remained attached with clear cornea. Suture removal and needling bleb revision preserved bleb function. Lens opacity progressed, and the patient underwent uneventful cataract surgery 4 months later.

**Conclusion:** Scleral flap closure using transconjunctival sutures can be used for DMD after trabeculectomy to make the eye a closed system. Surgical drainage of choroidal effusions should be considered to increase the AC depth.

**Keywords:** Descemet's Membrane Detachment; Trabeculectomy; Corneal Edema

*J Ophthalmic Vis Res* 2016; 11 (3): 323-325.

## INTRODUCTION

Descemet's membrane detachment (DMD) occurs when endothelium-DM separates from posterior corneal stroma. Although uncommon, it is a serious complication of intraocular surgery and may result in corneal stromal edema and significant loss of vision.<sup>[1]</sup> Small DMDs may

resolve spontaneously, but most large detachments require interventions such as pneumodescemetopexy with air, nonexpansile or expansile gases, tamponading with ophthalmic viscosurgical device (OVD), or transcorneal suture fixation of DM.<sup>[2]</sup>

Cataract extraction is the most common surgery associated with DMD. However, management of DMD following trabeculectomy is more challenging since the eye is no longer a closed system and the tamponading agents escape through the fistula.

Herein, we present a case of total DMD following trabeculectomy also complicated by choroidal effusion and shallow anterior chamber (AC).

### Correspondence to:

Farideh Sharifipour, MD. Department of Ophthalmology, Imam Khomeini Hospital, Ahvaz Jundishapur University of Medical Sciences, Azadegan St., Ahvaz 61936, Iran.  
E-mail: sharifipourf@yahoo.com

Received: 25-01-2015

Accepted: 26-08-2015

### Access this article online

Quick Response Code:



Website:

[www.jovr.org](http://www.jovr.org)

DOI:

10.4103/2008-322X.188403

This is an open access article distributed under the terms of the Creative Commons Attribution-NonCommercial-ShareAlike 3.0 License, which allows others to remix, tweak, and build upon the work non-commercially, as long as the author is credited and the new creations are licensed under the identical terms.

For reprints contact: [reprints@medknow.com](mailto:reprints@medknow.com)

**How to cite this article:** Sharifipour F, Nassiri S, Idan A. Descemet's membrane detachment management following trabeculectomy. *J Ophthalmic Vis Res* 2016;11:323-5.

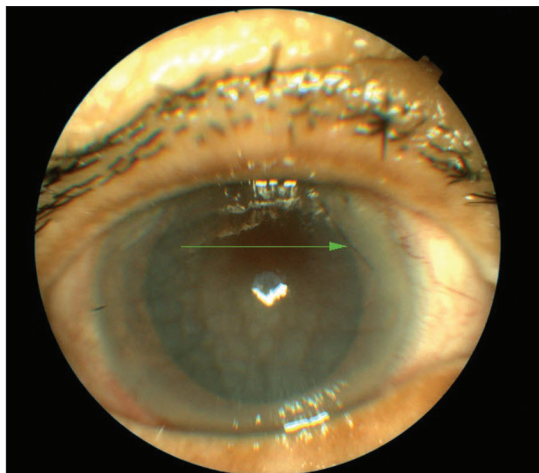
## CASE REPORT

A 68-year-old woman presented with severe corneal edema of the right eye one day after trabeculectomy for primary open angle glaucoma. Her past medical history was unremarkable, and past surgical history was significant for uneventful trabeculectomy in the left eye one year earlier.

Preoperative data included a best corrected visual acuity (BCVA) of 20/200 in both eyes. Intraocular pressure (IOP) was 18 mmHg in the right eye with antiglaucoma medications and 10 mmHg in the left eye without medication. Central corneal thickness (CCT) was 553  $\mu\text{m}$  and 560  $\mu\text{m}$  in the right and left eyes, respectively. Both eyes had moderate nuclear sclerosis. Fundus examination was significant for glaucomatous optic disc cupping with cup/disc ratio of 0.75 in the right and 0.9 in the left eye.

At presentation, visual acuity had decreased to counting fingers at 0.5 meter in the right eye. Slit lamp examination revealed elevated bleb, severe corneal stromal edema, and IOP of 6 mmHg [Figure 1]. The patient was first managed conservatively with intensive steroids and hyperosmotics with probable diagnosis of DMD. The diagnosis of DMD was confirmed using anterior segment optical coherence tomography (AS-OCT) (anterior module, Topcon 3D OCT-1000, Topcon Inc., Tokyo, Japan), and the patient underwent air descemetopexy on postoperative day (POD) 3. This was unsuccessful, and the patient also developed choroidal effusion which made the situation worse due to shallow AC. AS-OCT revealed scrolled DMD touching the lens and a CCT of 1204  $\mu\text{m}$  [Figure 2]. The patient underwent the 2<sup>nd</sup> reparative surgery including choroidal tap and intracameral air injection on POD 6.

The patient responded dramatically to this intervention, and the cornea was completely clear on day 7. The patient was on antibiotics, frequent steroids,



**Figure 1.** Severe corneal edema one day after trabeculectomy due to large Descemet's membrane detachment.

and cycloplegics. However, she returned to the clinic 5 days later with decreased vision and the same scenario including shallow AC, DMD, and choroidal effusion and an elevated bleb.


As there seemed to be a vicious cycle of hypotony and choroidal effusion, the patient underwent the 3<sup>rd</sup> surgery aimed at breaking the cycle and preventing recurrent choroidal detachment. This surgery consisted of transconjunctival suturing of the scleral flap using three 10-0 nylon sutures, choroidal tap, and AC reforming using 0.3 ml of 20% sulfur hexafluoride (SF<sub>6</sub>). During injection, the tip of the injection cannula was placed on the iris in order to prevent further damage to the scrolled DM.

The eye responded dramatically to this procedure and cornea became clear the next day after the intervention. DM remained attached post operatively and gas bubble resorbed from AC within 6 days. Sutures were removed after 2 weeks, and needling bleb revision was done 1 week later. After 3 months, IOP was 13 mmHg without medication; and endothelial cell counts were 1170 and 1720 in the right and left eyes, respectively. Lens opacity gradually increased, and the patient underwent uneventful cataract surgery 4 months after trabeculectomy.

## DISCUSSION

DMD is a rare but sight-threatening complication of trabeculectomy which usually remains undiagnosed during the surgery. Predisposing factors include shallow AC, accidental insertion of the instruments between stroma and DM, blunt keratomes, inadvertent injection of saline or OVD between the deep stroma and DM, or weak adhesions between them.<sup>[2]</sup> In our case, accidental insertion of the cannula and inadvertent injection of balanced salt solution (BSS) between stroma and DM seems to have been the cause of DMD.

Diagnosis of DMD on slit lamp examination may be difficult due to significant corneal edema. Ultrasound biomicroscopy (UBM) can be used successfully to detect DMD.<sup>[3]</sup> However, it has the disadvantage of being a contact method in post-trabeculectomy eyes. In contrast,



**Figure 2.** Anterior segment OCT 6 days after trabeculectomy showing detached Descemet's membrane touching the lens, severe corneal edema with a thickness of 1204  $\mu\text{m}$ , and shallow anterior chamber due to choroidal effusion.

AS-OCT which is a non-contact method is a very useful tool to diagnose and monitor the progress of DMD in eyes with severe corneal edema.

Whereas small DMDs may resolve spontaneously or by conservative management, large detachments frequently need to be repaired surgically.

Surgical management usually starts with intracameral injection of air and nonexpansile concentration of SF6 (15-20%). Perfluoropropane (12-14% C3F8) with longer resorption time and potential endothelial toxicity is used if reattachment fails with air or SF6. Expansile concentration (100%) of SF6 is not widely used.<sup>[2]</sup>

Other modalities include intracameral injection of OVD and transcorneal suture fixation of DM. For those unresponsive to the aforementioned interventions, Descemet's stripping automated endothelial keratoplasty or penetrating keratoplasty may be needed.<sup>[2]</sup>

Management of DMD after trabeculectomy is more challenging compared to those after cataract surgery. The eye after trabeculectomy is not a closed system, and the tamponading agents escape through the ostium, making them less effective for attaching DM.

There are a few reports regarding management of DMD after trabeculectomy.

Li et al reported a case of DMD after trabeculectomy which was attached after 5 injections of air, gas, and OVD.<sup>[3]</sup> Wigginton et al reported a case of DMD after AC reformation for flat AC and hypotony following trabeculectomy. The cornea was clear in spite of a large DMD which resolved with conservative treatment in 6 months.<sup>[4]</sup> Rasouli et al reported a case of DMD

following several AC reformations with OVD injection for management of post-trabeculectomy hypotony. This was managed by viscoelastic tamponade, full thickness 10-0 nylon sutures, and drainage of the fluid between the stroma and the DM.<sup>[5]</sup>

In the present report, large DMD after trabeculectomy, in the presence of choroidal effusion and shallow AC, was managed successfully with closure of the functional bleb by transconjunctival suturing of the scleral flap, choroidal tap, and DM tamponade with 20% SF6.

## Financial Support and Sponsorship

Nil.

## Conflicts of Interest

There are no conflicts of interest.

## REFERENCES

1. Marcon AS, Rapuano CJ, Jones MR, Laibson PR, Cohen EJ. Descemet's membrane detachment after cataract surgery: Management and outcome. *Ophthalmology* 2002;109:2325-2330.
2. Chow VW, Agarwal T, Vajpayee RB, Jhanji V. Update on diagnosis and management of Descemet's membrane detachment. *Curr Opin Ophthalmol* 2013;24:356-361.
3. Li YH, Shi JM, Fan F, Duan XC, Jia SB. Descemet membrane detachment after trabeculectomy. *Int J Ophthalmol* 2012;5:527-529.
4. Wigginton SA, Jungschaffer DA, Lee DA. Postoperative Descemet membrane detachment with maintenance of corneal clarity after trabeculectomy. *J Glaucoma* 2000;9:200-202.
5. Rasouli M, Mather R, Tingey D. Descemet membrane detachment following viscoelastic injection for posttrabeculectomy hypotony. *Can J Ophthalmol* 2008;43:254-255.