

The first report of onychomycosis caused by *Cryptococcus friedmannii* (*Naganishia friedmannii*) a basidiomycetous yeast



Masoom Ekhtiari^a, Shirin Farahyar^{a,*}, Mehraban Falahati^a, Elham Razmjou^a,
Mahtab Ashrafi-Khozani^a, Zeinab Ghasemi^b, Ziba Abbasi-Nejat^{c,d}

^a Department of Medical Parasitology and Mycology, School of Medicine, Iran University of Medical Sciences, Tehran, Iran

^b Department of Medical Parasitology and Mycology, School of Public Health, Tehran University of Medical Sciences, Tehran, Iran

^c International Campus, Iran University of Medical Sciences, Tehran, Iran

^d Deputy of Research and Technology, Golestan University of Medical Sciences, Gorgan, Iran

ARTICLE INFO

Keywords:

Cryptococcus friedmannii

Onychomycosis

Basidiomycetous yeast

Antifungal susceptibility

ABSTRACT

Yeasts are common etiologic agents of onychomycosis. This study reported a case of onychomycosis due to *Cryptococcus friedmannii* (*Naganishia friedmannii*). This yeast was isolated of the right great toenail of 57-year-old man. Microscopic examination of nail scrapings showed budding cells with thin capsule. Sequence analyzes of the internal transcribed spacer regions was closely related to *Cryptococcus friedmannii*. The results of susceptibility testing showed the *Cryptococcus friedmannii* to be sensitive to fluconazole, itraconazole and amphotericin B.

1. Introduction

Onychomycosis is a common nail infection due to yeasts and filamentous fungi [1,2]. The uncommon fungi such as *Trichosporon mucoides* [3] *Aspergillus clavatus* [4] and *Cryptococcus* spp. (basidiomycetous yeasts) [5] were reported as emerging pathogens of onychomycosis.

The basidiomycetous yeasts are important in economic, agricultural and medical problems [6]. *Cryptococcus neoformans* (*Cr. neoformans*) was an important agent of cryptococcal infections in immunocompromised patients and *Cr. gatti* is the major pathogen in the genus as well [7,8]. However the reports of infections due to non-*neoformans* have been increased [9]. The species of *Cryptococcus* genus have been identified from different environmental sources such as air, water, soil, wood, and pigeon excreta. *Cr. friedmannii* was reported as a new species of yeast from Antarctic in 1985 [10]. The other studies reported that *Cr. friedmannii* isolated from Beringian and Icelandic soils which were more vegetated. This kind of yeast was reported from soil of Tabriz in Iran as well [11,12]. *Cr. friedmannii* and some of the yeast species were isolated from the Atacama Desert, with high daily temperature variations. *Cr. friedmannii* had ability to survive at moderate to cold temperatures [13]. *Cr. friedmannii* has not been reported as an agent of onychomycosis.

2. Case

A 57-year-old man was admitted to our department in October 2015 (at day 0) with distal subungual hyperkeratosis clinical type of onychomycosis on the first right toenail (Fig. 1). The patient did not have disease like diabetes, psoriasis, immunodeficiencies or any chronic disease. However, four months ago (at day – 4 months), the patient had a history of ungueal trauma and small traumatic lesion was emerged on toenail. Three direct microscopic examinations (at day 0) of nail scrapings, with 20% potassium hydroxide revealed single or budding yeast cells. Three nail specimens were cultured on sabourauds dextrose agar plates with chloramphenicol (at day 0), and incubated at 20–25 °C, which were produced creamy and smooth colonies after a few days (Fig. 2). The other fungi were not isolated. Microscopic examinations (at day 7) of the colonies with Chinese ink were shown single or budding cells with a thin capsule (Fig. 3). Also, lactophenol cotton blue wet mount slide of colonies showed budding cells (Fig. 4). For molecular identification, the yeast was cultured on yeast extract peptone dextrose agar and incubated at 20–25 °C.

Genomic DNA was extracted using Qiagen tissue kit (Germany) (at day 11). The ITS1-5.8S-ITS2 region was amplified with ITS1 (TCC GTA GGT GAA CCT GCG G) and ITS4 (TCC TCC GCT TAT TGA TAT GC) universal primers by the following profile: 98 °C (5 min), 40 cycles of 98 °C (30 s), annealing temperature 56 °C (30 s), and 72 °C (30 s), followed by a final extension of 72 °C (5 min). Amplification of the

* Correspondence to: Department of Medical Mycology and Parasitology, School of Medicine, Iran University of Medical Sciences, Shahid Hemmat hwy, Tehran 14155 Iran.
E-mail address: farahyar.sh@iums.ac.ir (S. Farahyar).

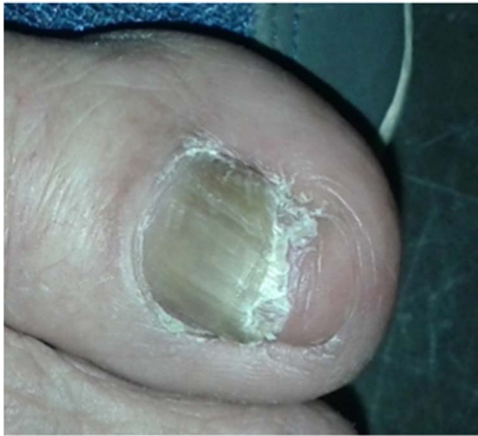

Fig. 1. Distal subungual thickening and hyperkeratosis of patient.




Fig. 4. Budding cells in lactophenol cotton blue wet mount slide of colonies (×400).

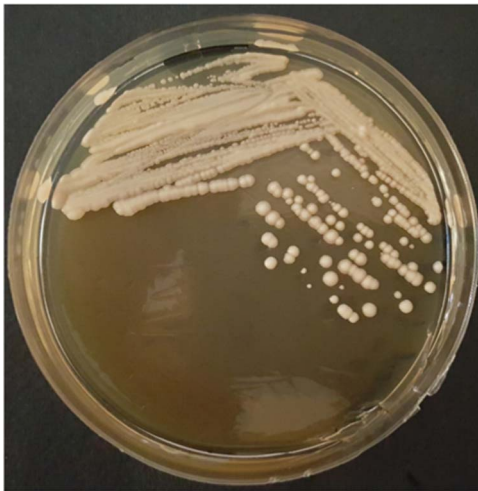

Fig. 2. Creamy and smooth colonies of *Cr. friedmannii* on sabourauds dextrose agar plate with chloramphenicol.




Fig. 3. Budding cells with a thin capsule with Chinese ink wet mount (×400).

isolate with ITS1 and ITS4 primers yielded 500 bp fragment (at day 11).

The PCR products were sequenced by Macrogen (Korea). Sequence analyzes was compared with the reference sequences of GenBank database using BLAST (basic local alignment search tool) (<http://www.ncbi.nlm.nih.gov/BLAST>). Sequence analyzes was 100% related to *Cr. friedmannii* (*Naganishia friedmannii*) with the accession number KM243311.1 (at day 23). The sequence of the ITS region was submitted to the GeneBank as the accession number KX268322 (Fig. 5).

The antifungal susceptibilities were conducted according to the Clinical and Laboratory Standard Institute method (document M27-S3). The susceptibility tests of *Cr. friedmannii* to fluconazole, Itraconazole and amphotericin B was determined at 72 h. The MICs results revealed this isolate was susceptible to these drugs with MIC values of 0.25, 0.125 and 0.25 µg/ml for fluconazole, itraconazole and amphotericin B, respectively (at day 30). The patient was treated with oral itraconazole at the dosage of 200 mg daily. Three months later, the symptoms of disease complete remission of the nail. Direct microscopic examinations of nail scrapings with 20% potassium hydroxide had not revealed single or budding yeast cells and culture of the nail sample was negative.

3. Discussion

The yeast *Cr. friedmannii* was first reported as a new species of basidiomycetous yeast of Antarctic in 1985 [10]. The incidence of infection due to non- *Cr. neoformans* has increased. This increased may reveal enhanced immunocompromised patients with impaired cell-mediated immunity, organ transplantation, diabetic patients, azole prophylaxis, and etc [9]. Some of non- *Cr. neoformans* species, such as *Cr. laurentii*, *Cr. albidus*, *Cr. luteolus*, *Cr. uniguttulatus*, *Cr. curvatus* and *Cr. humicola* were reported as opportunistic pathogens over the last few years [9,14]. A case of *Cr. laurentii* keratitis was reported in diabetic patient with onychomycosis. Cultures of the nail and of the contact lens have shown *Cr. laurentii* and *Fusarium solani* [15]. Three species of *Cryptococcus* (*Cr. albidus*, *Cr. uniguttulatus* and *Cr. laurentii*) were isolated of onychomycosis in type 2 diabetes mellitus

```

1  gattagaaag  cggctcttag  tcctgcaaca  gggccatccg  aagatgtcct  tagcgaaata
61  cttattacgc  caagtcaaac  catgtcgcga  gacagatcca  gctattactt  ttaagacgag
121  ccgacttgac  atcggcaaac  gtccaaatcc  aagcceaaga  aaggtcaaat  aaccaatcta
181  aggttgaggg  ttttcatgac  actcaaacag  gcatgtcctc  cggaatacca  aggagcgcaa
241  ggtgcgttca  aagattcgat  gattcactga  attctgcaat  tcacattact  tatcgcattt
301  cgctgcgctt  ttcacatgat  cgagagccaa  gagatccggt  gttgaaagtt  ttattttggt
361  ataataagac  tacatttggt  acattattgt  ttagtgtgta  tggatgacta  ttgactttag
421  gttttaccct  atgtccttag  atcatccaac  aagtgcacag  gtggttatga  tatgatagaa
481  agcccgtgag  caagctcgac  aggcactctg  attcattaat  gatccttccg
    
```

Fig. 5. The sequence of the ITS region was submitted to the GeneBank as the accession number KX268322.

patients [5]. Also, *Prothoteca* spp was reported as the first causative agent of onychomycosis in Brazil which was the 3rd case in the world [16]. The distribution of pathogens of onychomycosis is not uniform. It is related to several factors such as geographical region and climatic conditions. Furthermore, onychomycosis is related to the host ones such as age, occupation, chronic diseases, nail care and lifestyle. Deformity and pain in nails are caused by the fungi in onychomycosis. Thus, affected individuals may experience difficulties while walking and writing. Therefore, accurate diagnosis of the agents is important for suitable therapeutic approach. This study reports *Cr. friedmannii* is the first case of onychomycosis in the world.

Conflict of interest

There are none.

Acknowledgements

This research was supported by Iran University of Medical Sciences, grant 94-02-30-26132.

References

- [1] P. Nenoff, C. Kruger, G. Ginter-Hanselmayer, H.J. Tietz, Mycology - an update. Part 1: Dermatofungi: causative agents, epidemiology and pathogenesis, *J. Dtsch. Dermatol. Ges.* 12 (2014) 188–209.
- [2] B. Ahmadi, S.J. Hashemi, F. Zaini, M.R. Shidfar, M. Moazeni, B. Mousavi, et al., A case of onychomycosis caused by *Aspergillus candidus*, *Med. Mycol. Case. Rep.* 1 (2012) 45–48.
- [3] G. Rizzitelli, E. Guanziroli, A. Moschin, R. Sangalli, S. Veraldi, Onychomycosis caused by *Trichosporon mucoides*, *Int. J. Infect. Dis.* 42 (2016) 61–63.
- [4] M. Falahati, A. Ghoghghi, M. Abastabar, Z. Ghasemi, S. Farahyar, M. Roudbary, et al., The first case of total dystrophic onychomycosis caused by *Aspergillus clavatus* resistant to antifungal drugs, *Mycopathologia* 181 (2016) 273–277.
- [5] P. Manzano-Gayosso, F. Hernandez-Hernandez, L.J. Mendez-Tovar, Y. Palacios-Morales, E. Cordova-Martinez, E. Bazan-Mora, et al., Onychomycosis incidence in type 2 diabetes mellitus patients, *Mycopathologia* 166 (2008) 41–45.
- [6] J.W. Fell, T. Boekhout, A. Fonseca, G. Scorzetti, A. Stazzell-Tallman, Biodiversity and systematics of basidiomycetous yeasts as determined by large-subunit rDNA D1/D2 domain sequence analysis, *Int. J. Syst. Evol. Microbiol.* 50 (2000) 1351–1371.
- [7] E. Bielska, R.C. May, What makes *Cryptococcus gattii* a pathogen?, *Fems. Yeast. Res.* 16 (2016) fov106.
- [8] A.E. Merkler, N. Gaines, H. Baradaran, A.N. Schuetz, E. Lavi, S.A. Simpson, et al., Direct invasion of the optic nerves, chiasm, and tracts by *Cryptococcus neoformans* in an immunocompetent host, *Neurohospitalist* 5 (2015) 217–222.
- [9] T. Khawcharoenporn, A. Apisarnthanarak, L.M. Mundy, Non-*neoformans* cryptococcal infections: a systematic review, *Infection* 35 (2007) 51–58.
- [10] H.S. Vishniac, *Cryptococcus friedmannii*, a new species of yeast from the Antarctic, *Mycologia* 77 (1985) 149–153.
- [11] L. Mokhtarnejad, B. Turchetti, Molecular identification of basidiomycetous yeasts from soils in Iran, *Rostanihi* 16 (2015) 61–80.
- [12] H.S. Vishniac, A multivariate analysis of soil yeasts isolated from a latitudinal gradient, *Microb. Ecol.* 52 (2006) 90–103.
- [13] A.A. Pulschen, F. Rodrigues, R.T. Duarte, G.G. Araujo, I.F. Santiago, I.G. Paulino-Lima, et al., UV-resistant yeasts isolated from a high-altitude volcanic area on the Atacama Desert as eukaryotic models for astrobiology, *Microbiol. Open* 4 (2015) 574–588.
- [14] L. Bernal-Martinez, A. Gomez-Lopez, M.V. Castelli, A.C. Mesa-Arango, O. Zaragoza, J.L. Rodriguez-Tudela, et al., Susceptibility profile of clinical isolates of non-*Cryptococcus neoformans*/non-*Cryptococcus gattii* *Cryptococcus* species and literature review, *Med. Mycol.* 48 (2010) 90–96.
- [15] D.C. Ritterband, J.A. Seedor, M.K. Shah, S. Waheed, I. Schorr, A unique case of *Cryptococcus laurentii* keratitis spread by a rigid gas permeable contact lens in a patient with onychomycosis, *Cornea* 17 (1998) 115–118.
- [16] C.S. Ribeiro, C. Zaitz, V.M. Framil, T.S. Ottoni, M.S. Tonoli, R.P. Ribeiro, Descriptive study of onychomycosis in a hospital in Sao Paulo, *Braz. J. Microbiol.* 46 (2015) 485–492.