

Multicenter, Double-Blind, Randomized, Intraindividual Crossover Comparison of Gadobenate Dimeglumine and Gadopentetate Dimeglumine for MR Angiography of Peripheral Arteries¹

Suzanne C. Gerretsen, MD
Thierry F. le Maire, MD, PhD
Stephan Miller, MD
Siegfried A. Thurnher, MD
Christoph U. Herborn, MD
Henrik J. Michaely, MD
Harald Kramer, MD
Angelo Vanzulli, MD
Josef Vymazal, MD
Martin N. Wasser, MD
Claudio E.M. Ballarati, MD
Miles A. Kirchin, PhD
Gianpaolo Pirovano, MD
Tim Leiner, MD, PhD²

¹ From the Dept of Cardiovascular MR Research, Maastricht Univ Hosp, Peter Debijelaan 25, 6229HX Maastricht, the Netherlands (S.C.G., T.L.); Dept of Radiology, Reinier De Graaf Hosp, Delft, the Netherlands (T.F.L.M.); Dept of Diagnostic and Interventional Radiology, Eberhard-Karls Univ, Tübingen, Germany (S.M.); Dept of Radiology, Hosp of St John of God, Vienna, Austria (S.A.T.); Medical Prevention Ctr, Univ Medical Ctr Hamburg-Eppendorf, Hamburg, Germany (C.U.H.); Institute of Clinical Radiology and Nuclear Medicine, Univ Medical Ctr Mannheim, Mannheim, Germany (H.J.M.); Institute of Clinical Radiology, Ludwig Maximilians Univ, Munich, Germany (H.K.); Dept of Radiology, Ospedale Niguarda Ca' Granda, Milan, Italy (A.V.); Dept of Radiology, Homolce Hosp, Prague, Czech Republic (J.V.); Dept of Radiology, Leiden Univ Medical Ctr, Leiden, the Netherlands (M.N.W.); Dept of Radiology, Hosp Valduce, Como, Italy (C.E.M.B.); Dept of Worldwide Medical and Regulatory Affairs, Bracco Imaging, Milan, Italy (M.A.K.); and Dept of Worldwide Medical and Regulatory Affairs, Bracco Diagnostics, Princeton, NJ (G.P.). Received April 17, 2009; revision requested June 2; revision received August 9; accepted September 17; final version accepted October 5. Address correspondence to T.L. (e-mail: timleiner@gmail.com).

² Current address: Dept of Radiology, Maastricht Univ Medical Ctr, Maastricht, the Netherlands and Dept of Radiology, Utrecht Univ Medical Ctr, Utrecht, the Netherlands.

© RSNA, 2010

Purpose:

To prospectively compare the image quality and diagnostic performance achieved with doses of gadobenate dimeglumine and gadopentetate dimeglumine of 0.1 mmol per kilogram of body weight in patients undergoing contrast material-enhanced magnetic resonance (MR) angiography of the pelvis, thigh, and lower leg (excluding foot) for suspected or known peripheral arterial occlusive disease.

Materials and Methods:

Institutional review board approval was granted from each center and informed written consent was obtained from all patients. Between November 2006 and January 2008, 96 patients (62 men, 34 women; mean age, 63.7 years \pm 10.4 [standard deviation]; range, 39–86 years) underwent two identical examinations at 1.5 T by using three-dimensional spoiled gradient-echo sequences and randomized 0.1-mmol/kg doses of each agent. Images were evaluated on-site for technical adequacy and quality of vessel visualization and offsite by three independent blinded readers for anatomic delineation and detection/exclusion of pathologic features. Comparative diagnostic performance was determined in 31 patients who underwent digital subtraction angiography. Data were analyzed by using the Wilcoxon signed-rank, McNemar, and Wald tests. Interreader agreement was determined by using generalized κ statistics. Differences in quantitative contrast enhancement were assessed and a safety evaluation was performed.

Results:

Ninety-two patients received both agents. Significantly better performance ($P < .0001$; all evaluations) with gadobenate dimeglumine was noted on-site for technical adequacy and vessel visualization quality and offsite for anatomic delineation and detection/exclusion of pathologic features. Contrast enhancement ($P \leq .0001$) and detection of clinically relevant disease ($P \leq .0028$) were significantly improved with gadobenate dimeglumine. Interreader agreement for stenosis detection and grading was good to excellent ($\kappa = 0.749$ and 0.805, respectively). Mild adverse events were reported for four (six events) and five (eight events) patients after gadobenate dimeglumine and gadopentetate dimeglumine, respectively.

Conclusion:

Higher-quality vessel visualization, greater contrast enhancement, fewer technical failures, and improved diagnostic performance are obtained with gadobenate dimeglumine, relative to gadopentetate dimeglumine, when compared intraindividually at 0.1-mmol/kg doses in patients undergoing contrast-enhanced MR angiography for suspected peripheral arterial occlusive disease.

© RSNA, 2010

Contrast material-enhanced MR angiography is an accepted non-invasive alternative to conventional digital subtraction angiography (DSA) for assessment of peripheral arterial occlusive disease (1–5). However, a drawback of contrast-enhanced MR angiography is insufficient contrast enhancement for accurate visualization and diagnosis if the contrast agent dose is too low (6–9). This is particularly relevant in the peripheral runoff vasculature where vessels are smaller and highly susceptible to flow alterations in heavily diseased patients; it is also relevant if parallel imaging techniques are used because these techniques decrease the signal-to-noise ratio (SNR) (10).

One approach to improving SNR is to increase the contrast agent dose (11–14). Unfortunately, high gadolinium doses are inadvisable because of the risk of nephrogenic systemic fibrosis

(15–18). This is particularly relevant for elderly patients with peripheral arterial occlusive disease, not only because of the high gadolinium doses routinely administered, but also because these patients frequently have associated renal insufficiency or end-stage renal disease (19,20).

Gadobenate dimeglumine (MultiHance; Bracco Imaging, Milan, Italy) is a gadolinium-based contrast agent approved in Europe, Canada, and elsewhere for contrast-enhanced MR angiography at a dose of 0.1 mmol per kilogram of body weight. Compared with conventional agents, gadobenate dimeglumine possesses increased R1 relaxivity (21–25), which permits lower overall doses to achieve similar contrast enhancement and equivalent image quality to that achieved with conventional agents at higher doses (26,27). Previously, a comparison of equivalent 0.1-mmol/kg doses of gadobenate dimeglumine and gadopentetate dimeglumine (Magnevist; Bayer-Schering, Berlin, Germany) in healthy volunteers revealed superior vascular enhancement with gadobenate dimeglumine, particularly in smaller, more distal vessels (28). Improved diagnostic performance with gadobenate dimeglumine for below-knee segments was subsequently shown by Wyttenbach et al (29) in a comparison with gadoterate meglumine. However, Wyttenbach et al administered a standard volume of 34 mL, which corresponds to a high dose of almost 0.25 mmol/kg for a 70-kg person.

Our prospective study was performed to compare the image quality and diagnostic performance achieved with equivalent 0.1-mmol/kg doses of gadobenate dimeglumine and gadopentetate dimeglumine in patients undergoing contrast-enhanced MR angiogra-

phy for suspected or known peripheral arterial occlusive disease.

Materials and Methods

Our phase III, double-blind, multicenter, randomized, intraindividual crossover comparison was sponsored by Bracco Imaging (Milan, Italy) and was registered at www.clintrials.gov (ref. 00408083). Institutional review board and regulatory approval were granted from each center and all patients gave written informed consent. Two authors (M.A.K. and G.P.) are employees of Bracco Imaging. The lead authors (S.C.G. and T.L.) had complete access to all study results, and all authors had full control of the data and statistical results included in this report, including data that might have represented a potential conflict of interest to Bracco and employees thereof.

Patients

Ninety-six adult patients with suspected moderate to severe peripheral arterial occlusive disease, determined on the basis of the Fontaine classification (30), were enrolled at seven sites in Europe between November 2006 and January 2008. Centers enrolled 25, 25, 15, 11, nine, seven, and four patients.

Advances in Knowledge

- For contrast material-enhanced MR angiography of peripheral arterial vasculature from the pelvis to the calves, a dose of 0.1 mmol/kg of gadobenate dimeglumine is superior to an equivalent dose of gadopentetate dimeglumine in terms of quality of vessel visualization ($P < .0001$), technical failure rate ($P < .0001$), and level of contrast enhancement ($P < .0001$).
- Significantly improved detection ($P \leq .0017$) of clinically relevant stenoses (>50% vessel lumen narrowing) is achieved with 0.1 mmol/kg of gadobenate dimeglumine compared with 0.1 mmol/kg of gadopentetate dimeglumine, relative to digital subtraction angiography.
- Significant increases ($P < .0001$) in contrast-to-noise ratios of 45.0%–59.6% in the pelvis, 55.4%–100.6% in the thigh, and 49.2%–66.5% in the calf are achieved with 0.1 mmol/kg of gadobenate dimeglumine relative to 0.1 mmol/kg of gadopentetate dimeglumine.

Implication for Patient Care

- In most patients, a dose of 0.1 mmol/kg of gadobenate dimeglumine is sufficient for adequate depiction of the peripheral arterial tree from the pelvis to the calves.

Published online

10.1148/radiol.09090357

Radiology 2010; 255:988–1000

Abbreviations:

CNR = contrast-to-noise ratio
 DSA = digital subtraction angiography
 SI = signal intensity
 SNR = signal-to-noise ratio

Author contributions:

Guarantors of integrity of entire study, S.C.G., M.A.K., G.P., T.L.; study concepts/study design or data acquisition or data analysis/interpretation, all authors; manuscript drafting or manuscript revision for important intellectual content, all authors; approval of final version of submitted manuscript, all authors; literature research, T.F.I.M., H.K., M.A.K., T.L.; clinical studies, S.C.G., T.F.I.M., S.M., S.A.T., H.J.M., H.K., A.V., J.V., M.N.W., C.E.M.B., T.L.; experimental studies, T.L.; statistical analysis, T.L.; and manuscript editing, S.C.G., S.M., S.A.T., C.U.H., H.J.M., H.K., J.V., M.N.W., M.A.K., G.P., T.L.

See Materials and Methods for pertinent disclosures.

Patients with moderate to severe renal impairment (glomerular filtration rate or estimated glomerular filtration rate, <60 mL/min/1.73 m²), congestive heart failure (New York Heart Association functional class IV), or a known allergy to either agent were considered as ineligible and were not enrolled. Patients were also ineligible if they had received or were scheduled to receive another contrast medium in the 24 hours preceding and until 24 hours following either examination, any other investigational compound and/or medical device within 30 days before and until 24 hours after administration of the second agent, or were scheduled to undergo any intervention for peripheral arterial occlusive disease between the two examinations. Finally, patients were ineligible if they were pregnant or lactating or if they had any medical condition or other circumstances (eg, metallic vascular stent, pacemaker, severe claustrophobia) that would decrease the chances of obtaining adequate examination results or which would preclude proximity to a strong magnetic field.

Eligible patients were randomized prospectively to two groups (A and B). Group A ($n = 52$) received gadobenate dimeglumine for the first examination and gadopentetate dimeglumine for the second; patients in group B ($n = 44$) received the contrast agents in reverse order (Fig 1).

MR Angiographic Examinations

All procedures were performed at 1.5 T by using commercially available imagers (Avanto [$n = 37$], Siemens Medical Solutions, Erlangen, Germany; and Intera [$n = 25$], Achieva [$n = 25$], and Gyroscan Intera [$n = 9$], Philips Medical Systems, Best, the Netherlands) equipped with a gradient of at least 30 mT/m and an automatic moving table.

Peripheral arterial vasculature from the aortic bifurcation to the lower leg was imaged in three stations comprising the pelvis, thigh, and calf (excluding the foot). To ensure complete coverage of each station, images were acquired with a small overlap between consecutive data

Figure 1

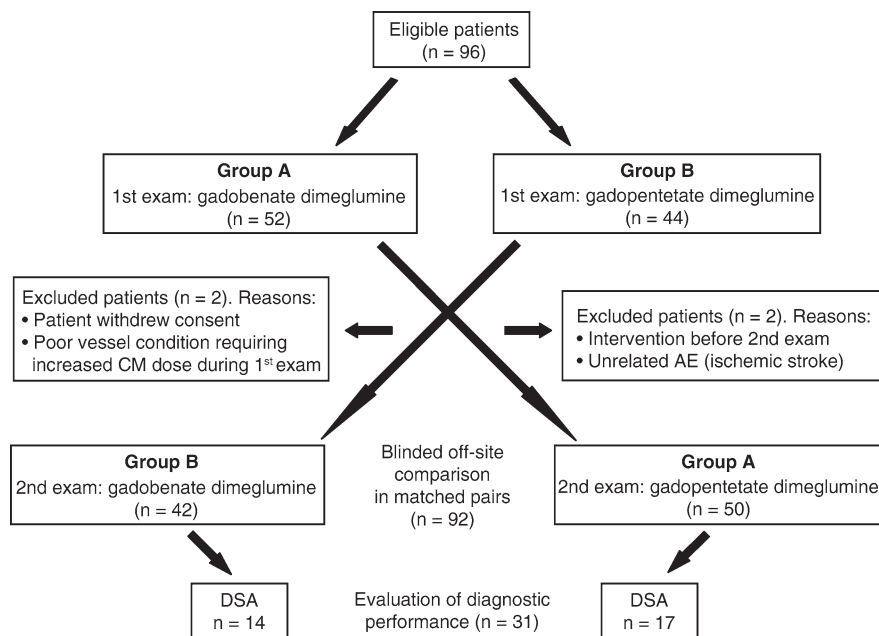


Figure 1: Flow diagram of patient enrollment and evaluation. AE = adverse event, CM = contrast medium.

sets. Both examinations in each patient were identical with respect to orientation, field-of-view, sequence parameters, spatial resolution, and contrast agent volume and injection rate. The interval between examinations in each patient ranged between 3 and 13 days, although in most patients ($n = 86$), the interval between examinations ranged between 4 and 7 days.

Each examination comprised an unenhanced three-dimensional spoiled gradient-echo (mask) sequence and a contrast-enhanced three-dimensional spoiled gradient-echo sequence. The sequence parameters necessarily varied slightly between centers because of the variety of imaging systems utilized; however, each sequence obtained at each center was selected to meet minimal requirements for image acquisition and interpretability. The range of parameters for each station is shown in Table 1. Parallel imaging techniques and fat suppression were recommended. Timing for table translation from one station to the next was determined by the duration of the acquisition for each station and was identical for both examinations in each patient.

Contrast-enhanced MR angiography was performed after administration of a dose of 0.1 mmol/kg (0.2 mL/kg of the available 0.5-mol formulation) gadobenate dimeglumine or gadopentetate dimeglumine. Injections were either monophasic ($n = 34$) at 1–3 mL/sec or biphasic ($n = 62$), administered at 1–1.5 mL/sec for the first injection and 0.5–0.8 mL/sec for the second. The injection scheme was identical for both examinations in each patient and were performed with a power injector (Medrad, Indianola, PA) and flushed with 20 mL of saline.

Timing for the contrast-enhanced MR angiography sequence was based on a bolus timing acquisition in 53 subjects or by means of automatic bolus detection (Bolus Trak, Philips Medical Systems [$n = 36$]; MR fluoroscopic triggering [$n = 7$]). The approach to sequence timing was the same for both examinations in each patient.

MR Angiographic Assessment

On-site assessment.—Unpaired assessments were performed by on-site investigators (S.C.G., T.M., S.M., S.A.T., C.U.H., H.J.M., H.K., and T.L., each with ≥ 8 years experience with

Table 1

Range of Sequence Parameters by Vascular Station

Parameter	Pelvic Station	Thigh Station	Calf Station
Repetition time (msec)*	2.5, 4.2	2.5, 5.0	2.9, 5.1
Echo time (msec) *	1.0, 1.3	1.0, 1.5	1.0, 1.6
Flip angle (degrees)*	15, 40	15, 40	15, 40
Number of signals*	1, 1	1, 1	1, 1
Minimum field of view	470 × 264 × 78	470 × 306 × 61	448 × 278 × 91
Maximum field of view	470 × 353 × 848	451 × 512 × 180	451 × 316 × 256
Acquisition matrix*	336 × 180, 512 × 250	336 × 180, 384 × 308	202 × 384, 480 × 480
No. of sections/partitions*	52, 104	51, 88	60, 160
Parallel acquisition factor*	2, 2	2, 2	0, 3
Section thickness (mm) *	2, 3	1, 3	1, 2
Acquisition time (sec) *	11, 18	11, 19	11, 96

* Data are the minimum followed by the maximum values.

contrast-enhanced MR angiography) who were blinded to the contrast agent used. Evaluation of each station was performed initially for technical adequacy (adequate or inadequate; ie, stations were inadequate if they were outside the scanning volume or if the acquisition was mistimed). Adequate image sets were thereafter assessed for vessel visualization quality at each station by using a four-point scale in which 1 = poor, 2 = sufficient, 3 = good, and 4 = excellent visualization.

Offsite assessment.—Offsite assessments were performed by three independent radiologists (A.V., J.V., and M.N.W., each with ≥10 years experience with contrast-enhanced MR angiography) who were unaffiliated with the study sites and blinded to patient information and contrast agent. Images were evaluated in matched pairs; in each case, axial source images and volumetric maximum intensity projection reconstructions from the two examinations in each patient were displayed simultaneously on two workstations (AquariusNet Viewer for Windows; TeraRecon, San Mateo, Calif).

Evaluations were performed by using an arterial segmentation scheme comprising 23 arterial segments across the pelvis (aortic bifurcation and left and right common, internal, and external iliac arteries), thigh (left and right common, superficial, and deep femoral arteries and left and right popliteal ar-

teries), and calf (left and right tibiofibular trunks, left and right anterior and posterior tibial arteries, and left and right peroneal arteries).

Qualitative assessments were performed for vessel anatomic delineation and pathologic feature detection/exclusion. Both comparisons were performed by using three-point scales, rated as -1 (examination 1 was superior), 0 (examinations were equal), or 1 (examination 2 was superior).

Quantitative measurements of signal intensity (SI) were performed for regions of interest positioned on each of three vessels and three muscles (one each per station) in each patient. Regions of interest were typically circular and large enough (≤0.5 cm²) to obtain reliable measurements at areas of maximum SI in the vessel lumen and on homogenous regions of muscle. Region of interest positioning was similar for the two examinations in each patient. SI measurements were obtained on a pixel-by-pixel basis by using quantitative analysis software (Aquarius Net Server, version 1.8.3.6; TeraRecon).

Absolute values for SNR and contrast-to-noise ratio (CNR) were not determined because of the variable use of parallel imaging across the investigational centers. Therefore, quantitative enhancement was compared in terms of contrast ratio and vessel-to-background signal ratio, which were calculated by using the following equations:

Contrast ratio =

$$\frac{CNR_{gb}}{CNR_{gp}} = \frac{\left(\frac{SI_{vessel} - SI_{muscle}}{SD_{muscle}} \right)}{\left(\frac{SI_{vessel} - SI_{muscle}}{SD_{muscle}} \right)}$$

and vessel-to-background signal ratio =

$$\frac{\left(\frac{SI_{vessel}}{SD_{muscle}} \right)_{\text{gadobenate dimeglumine}}}{\left(\frac{SI_{vessel}}{SD_{muscle}} \right)_{\text{gadopentetate dimeglumine}}}$$

where CNR_{gb} and CNR_{gp} are the CNRs of gadobenate dimeglumine and gadopentetate dimeglumine, respectively; SI_{vessel} and SI_{muscle} are the mean vessel and muscle SIs, respectively; and SD_{muscle} is the standard deviation of the muscle SI.

Diagnostic Performance

Digital subtraction angiography.—The 96 enrolled patients included 31 who underwent both contrast-enhanced MR angiography and conventional DSA. DSA was performed 1–110 days before the first contrast-enhanced MR angiographic examination or 1–221 days after the second contrast-enhanced MR angiographic examination by injecting an iodinated contrast medium through a pigtail or straight 4–5-F catheter (Cordis, Miami, Fla) inserted via a femoral artery puncture by using the Seldinger technique. The approach to DSA was at the discretion of the investigating center and involved imaging in one (13 patients) or both (18 patients) legs. Pelvic images were acquired by using anteroposterior and right and/or left anterior oblique projections at angulations of 15°–30°, as appropriate. Most examinations were performed by using contrast media with iodine concentrations of more than 300 mg of iodine per milliliter. The total volume administered ranged between 100 and 150 mL. Individual injections of 15–40 mL were administered at rates of 4–12 mL/sec, depending on the vessel of interest.

Assessment of diagnostic performance.—Evaluation of DSA images was performed by a radiologist (C.E.M.B.,

with >10 years experience) who was unaffiliated with the study centers and blinded to all clinical and radiologic information. Images were managed and displayed in random order by using software (DICOMed Review, version 4.0; AetMed, Genova, Italy). The presence and extent of disease were determined for each segment by using a four-point scale: a score of 1, segment has no or mild stenosis ($\leq 25\%$); 2, segment has moderate stenosis ($>25\%$ but $\leq 50\%$); 3, segment has clinically relevant disease ($>50\%$ – 99%); and 4, segment has occlusion (100% lumen blockage). Stenoses detected at DSA were labeled for subsequent lesion matching.

Assessment of contrast-enhanced MR angiograms was thereafter performed by the offsite radiologists. Images were randomized and evaluated separately and independently in blinded fashion by using the same criteria as those used for the assessment of DSA images. Stenoses detected at contrast-enhanced MR angiography were labeled on maximum intensity projection images for subsequent lesion matching.

Safety Assessments

The 96 subjects were monitored for adverse events from the time informed consent was obtained until 24 hours after administration of the first contrast agent, and then from 24 hours before and until 24 hours after administration of the second contrast agent. Events were classified as serious (death, life-threatening, requiring/prolonging hospitalization) or nonserious (mild: no disability/incapacity, self-resolving; moderate: no disability/incapacity requiring treatment; or severe: temporary and/or mild disability/incapacity requiring treatment). Event severity and its relationship to the contrast agent (probable, possible, unrelated, or unknown) were determined by the investigating radiologist.

Statistical Analysis

The study was powered to show a 3:1 ratio of superiority for either contrast agent with an effect size of 0.125 and assuming an equal response in 50% of cases. Given the results of a χ^2 test of

specified proportions in three categories performed with software (nQuery, version 5.0; Statistical Solutions, Cork, Ireland), 78 subjects were needed for 80% of power at an α level of .05. Assuming a 30% dropout rate, enrolment of 100 subjects was required.

Contrast-enhanced MR angiography technical failure rates and vessel visualization quality were assessed overall and at each station by using the χ^2 and Wilcoxon rank-sum tests, respectively. Comparison of vessel anatomic delineation and pathologic feature detection/exclusion were performed by using the Wilcoxon signed-rank test. Comparison of quantitative enhancement was performed by using a mixed model with subject, period, sequence, and contrast agent group as variables.

Determinations of diagnostic performance (sensitivity, specificity, accuracy, positive predictive value [PPV], negative predictive value [NPV], and 95% confidence intervals) for the detection of clinically relevant disease ($>50\%$ stenosis or occlusion) (31–33) were performed as described elsewhere (34). Differences in sensitivity, specificity, and accuracy were compared by using the McNemar test. Differences in PPV and NPV were compared by using the Wald test, derived from a generalized estimating equation, with intraindividual correlation accounted for.

Interreader agreement was determined by using generalized weighted κ statistics and measured as a percentage agreement. Agreement was classified as excellent ($\kappa > 0.8$), good ($\kappa = 0.61$ – 0.8), moderate ($\kappa = 0.41$ – 0.6), fair ($\kappa = 0.21$ – 0.4), or poor ($\kappa \leq 0.2$) (35). All statistical tests were two-sided, with a P value of less than .05 indicating a significant difference and were performed by using dedicated software (SAS, version 8.2; SAS, Cary, NC).

Results

There were 96 patients enrolled (mean age, 63.7 years \pm 10.4 [standard deviation]; range, 39–86 years), including 62 men (mean age, 64.3 years \pm 9.4; range, 39–86 years) and 34 women (mean age, 61.2 years \pm 11.7; range, 40–81 years),

with 86 (90%) with moderate-to-severe claudication (Fontaine stage IIb [33]), five (5%) with ischemic rest pain (Fontaine stage III), and five (5%) with ulceration (Fontaine stage IV). Most subjects underwent contrast-enhanced MR angiography to confirm or evaluate a previously detected stenosis (43 of 96, 45%) or because of clinical symptoms suggestive of stenosis (45 of 96, 47%). Eight (8%) subjects underwent contrast-enhanced MR angiography to guide revascularization or as follow-up to a previous treatment.

The patients were randomized to group A (33 men, 19 women; mean age, 63.4 years \pm 10.4) or B (29 men, 15 women; mean age, 64.0 years \pm 10.5) (Fig 1). There were no between-group differences in sex distribution ($P = .803$), age ($P = .748$), weight ($P = .795$), or Fontaine stage ($P = .463$). Overall, 92 (96%) of 96 patients received both agents. Four patients (two from each group) discontinued prematurely after the first examination. On-site assessment of technical adequacy and safety was performed for all patients who received at least one contrast agent ($n = 94$ for both contrast agents).

The 31 patients with DSA comprised 17 from group A and 14 from group B. Twenty-six patients were classified with Fontaine stage IIb disease while three and two patients classified with Fontaine stages III and IV, respectively. There were no between-group differences in sex distribution ($P = .566$), age ($P = .744$), weight ($P = .927$), or Fontaine stage ($P = .903$).

On-Site Assessments

Technical failure rate.—A total of 564 stations were assessed (188 + 188 + 188; pelvis, thigh, and calf measurements) across the 94 patients who received at least one contrast agent. Overall, significantly fewer stations were technically inadequate after gadobenate dimeglumine than after gadopentetate dimeglumine (20 of 564, 3.5% vs 67 of 564, 11.9%; $P < .0001$, Table 2).

Vessel visualization quality.—Superior vessel visualization quality was noted with gadobenate dimeglumine at each station ($P < .0001$) (Table 3). Overall,

Table 2

Technical Failure Rates for Contrast-enhanced MR Angiography

Vascular Station	Gadobenate Dimeglumine		Gadopentetate Dimeglumine		P Value*
	Technically Inadequate Stations	Technical Failure Rate (%)	Technically Inadequate Stations	Technical Failure Rate (%)	
Pelvis (n = 188)	2	1.06	11	5.85	.0111
Thigh (n = 188)	1	0.53	24	12.77	<.0001
Calf (n = 188)	17	9.04	32	17.02	.0216
All stations (n = 564)	20	3.55	67	11.88	<.0001

Note.—Examinations were performed with gadobenate dimeglumine and gadopentetate dimeglumine at equivalent doses of 0.1 mmol/kg, as determined by on-site investigators.

* Determined by using the χ^2 test.

Table 3

Unpaired (On-site) Assessments of Quality of Vessel Visualization

Vascular Station and Contrast Agent	Quality Score				P Value
	1 (Poor)	2 (Sufficient)	3 (Good)	4 (Excellent)	
Pelvis					
Gadobenate dimeglumine	3 (1.6)	9 (4.8)	39 (20.7)	137 (72.9)	<.0001
Gadopentetate dimeglumine	13 (6.9)	18 (9.6)	61 (32.4)	96 (51.1)	
Thigh					
Gadobenate dimeglumine	3 (1.6)	11 (5.9)	37 (19.7)	137 (72.9)	<.0001
Gadopentetate dimeglumine *	26 (14.0)	22 (11.8)	37 (19.9)	101 (54.3)	
Calf					
Gadobenate dimeglumine	18 (9.6)	29 (15.4)	59 (31.4)	82 (43.6)	<.0001
Gadopentetate dimeglumine	38 (20.2)	32 (17.0)	63 (33.5)	55 (29.3)	
All					
Gadobenate dimeglumine	24 (4.3)	49 (8.7)	135 (23.9)	356 (63.1)	<.0001
Gadopentetate dimeglumine	77 (13.7)	72 (12.8)	161 (28.6)	252 (44.8)	

Note.—Data are number of vessel segments; percentages are in parentheses.

* Left and right images of the thigh were missing for one patient given gadopentetate dimeglumine, owing to a scanner reconstruction problem. This image set was considered technically inadequate and no assessment was performed for quality of visualization; therefore, only 186 thigh stations were assessed for this contrast agent.

491 (87.06%) of 564 evaluated stations were of good or excellent image quality when using gadobenate dimeglumine compared with 413 (73.49%) of 562 stations when using gadopentetate dimeglumine. The quality of visualization was poor primarily for vessels in the calf (9.6% and 20.2% of vessels after gadobenate dimeglumine and gadopentetate dimeglumine administration, respectively) (Fig 2), and for vessels in the pelvis and thigh after gadopentetate dimeglumine (6.9% and 14.0% of vessels, respectively). Overall, 77 (13.7%) stations were of poor image quality when using gadopentetate dimeglumine

compared with 24 (4.3%) stations when using gadobenate dimeglumine.

Off-Site Assessments

Qualitative.—Gadobenate dimeglumine improved vessel anatomic delineation and pathologic feature detection/exclusion at each station (Table 4, Fig 3; $P < .0001$). Three-reader agreement was noted for 48–63 (52.7%–70.0%) patients across both endpoints at all vascular stations, resulting in a general-ized κ of 0.37–0.44.

Quantitative.—Significant increases ($P < .0001$; all readers, all evaluations) in CNR of 45.0%–59.6% (pelvis),

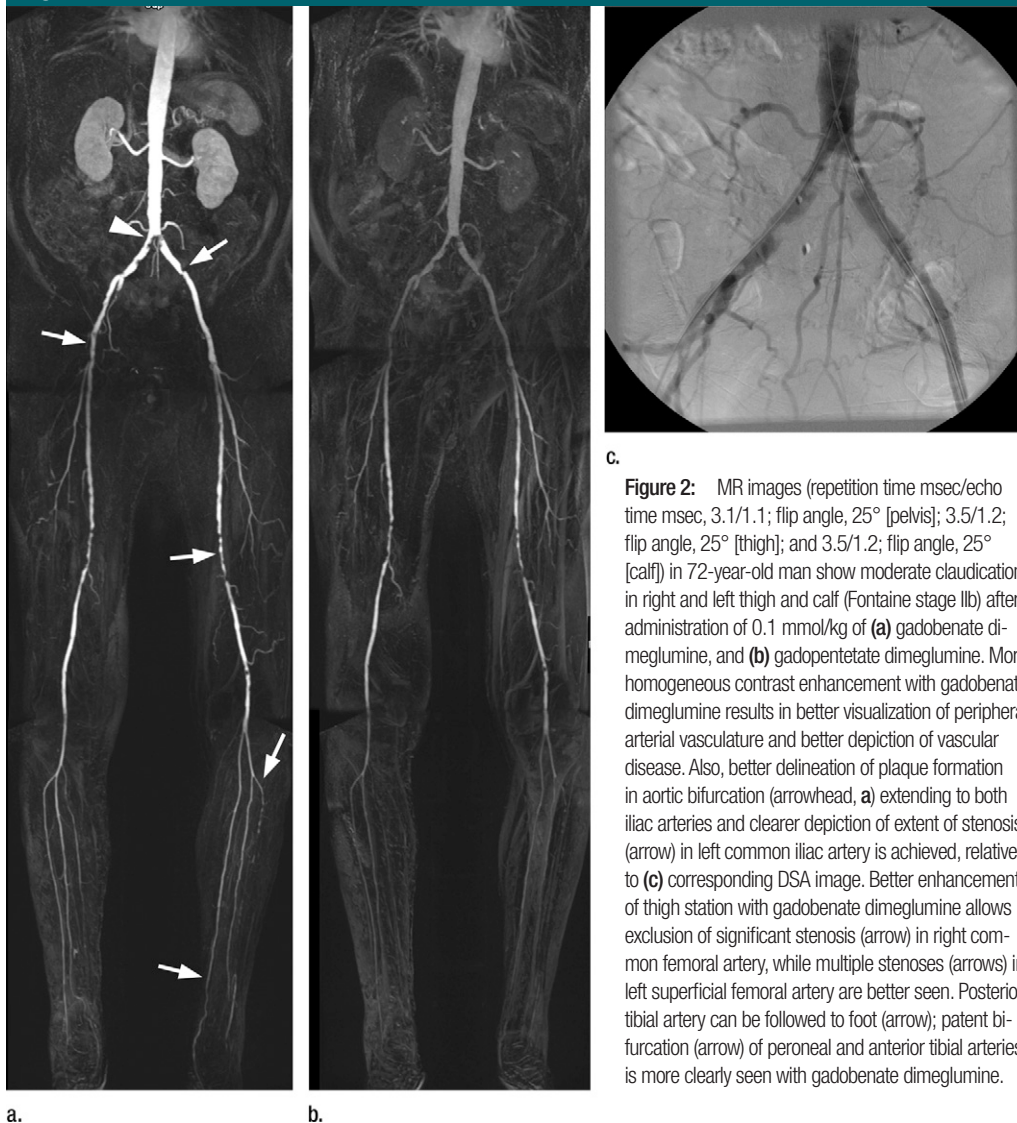
55.4%–100.6% (thigh), and 49.2%–66.5% (calf) were obtained with gadobenate dimeglumine compared with gadopentetate dimeglumine. The corresponding contrast ratios for gadobenate dimeglumine relative to gadopentetate dimeglumine ranged from 1.45 to 1.6 (pelvis), 1.55 to 2.0 (thigh), and 1.49 to 1.67 (calf). Significant increases ($P < .0001$) in vessel-to-background signal were similarly obtained with relative increases of 44.7%–55.0% (pelvis), 49.3%–90.9% (thigh), and 43.0%–58.1% (calf), corresponding to vessel-to-background signal ratios per patient of 1.42–1.55 (pelvis), 1.49–1.91 (thigh), and 1.43–1.58 (calf).

Diagnostic performance.—A total of 397 vascular segments were assessed across the 31 evaluated patients. DSA helped show clinically relevant disease in 127 (32.0%) of 397 segments. Each blinded reader reported significantly better ($P \leq .0017$) diagnostic performance with gadobenate dimeglumine than with gadopentetate dimeglumine (increases of 11.0%–18.1% in sensitivity, 4.4%–9.3% in specificity, and 7.8%–10.1% in accuracy) (Table 5; Fig 4). Each reader also reported significantly higher ($P \leq .0028$) predictive values with gadobenate dimeglumine, with differences ranging from 12.7% to 19.3% for PPV and 5.5% to 7.9% for NPV.

Good to excellent reader agreement for stenosis detection and grading was noted. All three readers agreed on 591 (90.2%) of 655 segments assessed on gadobenate dimeglumine-enhanced images ($\kappa = 0.805$) compared with 529 (87.6%) of 604 segments assessed on gadopentetate dimeglumine-enhanced images ($\kappa = 0.749$).

Safety.—Six adverse events (three reports of dizziness and one report each of nausea, dysgeusia, and pruritus) were reported by four (4%) patients after gadobenate dimeglumine compared with eight adverse events (one report each of eye irritation, nausea, vomiting, chest pain, heat sensation, dizziness, dysgeusia, and hyperhidrosis) reported by five (5%) patients after gadopentetate dimeglumine. All adverse events were nonserious and mild in intensity.

Figure 2



c.

Figure 2: MR images (repetition time msec/echo time msec, 3.1/1.1; flip angle, 25° [pelvis]; 3.5/1.2; flip angle, 25° [thigh]; and 3.5/1.2; flip angle, 25° [calf]) in 72-year-old man show moderate claudication in right and left thigh and calf (Fontaine stage IIb) after administration of 0.1 mmol/kg of (a) gadobenate dimeglumine, and (b) gadopentetate dimeglumine. More homogeneous contrast enhancement with gadobenate dimeglumine results in better visualization of peripheral arterial vasculature and better depiction of vascular disease. Also, better delineation of plaque formation in aortic bifurcation (arrowhead, a) extending to both iliac arteries and clearer depiction of extent of stenosis (arrow) in left common iliac artery is achieved, relative to (c) corresponding DSA image. Better enhancement of thigh station with gadobenate dimeglumine allows exclusion of significant stenosis (arrow) in right common femoral artery, while multiple stenoses (arrows) in left superficial femoral artery are better seen. Posterior tibial artery can be followed to foot (arrow); patent bifurcation (arrow) of peroneal and anterior tibial arteries is more clearly seen with gadobenate dimeglumine.

a.

b.

Discussion

Our study confirms previous findings (28) in showing that a dose of 0.1 mmol/kg of gadobenate dimeglumine is superior to an equivalent dose of gadopentetate dimeglumine for contrast-enhanced MR angiography in patients with peripheral arterial occlusive disease. Three blinded readers each reported better vessel anatomic delineation and improved detection/exclusion of pathologic features in significantly more ($P < .0001$) patients with gadobenate dimeglumine. In addition, the detection and correct grading of clinically

relevant stenoses were significantly superior ($P \leq .0017$) with gadobenate dimeglumine for each reader.

In terms of diagnostic accuracy, our values for gadobenate dimeglumine compare favorably with values from meta-analyses (31–33) and imply that correct patient management decisions are achievable in approximately 90% of cases. In comparison, the accuracy with 0.1 mmol/kg of gadopentetate dimeglumine was significantly lower ($P < .0001$). In part, the poorer diagnostic performance with gadopentetate dimeglumine can be ascribed to the dose

administered; in routine practice, conventional contrast agents such as gadopentetate dimeglumine are typically used at higher doses of up to 0.3 mmol/kg (13,31,37,38). Although a study that compared single and triple doses of gadodiamide for contrast-enhanced MR angiography of the lower extremities revealed more accurate stenosis grading with the lower dose (7), a study that compared 0.1-mmol/kg doses of gadodiamide and gadopentetate dimeglumine for detection of clinically relevant aortoiliac disease determined overall accuracy values of just 56.4% and 52.8%,

Table 4

Qualitative Comparison Assessment by Off-Site Readers

Parameter	Pelvis (n = 91)		Thigh (n = 90)		Calf (n = 91)	
	Gadobenate Dimeglumine	Gadopentetate Dimeglumine	Gadobenate Dimeglumine	Gadopentetate Dimeglumine	Gadobenate Dimeglumine	Gadopentetate Dimeglumine
Vessel anatomic delineation						
Reader 1	59 (64.8)	11 (12.1)	66 (73.3)	5 (5.6)	60 (65.9)	3 (3.3)
Reader 2	52 (57.1)	6 (6.6)	70 (77.8)	3 (3.3)	63 (69.2)	5 (5.5)
Reader 3	61 (67.0)	6 (6.6)	75 (83.3)	8 (8.9)	62 (68.1)	8 (8.8)
Pathologic feature detection/exclusion						
Reader 1	45 (49.5)	8 (8.8)	52 (57.8)	1 (1.1)	49 (53.8)	0
Reader 2	42 (46.2)	5 (5.5)	61 (67.8)	3 (3.3)	56 (61.5)	4 (4.4)
Reader 3	43 (47.3)	6 (6.6)	60 (66.7)	6 (6.7)	55 (60.4)	7 (7.7)

Note.—Qualitative comparison performed when one contrast agent was rated higher than the other for vessel delineation and pathologic feature detection/exclusion.

Table 5

Diagnostic Performance of MR Angiography of Peripheral Arterial Vasculature

Contrast Agent	Sensitivity	Specificity	Accuracy	Positive Predictive Value	Negative Predictive Value
Reader 1					
Gadobenate dimeglumine	75.6 (96/127) [68.1, 83.1]	95.9 (259/270) [93.5, 98.3]	89.4 (355/397) [86.4, 92.4]	89.7 (96/107) [83.9, 95.5]	89.3 (259/290) [85.7, 92.9]
Gadopentetate dimeglumine	60.6 (77/127) [52.1, 69.1]	91.5 (247/270) [88.2, 94.8]	81.6 (324/397) [77.8, 85.4]	77.0 (77/100) [68.8, 85.2]	83.2 (247/297) [78.9, 87.5]
P Value	$P < .0001$ [8.4, 21.5]	$P = .0005$ [2.0, 6.9]	$P < .0001$ [5.1, 10.5]	$P = .0016$ [2.6, 22.8]	$P < .0001$ [0.1, 11.6]
Reader 2					
Gadobenate dimeglumine	80.3 (102/127) [73.4, 87.2]	95.9 (259/270) [93.5, 98.3]	90.9 (361/397) [88.1, 93.7]	90.3 (102/113) [84.8, 95.8]	91.2 (259/284) [87.9, 94.5]
Gadopentetate dimeglumine	69.3 (88/127) [61.3, 77.3]	86.7 (234/270) [82.7, 90.8]	81.1 (322/397) [77.2, 85.0]	71.0 (88/124) [63.0, 79.0]	85.7 (234/273) [81.5, 89.9]
P Value	$P = .0017$ [4.4, 17.7]	$P < .0001$ [4.9, 13.7]	$P < .0001$ [6.2, 13.5]	$P = .0019$ [9.6, 29.0]	$P = .0009$ [0.2, 10.8]
Reader 3					
Gadobenate dimeglumine	82.7 (105/127) [76.1, 89.3]	95.9 (259/270) [93.5, 98.3]	91.7 (364/397) [89.0, 94.4]	90.5 (105/116) [85.2, 95.8]	92.2 (259/281) [89.1, 95.3]
Gadopentetate dimeglumine	64.6 (82/127) [56.3, 72.9]	89.6 (242/270) [86.0, 93.2]	81.6 (324/397) [77.8, 85.4]	74.5 (82/110) [66.4, 82.6]	84.3 (242/287) [80.1, 88.5]
P Value	$P < .0001$ [10.4, 25.8]	$P = .0016$ [2.5, 10.1]	$P < .0001$ [6.4, 13.7]	$P = .0028$ [6.3, 25.7]	$P = .0008$ [2.7, 13.1]

Note.—Data are percentages; raw numbers are in parentheses; 95% confidence intervals are in square brackets. Analysis was performed per segment; the denominator was the number of segments visualized by using DSA. All uninterpretable contrast-enhanced MR angiograms were considered inaccurate for all determinations. Significant differences in sensitivity, specificity, and accuracy were determined by using the McNemar test. Significant differences in positive and negative predictive values were determined by using the Wald test. Differences and their confidence intervals for sensitivity, specificity, and accuracy are estimated by using a paired binary approach. The confidence intervals for sensitivity, specificity, accuracy, negative and positive predictive values and the differences in them are calculated given a normal approximation of binomial distribution.

respectively (8). In that study, the poor diagnostic performance with both contrast agents was attributed to the relatively low doses administered. Other studies that have compared gadobenate dimeglumine with gadopentetate dimeglumine and other conventional agents for contrast-enhanced MR angiography (26–28,38,39) and other applications

(40–46) have similarly revealed improved performance with gadobenate dimeglumine when comparisons are performed at equivalent dose levels. Interestingly however, Wyttenbach et al (29) noted few differences between gadobenate dimeglumine and gadoterate meglumine for assessment of peripheral arterial occlusive disease from the

renal to the popliteal arteries. However, rather than adopt an intraindividual crossover study design as utilized here, Wyttenbach et al used an interindividual parallel group design and higher overall doses of contrast agent. On the one hand, an interindividual study design is subject to variability between study groups, which may have affected

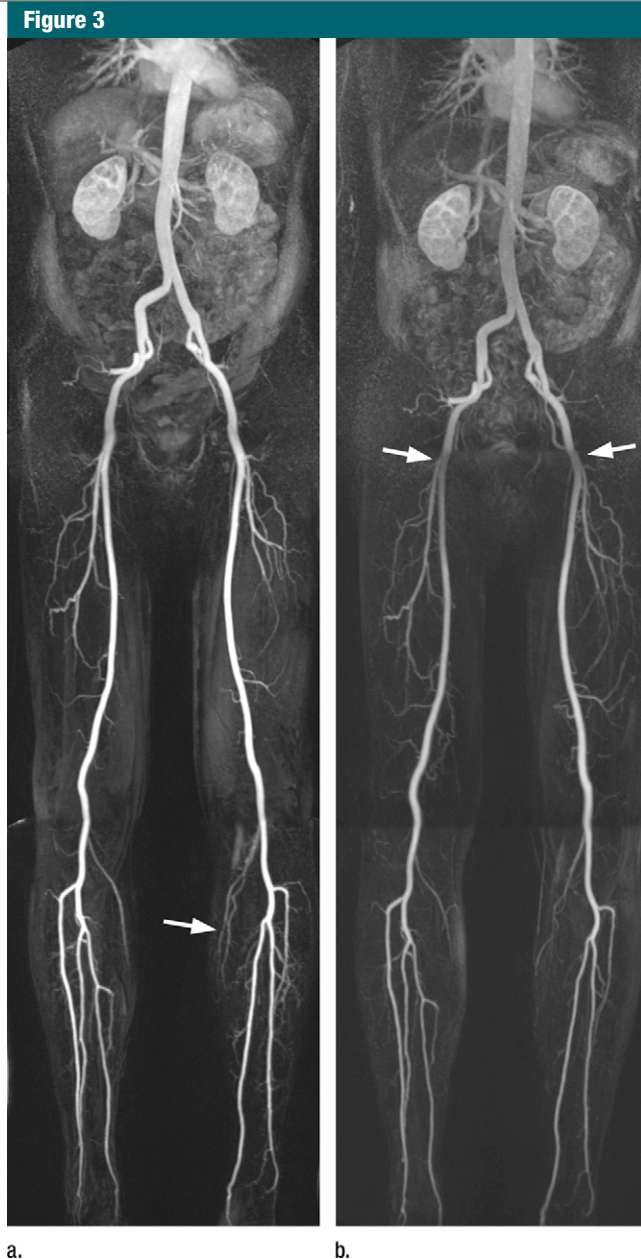


Figure 3: MR images (3.0/1.1; flip angle, 25° [pelvis]; 2.9/1.0; flip angle, 25° [thigh]; and 3.0/1.1; 25° [calf]) in 68-year-old man show moderate claudication in right and left calf (Fontaine stage IIb) after administration of 0.1 mmol/kg of (a) gadobenate dimeglumine, and (b) gadopentetate dimeglumine. Although on-site investigators considered quality of vessel visualization as excellent across all territories in both limbs for both agents, contrast enhancement obtained with gadobenate dimeglumine is much more homogeneous, with no decrease of signal intensity at boundaries between acquisition steps (arrows, b). Also, small vessels are more clearly seen with gadobenate dimeglumine, with better depiction of small arteries in popliteal area (arrow, a).

the overall findings; on the other hand, the higher doses used may have been appropriate for gadopentetate dimeglumine

but disadvantageous for gadobenate dimeglumine. In this regard, higher doses of 0.2 mmol/kg of gadobenate dimeglu-

mine have been shown as deleterious in terms of image quality and diagnostic performance (9,47,48). Notably, a 0.1-mmol/kg dose of gadobenate dimeglumine provides similar image quality and contrast enhancement to that achieved with a double 0.2-mmol/kg dose of gadopentetate dimeglumine for contrast-enhanced MR angiography of the renal arteries and abdominal aorta (26) and carotid arteries (27).

Of particular relevance for routine practice were the low technical failure rate and improved image quality in the calves. Similar findings have been noted by Knopp et al (28) and Wyttenbach et al (29), despite the higher dose used in the latter study. In terms of diagnostic performance, a recent multicenter Phase III study that used a dose of 0.1 mmol/kg of gadobenate dimeglumine revealed diagnostic accuracy values of 85.0%–87.5% in the iliofemoral arteries and 74.5%–77.5% in the calf arteries (34). Conversely, assessment of below-knee arteries was not performed in equivalent Phase III studies with other contrast agents at doses of 0.1 mmol/kg or less (8,49,50). Given that the quality of calf vessel visualization in our study was poor in significantly more patients after 0.1 mmol/kg gadopentetate dimeglumine than after 0.1 mmol/kg gadobenate dimeglumine, it is possible that worse overall results might have been obtained in these other studies had below-knee vessels been included in the assessment. More importantly, the comparatively poor quality of vessel visualization with gadopentetate dimeglumine in our study and elsewhere (28,29), particularly for below-knee arteries, would necessitate a repeat examination with associated increased costs.

An unfortunate consequence of the large number of sites involved in our study was a variable approach to the use of parallel imaging. Since local field inhomogeneities are known to affect SI determinations if parallel imaging techniques are utilized (51,52), it was deemed inappropriate to calculate absolute SNR and CNR values. Nevertheless, the determinations of contrast ratio and vessel-to-background signal ratio confirm

Figure 4

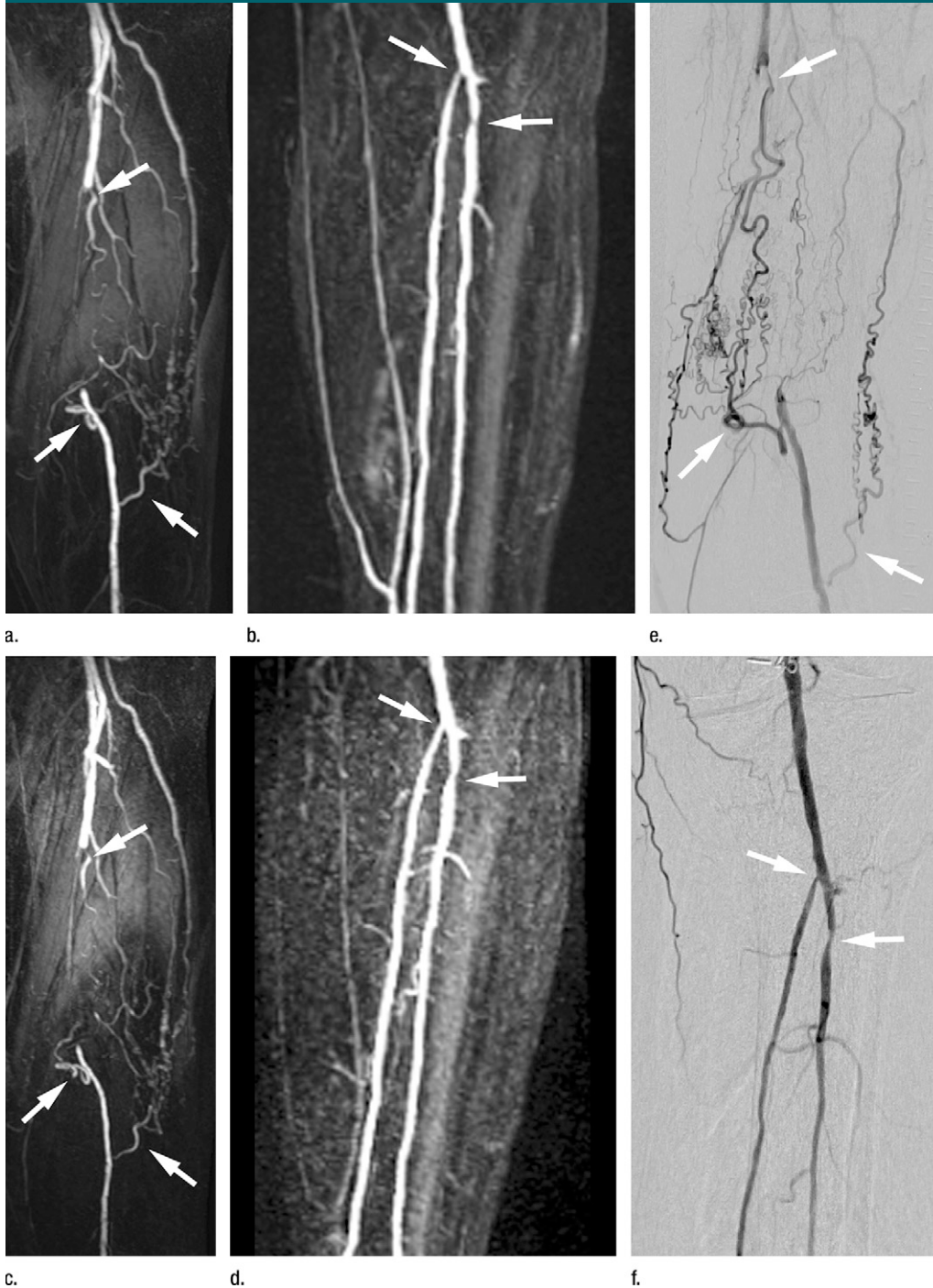


Figure 4: MR images in 74-year-old man show moderate claudication in right and left calf (Fontaine IIb) after (a,b) gadobenate dimeglumine, and (c,d) gadopentetate dimeglumine. On-site vessel visualization was excellent in pelvis and thigh and good in calf after gadobenate dimeglumine and good at all stations after gadopentetate dimeglumine. (e) DSA shows complete occlusion (upper arrow) of superficial femoral artery and multiple collateral vessels (lower arrows), both of which are visible with both contrast agents. Greater detail is apparent on a and b, as evidenced by collateral vessel just proximal to occlusion, which shows very good correlation with DSA. (f) Calf DSA shows high-grade stenosis (upper arrow) at origin of posterior tibial artery and moderate stenosis (lower arrow) of peroneal artery. Good correlation for both stenoses was noted for a and b; underestimation of stenosis and poorer overall image quality were apparent for c and d.

previous findings (26–28,38,40–44) in showing greater quantitative enhancement with gadobenate dimeglumine.

One limitation of our study was that assessments were not performed in the foot. Ischemic disease of the foot is an important complication of peripheral arterial occlusive disease, particularly in the diabetic population, and accurate assessment of the pedal vessels is necessary for possible revascularization or bypass procedures (53). The foot was not evaluated primarily because it is often not indicated in patients with intermittent claudication only, and because examination of the entire arterial vasculature from the pelvis to the foot is not yet a widely used procedure owing to technical difficulties associated with acquisition over large anatomic areas.

Other limitations were that state-of-the-art sequences and hardware were not utilized at all centers and that a diagnostic reference standard was not available for all patients. Concerning the imaging parameters utilized, these were a reflection of the multicenter study design and the fact that not all centers were equipped with advanced hardware. On the other hand, the sequences used were those used routinely at the individual centers and thus the results may reflect those that might be obtained routinely at similarly equipped centers. Concerning the lack of a reference standard for all patients, this reflects the fact that contrast-enhanced MR angiography has fully replaced DSA at most centers for purely diagnostic imaging. The fact that DSA was performed in only 31 patients indicates that the contrast-enhanced MR angiography findings were invariably considered adequate for subsequent patient treatment decisions. However, it should be kept in mind that the absence of DSA performed in all other patients is a potential source of bias for determinations of diagnostic performance because patients without abnormalities seen at contrast-enhanced MR angiography are typically not referred for DSA. Thus, the assessment of diagnostic performance is based on only a subset of patients with severe disease (54). It should also be kept in mind that

the diagnostic accuracy achieved with gadobenate dimeglumine was significantly greater ($P < .0001$) among the subgroup of patients for whom accurate diagnosis is most critical.

In summary, this study demonstrates that image quality and diagnostic accuracy for the detection of clinically relevant peripheral arterial occlusive disease are significantly improved at peripheral contrast-enhanced MR angiography with a dose of 0.1 mmol/kg of gadobenate dimeglumine compared with a dose of 0.1 mmol/kg of gadopentetate dimeglumine.

Acknowledgments: The authors thank Bastiaan Versluis, MD, of Maastricht University Medical Center for his extensive support in data acquisition, Jeffrey H. Maki, MD, of the University of Washington Medical Center (Seattle, Wash), for helpful suggestions regarding the evaluation of quantitative contrast enhancement, and Sharon Ma, MsC, of Bracco Diagnostics, for the statistical analyses performed.

References

- Ruehm SG, Hany TF, Pfammatter T, Schneider E, Ladd M, Debatin JF. Pelvic and lower extremity arterial imaging: diagnostic performance of three-dimensional contrast-enhanced MR angiography. *AJR Am J Roentgenol* 2000;174(4):1127–1135.
- Vavrik J, Rohrmoser GM, Madani B, Ersek M, Tscholakoff D, Bucek RA. Comparison of MR angiography versus digital subtraction angiography as a basis for planning treatment of lower limb occlusive disease. *J Endovasc Ther* 2004;11(3):294–301.
- Lapeyre M, Kobeiter H, Desgranges P, Rahmouni A, Becquemin JP, Luciani A. Assessment of critical limb ischemia in patients with diabetes: comparison of MR angiography and digital subtraction angiography. *AJR Am J Roentgenol* 2005;185(6):1641–1650.
- Drescher R, Haller S, Köster O, von Rothenburg T, Titschert A. Standard-protocol moving-table magnetic resonance angiography for planning of interventional procedures in patients with peripheral vascular occlusive disease. *Clin Imaging* 2006;30(6):382–387.
- Collins R, Burch J, Cranny G, et al. Duplex ultrasonography, magnetic resonance angiography, and computed tomography angiography for diagnosis and assessment of symptomatic, lower limb peripheral arterial disease: systematic review. *BMJ* 2007;334(7606):1257–1265.
- Thurnher SA, Capelastegui A, Del Olmo FH, et al. Safety and effectiveness of single- versus triple-dose gadodiamide injection-enhanced MR angiography of the abdomen: a phase III double-blind multicenter study. *Radiology* 2001;219(1):137–146.
- Krause U, Kroencke T, Spielhauer E, et al. Contrast-enhanced magnetic resonance angiography of the lower extremities: standard-dose vs. high-dose gadodiamide injection. *J Magn Reson Imaging* 2005;21(4):449–454.
- Schaefer PJ, Boudghene FP, Brambs HJ, et al. Abdominal and iliac arterial stenoses: comparative double-blinded randomized study of diagnostic accuracy of 3D MR angiography with gadodiamide or gadopentetate dimeglumine. *Radiology* 2006;238(3):827–840.
- Schneider G, Ballarati C, Grazioli L, et al. Gadobenate dimeglumine-enhanced MR angiography: diagnostic performance of four doses for detection and grading of carotid, renal, and aorto-iliac stenoses compared to digital subtraction angiography. *J Magn Reson Imaging* 2007;26(4):1020–1032.
- Wilson GJ, Hoogveen RM, Willinek WA, Muthupillai R, Maki JH. Parallel imaging in MR angiography. *Top Magn Reson Imaging* 2004;15(3):169–185.
- Zhang H, Maki JH, Prince MR. 3D contrast-enhanced MR angiography. *J Magn Reson Imaging* 2007;25(1):13–25.
- de Vries M, Nijenhuis RJ, Hoogveen RM, de Haan MW, van Engelsehoven JM, Leiner T. Contrast-enhanced peripheral MR angiography using SENSE in multiple stations: feasibility study. *J Magn Reson Imaging* 2005;21(1):37–45.
- Swan JS, Carroll TJ, Kennell TW, et al. Time-resolved three-dimensional contrast-enhanced MR angiography of the peripheral vessels. *Radiology* 2002;225(1):43–52.
- Boos M, Lentschig M, Scheffler K, Bongartz GM, Steinbrich W. Contrast-enhanced magnetic resonance angiography of peripheral vessels: different contrast agent applications and sequence strategies—a review. *Invest Radiol* 1998;33(9):538–546.
- Broome DR, Girguis MS, Baron PW, Cottrell AC, Kjellin I, Kirk GA. Gadodiamide-associated nephrogenic systemic fibrosis: why radiologists should be concerned. *AJR Am J Roentgenol* 2007;188(2):586–592.
- Sadowski EA, Bennett LK, Chan MR, et al. Nephrogenic systemic fibrosis: risk factors and incidence estimation. *Radiology* 2007;243(1):148–157.

17. Kallen AJ, Jhung MA, Cheng S, et al. Gadolinium-containing magnetic resonance imaging contrast and nephrogenic systemic fibrosis: a case-control study. *Am J Kidney Dis* 2008;51(6):966–975.
18. Abujudeh HH, Kaewlai R, Kagan A, et al. Nephrogenic systemic fibrosis after gadopentetate dimeglumine exposure: case series of 36 patients. *Radiology* 2009;253(1):81–89.
19. O'Hare A, Johansen K. Lower-extremity peripheral arterial disease among patients with end-stage renal disease. *J Am Soc Nephrol* 2001;12(12):2838–2847.
20. Matsumae T, Abe Y, Murakami G, Ishihara M, Ueda K, Saito T. Determinants of arterial wall stiffness and peripheral artery occlusive disease in nondiabetic hemodialysis patients. *Hypertens Res* 2007;30(5):377–385.
21. Pintaske J, Martirosian P, Graf H, et al. Relaxivity of gadopentetate dimeglumine (Magnevist), gadobutrol (Gadovist), and gadobenate dimeglumine (MultiHance) in human blood plasma at 0.2, 1.5, and 3 Tesla. [Published correction appears in *Invest Radiol* 2006;41(12):859.] *Invest Radiol* 2006;41(3):213–221.
22. Cavagna FM, Maggioni F, Castelli PM, et al. Gadolinium chelates with weak binding to serum proteins: a new class of high-efficiency, general purpose contrast agents for magnetic resonance imaging. *Invest Radiol* 1997;32(12):780–796.
23. Giesel FL, von Tengg-Kobligh H, Wilkinson ID, et al. Influence of human serum albumin on longitudinal and transverse relaxation rates (r_1 and r_2) of magnetic resonance contrast agents. *Invest Radiol* 2006;41(3):222–228.
24. Yrjänä SK, Vaara T, Karttunen A, Koivukangas J. Pulse repetition time and contrast enhancement: simulation study of Gd-BOPTA and conventional contrast agent at different field strengths. *Invest Radiol* 2008;43(4):267–275.
25. Bleicher AG, Kanal E. A serial dilution study of gadolinium-based MR imaging contrast agents. *AJNR Am J Neuroradiol* 2008;29(4):668–673.
26. Prokop M, Schneider G, Vanzulli A, et al. Contrast-enhanced MR angiography of the renal arteries: blinded multicenter crossover comparison of gadobenate dimeglumine and gadopentetate dimeglumine. *Radiology* 2005;234(2):399–408.
27. Pediconi F, Fraioli F, Catalano C, et al. Gadobenate dimeglumine (Gd-DTPA) vs gadopentetate dimeglumine (Gd-BOPTA) for contrast-enhanced magnetic resonance angiography (MRA): improvement in intravascular signal intensity and contrast to noise ratio. *Radiol Med (Torino)* 2003;106(1–2):87–93.
28. Knopp MV, Giesel FL, von Tengg-Kobligh H, et al. Contrast-enhanced MR angiography of the run-off vasculature: intraindividual comparison of gadobenate dimeglumine with gadopentetate dimeglumine. *J Magn Reson Imaging* 2003;17(6):694–702.
29. Wyttenbach R, Gianella S, Alerci M, Bragheti A, Cozzi L, Gallino A. Prospective blinded evaluation of Gd-DOTA- versus Gd-BOPTA-enhanced peripheral MR angiography, as compared with digital subtraction angiography. *Radiology* 2003;227(1):261–269.
30. Fontaine R, Kim M, Kiény R. Surgical treatment of peripheral circulation disorders [in German]. *Helv Chir Acta* 1954;21(5–6):499–533.
31. Visser K, Humink MG. Peripheral arterial disease: gadolinium-enhanced MR angiography versus color-guided duplex US—a meta-analysis. *Radiology* 2000;216(1):67–77.
32. Nelemans PJ, Leiner T, de Vet HC, van Engelshoven JM. Peripheral arterial disease: meta-analysis of the diagnostic performance of MR angiography. *Radiology* 2000;217(1):105–114.
33. Koelemay MJ, Lijmer JG, Stoker J, Legemate DA, Bossuyt PM. Magnetic resonance angiography for the evaluation of lower extremity arterial disease: a meta-analysis. *JAMA* 2001;285(10):1338–1345.
34. Thurnher S, Miller S, Schneider G, et al. Diagnostic performance of gadobenate dimeglumine enhanced MR angiography of the iliofemoral and calf arteries: a large-scale multicenter trial. *AJR Am J Roentgenol* 2007;189(5):1223–1237.
35. Fleiss JL. *Statistical methods for rates and proportions*. 2nd ed. New York, NY: Wiley, 1981.
36. Willmann JK, Wildermuth S, Pfammatter T, et al. Aortoiliac and renal arteries: prospective intraindividual comparison of contrast-enhanced three-dimensional MR angiography and multi-detector row CT angiography. *Radiology* 2003;226(3):798–811.
37. Bezooijen R, van den Bosch HC, Tielbeek AV, et al. Peripheral arterial disease: sensitivity-encoded multiposition MR angiography compared with intraarterial angiography and conventional multiposition MR angiography. *Radiology* 2004;231(1):263–271.
38. Bueltmann E, Erb G, Kirchin MA, Klose U, Naegele T. Intra-individual crossover comparison of gadobenate dimeglumine and gadopentetate dimeglumine for contrast-enhanced MR angiography of the supraaortic vessels at 3 Tesla. *Invest Radiol* 2008;43(10):695–702.
39. Knopp MV, Schoenberg SO, Rehm C, et al. Assessment of gadobenate dimeglumine for magnetic resonance angiography: phase I studies. *Invest Radiol* 2002;37(12):706–715.
40. Maravilla KR, Maldjian JA, Schmalfuss IM, et al. Contrast enhancement of central nervous system lesions: multicenter intraindividual crossover comparative study of two MR contrast agents. *Radiology* 2006;240(2):389–400.
41. Rowley HA, Scialfa G, Gao PY, et al. Contrast-enhanced MR imaging of brain lesions: a large-scale intraindividual crossover comparison of gadobenate dimeglumine versus gadodiamide. *AJNR Am J Neuroradiol* 2008;29(9):1684–1691.
42. Rumboldt Z, Rowley HA, Steinberg F, et al. Multicenter, double-blind, randomized, intraindividual crossover comparison of gadobenate dimeglumine and gadopentetate dimeglumine in MRI of brain tumors at 3 tesla. *J Magn Reson Imaging* 2009;29(4):760–767.
43. Pediconi F, Catalano C, Occhiato R, et al. Breast lesion detection and characterization at contrast-enhanced MR mammography: gadobenate dimeglumine versus gadopentetate dimeglumine. *Radiology* 2005;237(1):45–56.
44. Pediconi F, Catalano C, Padula S, et al. Contrast-enhanced MR mammography: improved lesion detection and differentiation with gadobenate dimeglumine. *AJR Am J Roentgenol* 2008;191(5):1339–1346.
45. Balci NC, Inan N, Anik Y, Erturk MS, Ural D, Demirci A. Low-dose gadobenate dimeglumine versus standard-dose gadopentetate dimeglumine for delayed contrast-enhanced cardiac magnetic resonance imaging. *Acad Radiol* 2006;13(7):833–839.
46. Schneider G, Maas R, Schultze Kool L, et al. Low-dose gadobenate dimeglumine versus standard dose gadopentetate dimeglumine for contrast-enhanced magnetic resonance imaging of the liver: an intra-individual crossover comparison. *Invest Radiol* 2003;38(2):85–94.
47. Kroencke TJ, Wasser MN, Pattynama PM, et al. Gadobenate dimeglumine-enhanced MR angiography of the abdominal aorta and renal arteries. *AJR Am J Roentgenol* 2002;179(6):1573–1582.

48. Wikström J, Wasser MN, Pattinama PM, et al. Gadobenate dimeglumine-enhanced magnetic resonance angiography of the pelvic arteries. *Invest Radiol* 2003;38(8):504–515.
49. Rapp JH, Wolff SD, Quinn SF, et al. Aortoiliac occlusive disease in patients with known or suspected peripheral vascular disease: safety and efficacy of gadofosveset-enhanced MR angiography—multicenter comparative phase III study. *Radiology* 2005;236(1):71–78.
50. Goyen M, Edelman M, Perreault P, et al. MR angiography of aortoiliac occlusive disease: a phase III study of the safety and effectiveness of the blood-pool contrast agent MS-325. *Radiology* 2005;236(3):825–833.
51. Dietrich O, Raya JG, Reeder SB, Ingrisch M, Reiser MF, Schoenberg SO. Influence of multichannel combination, parallel imaging and other reconstruction techniques on MRI noise characteristics. *Magn Reson Imaging* 2008;26(6):754–762.
52. Reeder SB, Wintersperger BJ, Dietrich O, et al. Practical approaches to the evaluation of signal-to-noise ratio performance with parallel imaging: application with cardiac imaging and a 32-channel cardiac coil. *Magn Reson Med* 2005;54(3):748–754.
53. Berg F, Bangard C, Bovenschulte H, et al. Hybrid contrast-enhanced MR angiography of pelvic and lower extremity vasculature at 3.0 T: initial experience. *Eur J Radiol* 2009;70(1):170–176.
54. Leiner T, Kessels AG, Nelemans PJ, et al. Peripheral arterial disease: comparison of color duplex US and contrast-enhanced MR angiography for diagnosis. *Radiology* 2005;235(2):699–708.