



ELSEVIER

Contents lists available at ScienceDirect

## International Journal of Infectious Diseases

journal homepage: [www.elsevier.com/locate/ijid](http://www.elsevier.com/locate/ijid)INTERNATIONAL  
SOCIETY  
FOR INFECTIOUS  
DISEASES

## Clinical characteristics in a sentinel case as well as in a cluster of tularemia patients associated with grape harvest

Nils Wetzstein<sup>a,\*</sup>, Iris Kärcher<sup>b</sup>, Claus P. Küpper-Tetzl<sup>a</sup>, Gerrit Kann<sup>a</sup>, Michael Hogardt<sup>a</sup>, Katalin Jozsa<sup>a</sup>, Daniela Jacob<sup>c</sup>, Roland Grunow<sup>c</sup>, Gudrun Just-Nübling<sup>a</sup>, Timo Wolf<sup>a</sup><sup>a</sup> University Hospital Frankfurt, Frankfurt, Germany<sup>b</sup> ENT-practice Dr. med. Iris Kärcher, Bingen, Germany<sup>c</sup> Robert Koch Institute, Berlin, Germany

## ARTICLE INFO

## Article history:

Received 1 February 2019

Received in revised form 26 April 2019

Accepted 29 April 2019

**Corresponding Editor:** Eskild Petersen, Aarhus, Denmark

## Keywords:

Tularemia

Zoonosis

*Francisella tularensis**Francisella tularensis* subspecies *holarctica*

## ABSTRACT

**Background:** Tularemia is caused by *Francisella tularensis* and can occasionally establish foodborne transmission.**Methods:** Patients were identified by active case detection through contact with the treating physicians and consent for publication was obtained. Clinical data were accumulated through a review of the patient charts. Serology, culture, and PCR methods were performed for confirmation of the diagnosis.**Case cluster:** A 46-year-old patient was hospitalised in the University Hospital Frankfurt (a tertiary care hospital) for pharyngitis and cervical lymphadenitis with abscess. A diagnosis of tularemia was made serologically, but treatment with ciprofloxacin initially failed. *F. tularensis* was detected in pus from the lymph node using a specific real-time PCR. The use of RD1 PCR led to the identification of the subspecies *holarctica*. Antibiotic therapy with high-dose ciprofloxacin and gentamicin was administered and was subsequently changed to ciprofloxacin and rifampicin. During a must-tasting, five other individuals became infected with tularemia by ingestion of contaminated must. All patients required treatment durations of more than 14 days.**Conclusions:** Mechanically harvested agricultural products, such as wine must, can be a source of infection, probably due to contamination with animal carcasses. The clinical course of tularemia can be complicated and prolonged and requires differentiated antibiotic treatment.© 2019 The Author(s). Published by Elsevier Ltd on behalf of International Society for Infectious Diseases. This is an open access article under the CC BY-NC-ND license (<http://creativecommons.org/licenses/by-nc-nd/4.0/>).

## Introduction

Tularemia is a rare infectious disease caused by *Francisella tularensis*. There are two major subspecies causing the disease: *F. tularensis* subspecies *tularensis*, mainly described in Northern America and leading to a more severe form of the disease, and *F. tularensis* subspecies *holarctica*, the most important subtype found across the whole Northern Hemisphere, usually causing milder forms of the disease (Gunnell et al., 2016).

In 2016, 41 cases were notified in Germany (Robert Koch Institute, 2016a). In Europe, approximately 500 to 1000 cases per year are reported, despite the fact that tularemia is not a notifiable disease in all European countries (Robert Koch Institute, 2016b). The disease has shown a re-emergence in Europe since the turn of

the century. Tularemia outbreaks have been recorded in Sweden and Spain (Eliasson et al., 2002; Pérez-Castrillón et al., 2001). In 2005, an airborne epidemic among hare hunters involving 39 patients was reported from Hesse, Germany (Hauri et al., 2010). Nonetheless, tularemia can still be regarded as a rare infectious disease.

Six major forms can be classified on the basis of clinical manifestations: the glandular form, the ulceroglandular form, the oropharyngeal form, the typhoidal form, pulmonary tularemia, and an oculoglandular form (Weber et al., 2012). A Turkish study reported a therapeutic failure rate of 38% after 1 year despite early antibiotic treatment (Meric et al., 2008). It is known that in the case of late diagnosis and inadequate treatment, tularemia caused by *F. tularensis* ssp *holarctica* can have a protracted and severe course (Lübbert et al., 2009).

*F. tularensis* is a fastidious bacterium that can infect over 250 different animals. It is mainly found in rodents (e.g., voles) and lagomorphs (e.g., hares, rabbits) (Santic et al., 2010). German studies have found the bacterium to be present in 4.92% of trapped

\* Corresponding author at: University Hospital Frankfurt, Internal Medicine II, Department of Infectious Diseases, Theodor Stern Kai 7, 60590 Frankfurt, Germany. E-mail address: [nils.wetzstein@kgu.de](mailto:nils.wetzstein@kgu.de) (N. Wetzstein).

mammals in areas at risk, but in water samples and in wild animals in general (Kaysser et al., 2008; Kuehn et al., 2013). Transmission by direct contact with animals is possible, for example while skinning them or processing their meat. Thus, hunters and forest workers are at increased risk of infection (Hauri et al., 2010). Cats may also be a reservoir, and transmission via cat bites has been described (Capellan and Fong, 1993).

In the past, direct contamination of drinking water and food was responsible for infections (Willke et al., 2009; Grunow et al., 2012). In particular, *F. tularensis* ssp *holarctica* has been shown to be associated with waterborne infections and epidemics (Santic et al., 2010). The bacterium is able to survive in brackish water, and deficient tap water chlorination devices have caused epidemics of oropharyngeal tularemia in Turkey (Aktas et al., 2015; Berrada and Telford, 2011). *Francisella* spp are able to persist within amoebae (*Acanthamoeba castellanii*) in the same way as other intracellular bacterial species (e.g. *Legionella*, *Chlamydia*, *Mycobacterium*), which may explain the persistence of the bacterium in the environment (El-Etr et al., 2009; Abd et al., 2003). *F. tularensis* is a very contagious bacterium, as only 1–10 bacteria are sufficient to cause infection (Ellis et al., 2002).

## Methods

### Patient data acquisition

Patients were identified by active case detection through contact with the treating physicians and consent for publication was obtained. Clinical data were accumulated through a review of the patient charts.

### Serology

An ELISA was used for screening and Western blot (WB) for confirmation of antibodies against *F. tularensis* lipopolysaccharide (LPS). Both in-house assays are accredited by DIN EN ISO/IEC 17025:2005 and DIN EN ISO 15189:2014 and have been described elsewhere (Jenzora et al., 2008). Briefly, a 96-well microtitre plate (Polysorb, Nunc, Germany) was coated with purified LPS from the live vaccine strain as antigen (Micromun, Germany). Bound human antibodies to *F. tularensis* LPS were detected by polyvalent or monovalent goat anti-human IgA, IgM, and IgG horseradish peroxidase-conjugated secondary antibody (Dianova, Germany) and subsequent substrate reaction. Serum dilutions starting with 1:500 that revealed an optical density above the validated cut-off were counted as positive. For the WB, the soluble fraction of formalin-inactivated live vaccine strain was separated using sodium dodecyl sulphate polyacrylamide gel electrophoresis (SDS-PAGE) and then transferred to polyvinylidene difluoride (PVDF) membranes (ImmobilonP, Millipore, USA). Using polyvalent horseradish peroxidase-conjugated secondary antibodies, the typical LPS ladder revealed the presence of specific anti-*F. tularensis* antibodies. The final results were given after confirmation of the ELISA results by WB: 'positive' denoted strong bands, 'negative' almost no bands, and 'borderline' weak but clearly visible bands.

### Quantitative real-time PCR (qPCR) and subtyping

DNA was extracted from 100 µl pus and blood using the DNeasy Blood and Tissue Kit according to the manufacturer's instructions (Qiagen, Germany). A multiplex real-time PCR (5' nuclease assay) targeting *fopA* and *tul4* was used to detect *F. tularensis* DNA in the investigated samples; this assay is accredited by DIN EN ISO/IEC 17025:2005 and DIN EN ISO 15189:2014 and has been described elsewhere with some modifications (Schulze et al., 2016). Primer

and probe sequences for the detection of *fopA* were Ft-fopA-F: TTGGGCA AATCTAGCAGGTC; Ft-fopA-R: ATCTGTAGTCAACACTTG CTTGAACA; and Ft-fopA-TM: FAM-AAGACCACCACCAACATCC-CAAGCA-BHQ-1. Those for the detection of *tul4* were Ft-tul4-F: AGATTACAATGGCAGGCTCC; Ft-tul4-R: AGCTGTCCACTT ACCGC TACA; and Ft-tul4-TM: Cy5-TTCTAAGTGCCATGATACAAGCTTCC-CAA-BHQ-2. The real-time PCR assays were run in a total volume of 25 µl including 5 µl sample volume or DNA in duplicate. The reaction mix components were TaqMan Environmental MasterMix 2.0 (6.25 µl), 10 pmol/µl primers (0.75 µl each) and probes (0.25 µl each). Amplification was performed in an ABI 7500 instrument (Thermo Fisher Scientific, Germany), each run with an initial denaturation step at 95 °C for 10 min, followed by 40 cycles of a denaturation step at 95 °C for 15 s, and a combined primer annealing and elongation step at 60 °C for 60 s. An internal extraction and amplification control (KoMa) was added (Kirchner et al., 2010). The detection limit of the qPCR was 10 genome equivalents (GE)/5 µl DNA in the reaction volume.

*F. tularensis* subspecies differentiation was performed by targeting region of difference 1 (RD1) according to protocols described by Broekhuijsen et al. (2003). The PCR was conducted using the Dream Taq Green DNA Polymerase (Thermo Fisher Scientific, Germany) with 15–100 ng template DNA.

### Approaches for pathogen isolation by culture

For isolation of *F. tularensis*, 100 µl of pus was cultured in 10 ml medium T (Becker et al., 2016) and directly on CHAB-PASCV (cysteine heart agar with blood (Difco, Bestbion, Germany) plus  $8 \times 10^4$  U/l polymyxin B, 2.5 mg/l amphotericin B, 20 mg/l sulfamethoxazole, 100 mg/l cycloheximide, 4 mg/l vancomycin) and on Neisseria Selective Medium Plus (Oxoid, Germany) agar plates for 3–14 days at 37 °C with 5% CO<sub>2</sub> for up to 14 days. Conventional culture media were inoculated as well.

The same procedure was performed for blood samples. The first blood culture at University Hospital Frankfurt was drawn on day 60, when the patient had already received amoxicillin, clindamycin, sultamicillin, co-amoxiclav, doxycycline, and ciprofloxacin consecutively. Samples were transported under biosafety level 3 (BSL3) conditions at room temperature with a maximum delay of 3 h between withdrawal and arrival in the laboratory. Bacterial culture was performed in a BSL3 laboratory.

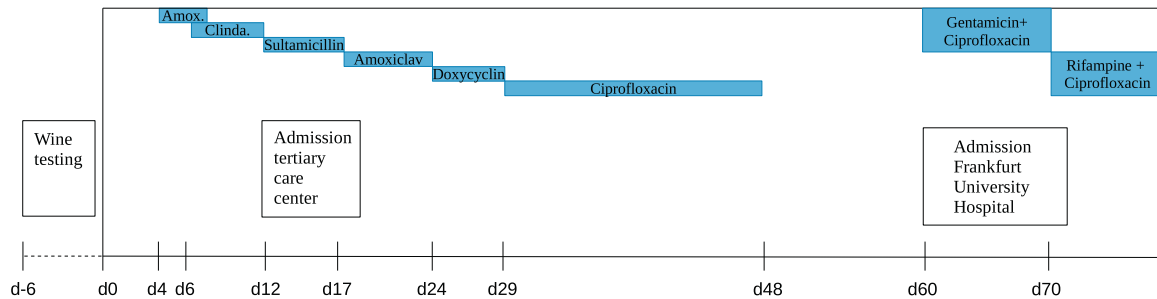
## Sentinel case and cluster description

### Sentinel case

A 46-year-old man attended a wine-tasting in the region of Rhineland-Palatinate in the west of Germany. He subsequently suffered a severe fever and general malaise for 5 days and consulted a doctor 2 days later (day 7). The doctor noted a swollen lymph node on the left side of the man's neck and suspected a viral infection. Another 2 days later (day 9), problems swallowing and severe tonsillo-pharyngitis developed. Treatment was initiated with amoxicillin 1000 mg TID for 2 days, which was subsequently changed to clindamycin (for a timeline see Figure 1).

Serological tests for Epstein-Barr virus showed no evidence of acute disease. On day 12, the patient was hospitalized for the first time in a tertiary care hospital and was treated intravenously with sultamicillin and cortisone for 5 days. On discharge he received amoxicillin-clavulanic acid for another week. At that time, the tonsillitis had improved and there was no fever, but his lymph nodes were still enlarged.

Subsequently, the submandibular lymph nodes increased in size and became heavily inflamed. The patient consulted an ENT clinician and received doxycycline orally (day 24). Serum



**Figure 1.** Timeline of the clinical course in the sentinel case. The x-axis shows the days after the wine-tasting event. The antibiotic treatment administered is shown in blue.

samples were sent to the consultant laboratory for tularemia at the Robert Koch Institute (RKI, Berlin, Germany). Here, antibodies against *F. tularensis* LPS were identified. Ciprofloxacin 500 mg twice daily was given for 14 days, which initially led to clinical improvement. However, the lymph node swelling and inflammation increased again and the patient was therefore admitted to the University Hospital Frankfurt for inpatient treatment on day 60.

On admission, the patient showed slightly elevated markers of inflammation, including C-reactive protein (CRP) of 1.71 mg/dl (normal range <0.5 mg/dl) and a leukocyte count of  $10.6 \times 10^9/l$  with 1% immature neutrophils, 60% segmented leukocytes, and 10% monocytes. Clinically a large mass of the left neck could be observed (Figure 2a). A computed tomography (CT) scan of the neck was performed. Suppurative lymph nodes infiltrating the platysma and different levels of the neck could be seen (Figure 2b). A puncture was performed on the same day and the purulent aspirate was sent to the local microbiology department and the consultant laboratory (RKI, Berlin). A chest X-ray showed no pulmonary involvement. Oral ciprofloxacin was given at 750 mg twice daily, combined with gentamicin at 3 mg/kg body weight QD intravenously from day 60.

On day 66, blood samples were found to be positive for *F. tularensis* DNA, and Gram stain of the puncture pus showed small, gram-negative coccoid rods. On day 67, *F. tularensis* was confirmed by 16S rDNA-PCR of pus from the lymph node and subsequent amplicon sequencing. *Treponema pallidum* serology and *Mycobacterium tuberculosis* complex PCR were performed to investigate differential diagnoses; both remained negative. A confirmatory real-time PCR for *tul4* and *fopA* specific for *F. tularensis* was performed on pus at the consultant laboratory. The RD1 PCR (Broekhuijsen et al., 2003) showed positive amplification of *F.*

*tularensis* ssp *holarctica*. Culture of pus over 14 days in rich media specific for *F. tularensis* was unsuccessful.

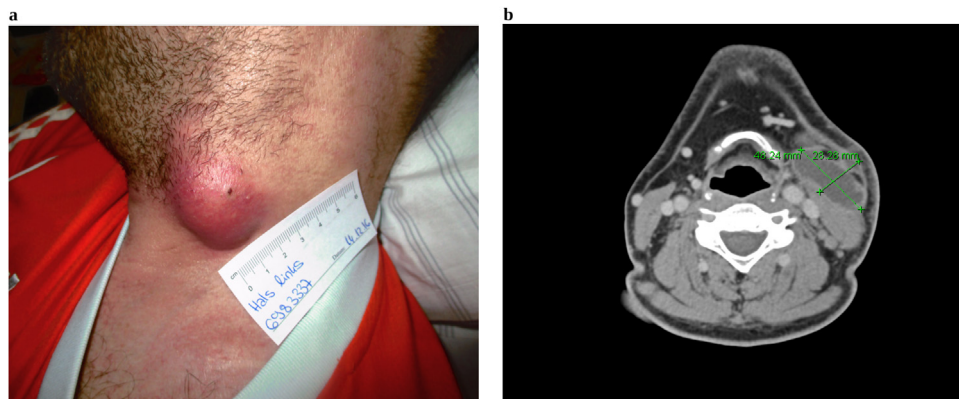
The abscess was punctured several times under sterile conditions. A slight clinical improvement could be observed with the use of these procedures and the antibiotic treatment. Unfortunately, an isolate of *F. tularensis* could not be obtained at any time; furthermore, culture on conventional media was unsuccessful.

A CT scan of the neck on day 71 showed that the abscess formation was only decreasing slightly. Therefore, it was decided to perform surgical drainage. The patient was discharged with oral antibiotic treatment comprising ciprofloxacin 500 mg twice daily and rifampicin 600 mg QD on the same day. The drain was kept in place for 9 days and removed on day 80 after the onset of symptoms. In the meantime, CRP normalized and the clinical inflammation and swelling decreased as well. The patient recovered and remained well; he was free of symptoms 8 months after the onset of the disease.

#### Clinical data in all patients from the cluster

Five other patients were infected during the same wine-tasting event: three males and two females (Table 1). The patients ranged in age from 3 to 41 years (as grape must is non-alcoholic, three children were attending the tasting). The onset of symptoms occurred between 4 and 24 days after this wine-tasting event. Clinically, cervical lymphadenopathy and pharyngitis were observed in nearly all patients, accompanied by fever and general malaise.

Tularemia was proven serologically in all patients. Effective treatment was conducted with doxycycline and ciprofloxacin in adult patients, and with ciprofloxacin monotherapy in the three



**Figure 2.** (a) Image showing the clinical manifestations in the sentinel case. A local lymph node swelling with massive inflammation evolved in this patient despite multiple antibiotic treatments. The clinical picture shows day 60 after the onset of symptoms, at admission to the tertiary care centre. (b) CT scan of the neck of the sentinel patient. The lymphadenopathy described above can be seen in the left side of the neck, with a size of 48.24 mm × 28.28 mm.

**Table 1**

Data of all patients in this cluster of tularemia patients.

Patient	Age (years)	Sex	Start of symptoms (days after wine tasting)	Clinical manifestations	Diagnosis of tularemia	Antibiotic treatment	Start of effective treatment (days after onset of symptoms)	Resolution of last symptoms (days after onset of symptoms)	Cumulative duration of treatment (days)
1 (Sentinel patient)	46	M	6	Lymphadenitis colli Fever Malaise	Serology PCR from blood and pus	Amoxicillin; clindamycin; co-amoxiclav; sultamicillin; doxycycline <sup>a</sup> ; ciprofloxacin <sup>a</sup> ; gentamicin <sup>a</sup> + ciprofloxacin <sup>a</sup> ; rifampicin <sup>a</sup> + ciprofloxacin <sup>a</sup>	24	More than 76	76
2	41	M	8	Lymphadenitis colli Pharyngitis Fever Diarrhoea	Serology	Erythromycin; doxycycline <sup>a</sup> ; ciprofloxacin <sup>a</sup>	29	42	14
3	39	F	24	Lymphadenitis colli Pharyngitis Fever	Serology	Clindamycin; cefuroxime; doxycycline <sup>a</sup> ; ciprofloxacin <sup>a</sup>	13	Approx. 45	14
4	3	F	5	Lymphadenitis colli Pharyngitis Fever Shivering	Serology	Cefaclor; ciprofloxacin <sup>a</sup>	32	Approx. 23	14
5	10	F	4	Lymphadenitis colli Pharyngitis Fever Malaise	Serology	Cefuroxime; ciprofloxacin <sup>a</sup>	33	Approx. 24	14
6	11	F	4	Fever Headache Malaise Pharyngitis Peri-umbilical swelling	Serology	Cefaclor; cefuroxime; ciprofloxacin <sup>a</sup>	33	Approx. 24	14

M, male; F, female.

<sup>a</sup> Effective antibiotic treatments.

children. The time to resolution of symptoms was between 23 and 45 days; in none of the five patients did the time to resolution exceed that of the sentinel patient, whose course of disease is described above.

## Discussion

Tularemia is a very rare zoonotic disease in Central Europe that has to be suspected if epidemiological risk factors are present. In the case presented here, a prolonged history of pharyngitis and lymphadenopathy complicated by septicaemia led to the delayed or late clinical diagnosis of tularemia by an ENT doctor. The tularemia was confirmed serologically and later by microscopy and 16SrDNA PCR. Subsequent antibiotic therapy with gentamicin and ciprofloxacin, later changed to rifampicin and ciprofloxacin, was found to be efficient and led to a decrease in symptoms.

The sentinel patient was diagnosed with an oropharyngeal form of tularemia suggesting oral intake of the infectious agent (Aktas et al., 2015; Willke et al., 2009; Djordjevic-Spasic et al., 2011). The sentinel patient presented with cervical lymphadenopathy and suppurative lymph nodes and this case took a prolonged course despite the initial treatment, which could be regarded as adequate. However, *Francisella* DNA was detectable in the patient's lymph node material after treatment with ciprofloxacin, which is noteworthy.

In the case presented, the probable source of transmission was must consumption in a wine area in Rhineland-Palatinate, Germany. Here the grapes are pressed directly and the juice remains unfiltered until it is subjected to further fermentation for the production of wine and grape juice. The suspected grape must was shown to carry tularemia DNA and a mechanical harvester was identified as the source, as described previously (Burckhardt et al., 2018). The consumption of fresh must with the highest genomic equivalents of *F. tularensis ssp holarctica* was significantly associated with development of the disease. In the past, direct contamination of

drinking water and food was responsible for infections (Aktas et al., 2015; Grunow et al., 2012). In particular, *F. tularensis ssp holarctica* has been shown to be associated with waterborne infections and epidemics (Santic et al., 2010). Thus, the use of automatic harvest machines could have caused contamination of the grape must with an infected rodent or lagomorph. This is underlined by the fact that *F. tularensis* is a highly contagious bacterium, as only 1–10 bacteria are sufficient to cause infection (Ellis et al., 2002).

In the cluster described herein, the treatment of tularemia was complicated by a prolonged course of the disease and treatment needed to be very differentiated. For all patients in this cluster, the time to resolution of symptoms was more than 3 weeks, indicating that a treatment duration of 14 days (as described, for example, in the German recommendations of the Robert Koch Institute, 2016b) might be too short. Other guidelines do recommend a longer treatment duration of up to 21 days (Dennis et al., 2001). The duration of anti-infective treatment could be guided by carefully evaluating the treatment response in these cases.

In conclusion, mechanically harvested products such as wine and grape juice can be a source of *F. tularensis* infection and may cause small epidemics. This has implications for public health, as outbreaks have to be taken into account in hitherto unknown epidemiological settings. As a consequence, the diagnosis of tularemia should be considered in the case of a corresponding clinical pattern and a history of exposure to the agricultural processes and products mentioned above. Antibiotic treatment in tularemia patients can be difficult and prolonged. Current recommended treatment durations might be too short in some cases.

## Funding sources

This research did not receive any specific grant from funding agencies in the public, commercial, or not-for-profit sectors.

## Conflict of interest

NW, IK, MH, KJ, GK, GJN, DJ, RG declare that they have no competing interests. TW reports having received personal fees from Gilead, Janssen, Astellas, and Merck Sharp and Dohme, all outside the submitted work. CPKT reports having received personal fees from Gilead, Janssen, and Abbvie, all outside the submitted work.

## Acknowledgements

We thank all patients, treating physicians, and nursing staff.

## Appendix A. Supplementary data

Supplementary material related to this article can be found, in the online version, at doi:<https://doi.org/10.1016/j.ijid.2019.04.031>.

## References

- Abd H, Johansson T, Golovliov I, Sandström G, Forsman M. Survival and growth of *Francisella tularensis* in *Acanthamoeba castellanii*. *Appl Environ Microbiol* 2003;69(January (1)):600–6.
- Aktas D, Celebi B, Isik ME, Tutus C, Ozturk H, Temel, et al. Oropharyngeal tularemia outbreak associated with drinking contaminated tap water, Turkey, July–September 2013. *Emerg Infect Dis* 2015;21(December (12)):2194–6.
- Becker S, Lochau P, Jacob D, Heuner K, Grunow R. Successful re-evaluation of broth medium T for growth of *Francisella tularensis* ssp. and other highly pathogenic bacteria. *J Microbiol Methods* 2016;121(February):5–7.
- Berrada ZL, Telford III SR. Survival of *Francisella tularensis* Type A in brackish-water. *Arch Microbiol* 2011;193(March (3)):223–6.
- Broekhuijsen M, Larsson P, Johansson A, Byström M, Eriksson U, Larsson E, et al. Genome-wide DNA microarray analysis of *Francisella tularensis* strains demonstrates extensive genetic conservation within the species but identifies regions that are unique to the highly virulent *F. tularensis* subsp. *tularensis*. *J Clin Microbiol* 2003;41(July (7)):2924–31.
- Burckhardt F, Hoffmann D, Jahn K, Heuner K, Jacob D, Vogt M, et al. Oropharyngeal tularemia from freshly pressed grape must. *N Engl J Med* 2018;379:197–9.
- Capellan J, Fong IW. Tularemia from a cat bite: case report and review of feline-associated tularemia. *Clin Infect Dis* 1993;16(April (4)):472–5.
- Dennis DT, Inglesby TV, Henderson DA, Bartlett JG, Ascher MS, Eitzen E, et al. Tularemia as a biological weapon: medical and public health management. *JAMA* 2001;285(21):2763–73.
- Djordjevic-Spasic M, Potkonjak A, Kostic V, Lako B, Spasic Z. Oropharyngeal tularemia in father and son after consumption of under-cooked rabbit meat. *Scand J Infect Dis* 2011;43(December (11–12)):977–81.
- El-Etr SH, Margolis JJ, Monack D, Robison RA, Cohen M, Moore E, et al. *Francisella tularensis* type A strains cause the rapid encystment of *Acanthamoeba castellanii* and survive in amoebal cysts for three weeks postinfection. *Appl Environ Microbiol* 2009;75(December (23)):7488–500.
- Eliasson H, Lindbäck J, Nuorti JP, Arneborn M, Giesecke J, Tegnell A. The 2000 tularemia outbreak: a case-control study of risk factors in disease-endemic and emergent areas, Sweden. *Emerg Infect Dis* 2002;8(September (9)):956–60.
- Ellis J, Oyston PCF, Green M, Titball RW. Tularemia. *Clin Microbiol Rev* 2002;15(October (4)):631–46.
- Gunnell MK, Adams BJ, Robison RA. The genetic diversity and evolution of *Francisella tularensis* with comments on detection by PCR. *Curr Issues Mol Biol* 2016;18:79–91.
- Grunow R, Kalaveshi A, Kühn A, Mulliqi-Osmani G, Ramadan N. Surveillance of tularemia in Kosovo, 2001 to 2010. *Euro Surveill* 2012;17(July (28)).
- Hauri AM, Hofstetter I, Seibold E, Kaysser P, Eckert J, Neubauer H, et al. Investigating an airborne tularemia outbreak, Germany. *Emerg Infect Dis* 2010;16(February (2)):238–43.
- Jenzora A, Jansen A, Ranisch H, Lierz M, Wichmann O, Grunow R. Seroprevalence study of *Francisella tularensis* among hunters in Germany. *FEMS Immunol Med Microbiol* 2008;53(July (2)):183–9.
- Kaysser P, Seibold E, Mätz-Rensing K, Pfeiffer M, Essbauer S, Spletstoeser WD, et al. Re-emergence of tularemia in Germany: presence of *Francisella tularensis* in different rodent species in endemic areas. *BMC Infect Dis* 2008;8(November):157.
- Kirchner S, Krämer KM, Schulze M, Pauly D, Jacob D, Gessler F, et al. Pentaplexed quantitative real-time PCR assay for the simultaneous detection and quantification of botulinum neurotoxin-producing clostridia in food and clinical samples. *Appl Environ Microbiol* 2010;76(July (13)):4387–95.
- Kuehn A, Schulze C, Kutzer P, Probst C, Hlinak A, Ochs A, et al. Tularemia seroprevalence of captured and wild animals in Germany: the fox (*Vulpes vulpes*) as a biological indicator. *Epidemiol Infect* 2013;141(April (4)):833–40.
- Lübbert C, Taeye C, Seufferlein T, Grunow R. Prolonged course of tick-borne ulceroglandular tularemia in a 20-year-old patient in Germany—case report and review of the literature [in German]. *Dtsch Med Wochenschr* 2009;134(July (27)):1405–10.
- Meric M, Willke A, Finke E-J, Grunow R, Sayan M, Erdogan S, et al. Evaluation of clinical, laboratory, and therapeutic features of 145 tularemia cases: the role of quinolones in oropharyngeal tularemia. *APMIS Acta Pathol Microbiol Immunol Scand* 2008;116(January (1)):66–73.
- Pérez-Castrillón JL, Bachiller-Luque P, Martín-Luquero M, Mena-Martin FJ, Herreros V. Tularemia epidemic in northwestern Spain: clinical description and therapeutic response. *Clin Infect Dis* 2001;33(August (4)):573–6.
- Robert Koch Institute. Infektionsepidemiologisches Jahrbuch meldepflichtiger Krankheiten für 2016. 2016. . . [Accessed on 3 December 2017]. [in German] [http://www.rki.de/DE/Content/Infekt/Jahrbuch/Jahrbuch\\_2016.pdf?\\_\\_blob=publicationFile](http://www.rki.de/DE/Content/Infekt/Jahrbuch/Jahrbuch_2016.pdf?__blob=publicationFile).
- Robert Koch Institute. RKI-Ratgeber für Ärzte. 2016. . . [Accessed on 3 December 2017]. [in German] [https://www.rki.de/Content/Infekt/EpidBull/Merkblaetter/Ratgeber\\_Tularaemie.html;jsessionid=C1311A8EF5A6-B4E26B55804969228912.2\\_cid363#doc2398238bodyText3](https://www.rki.de/Content/Infekt/EpidBull/Merkblaetter/Ratgeber_Tularaemie.html;jsessionid=C1311A8EF5A6-B4E26B55804969228912.2_cid363#doc2398238bodyText3).
- Santic M, Al-Khodori S, Abu Kwaik Y. Cell biology and molecular ecology of *Francisella tularensis*. *Cell Microbiol* 2010;12(February (2)):129–39.
- Schulze C, Heuner K, Myrtenäs K, Karlsson E, Jacob D, Kutzer P, et al. High and novel genetic diversity of *Francisella tularensis* in Germany and indication of environmental persistence. *Epidemiol Infect* 2016;144(October (14)):3025–36.
- Weber IB, Turabelidze G, Patrick S, Griffith KS, Kugeler KJ, Mead PS. Clinical recognition and management of tularemia in Missouri: a retrospective records review of 121 cases. *Clin Infect Dis* 2012;55(November (10)):1283–90.
- Willke A, Meric M, Grunow R, Sayan M, Finke E, Spletstoeser W, et al. An outbreak of oropharyngeal tularemia linked to natural spring water. *J Med Microbiol* 2009;58(January (Pt 1)):112–6.