

PDF hosted at the Radboud Repository of the Radboud University Nijmegen

The following full text is a publisher's version.

For additional information about this publication click this link.

<http://hdl.handle.net/2066/207089>

Please be advised that this information was generated on 2020-09-08 and may be subject to change.

Thalamus: a key player in alcohol use disorder and Korsakoff's syndrome

This scientific commentary refers to 'Dissociating thalamic alterations in alcohol use disorder defines specificity of Korsakoff's syndrome', by Segobin *et al.* (doi:10.1093/brain/awz056).

Although alcohol is consumed worldwide as part of recreational or ceremonial activities, alcohol misuse or dependency is also a significant global public health problem. At least 280 million people worldwide are thought to have alcohol use disorder (AUD) (WHO, 2018). Heavy or excessive drinking is defined by the Centers for Disease Control and Prevention as 15 or more drinks per week for males and eight or more drinks per week for females (CDC, 2016). The effects of AUD on cognition vary greatly, with some individuals retaining intact cognitive function while others show global cognitive impairment, including deficits in executive function (Sullivan *et al.*, 2010). Korsakoff's syndrome is a form of brain damage caused mainly by severe vitamin B1 deficiency due to chronic excessive alcohol consumption in combination with malnutrition (Kopelman *et al.*, 2009). The key neuropsychological feature of Korsakoff's syndrome is profound memory impairment resulting in anterograde and retrograde amnesia (Kopelman *et al.*, 2009). The pathophysiology of the cognitive sequelae in AUD and Korsakoff's syndrome is still not fully understood. Two brain networks are particularly affected, the Papez circuit and the frontocerebellar circuit (FCC) (Pitel *et al.*, 2015) (Fig. 1). The thalamus plays an important role in both of these networks. In this issue of *Brain*, Segobin and co-workers provide evidence of specific, differential thalamic alterations in patients with Korsakoff's syndrome versus those with AUD without severe

neurological impairments (Segobin *et al.*, 2019).

Previous neuroimaging studies have shown structural damage in AUD and Korsakoff's syndrome, including atrophy of the entire brain and in particular of regions within the FCC and the Papez circuit. However, the thalamus appears to be affected to a greater degree in patients with Korsakoff's syndrome than in those with AUD without severe neurological impairments ('uncomplicated alcoholics') (Pitel *et al.*, 2015). The thalamus consists of multiple subregions and contributes to a broad array of functions via reciprocal connections to and from areas including the cortex and the cerebellum (Haber, 2003). The anterior thalamic nuclei form part of the Papez circuit, while the mediodorsal nuclei belong to the FCC (Pitel *et al.*, 2015). The FCC is thought to be involved in executive and motor functions, while the Papez circuit has been implicated in episodic memory. Given that dysfunction of the FCC and the Papez circuit have different clinical consequences, this raises the question of whether specific structural abnormalities within the thalamic nuclei exist in uncomplicated AUD and Korsakoff's syndrome. Identifying the different nuclei of the thalamus using conventional MRI techniques, i.e. T₁- or T₂-weighted images, is challenging due to the small size of the nuclei and the low contrast signal in these images. An alternative technique for parcellation of the thalamus into its various subdivisions is probabilistic tractography based on diffusion-weighted imaging data. Diffusion-weighted imaging is a non-invasive technique that measures local water diffusion profiles, and provides valuable information on tissue integrity. Based on connectivity patterns, this technique reveals distinct thalamic subdivisions that closely resemble those shown in

histological data (Behrens *et al.*, 2003). In recent years, there have been several attempts to further refine the technique to advance the quantitative segmentation of the thalamus (Lambert *et al.*, 2017).

Segobin *et al.* recruited patients with Korsakoff's syndrome, uncomplicated alcoholics and healthy control subjects to investigate the specific mechanisms underlying the thalamic alterations in AUD. To this end, they conducted quantitative MRI using an innovative approach in which they performed probabilistic tractography on diffusion imaging data to segment the thalamus according to its connectivity to key brain regions within the FCC and Papez circuits (Behrens *et al.*, 2003) (Fig. 1). Key regions in the FCC included regions involved in frontal-executive, cerebellar-executive, frontal-motor and cerebellar-motor functioning, while the key region considered in the Papez circuit was the hippocampus. This technique enabled Segobin *et al.* to calculate the volumes and connectivity of thalamic subregions, which in turn allowed them to disentangle the different biological processes in their three groups of subjects.

The topology and connectivity of thalamic nuclei are complex (Haber, 2003). The connections of the nodes of the FCC and Papez circuit were not confined to one nucleus within the thalamus. For example, Segobin *et al.* were able to show that in the Papez circuit, the hippocampus was not only connected to the anterior nuclei via the fornix, but also to the ventral midline nuclei, and the pulvinar and latero-dorsal nuclei via non-fornical connections, as shown in previous human and animal studies. To verify their findings *a posteriori*, the authors used a histological atlas to show that anterior nuclei are mainly connected to the hippocampus,

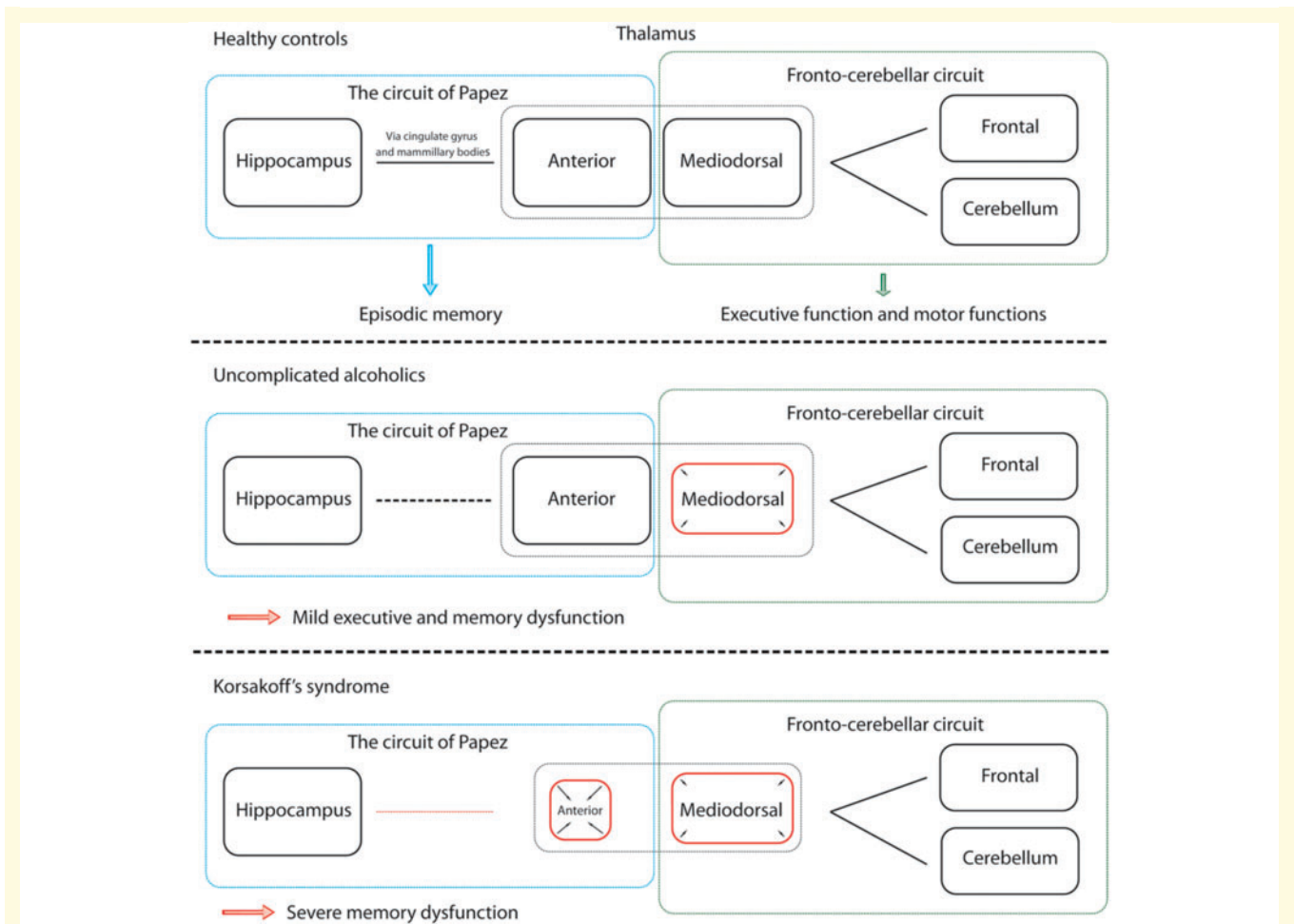


Figure 1 Schematic overview of two brain networks. Top: A schematic overview of the two brain networks implicated in uncomplicated alcohol use disorder and Korsakoff's syndrome, and their role in cognitive functioning. The thalamus plays an important role in both networks. Middle and bottom: Highlighting the findings of Segobin *et al.* in uncomplicated alcoholics (atrophy of the mediodorsal nuclei) and patients with Korsakoff's syndrome (atrophy of the mediodorsal nuclei and more specifically atrophy of the anterior nuclei with associated decreased connectivity between anterior nuclei and hippocampus) compared to healthy controls.

whereas mediodorsal nuclei are connected to frontal-executive regions.

Aside from revealing the complex topological structure of the thalamus with MRI, the findings of Segobin *et al.* suggest that the harmful effects of alcohol predominantly involve the mediodorsal and anterior nuclei. A graded effect of decreasing connectivity strength between the anterior nuclei and the hippocampus was observed from controls to uncomplicated alcoholics to patients with Korsakoff's syndrome. Atrophy of the mediodorsal nuclei was seen in both uncomplicated alcoholics and those with Korsakoff's syndrome, while atrophy of anterior nuclei was found only in the latter. One potential explanation for this observation is that disconnection

between the hippocampus and the anterior nuclei may result in atrophy of the anterior nuclei, eventually leading to the clinical symptoms that define Korsakoff's syndrome. However, because of the cross-sectional design of the study, this hypothesis cannot be tested directly. An alternative explanation may also be possible in that atrophy of the anterior nuclei could lead to decreased connectivity between these nuclei and the hippocampus. A potential limitation of the study is the presence of atrophy throughout the brain, which may affect the connectivity profiles derived from the probabilistic tractography data. However, the atrophy of the anterior nuclei seems to exceed what one would expect due to alcohol-associated global brain

atrophy. Future studies should be prospective and preferably use serial imaging such that the origin of the structural damage and the propagation of the damage can be investigated, independent of overall brain atrophy.

Limitations aside, this study adds an important piece to the puzzle of alcohol-related thalamic pathology. However, a number of issues remain to be resolved. These include identifying the most important pathophysiological mechanisms by which excessive alcohol use leads to specific thalamic damage, particularly in combination with thiamine deficiency, as well as the course of structural changes throughout different periods, including periods of drinking and abstinence. Longitudinal MRI studies and in-

depth phenotyping of patients with uncomplicated AUD and Korsakoff's syndrome are required to address these issues. Furthermore, it is important to better understand the pathophysiology of alcohol craving and addiction, in which the thalamus—especially the anterior nuclei—may also be involved (George *et al.*, 2001). For example, could addictive behaviour be reinforced by a self-propelling process in which the thalamic alterations *per se* are involved in the pathophysiology of addiction? In this light, can specific MRI findings be identified in patients with AUD that could be used to provide more personalized treatment or information on prognosis?

Taken together, the findings of this study point to a central role for structural abnormalities in both the mediodorsal and anterior thalamic nuclei observed in uncomplicated AUD and Korsakoff's syndrome. In the FCC, atrophy of the mediodorsal nuclei is the most prominent finding, while decreased connectivity between the anterior nuclei and hippocampus was observed in the Papez circuit. This disconnection may result in atrophy of the anterior nuclei, which seems to be specific to Korsakoff's syndrome, and thus could potentially be used as a neuroimaging marker for this disorder. Future—preferably longitudinal—studies will be necessary to better understand the pathophysiology and heterogeneity of AUD, and to assist the development of evidence-based treatments. Until

then, public health interventions must ensure that people are informed about the harmful effects of chronic excessive alcohol consumption—not only neuropsychological sequelae but also an increased risk of cancer and cardiovascular disease—to try to reduce the impact of alcohol (Day *et al.*, 2015).

Anil M. Tuladhar and
Frank-Erik de Leeuw
Department of Neurology, Donders
Institute for Brain, Cognition and
Behaviour, Radboud University Medical
Center, Nijmegen, The Netherlands

Correspondence to: Anil M. Tuladhar,
PhD
E-mail: anil.tuladhar@radboudumc.nl

doi:10.1093/brain/awz096

Funding

A.M.T. was supported by the Dutch Heart Foundation (grant 2016T044). F.E.d.L. was supported by a clinical established investigator grant of the Dutch Heart Foundation (grant 2014 T060), and by a VIDI innovational grant from The Netherlands Organisation for Health Research and Development, ZonMw (grant 016126351).

Competing interests

The authors report no competing interests.

References

- Behrens TE, Johansen-Berg H, Woolrich MW, Smith SM, Wheeler-Kingshott CA, Boulby PA, et al. Non-invasive mapping of connections between human thalamus and cortex using diffusion imaging. *Nat Neurosci* 2003; 6: 750–7.
- CDC. Alcohol and Public Health. Fact Sheets- Alcohol Use and Your Health; 2016.
- Day E, Copello A, Hull M. Assessment and management of alcohol use disorders. *BMJ* 2015; 350: h715.
- George MS, Anton RF, Bloomer C, Teneback C, Drobos DJ, Lorberbaum JP, et al. Activation of prefrontal cortex and anterior thalamus in alcoholic subjects on exposure to alcohol-specific cues. *Arch Gen Psychiatry* 2001; 58: 345–52.
- Haber SN. The primate basal ganglia: parallel and integrative networks. *J Chem Neuroanat* 2003; 26: 317–30.
- Kopelman MD, Thomson AD, Guerrini I, Marshall EJ. The Korsakoff syndrome: clinical aspects, psychology and treatment. *Alcohol Alcohol* 2009; 44: 148–54.
- Lambert C, Simon H, Colman J, Barrick TR. Defining thalamic nuclei and topographic connectivity gradients in vivo. *Neuroimage* 2017; 158: 466–79.
- Pitel AL, Segobin SH, Ritz L, Eustache F, Beaunieux H. Thalamic abnormalities are a cardinal feature of alcohol-related brain dysfunction. *Neurosci Biobehav Rev* 2015; 54: 38–45.
- Segobin S, Lanipece A, Ritz L, Lannuzel C, Boudehent C, Cabé N, et al. Dissociating thalamic alterations in alcohol use disorder defines specificity of Korsakoff's syndrome. *Brain* 2019; 142: 1458–70.
- Sullivan EV, Harris A, Pfefferbaum A. Alcohol's effects on brain and behavior. *Alcohol Res Health* 2010; 33: 127–43.
- WHO. Global status report on alcohol and health 2018. Geneva: World Health Organization; 2018.

Theoretically meaningful models can answer clinically relevant questions

This scientific commentary refers to 'The ease and sureness of a decision: evidence accumulation of conflict and uncertainty', by Mandali *et al.* (doi:10.1093/brain/awz013).

One of the most dominant models of human decision-making over the past decades has been the diffusion model (Ratcliff, 1978; Ratcliff *et al.*, 2016). However, the diffusion model may

not be familiar to all readers of *Brain*, as the model has primarily been applied within the field of cognitive psychology. The diffusion model proposes that decision-making