



Waine, K., Strugnell, B. W., Howie, F., Swinson, V., & Millar, M. (2019). Diaphragmatic lesions and fatal haemorrhage in Texel sheep. *Veterinary Record Case Reports*, 7(2), [e000745]. <https://doi.org/10.1136/vetreccr-2018-000745>

Peer reviewed version

License (if available):
Other

Link to published version (if available):
[10.1136/vetreccr-2018-000745](https://doi.org/10.1136/vetreccr-2018-000745)

[Link to publication record in Explore Bristol Research](#)
PDF-document

This is the accepted author manuscript (AAM). The final published version (version of record) is available online via BMJ at <http://dx.doi.org/10.1136/vetreccr-2018-000745> . Please refer to any applicable terms of use of the publisher.

University of Bristol - Explore Bristol Research

General rights

This document is made available in accordance with publisher policies. Please cite only the published version using the reference above. Full terms of use are available:
<http://www.bristol.ac.uk/pure/about/ebr-terms>

Veterinary Record casereports

Submission template for full cases

All case reports MUST be submitted online using this Word template. Please refer to the [Hints and Tips template](#) so you know what to include in each section

- <http://mc.manuscriptcentral.com/vetreccr>
- You will be asked for more detailed information on submission where you can also upload images, multimedia files, etc
- Further details are available in the [Instructions for authors](#)

For studies using client-owned animals the article must demonstrate a high standard (best practice) of veterinary care and have informed client consent

You, your practice or institution must be a subscriber to Veterinary Record Case Reports in order to submit. Subscribers can submit as many cases as they like, access all the published material, and re-use any published material for personal use and teaching without further permission.

- For more information on rates and how to purchase your subscription visit <http://vetrecordcasereports.bmj.com/site/about/Subslanding.xhtml>
- Contact your librarian, head of department or practice owner to see if your institution already has a subscription

TITLE OF CASE <i>Do not include "a case report"</i>
Diaphragmatic lesions and fatal haemorrhage in Texel sheep
SUMMARY <i>Up to 150 words summarising the case presentation and outcome (this will be freely available online)</i>
<p>Twelve Texel sheep were found to have diaphragmatic lesions, with or without thoracic haemorrhage, at post mortem examination over a period of two-and-a-half years. Presenting clinical signs ranged from general malaise or mild respiratory stertor, to severe respiratory distress or sudden death. Gross post mortem findings included focal areas of diaphragmatic haemorrhage, diaphragmatic musculature necrosis or diaphragmatic rupture with herniation of abdominal viscera into the thoracic cavity. In some cases, acute severe fatal haemorrhage from either thoracic vessels or the diaphragmatic lesions was observed. Histopathology confirmed an acute event leading to the sudden death of affected animals, but also suggested a pre-existing chronic diaphragmatic lesion of unknown aetiology.</p> <p>This case report suggests diaphragmatic lesions, with or without fatal thoracic haemorrhage, as a differential for respiratory distress or sudden death in young Texel sheep.</p>
BACKGROUND <i>Why you think this case is important – why did you write it up?</i>
<p>Diaphragmatic hernias have previously been reported as sporadic events in sheep (1–6). Possible causes include a congenital abnormality of the diaphragmatic musculature (1,7), increased abdominal or thoracic pressure during parturition (6), trauma through mounting or fighting (3) or a breed disposition in Texel sheep (1,5).</p> <p>Diaphragmatic lesions have also been observed in Texel sheep with severe laryngeal chondritis lesions which may suggest an aetiology related to increased respiratory effort (4,8) or possibly the effects of increased forces within the thorax or mediastinum. This theory is supported by findings of haemorrhage in diaphragmatic muscle fibres of Southdown sheep with laryngeal</p>

chondritis (9), and is also suspected to have caused a severe thoracic bleed in a Texel ram with laryngeal chondritis (8).

This case report describes a series of twelve Texel sheep diagnosed with diaphragmatic lesions at post mortem. It suggests that the condition may be more common than previously thought, and could be an important differential to consider when investigating severe respiratory signs or sudden death.

CASE PRESENTATION *Presenting features, clinical and environmental history*

Twelve Texel sheep, ten of which were male, presented for post mortem examination over a two-and-a-half year period (July 2015 – December 2017) at five different post mortem providers in England and Scotland (APHA Veterinary Investigation Centre, Shrewsbury; APHA Veterinary Investigation Centre, Thirsk; Farm Post Mortems Ltd, County Durham; Farm Animal Pathology Service, University of Bristol; SAC Disease Surveillance Centre, Edinburgh). Nine of the animals were less than 12-months-old (seven were between four and seven months of age), and one of the adults was in-lamb. Seven died suddenly with no clinical signs displayed, four showed respiratory signs that included wheezing, inspiratory stertor or dyspnoea and one animal presented with general malaise before being found dead the following day.

INVESTIGATIONS *If relevant*

All animals were in good body condition at the time of death. A summary of the gross lesions identified at post mortem examination are shown below:

Case	Diaphragmatic lesions	Thoracic haemorrhage	Laryngeal lesions
1	7cm vent in diaphragm with herniated abomasum in thoracic cavity	Not observed	Not observed
2	Large vent in diaphragm with herniated abomasum in thoracic cavity	Not observed	Moderate swelling and necrosis of right arytenoid cartilages
3	Vent in left dorsal aspect of diaphragm with herniated jejunum in thoracic cavity	Not observed	Not observed
4	Diaphragmatic necrosis	Severe left sided haemothorax; haemorrhage from diaphragmatic lesion close to vena cava	Not observed
5	Vent in diaphragm with haemorrhagic margin, muscle tearing, haemorrhage and fibrin. Liver herniated into thoracic cavity	Large blood clot in right mediastinal space and at root of diaphragm and liver. Haemorrhage from diaphragmatic lesion	Not observed
6	Vent in diaphragm with haemorrhagic margin. Herniated abomasum in thoracic cavity	Not observed	Not observed
7	Haemorrhage and thinning of 4cm diameter portion of abdominal surface of central diaphragm with associated 3mm thick blood clot. Multifocal haemorrhages on thoracic surface.	Severe haemothorax. Haemorrhage from diaphragmatic lesions or aorta.	Not observed
8	Multifocal areas of pallor	Focal haemorrhagic lesion cranial to diaphragm possible from hepatic vein	Moderate laryngeal chondritis
9	Defect in diaphragm with herniation of abomasum into thoracic cavity	Severe mediastinal haemorrhage	Some narrowing of laryngeal lumen

10	12cm x 4cm haemorrhagic thickening on right dorsal aspect of diaphragm adjacent to the caval opening.	Approximately 700mls of blood in the thoracic cavity – source unknown	Mild laryngeal chondritis
11	Bulging of diaphragm	2kg blood clot in right mediastinum – defect present in aorta	Moderate unilateral laryngeal chondritis
12	7cm vent in diaphragm on right side with herniated jejunum in thoracic cavity	Large blood clot in mediastinum next to diaphragmatic lesion	Not observed

The gross diaphragmatic lesions ranged from pallor, thickening and haemorrhage of the diaphragmatic musculature to full thickness defects with herniation of abdominal contents into the thoracic cavity (Figure 1-4). Thoracic haemorrhage was observed in seven of the cases and was often severe (Figures 5-8). The source of bleeding (where it could be identified) was either the diaphragmatic lesion or a ruptured vessel such as the aorta. Laryngeal lesions were observed in five of the eleven cases (Figure 9).

Tissues from five of the cases were fixed in 10 per cent buffered formalin and histological sections were routinely prepared for haemotoxylin and eosin staining.

Microscopic examination of the diaphragm from Case 5 showed haemorrhage at the margin of the tear on both sides, with fibrin and plump active spindle cells within the tissue. Some vessels contained fibrin clots. On one side of the skeletal muscle, a layer of fibrovascular tissue resembling organising granulation tissue was seen getting steadily thicker from muscle to tear margin. One section of diaphragmatic muscle showed fibrin, haemorrhage and organising granulation tissue with necrosis, fibrosis and mineralisation (chronic myofibre degeneration). The herniated portion of liver showed fibrin on the pleural surface with extensive multifocal haemorrhage and mid-zonal coagulative necrosis with mineralisation, suggesting remodelling. Similar changes were observed in the diaphragm of Case 12 suggesting chronic damage with acute necrosis and haemorrhage.

Case 7 showed necrosis of tissues with extensive granulation tissue, fibrosis and deposition of collagen. The diaphragm of Case 9 showed microscopic changes that included a large focus of acute haemorrhage and surrounding myofibre degeneration. Fibrin, oedema, mild suppurative inflammation and haemorrhage were present in the surrounding connective tissue. The dense connective tissue was highly cellular with many plump active cells. Histopathology of Case 11 identified a reduction in thickness of the fibro-elastic connective tissue confirming a spontaneous aortic rupture.

Histopathology of Case 4 revealed inflammation and fibrin on the surface of the diaphragm with numerous intralesional gram-positive bacilli. *Clostridium septicum* was isolated from the spleen which could suggest malignant oedema as a cause of the diaphragmatic necrosis, or possibly acting as an opportunistic secondary invader (local events may have lowered oxygen tension promoting activation of latent spores). The fact that these bacteria were intralesional suggests that the bacteria cultured were not postmortem contaminants.

A gram stain of a slide prepared from a swab from the site of diaphragmatic thickening and dark red colouration in Case 10 showed some gram-positive rods suggesting clostridial post mortem invasion.

DIFFERENTIAL DIAGNOSIS *If relevant*

Not applicable

TREATMENT <i>If relevant</i>
Not applicable
OUTCOME AND FOLLOW-UP
Not applicable
DISCUSSION <i>Include a very brief review of similar published cases</i>
<p>Diaphragmatic lesions, which may or may not proceed to full thickness tears with herniation of abdominal viscera, are an uncommon finding in sheep. The condition, however, does present a health and welfare issue for affected sheep, and the loss of animals close to slaughter, or intended for sale as breeding animals (terminal sires), has an economic cost for farmers.</p> <p>The histopathology conducted in the cases described suggests chronic damage with attempted repair, followed by an acute terminal event. Congenital diaphragmatic hernias could not be ruled out in the cases examined microscopically, but all animals in this case report were greater than 4 months-old which suggests a congenital effect is less likely(7).</p> <p>An acquired defect showing some healing (as determined by histological examination) (in contrast to a congenital hernia) was noted in one of the cases. Trauma remains a potential cause of an acquired defect and could be supported by the over representation of young rams where fighting and mounting within groups may be common (1,3). However, none of the cases were accompanied by a history of known trauma.</p> <p>The ewe that was in-lamb was 6-8 weeks away from parturition and therefore increased abdominal pressure as the single cause for the diaphragmatic hernia seen would be unlikely (6).</p> <p>Case 4 suggests that malignant oedema may have played a part in the pathogenesis of the necrotising myositis observed, although these bacteria could have been secondary invaders. The Gram-positive bacilli found in case 10 were presumed to be postmortem invaders but further testing was not carried out in the other cases. This may be an area for further investigation in the future. Mineralisation and granulation tissue formation were present in case 9. Granulation tissue formation does not usually feature in nutritional myopathy so the possibility of infection must be considered in this case.</p> <p>The relationship with laryngeal chondritis may be an epiphenomenon. Some of the cases discussed here had laryngeal lesions, which could suggest an association of the diaphragmatic pathology with an increased pressure exerted during respiratory dyspnoea. Should the cause of the diaphragmatic lesions be an undying congenital or genetic weakness in the diaphragm, then the association of the final acute event with increased respiratory effort may be highly plausible.</p> <p>Diaphragmatic hernias are reported in medicine most commonly associated with congenital defects or traumatic events (10–12). If the cause was trauma, one would expect other breeds to be represented in this case series. A less frequently reported cause of spontaneous diaphragmatic rupture in people is Ehlers-Danlos syndrome, a rare disorder causing abnormalities in the synthesis and structure of collagen(13,14). This condition has been reported in dogs, cats and rabbits, while dermatosparaxis has been reported in sheep and cattle (15). In animals however, reported cases of these syndromes describe thin and hyperextensible skin, atrophic scarring and lax joints. They do not mention acute diaphragmatic herniation.</p> <p>In agreement with previous publications, a breed predisposition in Texel sheep to diaphragmatic tearing and herniation can be speculated (1,5). However, the cases reported here were collated through conversations with individuals recalling specific cases and only a</p>

superficial search of post mortem and surveillance data. Recall bias may therefore have affected the cases that have been included. The Texel breed is also the most popular terminal sire used in the UK, and the sire of more than 12% of the national ewe flock, so over representation could be due to the high numbers in the national flock (16).

The pathogenesis and significance of the observed haemorrhages are unknown. Aortic rupture was confirmed by histopathology in one case but in the majority of the cases the haemorrhage appeared to be from the diaphragmatic lesions. The cases with thoracic haemorrhage did not necessarily correlate to the cases with laryngeal chondritis.

The incidence of subclinical degenerative diaphragmatic muscle lesions in Texel sheep, which do not lead to rupture, is unknown and may be worthy of further investigation.

In conclusion, this case report suggests that the prevalence of diaphragmatic hernias with or without fatal haemorrhage in Texel sheep may be higher than previously thought, and that it may be considered a differential for dyspnoea and sudden death. Further work is needed to determine the cause and the pathogenesis of the lesions described, particularly the degenerative diaphragmatic lesions which appear to precede the final diaphragmatic rupture.

LEARNING POINTS/TAKE HOME MESSAGES 3 to 5 bullet points – this is a required field

- Diaphragmatic lesions with or without severe thoracic haemorrhage should be considered as a differential for respiratory distress and sudden death in sheep
- In the cases of diaphragmatic herniation there appears to be a pre-existing defect in the diaphragm that goes on to rupture as a result of an acute event – the causes of both remain unknown
- The significance of the condition being seen predominantly in Texel sheep is interesting to note, but could just be due to the popularity of the breed and not necessarily a genetic predisposition
- The value of post mortem examinations in livestock and collaborations between institutes to recognise new and emerging disease conditions is highlighted by this case report.

REFERENCES Vancouver style

1. Busin V, Del Pozo J, Sargison N. The diagnosis of diaphragmatic hernia in a 4-month-old Texel lamb. *Livestock*. 2013 Nov 1;18(6):242–3.
2. Brooks G. Diaphragmatic hernias in Texel tup lambs. *Vet Rec*. 2004;155(24):783–4.
3. Earl J. Diaphragmatic hernia in a tup. *Vet Rec*. 2004;155(25):811.
4. Division SV. Sheep, respiratory tract conditions. *Vet Rec*. 2002;151:719.
5. Edwards GT, Schock A. Obstructive Jaundice and Photosensitization in a Lamb Secondary to Diaphragmatic Hernia. *J Comp Pathol*. 2010 Feb 1;142(2–3):205–7.
6. Ahmed SS, El-Hamamsy H. Diaphragmatic hernia in a sheep. *Vet Rec*. 1984 Oct 27;115(17):441.
7. Dennis SM, Leipold HW. Congenital hernias in sheep. *J Am Vet Med Assoc*. 1968 Apr 1;152(7):999–1003.
8. Lane JG, Brown PJ, Lancaster ML, Todd JN. Laryngeal chondritis in Texel sheep. *Vet Rec*. 1987 Jul 25;121(4):81–4.
9. Salisbury R. Chronic ovine laryngitis. *N Z Vet J*. 1956;4(4):144–6.
10. Long A-M, Bunch KJ, Knight M, Kurinczuk JJ, Losty PD, BAPS-CASS. Early population-based outcomes of infants born with congenital diaphragmatic hernia. *Arch Dis Child Fetal Neonatal Ed*. 2018 Jan 4;fetalneonatal-2017-313933.
11. Amer K. Thoracoscopic approach to congenital diaphragmatic hernias in adults: Southampton approach and review of the literature. *J Vis Surg*. 2017 Nov 30;3:176–176.
12. Allan Z, Peng C, Chandra R. Traumatic diaphragmatic rupture with underlying lung laceration and tension pneumoperitoneum. *J Surg Case Reports*. 2017 Jun;2017(6):rjx120.
13. Hamaoui K, Riaz A, Hay A, Botha A. Massive spontaneous diaphragmatic rupture in

- Ehlers-Danlos syndrome. *Ann R Coll Surg Engl.* 2012 Jan;94(1):e5-7.
14. Iglesias JL, Renard T. Diaphragmatic hernia in an 8-year-old with Ehlers-Danlos syndrome. *Pediatr Surg Int.* 1998 Oct 23;13(8):553-5.
 15. Halper J. Connective Tissue Disorders in Domestic Animals. In Springer, Dordrecht; 2014. p. 231-40.
 16. Texel breed Society. Research and development. 2018.

FIGURE/VIDEO CAPTIONS *figures should NOT be embedded in this document*

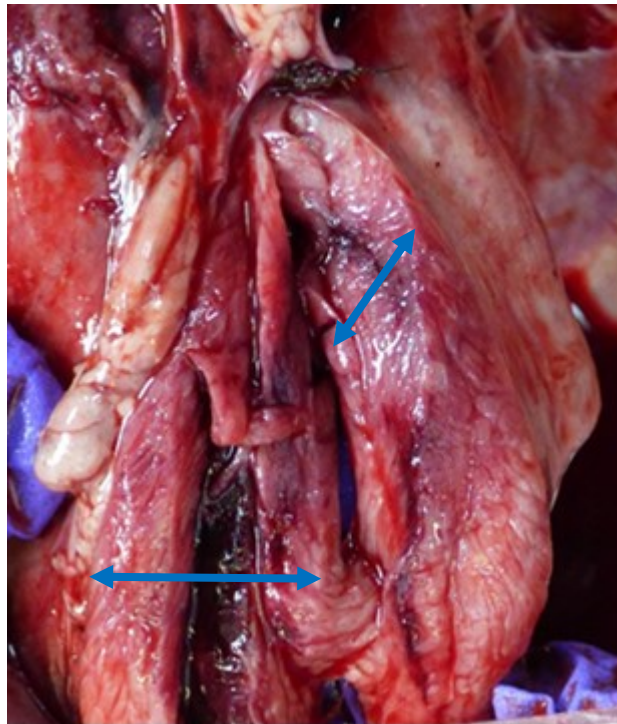


Figure 1 Incision of the thickened diaphragm (arrows) in Case 10
[Photo: Mick Millar]

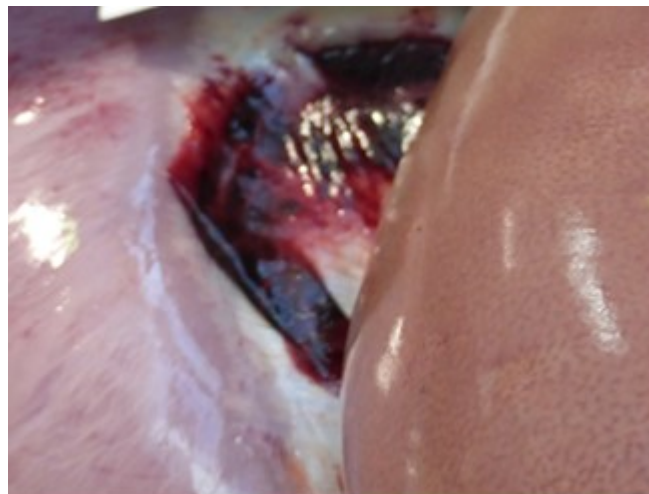

Figure 2 Area of haemorrhage on the abdominal surface of the diaphragm in Case 7
[Photo: Vanessa Swinson]

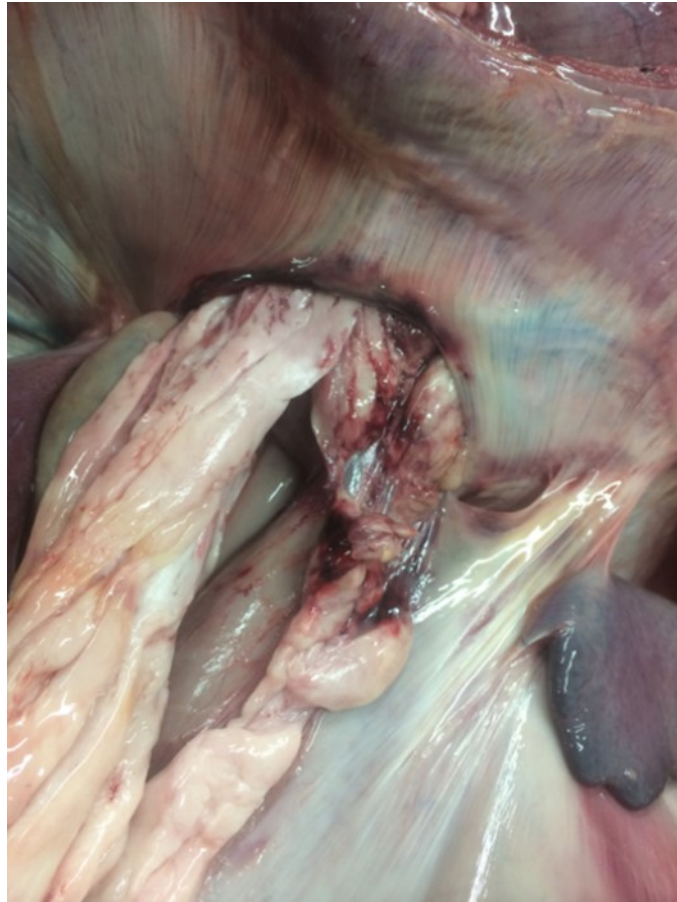

Figure 3 Haemorrhagic margin of the vent in the diaphragm with herniation of the abomasum into the thoracic cavity in Case 1 [Photo: Ben Strugnell]

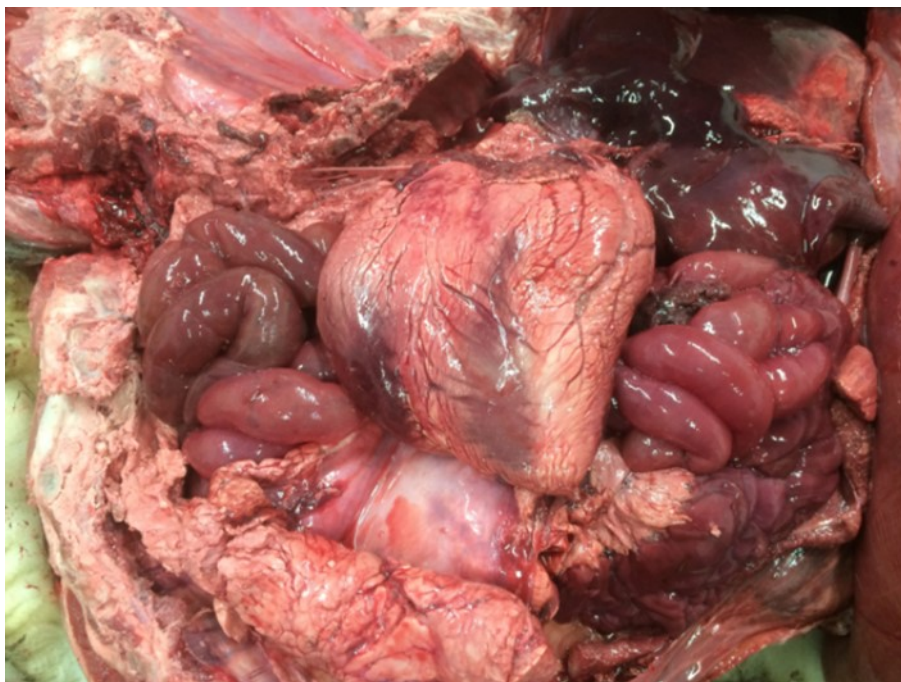


Figure 4 Herniation of the small intestines into the thoracic cavity in Case 3 [Photo: Ben Strugnell]

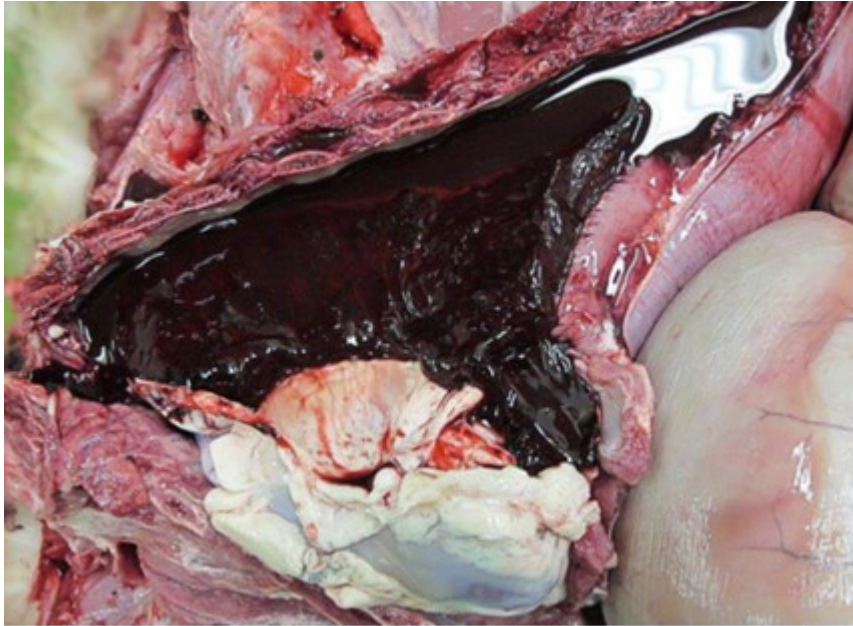


Figure 5 Severe left sided haemothorax seen in Case 4 [Photo: SAC]

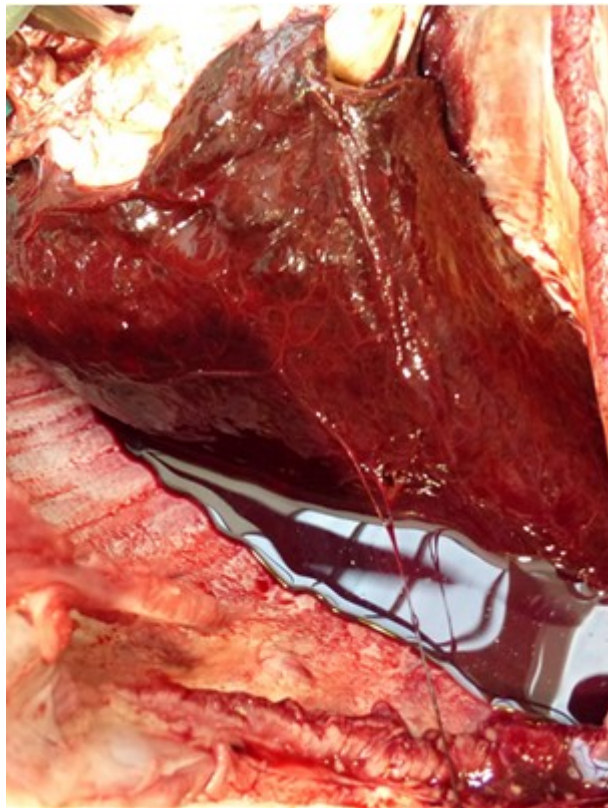


Figure 6 A large blood clot around the right lung lobe of Case 7 [Photo: Vanessa Swinson]

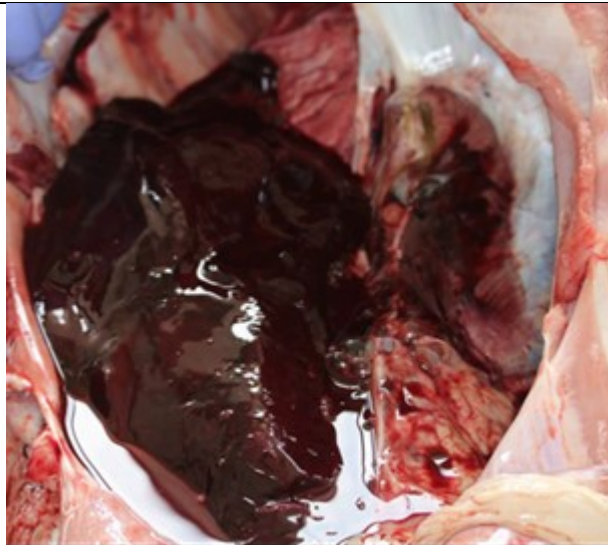


Figure 7 Large blood clot in the right mediastinum of Case 11 [Photo: APHA Shrewsbury]

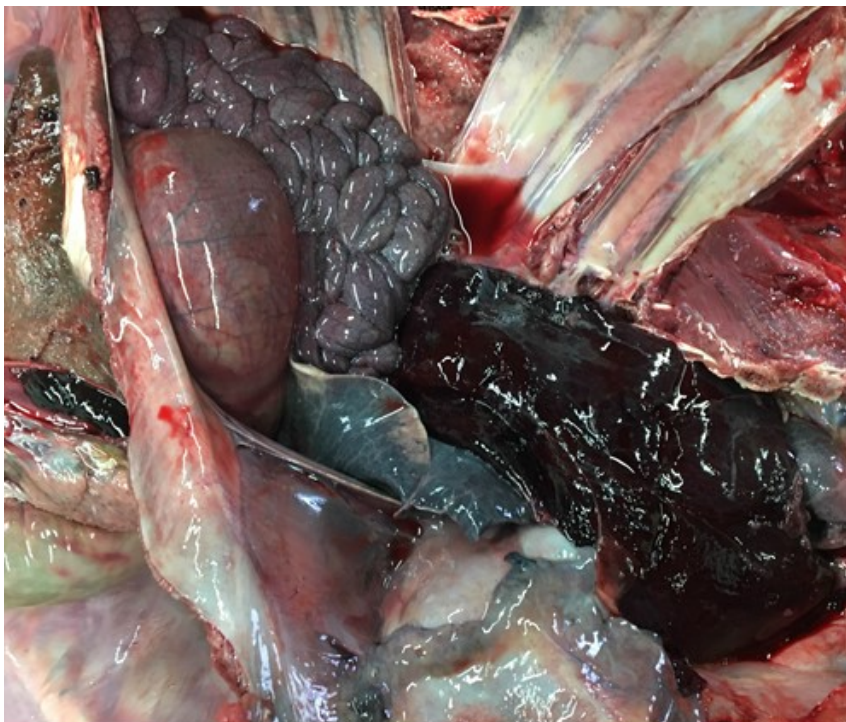

Figure 8 Large blood clot in the mediastinum of Case 11 [Photo: Ben Strugnell]

OWNER'S PERSPECTIVE *Optional*

N/A

Copyright Statement

I, _____, The Corresponding Author, has the right to assign on behalf of all authors and does assign on behalf of all authors, a full assignment of all intellectual property rights for all content within the submitted case report (other than as agreed with the BMJ Publishing Group Ltd and the British Veterinary Association) ("BMJ" and "BVA") in any media known now or created in the future, and permits this case report (if accepted) to be published on Veterinary Record Case Reports and to be fully exploited within the remit of the assignment as set out in the assignment which has been read <http://journals.bmj.com/site/misc/vetreccrcopyright.pdf>

Date:

PLEASE SAVE YOUR TEMPLATE WITH THE FOLLOWING FORMAT:

Corresponding author's last name and date of submission, eg,

Smith_June_2017.doc