

Breast Lesion Detection and Characterization With Contrast-Enhanced Magnetic Resonance Imaging: Prospective Randomized Intraindividual Comparison of Gadoterate Meglumine (0.15 mmol/kg) and Gadobenate Dimeglumine (0.075 mmol/kg) at 3T

Paola Clauser, MD,¹ Thomas H. Helbich, MD,^{1*} Panagiotis Kapetas, MD,¹
Katja Pinker, MD, PhD,^{1,2} Maria Bernathova, MD,¹ Ramona Woitek, MD,¹
Andreas Kaneider, MD,³ and Pascal A.T. Baltzer, MD¹

Background: Contrast-enhanced magnetic resonance imaging (CE-MRI) of the breast is highly sensitive for breast cancer detection. Multichannel coils and 3T scanners can increase signal, spatial, and temporal resolution. In addition, the T₁-reduction effect of a gadolinium-based contrast agent (GBCA) is higher at 3T. Thus, it might be possible to reduce the dose of GBCA at 3T without losing diagnostic information.

Purpose: To compare a three-quarter (0.075 mmol/kg) dose of the high-relaxivity GBCA gadobenate dimeglumine, with a 1.5-fold higher than on-label dose (0.15 mmol/kg) of gadoterate meglumine for breast lesion detection and characterization at 3T CE-MRI.

Study Type: Prospective, randomized, intraindividual comparative study.

Population: Eligible were patients with imaging abnormalities (BI-RADS 0, 4, 5) on conventional imaging. Each patient underwent two examinations, 24–72 hours apart, one with 0.075 mmol/kg gadobenate and the other with 0.15 mmol/kg gadoterate administered in a randomized order. In all, 109 patients were prospectively recruited.

Field Strength/Sequence: 3T MRI with a standard breast protocol (dynamic-CE, T₂w-TSE, STIR-T₂w, DWI).

Assessment: Histopathology was the standard of reference. Three blinded, off-site breast radiologists evaluated the examinations using the BI-RADS lexicon.

Statistical Tests: Lesion detection, sensitivity, specificity, and diagnostic accuracy were calculated per-lesion and per-region, and compared by univariate and multivariate analysis (Generalized Estimating Equations, GEE).

Results: Five patients were excluded, leaving 104 women with 142 histologically verified breast lesions (109 malignant, 33 benign) available for evaluation. Lesion detection with gadobenate (84.5–88.7%) was not inferior to gadoterate (84.5–90.8%) ($P \geq 0.165$). At per-region analysis, gadobenate demonstrated higher specificity (96.4–98.7% vs. 92.6–97.3%, $P \leq 0.007$) and accuracy (96.3–97.8% vs. 93.6–96.1%, $P \leq 0.001$) compared with gadoterate. Multivariate analysis demonstrated superior, reader-independent diagnostic accuracy with gadobenate (odds ratio = 1.7, $P < 0.001$ using GEE).

View this article online at wileyonlinelibrary.com. DOI: 10.1002/jmri.26335

Received Jun 19, 2018, Accepted for publication Aug 24, 2018.

*Address reprint requests to: T.H.H., Department of Biomedical Imaging and Image-guided Therapy, Division of Molecular and Gender Imaging, Medical University of Vienna / General Hospital Vienna, Waehringer Guertel 18-20, 1090 Vienna, Austria. E-mail: thomas.helbich@meduniwien.ac.at

From the ¹Department of Biomedical Imaging and Image-guided Therapy, Division of Molecular and Gender Imaging, Medical University of Vienna, Vienna, Austria; ²Department of Radiology, Breast Imaging Service, Memorial Sloan Kettering Cancer Center, New York, New York, USA; and ³Diagnose Zentrum Urania, Vienna, Austria

Additional supporting information may be found in the online version of this article.

This is an open access article under the terms of the Creative Commons Attribution NonCommercial License, which permits use, distribution and reproduction in any medium, provided the original work is properly cited and is not used for commercial purposes.

Data Conclusion: A 0.075 mmol/kg dose of the high-relaxivity contrast agent gadobenate was not inferior to a 0.15 mmol/kg dose of gadoterate for breast lesion detection. Gadobenate allowed increased specificity and accuracy.

Level of Evidence: 1

Technical Efficacy: Stage 2

J. MAGN. RESON. IMAGING 2019;49:1157–1165.

Contrast-enhanced magnetic resonance imaging (CE-MRI) of the breast is highly sensitive for breast cancer detection.^{1–3} Ongoing technological developments and rapid system turnover have made multichannel coils and 3T scanners broadly available for clinical use.⁴ Both these developments increase the available signal that can be invested into increased spatial and temporal resolution. In addition, the T₁-reduction effect of a gadolinium-based contrast agent (GBCA) is higher at 3T compared with 1.5T, which translates into a higher enhancement at T₁-weighted imaging.⁵ Both the higher signal-to-noise ratio (SNR) and the higher sensitivity to GBCAs suggest that it might be possible to reduce the dose of GBCA without losing diagnostic information at 3T. This could have relevant clinical implications, as GBCAs are expensive and are associated with several adverse effects.^{6,7}

Of the GBCAs available for breast MRI, gadobenate dimeglumine (MultiHance; Bracco, Milan, Italy) is a linear, ionic contrast agent characterized by a higher r₁ relaxivity⁸ due to weak, transient interaction of the gadobenate contrast-effective molecule with serum albumin.⁹ At 1.5T, this higher r₁ relaxivity translates into greater signal intensity, and thus, better lesion visualization and significantly better diagnostic performance for breast MRI when compared intraindividually with comparative standard relaxivity GBCAs at an equivalent dose.^{10–14} Findings with gadobenate for MR applications other than breast MRI have shown that a reduced dose provides image quality and diagnostic information similar to that achieved with a 2-fold higher dose of a comparative GBCA.^{15–19}

Based on the available evidence, we hypothesized that a reduced dose of gadobenate might also prove effective for breast lesion detection and characterization when compared with 1.5-fold higher than the on-label dose of a standard relaxivity GBCA (gadoterate meglumine, Dotarem; Guerbet, Aulnay-sous-Bois, France) under otherwise identical imaging conditions. Gadoterate meglumine is a macrocyclic, ionic GBCA characterized by a lower relaxivity, osmolality, and viscosity compared with gadobenate,²⁰ and it is commonly used for breast MRI in several institutions,²¹ including the one where this study was conducted. The aim of this prospective, randomized, single-center study was to intraindividually compare a three-quarter (0.075 mmol/kg bodyweight) dose of gadobenate with a 1.5-fold higher-than-on-label dose (0.15 mmol/kg bodyweight) of the standard relaxivity GBCA, gadoterate meglumine, with regard to noninferiority for breast lesion detection and characterization at 3T.

Materials and Methods

The local Ethics Review Board approved this investigator-initiated, prospective, double-blinded, randomized, single-center, controlled, crossover study and all regulatory approvals were granted (EudraCT number 2011-005498-21). All procedures were in accordance with the ethical standards as laid down in the 1964 Declaration of Helsinki and its later amendments. An unrestricted grant from Bracco (Milan, Italy) was provided to support the trial. All authors had full control of all data and statistical results. All patients gave written, informed consent. Patient enrollment occurred between November 2014 and May 2015.

Patient selection and Standard of Reference

Consecutive women presenting to our tertiary care university hospital breast unit for the assessment of abnormal breast imaging findings (ie, classified as BI-RADS 0, 4, or 5) on mammography, tomosynthesis, or ultrasound were eligible for this study. Excluded were women below 18 years of age, women who were pregnant or lactating, or who were undergoing radiation therapy, chemotherapy, or anticancer hormonal therapy, and women with contraindications to MRI (eg, pacemaker, metallic implants), a history of hypersensitivity to gadolinium chelates, or who had chronic renal disease. Women who were administered another contrast agent within 24 hours before the examination or underwent interventional procedures between the two MRI examinations were also excluded.

Lesions considered suspicious after completion of both MRI examinations underwent image-guided biopsy. Histopathology performed within 1 week after the MRI examinations, from either image-guided biopsy or surgical excision, was considered the standard of reference. For lesions classified as high-risk (lesions with an uncertain malignant potential) after image-guided biopsy, surgical excision was performed and the postsurgical results were considered for the analysis.

Clinical data were collected (age, menopausal status, symptoms, indication for CE-MRI), as well as data on adverse reactions following GBCA administration.

Image Acquisition

All examinations were performed using a 3T magnet (TIM Trio, Siemens Healthcare, Erlangen, Germany) with a dedicated 16-channel bilateral breast coil (Sentinelle, Invivo, Best, The Netherlands). Patients were examined in the prone position using a standard protocol, as recommended by international guidelines.²² Images were acquired in the axial plane with the following sequences: a T₂-weighted short tau inversion recovery sequence (STIR, repetition time [TR] = 4800 msec, echo time [TE] = 59 msec, inversion time [TI] = 230 msec, spatial resolution 0.7 × 0.7 × 4 mm, interslice gap 20%, 44 slices, GRAPPA factor 3, acquisition time [TA] 2:35); a T₂-weighted turbo spin echo

sequence (TSE, TR = 4630 msec, TE = 194 msec, spatial resolution $0.7 \times 0.5 \times 2.5$ mm, interslice gap 20%, 65 slices, GRAPPA factor 3, TA = 2:48); and a readout-segmented, multishot, echo-planar, imaging-based diffusion-weighted imaging (DWI) sequence (RESOLVE, TR = 5800 msec, TE₁ = 68 msec, TE₂ = 116 msec, b values 0 and 850 s/mm², spatial resolution $1.4 \times 1.4 \times 4$ mm, no interslice gap, 28 slices, TA = 2:54). Contrast-enhanced T₁-weighted images were acquired using a view-sharing, 3D, time-resolved angiography with stochastic trajectory, gradient echo sequence (TWIST, TR = 6.23 msec, TE = 2.95 msec, spatial resolution $0.9 \times 0.9 \times 1.1$ msec, 140 slices, GRAPPA factor 3, temporal resolution 28 sec, one pre- and 10 postcontrast acquisitions). After the baseline (*k*-space mask) scan, contrast agent was injected intravenously, without a delay, using an automated injector (Spectris, Medrad, Pittsburgh, PA). Contrast agent was administered intravenously at a rate of 3 ml/s, followed by a 15-ml saline flush at the same rate.

Patients were randomized into two groups. One group received gadoterate (0.15 mmol/kg) for the first examination and gadobenate (0.075 mmol/kg) for the second examination, while the other group received the two GBCAs in reverse order. Each patient received both contrast agents with the second examination performed at least 24 hours after the first examination to allow for clearance of the first agent from the body, but within 72 hours to assure equivalent morphological and functional conditions.

The dose of gadobenate (0.075 mmol/kg) was based on findings from previous studies for other indications in which a lower dose of gadobenate compared favorably with a higher dose of standard relaxivity GBCA.^{15–18,23} The comparator agent gadoterate was chosen primarily because it is the GBCA routinely used in our center for breast MRI. A higher-than-on-label dose (0.15 mmol/kg) was selected for this study for three reasons: 1) gadoterate has the lowest r1 relaxivity of all GBCAs at 3T (~ 3.4 L·mmol⁻¹·sec⁻¹ compared with ~ 5.35 L·mmol⁻¹·sec⁻¹ for gadobenate), and thus, might be expected to provide a relatively lower enhancement (8); 2) comparative studies with gadobenate for other indications have revealed similar imaging performance for a half-dose of gadobenate compared with a full dose of gadoterate,^{17–19} as well as superior performance for a three-quarter dose (0.075 mmol/kg) of gadobenate compared with a full dose of gadoterate²⁴; 3) an early interindividual comparative study revealed not dissimilar imaging performance for a half-dose (0.05 mmol/kg) of gadobenate compared with full and double doses (0.1 and 0.2 mmol/kg) of the standard relaxivity GBCA gadopentetate dimeglumine (Magnevist; Bayer, Berlin, Germany) for breast MRI.¹⁰ This dosage set-up for our breast MR imaging protocol is in line with international recommendations and current European clinical practice.^{4,25}

Image Analysis

Three independent readers with 8–15 years of experience in breast MRI evaluated all images off-site in three separate reading sessions. Each reader was blinded to all clinical and radiological information including the type of contrast agent. The reading sessions were performed on a dedicated workstation (multimonitor imaging TeraRecon client server, TeraRecon AquariusNet server v. 4.4.5.36) with all routine image-processing functions (eg, window/level, zoom, pan, etc.) available.

In each of the first two unpaired sessions, half the examinations performed with gadoterate and half of those performed with

gadobenate were displayed and assessed in randomized order. The entire examination was available for the readings. Readers were asked to evaluate precontrast along with early and delayed postcontrast sequences including subtracted images. T₂-weighted sequences, DWI, and nonsubtracted images were available for the evaluation if the readers deemed it necessary. Readers were asked first to assess the technical adequacy of the images. Thereafter, for all technically adequate images, each reader was asked to define the presence, number, location, size (≤ 5 mm / 6–10 mm / 11–20 mm / >20 mm), and nature (benign/high-risk/malignant) of all enhancing lesions according to the BI-RADS lexicon.²⁶ The presence and location of lesions in this Obuchowski Level III setup²⁷ were defined using a scheme (Supplemental Material, Fig. a) that divided the breast into five regions: upper-outer, upper-inner, lower-outer, lower-inner, and retroareolar. Lesions classified as BI-RADS >3 were considered suspicious. Diagnostic confidence was assigned to BI-RADS scores ranging from 1 (minimal) to 5 (maximal). Breast density (amount of fibroglandular tissue [FGT]; a, almost entirely fat; b, scattered FGT; c, heterogeneous FGT; d, extreme FGT) and background parenchymal enhancement (BPE; a, minimal; b, mild; c, moderate; d, marked) were also assessed according to the BI-RADS lexicon.²⁶

In the third session, gadobenate and gadoterate examinations of the same patient were placed side-by-side in randomized order to comparatively assess examination quality. In this session, readers expressed a preference for one image set or the other in terms of lesion conspicuity and lesion border delineation relative to surrounding normal breast tissue (each evaluation based on a five-point scale from -2 to $+2$, with 0 indicating equality of the two examinations), and overall diagnostic preference based on available radiological information for diagnosis or clinical management (a seven-point scale from -3 to $+3$, with 0 indicating equality of the two examinations).

Finally, an on-site radiologist performed lesion-tracking. Only lesions detected by at least one reader for one contrast agent, and for which the standard of reference was available (histology obtained with image-guided biopsy or surgical excision), were included. The on-site reader assessed whether the same lesions had concordantly been identified by all readers and with both contrast agents. If a reader missed a lesion, the classification was considered incorrect for that reader. Likewise, if a malignant lesion was detected by a reader, but classified as BI-RADS 2 or 3, then the classification was considered incorrect for that reader. In case of doubt, a second on-site reader was consulted.

Statistical Analysis

The patient sample size was based on the primary efficacy analysis, ie, the noninferiority of 0.075 mmol/kg gadobenate compared with 0.15 mmol/kg gadoterate for the detection of malignant breast lesions. The noninferiority margin was set at -10% , with a study power of 85%. Lesion detection was calculated for all lesions identified, regardless of the BI-RADS classification. Detection rate (lesions identified / total lesions included in the study), sensitivity, specificity, and diagnostic accuracy were calculated separately for each reader and for each contrast agent, and compared using the McNemar test. Analysis was performed both per-lesion and per-region. The per-region analysis (Obuchowski Level III²⁷ considered the presence or absence of suspicious findings (BI-RADS 4 and 5) for each of the five predefined regions of each breast. Logistic regression model was

performed to determine if lesion size, FGT, and type of lesions were predictors for the sensitivity, specificity, and accuracy of the lesion characterization. Finally, Generalized Estimating Equations (GEE) were used to evaluate the effect of readers and contrast agent on diagnostic accuracy. Fisher’s exact-test was used to test for differences in the false-positive (FP) rate between readers and GBCAs. Wilcoxon’s signed rank test was used to evaluate the differences in the paired assessment. Interreader agreement about lesion nature (benign vs. malignant) was assessed using kappa statistics. All statistical tests were two-sided at the $P < 0.05$ level of significance.

Results

Patient Characteristics and Safety Analysis

A flow chart with subject enrollment and dropout is shown in Fig. 1. The final population included 104 patients from 26 to 84 years of age (mean ± standard deviation: 51.7 ± 13.45 years). Clinical data and indications to perform breast CE-MRI, as well as information on breast density and background parenchymal enhancement, are given in Tables 1 and 2. A total of 142 histologically verified breast lesions (109 malignant, 33 benign) were identified (Table 3).

No moderate or severe adverse events were reported. Only one minor adverse event (self-limiting urticaria) was reported after gadoterate injection.

Detection Rate

A three-quarter dose of gadobenate was not inferior to a 1.5-fold higher-than-on-label dose of gadoterate for breast lesion detection

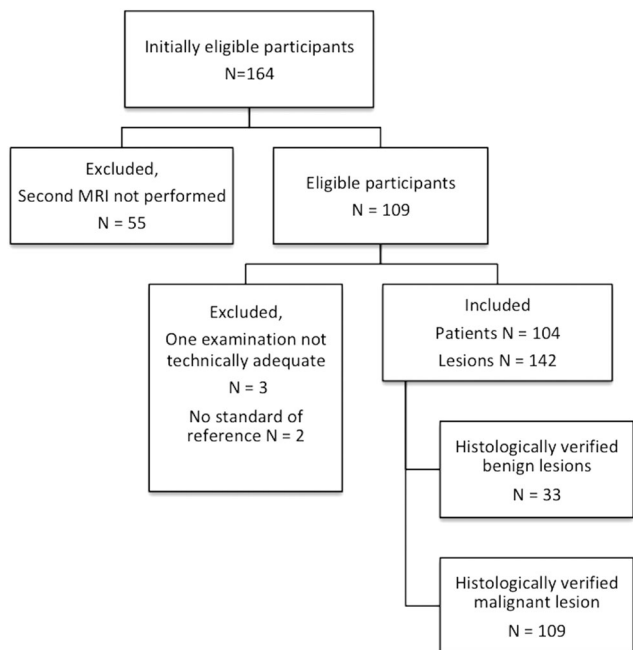


FIGURE 1: Flow chart showing the inclusion process. Examination was considered not technically adequate when the target lesion was outside the field of view, or reconstruction artifacts in the postcontrast images were present in one of the examinations, which made the images of not sufficient quality for evaluation according to at least one reader.

TABLE 1. Clinical Data and Indications to Perform Breast MRI

Number of patients (%)	
Menopausal status	
Premenopausal	47 (45.2)
Perimenopausal	3 (2.9)
Postmenopausal ^a	54 (51.9)
Symptoms	
No symptoms	55 (52.9)
Palpable lesion	35 (33.7)
Skin thickening	13 (12.5)
Nipple retraction	4 (3.8)
Nipple discharge	3 (2.9)
MRI indications	
Staging of a highly suspected breast cancer	66 (63.5)
Evaluation of a suspicious lesion	15 (14.4)
Evaluation of equivocal findings	23 (22.2)

^aPhysiological and postsurgical (ie, ovariectomy) menopause were considered together.

for any reader ($P \geq 0.165$; Table 4). Lesion detection was high, ranging from 84.5–88.7% for gadobenate and from 84.5–90.8% for gadoterate. Five of the 25 lesions (20%) not detected by at least one reader with gadobenate and five of the 23 (22%) lesions not detected with gadoterate were malignant ($P > 0.06$). Two invasive lobular carcinomas and three ductal carcinomas in situ were missed by at least one reader with both contrast agents.

Diagnostic Performance: Per-Lesion Analysis

In the 0.075 mmol/kg gadobenate group, higher sensitivity, specificity, and diagnostic accuracy were observed; however, only the higher specificity reported by Reader 1 was statistically significant ($P = 0.034$) (Table 4).

Lesions incorrectly classified by at least one reader are described in the Supplemental Material (Table a). Multivariate analysis showed that the FP rate was not influenced by the background parenchymal enhancement (BPE, $P > 0.319$). This was true despite a generally higher BPE in the examinations performed with gadoterate (moderate or marked BPE present in 34.6–68.2% of the examinations with gadoterate vs. 29.8–57.7% with gadobenate [Table 2]).

Multivariate analysis showed that 0.075 mmol/kg gadobenate was superior to 0.15 mmol/kg gadoterate for tumor characterization (odds ratio [OR] = 1.43, $P = 0.003$) and that this result was independent of the readers. Interreader agreement on

TABLE 2. Distribution of Fibroglandular Breast Tissue (FGT) and Background Parenchymal Enhancement (BPE), for Each Reader and Contrast Agent

	Reader 1		Reader 2		Reader 3	
	Gadobenate No. (%)	Gadoterate No. (%)	Gadobenate No. (%)	Gadoterate No. (%)	Gadobenate No. (%)	Gadoterate No. (%)
FGT a	45 (43.3)	40 (38.5)	18 (17.3)	19 (18.3)	4 (3.8)	5 (4.8)
FGT b	27 (26.0)	30 (28.8)	20 (19.2)	21 (20.2)	39 (37.5)	40 (38.5)
FGT c	18 (17.3)	18 (17.3)	37 (35.6)	33 (31.7)	48 (46.2)	45 (43.3)
FGT d	14 (13.5)	16 (15.4)	29 (27.9)	31 (29.8)	13 (12.5)	14 (13.5)
BPE a	44 (42.3)	37 (35.6)	40 (38.5)	36 (34.6)	21 (20.2)	12 (11.5)
BPE b	29 (27.9)	31 (29.8)	16 (15.4)	14 (13.5)	23 (22.1)	21 (20.2)
BPE c	20 (19.2)	20 (19.2)	17 (16.3)	18 (17.3)	26 (25.0)	30 (28.8)
BPE d	11 (10.6)	16 (15.4)	31 (29.8)	36 (34.6)	34 (32.7)	41 (39.4)

lesion nature was moderate for both contrast agents ($\kappa = 0.398$ with gadobenate and $\kappa = 0.370$ with gadoterate).

Logistic regression showed no effect of FGT on readers' accuracy ($P \geq 0.256$ with gadobenate and $P = 0.133$ with gadoterate).

Lesion size was a significant positive predictor in both groups for all three readers, with significantly better accuracy

for larger lesions noted by Reader 1 for gadoterate ($P = 0.004$) and by Reader 2 for both gadobenate and gadoterate ($P = 0.028$ and $P = 0.003$, respectively).

Lesion type had no effect on accuracy for Reader 1 ($P = 0.341$ with gadobenate and $P = 0.133$ with gadoterate) and Reader 2 ($P = 0.673$ with gadobenate and $P = 0.078$ with gadoterate). Reader 3 reported higher accuracy for nonmass lesions with both contrast agents ($P = 0.041$ with gadobenate and $P = 0.008$ with gadoterate).

TABLE 3. Histology of the 109 Malignant and 33 Benign Lesions Included in the Analysis

Histology	Number of lesions (%)
Malignant	
Invasive carcinoma NST	66/109 (60.6)
Ductal carcinoma in situ	23/109 (21.1)
Invasive lobular carcinoma	16/109 (14.7)
Others ^a	4/109 (3.6)
Benign	
Fibrocystic changes	19/33 (57.6)
Papilloma without atypias	5/33 (15.2)
Fat necrosis	4/33 (12.1)
Sclerosing adenosis without atypias	3/33 (9.1)
Fibroadenoma	2/33 (6.0)

NST: nonspecial type.

^aOne medullary carcinoma, one mucinous carcinoma, one invasive ducto-lobular carcinoma, one secretory carcinoma.

Diagnostic Performance: Per-Region Analysis

Per-region analysis was performed by dividing each breast into five regions (Supplemental Material Fig. a) to give 1040 regions in total.

In the per-region analysis (Table 5), all readers reported better performance with 0.075 mmol/kg gadobenate group than with 0.15 mmol/kg gadoterate. Significant differences were found by Reader 2 for sensitivity ($P = 0.011$) and by all three readers for specificity and accuracy ($P < 0.007$ and $P < 0.001$, respectively).

The number of FP cases was lower in the 0.075 mmol/kg gadobenate group than in the 0.15 mmol/kg gadoterate group for all three readers: 31 (3.0%) vs. 63 (6.1%); 18 (1.7%) vs. 29 (2.8%); and 11 (1.1%) vs. 23 (2.2%) for Readers 1, 2, and 3, respectively.

The GEE model confirmed the superior diagnostic accuracy with gadobenate (OR = 1.7, $P < 0.001$), with only minor differences between readers. In the model adjusted for random and fixed reader effects, the differences between both contrast media groups were confirmed. Examples of the contrast enhancement achieved with both agents and the better diagnostic performance achieved in the 0.075 mmol/kg gadobenate group are shown in Figs. 2 and 3.

TABLE 4. Detection Rate, Sensitivity, Specificity, and Accuracy Calculated on a Per-Lesion Basis for the Three Readers

Parameter	Reader 1			Reader 2			Reader 3		
	Gadoterate	Gadobenate	<i>P</i> ^a (95% CI) ^b	Gadoterate	Gadobenate	<i>P</i> ^a (95% CI) ^b	Gadoterate	Gadobenate	<i>P</i> ^a (95% CI) ^b
Detection	90.8 (129/142)	87.3 (124/142)	0.165 (-8.5,1.4)	84.5 (120/142)	84.5 (120/142)	1.000 (-3.9,3.9)	90.8 (129/142)	88.7 (126/142)	0.317 (-6.2,2.0)
Sensitivity	97.2 (106/109)	95.4 (104/109)	0.157 (-4.4,0.7)	88.1 (96/109)	91.7 (100/109)	0.157 (-1.4,8.7)	89.9 (98/109)	92.7 (101/109)	0.257 (-2.0,7.5)
Specificity	57.6 (19/33)	75.8 (25/33)	0.034 (2.6,34)	66.7 (22/33)	72.7 (24/33)	0.157 (-2.1,14)	78.8 (26/33)	87.9 (29/33)	0.083 (-0.7,19)
Accuracy	88.0 (125/142)	90.8 (129/142)	0.206 (-1.5,7.2)	83.1 (118/142)	87.3 (124/142)	0.058 (-0.1,8.5)	87.3 (124/142)	91.5 (130/142)	0.058 (-0.1,8.5)

^aMcNemar test.
^b95% confidence interval for difference; noninferiority of gadobenate was demonstrated if the lower limit of the 95% CI was greater than -10%.

TABLE 5. Sensitivity, Specificity, and Accuracy Calculated on a Per-Region Basis (See Supplemental Material Figure a) for the Three Readers

Parameter	Reader 1			Reader 2			Reader 3		
	Gadoterate	Gadobenate	<i>P</i> -value	Gadoterate	Gadobenate	<i>P</i> -value	Gadoterate	Gadobenate	<i>P</i> -value
Sensitivity	97.8 (179/183)	96.2 (176/183)	0.083	89.6 (164/183)	94.0 (172/183)	0.011	90.2 (165/183)	93.4 (171/183)	0.083
Specificity	92.6 (794/857)	96.4 (826/857)	0.001	96.6 (828/857)	97.9 (839/857)	0.007	97.3 (834/857)	98.7 (846/857)	0.005
Accuracy	93.6 (973/1040)	96.3 (1002/1040)	0.001	95.4 (992/1040)	97.2 (1011/1040)	0.001	96.1 (999/1040)	97.8 (1017/1040)	0.001

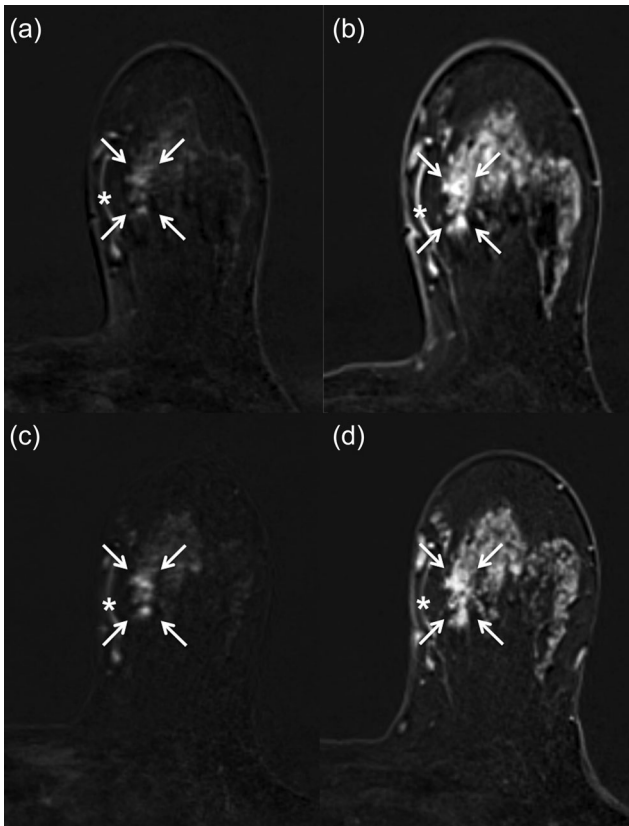


FIGURE 2: Invasive breast cancer in the left breast of a 46-year-old woman. Postcontrast, subtracted, T₁-weighted 3D gradient echo images (TR 6.23 msec, TE 2.95 msec) acquired 1 minute (a) and 5 minutes (b) after the administration of 0.15 mmol/kg of gadoterate meglumine. A moderate background parenchymal enhancement was present in both examinations. The arrows indicate an area of clumped nonmass enhancement, which is difficult to differentiate from background parenchymal enhancement (BPE). Two of the three readers classified this area as BI-RADS 2 (benign finding). Postcontrast, subtracted, T₁-weighted 3D gradient echo images acquired 1 minute (c) and 5 minutes (d) after the administration of 0.075 mmol/kg of gadobenate dimeglumine. The arrows indicate the area of clumped nonmass enhancement in the early postcontrast sequence, which is clearly visible despite the BPE in the late postcontrast sequence. Two of the three readers classified this area as BI-RADS 4 (suspicious). Asterisk indicates a vessel.

Confidence and Paired Assessment

Reader confidence in BI-RADS assessment was high (median = 4, for all readers), regardless of the contrast agent used. In the paired assessment (Supplemental Material Table b), the two examinations were considered equal in quality in more than 50% of cases (ranging from 52.4–91.3% depending on the reader and the endpoint) by all three readers. For the remaining cases, the readers preferred 0.15 mmol/kg gadoterate in 4.3–25.2% of the cases and 0.075 mmol/kg gadobenate in 3.9–22.3% of the cases with no significant difference in terms of preference (*P* > 0.392).

Discussion

Our study shows that a three-quarter (0.075 mmol/kg) dose of gadobenate is not inferior to a 0.15 mmol/kg dose of

gadoterate for breast lesion detection. Specifically, three blinded, unaffiliated readers assigned fewer FP ratings with the reduced dose of gadobenate, which resulted in small, but highly significant benefit in specificity for lesion characterization, without a loss of sensitivity for lesion detection. A clear clinical impact of this finding is a lower number of unnecessary breast biopsies of benign breast tumors, and, consequently, fewer short-term follow-up examinations and lower costs. Importantly, all three readers considered the images with both agents to be of comparable quality in most cases,

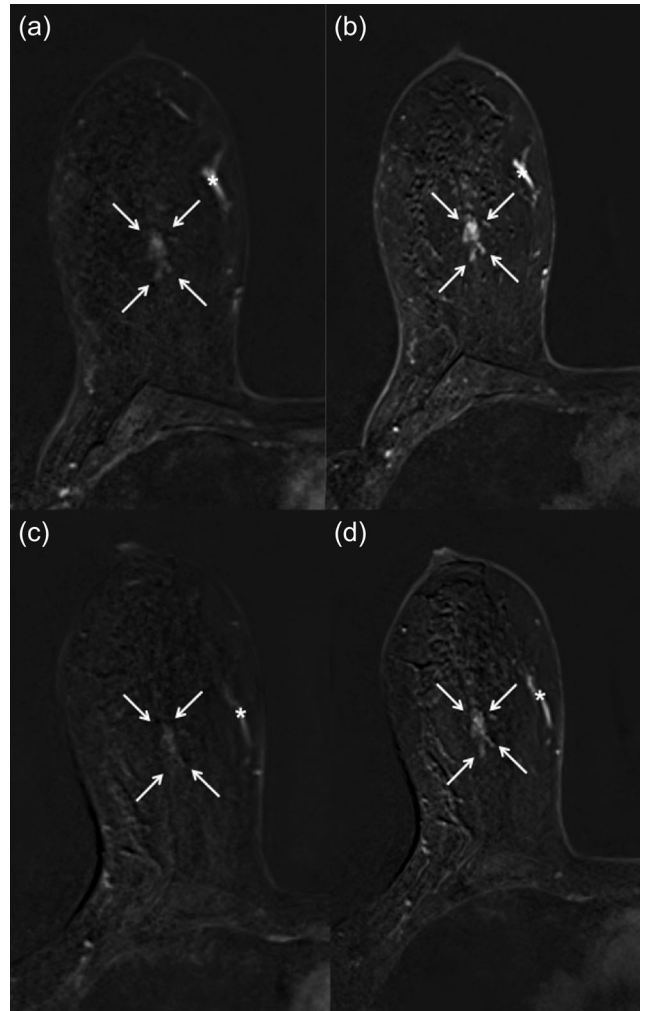


FIGURE 3: MRI of the breast in a 39-year-old woman. Histology revealed an area of pseudoangiomatous stromal hyperplasia in the right breast. Postcontrast, subtracted, T₁-weighted 3D gradient echo images (TR 6.23 msec, TE 2.95 msec) acquired 1 minute (a) and 5 minutes (b) after the administration of 0.15 mmol/kg of gadoterate meglumine. A minimal background parenchymal enhancement was present in both examinations. The arrows indicate an area of heterogeneous nonmass enhancement. The readers classified the enhancement as BI-RADS 4 (suspicious). Postcontrast, subtracted, T₁-weighted 3D gradient echo images acquired 1 minute (c) and 5 minutes (d) after the administration of 0.075 mmol/kg of gadobenate dimeglumine. The arrows indicate the area of nonmass enhancement, which presented with a weak enhancement and was classified by the readers as BI-RADS 2 (benign finding). Asterisk indicates a vessel.

with neither agent demonstrating a significant advantage over the other for any qualitative endpoint.

Previous intraindividual crossover studies at 1.5T compared gadobenate with gadopentetate at an equivalent approved dose of 0.1 mmol/kg bodyweight.^{10–13} Martincich et al¹³ showed a reduction in the rate of cancer misdiagnosis when comparing the same dose of gadobenate and gadopentetate. In addition, two studies by Pediconi et al demonstrated that gadobenate leads to an improved diagnostic performance compared with gadopentetate.^{11,12} The superior diagnostic performance observed was ascribed to the greater signal intensity enhancement achievable with gadobenate due to its higher relaxivity. A more recent study at 1.5T compared gadobenate with the macrocyclic GBCA gadobutrol (Gadovist; Bayer) at an equivalent dose (0.1 mmol/kg)²⁸ and reported noninferiority for gadobutrol with regard to lesion detection and sensitivity for characterization based on findings from two blinded readers.

Our study demonstrates that it is feasible to reduce the dose of the administered GBCA at 3T without losing important information in terms of lesion detection and sensitivity. This seems to be particularly relevant considering the growing concern over gadolinium deposition in the brain following GBCA administration.²⁹ In this regard, it is worth bearing in mind that gadolinium retention has been observed in both the brain and other body tissues after administration of both linear and macrocyclic GBCAs,³⁰ and as yet there is no evidence of any detrimental clinical signs or symptoms.^{29,31,32} Based on our findings and those of others,^{11–14} in the absence of definitive data regarding the potential risk of gadolinium retention (or lack thereof), it would seem prudent to consider a lower dose of gadobenate (ie, less administered gadolinium), at least for diagnostically challenging indications such as locoregional staging and problem-solving. Currently, a large-scale prospective randomized phase II trial is under way to evaluate a gadobenate-based MRI protocol as an additional screening test in women with dense breasts.³³ If this trial proves successful, our findings may prove useful in terms of dose optimization.

A further advantage of using a reduced dose of GBCA might be a reduction in BPE, an effect that may be pronounced at 3T due to the inherently higher sensitivity to GBCAs.⁵ A reduction in BPE facilitates lesion characterization and may be one reason for the increased specificity of the readers in the reduced-dose group in our study. In addition to a BPE reduction, a lower GBCA dosage will also lead to a lower contrast enhancement of suspicious lesions. Due to our specific study design, we cannot answer whether it is generally possible to reduce GBCA dosages at 3T without reducing sensitivity. Importantly, all three readers considered the images from both agents to be of comparable quality in most cases, with neither agent demonstrating a significant advantage over the other for any qualitative

endpoint. In studies that have compared equivalent doses^{11,13} at 1.5T, readers preferred examinations performed with gadobenate, a finding that does not seem to apply at 3T comparing different doses.

Our study has several limitations. First, the dose of gadoterate used (0.15 mmol/kg) was higher than the recommended dose (0.1 mmol/kg). This has two possible consequences for specificity: a higher dose will lead to both an increased lesion enhancement and higher BPE, both likely leading to a higher FP rate. A detrimental effect of BPE on FP rates, however, could not be corroborated by multivariate analysis. A side-by-side evaluation of examinations with both agents revealed no differences in contrast enhancement or image quality; thus, there are no obvious reasons for a higher FP rate with gadoterate, based on contrast enhancement. Although our data do not allow us to answer the question whether a reduced contrast medium dose will generally improve breast MRI specificity at 3T, we deem this quite likely. However, trying to improve specificity may lead to decreased sensitivity. Although the reduced dosage of the high-relaxivity contrast agent gadobenate achieved sensitivities equal to even a higher-than-on-label dose of gadoterate, our data do not allow drawing conclusions about contrast media with lower relaxivity in this respect. A lower dose of a low-relaxivity contrast medium may lead to a lower lesion detection rate and poorer diagnostic performance. Second, our study was a single-center observational study performed in patients who presented with suspicious findings on conventional imaging. Only cases for which a histological examination was performed were included, leading to greater selection of more suspicious or complicated lesions, and to a higher rate of malignancy in our cohort. Third, we did not perform kinetic analysis and did not compare the dynamic enhancement-time curves for gadobenate and gadoterate. This would be of interest for further studies but was considered beyond the scope of this analysis. Fourth, the lack of long-term follow-up suggests the possibility—albeit small—that single FN findings were missed. Consequently, the study design is associated with a minor risk of overestimating sensitivity and a moderate risk of underestimating specificity. Finally, we considered noninvasive ductal carcinoma *in situ* as a malignant lesion for this study, which is generally in line with the surgical management.

In conclusion, a three-quarter dose (0.075 mmol/kg) of high-relaxivity gadobenate is not inferior to a 1.5-fold higher-than-on-label dose (0.15 mmol/kg) of lower relaxivity gadoterate for breast lesion detection. Moreover, the reduced dose of gadobenate allows improved lesion characterization by lowering the number of FP reports, thus leading to increased specificity and diagnostic accuracy. The use of a reduced dose of gadobenate would seem particularly beneficial for diagnostically challenging indications, such as locoregional staging and problem-solving cases.

Acknowledgments

The authors thank the three readers, Federica Pediconi, MD, Luca Carbonaro, MD, and Matthias Dietzel, MD, for their dedicated effort. We thank Dr. Gunter Erb for the fruitful discussion, Claudio Spick, MD, for assistance in data collection, Gianpaolo Pirovano and Massimo Bona for assistance in data management, and Miles Kirchin and Gianpaolo Pirovano for assistance in article preparation and language revision.

References

- Houssami N, Ciatto S, Macaskill P, et al. Accuracy and surgical impact of magnetic resonance imaging in breast cancer staging: systematic review and meta-analysis in detection of multifocal and multicentric cancer. *J Clin Oncol* 2008;26:3248–3258.
- Riedl CC, Luft N, Bernhart C, et al. Triple-modality screening trial for familial breast cancer underlines the importance of magnetic resonance imaging and questions the role of mammography and ultrasound regardless of patient mutation status, age, and breast density. *J Clin Oncol* 2015;33:1128–1135.
- Bennani-Baiti B, Bennani-Baiti N, Baltzer PA. Diagnostic performance of breast magnetic resonance imaging in non-calcified equivocal breast findings: results from a systematic review and meta-analysis. *PLoS One* 2016;11:e0160346.
- Clauser P, Mann R, Athanasiou A, et al. A survey by the European Society of Breast Imaging on the utilisation of breast MRI in clinical practice. *Eur Radiol* 2018;28:1909–1918.
- Kuhl CK, Träber F, Schild HH. Whole-body high-field-strength (3.0-T) MR imaging in clinical practice. Part I. Technical considerations and clinical applications. *Radiology* 2008;246:675–696.
- Hunt CH, Hartman RP, Hesley GK. Frequency and severity of adverse effects of iodinated and gadolinium contrast materials: retrospective review of 456,930 doses. *Am J Roentgenol* 2009;193:1124–1127.
- European Society of Urogenital Radiology [http://www.esur.org/guidelines/]
- Shen Y, Goerner FL, Snyder C, et al. T1 relaxivities of gadolinium-based magnetic resonance contrast agents in human whole blood at 1.5, 3, and 7 T. *Invest Radiol* 2015;50:330–338.
- Giesel FL, von Tengg-Kobligh H, Wilkinson ID, et al. Influence of human serum albumin on longitudinal and transverse relaxation rates (r1 and r2) of magnetic resonance contrast agents. *Invest Radiol* 2006;41:222–228.
- Knopp MV, Bourne MW, Sardanelli F, et al. Gadobenate dimeglumine-enhanced MRI of the breast: analysis of dose response and comparison with gadopentetate dimeglumine. *AJR Am J Roentgenol* 2003;181:663–676.
- Pediconi F, Catalano C, Occhiato R, et al. Breast lesion detection and characterization at contrast-enhanced MR mammography: gadobenate dimeglumine versus gadopentetate dimeglumine. *Radiology* 2005;237:45–56.
- Pediconi F, Catalano C, Padula S, et al. Contrast-enhanced MR mammography: improved lesion detection and differentiation with gadobenate dimeglumine. *AJR Am J Roentgenol* 2008;191:1339–1346.
- Martincich L, Faivre-Pierret M, Zechmann CM, et al. Multicenter, double-blind, randomized, intraindividual crossover comparison of gadobenate dimeglumine and gadopentetate dimeglumine for Breast MR imaging (DETECT Trial). *Radiology* 2011;258:396–408.
- Gilbert FJ, van den Bosch HCM, Petrillo A, et al. Comparison of gadobenate dimeglumine-enhanced breast MRI and gadopentetate dimeglumine-enhanced breast MRI with mammography and ultrasound for the detection of breast cancer. *J Magn Reson Imaging* 2014;39:1272–1286.
- Bauner KU, Reiser MF, Huber AM. Low dose gadobenate dimeglumine for imaging of chronic myocardial infarction in comparison with standard dose gadopentetate dimeglumine. *Invest Radiol* 2009;44:95–104.
- Woodard PK, Chenevert TL, Sostman HD, et al. Signal quality of single dose gadobenate dimeglumine pulmonary MRA examinations exceeds quality of MRA performed with double dose gadopentetate dimeglumine. *Int J Cardiovasc Imaging* 2012;28:295–301.
- Vaneckova M, Herman M, Smith MP, et al. The benefits of high relaxivity for brain tumor imaging: results of a multicenter intraindividual crossover comparison of gadobenate dimeglumine with gadoterate meglumine (the BENEFIT Study). *AJNR Am J Neuroradiol* 2015;36:1589–1598.
- Crisi G, Filice S, Erb G, Bozzetti F. Effectiveness of a high relaxivity contrast agent administered at half dose in dynamic susceptibility contrast MRI of brain gliomas. *J Magn Reson Imaging JMRI* 2017;45:500–506.
- Filice S, Crisi G, Erb G. T2*-correction in dynamic contrast-enhanced magnetic resonance imaging of glioblastoma from a half dose of high-relaxivity contrast agent. *J Comput Assist Tomogr* 2017;41:916–921.
- Kanal E, Maravilla K, Rowley HA. Gadolinium contrast agents for CNS imaging: current concepts and clinical evidence. *Am J Neuroradiol* 2014;35:2215–2226.
- Seithe T, Braun J, Wolf M, et al. Diagnostic efficacy and safety of gadoteric acid MR mammography in 1537 patients. *Eur J Radiol* 2016;85:2281–2287.
- Sardanelli F, Boetes C, Borisch B, et al. Magnetic resonance imaging of the breast: recommendations from the EUSOMA working group. *Eur J Cancer Oxf Engl* 1990;26:1296–1316.
- Li Y, Li X, Li D, et al. Multicenter, intraindividual comparison of single-dose gadobenate dimeglumine and double-dose gadopentetate dimeglumine for MR angiography of the supra-aortic arteries (the Supra-Aortic VALUE study). *AJNR Am J Neuroradiol* 2013;34:847–854.
- Khouri Chalouhi K, Papini GDE, Bandirali M, Sconfienza LM, Di Leo G, Sardanelli F. Less is better? Intraindividual and interindividual comparison between 0.075 mmol/kg of gadobenate dimeglumine and 0.1 mmol/kg of gadoterate meglumine for cranial MRI. *Eur J Radiol* 2014;83:1245–1249.
- Mann RM, Kuhl CK, Kinkel K, Boetes C. Breast MRI: guidelines from the European Society of Breast Imaging. *Eur Radiol* 2008;18:1307–1318.
- Morris EA, Comstock C, Lee C, et al. ACR BI-RADS® Magnetic Resonance Imaging. In: *ACR BI-RADS® Atlas, Breast Imaging Reporting and Data System*. Reston, VA, American College of Radiology; 2013.
- Obuchowski NA, Mazzone PJ, Dachman AH. Bias, underestimation of risk, and loss of statistical power in patient-level analyses of lesion detection. *Eur Radiol* 2010;20:584–594.
- Pediconi F, Kubik-Huch R, Chilla B, Schwenke C, Kinkel K. Intra-individual randomised comparison of gadobutrol 1.0 M versus gadobenate dimeglumine 0.5 M in patients scheduled for preoperative breast MRI. *Eur Radiol* 2013;23:84–92.
- Gulani V, Calamante F, Shellock FG, Kanal E, Reeder SB, International Society for Magnetic Resonance in Medicine. Gadolinium deposition in the brain: summary of evidence and recommendations. *Lancet Neurol* 2017;16:564–570.
- Murata N, Gonzalez-Cuyar LF, Murata K, et al. Macrocyclic and other non-group 1 gadolinium contrast agents deposit low levels of gadolinium in brain and bone tissue: preliminary results from 9 patients with normal renal function. *Invest Radiol* 2016;51:447–453.
- Welk B, McArthur E, Morrow SA, et al. Association between gadolinium contrast exposure and the risk of parkinsonism. *JAMA* 2016;316:96–98.
- Pullicino R, Radon M, Biswas S, Bhojak M, Das K. A review of the current evidence on gadolinium deposition in the brain. *Clin Neuroradiol* 2018;28:159–169.
- Abbreviated Breast MRI and Digital Tomosynthesis Mammography in Screening Women With Dense Breasts, Full Text View. *ClinicalTrials.gov* [https://clinicaltrials.gov/ct2/show/NCT02933489?term=ACRIN&cond=Breast+Cancer+Female&cntry1=NA%3AUS&rank=2]