



Targeting SLMAP-ALK—a novel gene fusion in lung adenocarcinoma

Carlos Pagan, Subit Barua, Susan J. Hsiao, Mahesh Mansukhani, Anjali Saqi, Vundavalli Murty, and Helen Fernandes

Laboratory of Personalized Genomic Medicine, Department of Pathology and Cell Biology, Columbia University Medical Center, New York, New York 10032, USA

Abstract Assessment of *ALK* gene rearrangements is strongly recommended by the Molecular Testing Guideline for Selection of Lung Cancer Patients proposed by IASLC, AMP, and CAP at the time of diagnosis for patients with advanced stage disease. Non-small-cell lung cancer (NSCLC) with *ALK* gene rearrangements or the resulting fusion proteins have been, for the most part, successfully targeted with *ALK* tyrosine kinase inhibitors (TKIs). The most frequent rearrangement, the *EML4-ALK* oncogenic fusion, has more than 10 distinct variants, each with a discrete breakpoint in *EML4*. Recent studies have suggested that *EML4-ALK* variants may have differential responses to TKIs. Additionally, non-*EML4-ALK* fusions that result from *ALK* rearrangements with diverse 5' partners could possibly have varied biologic and clinical implications in their therapeutic responses and outcomes of patients with NSCLC. Existing literature documents at least 20 non-*EML4* fusion partners for *ALK*, and the clinical responsiveness to crizotinib ranges from increased sensitivity to resistance. This underscores the importance of identifying the precise 5' fusion partner to *ALK* before initiation of therapy. Herein we report the identification of a novel *SLMAP-ALK* fusion in a patient with NSCLC.

[Supplemental material is available for this article.]

CASE PRESENTATION

Corresponding author:
hf2340@cumc.columbia.edu

© 2019 Pagan et al. This article is distributed under the terms of the Creative Commons Attribution-NonCommercial License, which permits reuse and redistribution, except for commercial purposes, provided that the original author and source are credited.

Ontology term: lung adenocarcinoma

Published by Cold Spring Harbor Laboratory Press

doi:10.1101/mcs.a003939

A 73-yr-old man, a former smoker, was found to have a right lower lobe spiculated mass with adjacent peribronchovascular soft tissue thickening (Fig. 1A) that was noted incidentally on MRI of his abdomen to monitor a previously diagnosed pancreatic intraductal papillary mucinous neoplasm. Subsequent PET CT showed a large, FDG-avid mass in the right lower lobe measuring 4.1 cm in its greatest dimension and no evidence of metastatic lesions.

The patient then underwent video-assisted thoracoscopic surgery (VATS) resection of the right lower lobe with lymph node resection. Surgical resection showed pathology of a stage IIA (pT2bN1) lung adenocarcinoma, measuring 6.0 cm, acinar predominant with papillary and micropapillary features (Fig. 1B). One lobar lymph node was positive for metastatic carcinoma, and one lymph node was involved by direct extension of tumor. *ALK* D5F3 clone immunohistochemistry (IHC) was performed on the lung specimen and showed diffuse granular cytoplasmic staining (Fig. 1C). The tumor was negative for p40 and focally positive for TTF-1 by IHC.

An *ALK* rearrangement detected using Anchored Multiplex PCR (AMP) technology was confirmed by fluorescence in situ hybridization (FISH) with the *ALK* (2p23) break-apart probe (Fig. 1D). The patient was started on adjuvant chemotherapy: cisplatin and pemetrexed for four cycles. RNA analysis was performed on formalin-fixed paraffin-embedded (FFPE) tissue

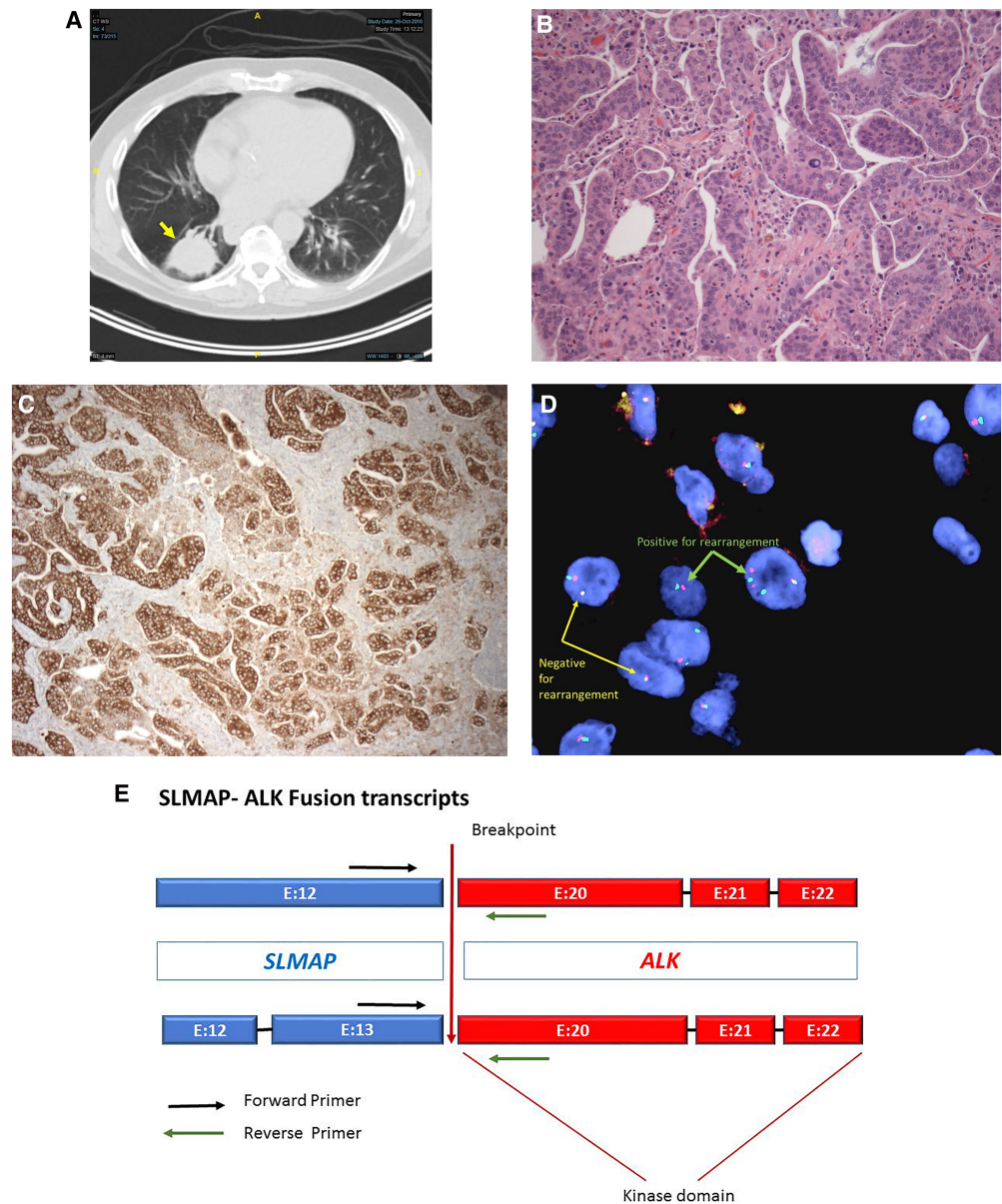


Figure 1. (A) CT image showing a right lower lobe spiculated lung mass with soft tissue thickening (arrow). (B) Hematoxylin and eosin (H&E)-stained tissue showing lung adenocarcinoma, acinar predominant with papillary and micropapillary features. (C) Immunostaining for ALK D5F3 with strong granular cytoplasmic staining. (D) Positive fluorescence with ALK break-apart probe is represented with split red and green signals. Cells negative for the rearrangement show fused yellow signal. (E) Novel SLMAP-ALK fusions with two different breakpoints in SLMAP, yielding two transcripts (E12:E20 SLMAP-ALK and E13:E20 SLMAP-ALK) fused with the canonical breakpoint (exon 20) of the ALK gene. (Figure and legend continue on following page.)

and revealed a novel fusion of *SLMAP* and *ALK*. Two different breakpoints in *SLMAP*, yielding two transcripts (exon 11 and exon 12) were fused with the canonical *ALK* breakpoint (exon 20), retaining the tyrosine kinase domain (Childress et al. 2018). After chemotherapy the patient was enrolled in a clinical trial (ALCHEMIST) and received treatment with crizotinib. Clinical and radiological follow-up has shown no evidence of recurrent or metastatic disease more than 2 yr after surgery.

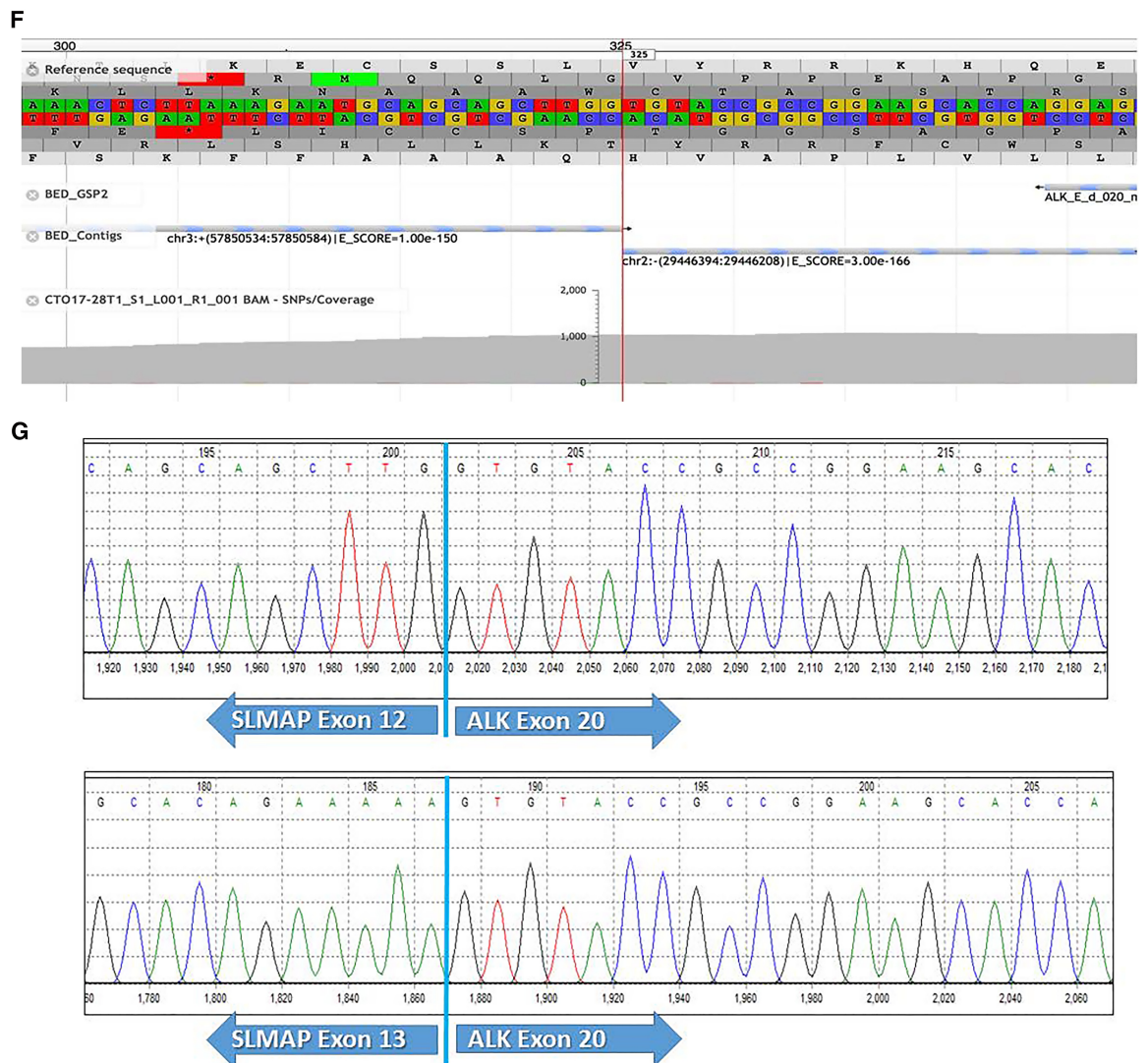


Figure 1. (Continued.) (F) JBrowse view of the SLMAP-ALK fusion. (G) Electropherogram from Sanger sequencing showing both SLMAP-ALK transcripts with the junctional sequence. Primers used are in Supplemental Table S1.

TECHNICAL ANALYSIS

DNA extraction from FFPE resection tissue was performed following the manufacturer's protocol using DNeasy Tissue kit on the QIAcube (QIAGEN). The extracted DNA was subjected to library preparation and targeted next-generation sequencing (NGS) using the TruSeq Amplicon—Cancer Panel on the MiSeq (illumina). Variant analysis was performed with the NextGENe software v2.4 (SoftGenetics, LLC).

RNA from the same FFPE resection tissue was extracted using the ALLPrep DNA/RNA kit (QIAGEN). RNA fusions were detected with a custom panel targeting 17 genes involved in cancer, using Archer's Anchored Multiplex PCR (AMP) NGS-based technology (ArcherDx). Briefly, after preparation of cDNA with random priming, the library is subject to a cDNA

quality check using a quantitative PCR (qPCR) assay that uses SYBR green to quantify fragments available for downstream amplification and library preparation. AMP chemistry then uses molecular barcodes along with universal primer binding sites to ligate with the double-stranded cDNA library for selection of fragments with known and novel fusion partners. Subsequent annealing with gene-specific primers that target the 17 genes in the fusion panel leads to PCR amplification of the fusion product. The resulting NGS library is sequenced on the MiSeq. Identification of fusion transcripts, exons, and breakpoints was performed with the Archer Analysis software v5.1.2 (ArcherDx). Novel fusions detected were confirmed by rt-PCR and Sanger sequencing of the product using BigDye Terminators on the ABI3130 (Thermo Fisher Scientific).

ALK IHC was performed with ALK D3F5 Ventana CDx Assay (Roche Diagnostics GmbH) and FISH, using an ALK (2p23) break-apart probe (Abbott Molecular).

GENOMIC ANALYSIS

A novel ALK fusion was identified in the RNA that was analyzed using AMP technology. The transcript (Table 1; Fig. 1E) demonstrated a 5' *SLMAP* fusion with 3' *ALK*. Details of the breakpoints showed that there were likely two isoforms of the fusion—E12:E20 *SLMAP*-*ALK* and E13:E20 *SLMAP*-*ALK*. Both isoforms were in-frame and exceeded the quality control requirements for a confident fusion call. These included a minimum of three start sites, five reads spanning the junction and 10% of total reads (#/%) as indicated in Figure 1E. The E12:E20 *SLMAP*-*ALK* fusion was clearly seen in the JBrowse viewer (Fig. 1F). Exon-specific primers that were selected and synthesized were able to correctly identify and confirm the fusion junctions of both—E12:E20 *SLMAP*-*ALK* and E13:E20 *SLMAP*-*ALK*—isoforms (Fig. 1G). No clinically relevant DNA variants were detected in the genes targeted by the TruSeq Amplicon—Cancer NGS Panel.

VARIANT INTERPRETATION

Molecular testing is critical in the management of advanced lung cancer. Prior knowledge of the *ALK* fusion partner has an impact on the efficacy of ALK TKIs. In vitro studies have suggested that different *EML4*-*ALK* fusion transcripts show varied susceptibility to crizotinib (Heukman et al. 2012). Yoshida et al. (2016) have further documented differential clinical impact of *ALK* fusion variants to crizotinib in patients. Some partners lead to primary resistance to crizotinib, and some partners might predict efficacy of ALK TKIs other than *EML4* in

Table 1. Details for the two fusion transcripts found in the patient

Gene 1	Gene 2	Position 1	Position 2	Exon #1	Transcript #1	Exon #2	Transcript #2	Fusion sequence	Number of supporting reads
<i>SLMAP</i>	<i>ALK</i>	Chr 3: 57850583	Chr 2: 29446394	11	NM_001304420.2	20	NM_004304.4	GAGAAACTCTTAAA GAATGCAGCAGCTTG tgtaccgccggaagcaccag gagctgcaagc	607
<i>SLMAP</i>	<i>ALK</i>	Chr 3: 57851019	Chr 2: 29446394	12	NM_001304420.2	20	NM_004304.4	TTACCTAAAATAAATG GGAGCACAGAAAAAG tgtaccgccggaagcaccag gagctgcaagc	344

advanced ALK-positive NSCLCs (Kang et al. 2018). Guidelines for ALK testing recommend testing and include either ALK IHC or FISH. However, these methods do not identify or distinguish from any of the many ALK partners. The AMP technology is able to detect novel RNA fusions in tumors. To the best of our knowledge, this is the first time a fusion of *SLMAP* and ALK has been reported in a solid or hematologic malignancy.

Patients with ALK fusion positive lung adenocarcinoma are generally younger and have either none or a light smoking history. These lung tumors have also been reported to more frequently show signet ring cell morphology (Pareja et al. 2015). This patient's age, smoking history, and presence of papillary/micropapillary patterns are notable and support guidelines to routine testing for ALK fusions (Lindeman et al. 2018). Although patients with EML4-ALK fusions are likely to benefit from ALK inhibitor therapy, the response of other ALK fusion oncoproteins remains to be investigated.

SLMAP encodes a striatin-interacting phosphatase and kinase (STRIPAK) complex with roles in cell signaling, cell cycle control, cell migration, Golgi assembly, and apoptosis. Missense mutations in *SLMAP* have been associated with the pathophysiology of diabetes and Brugada syndrome (Ishikawa et al. 2012; Upadhyay et al. 2015). Although *SLMAP* is not considered an oncogene, growing evidence correlates dysregulation of STRIPAK complexes with human diseases including cancer (Shi et al. 2016). As the genomic landscape expands, documentation of structural variants in which new and novel genes that associate with known drivers are responsive to targeted therapy is essential for patient care.

SUMMARY

This is a case of a 73-yr-old former smoker who had a lung adenocarcinoma that was positive by ALK IHC and FISH. NGS testing on the RNA revealed a *SLMAP*-ALK fusion. The patient has been free of recurrence and/or metastatic disease for 2 yr. Identification of new and novel fusions with appropriate NGS technologies can provide further biological and clinical insights into ALK-positive lung cancer. It is also helpful in understanding the variable responses to ALK-targeted therapies in patients with NSCLC. Identification of ALK fusion partners, using NGS, before initiation of therapy, may result in more effective patient management.

ADDITIONAL INFORMATION

Data Deposition and Access

The variant for this case was deposited into ClinVar (<https://www.ncbi.nlm.nih.gov/clinvar/>) under accession number SCV000902410.

Ethics Statement

This study was conducted with approval from the Columbia University Medical Center Institutional Review Board (IRB) under protocol number AAAD7936.

Competing Interest Statement

The authors have declared no competing interest.

Received January 4, 2019;
accepted in revised form
March 8, 2019.

Author Contributions

H.F., C.P., and S.B. designed the study and performed the analysis. H.F., V.M., S.J.H., and M.M. analyzed the data. C.P. and A.S. reviewed pathology slides and collected pathology data. H.F. and C.P. collected the clinical data. C.P. and H.F. wrote the manuscript in consultation with the other authors.

REFERENCES

- Childress MA, Himmelberg SM, Chen H, Deng W, Davies M, Lovly CM. 2018. ALK fusion partners impact response to ALK inhibition: differential effects on sensitivity, cellular phenotypes, and biochemical properties. *Mol Cancer Res* **16**: 1724–1736. doi:10.1158/1541-7786.MCR-18-0171
- Heukman JM, Balke-Want H, Malchers F, Peifer M, Sos ML, Koker M, Meder L, Lovly CM, Heukamp LC, Pao W, et al. 2012. Differential protein stability and ALK inhibitor sensitivity of EML4_ALK fusion variants. *Clin Cancer Res* **18**: 4682–4690. doi:10.1158/1078-0432.CCR-11-3260
- Ishikawa T, Sato A, Marcou CA, Tester DJ, Ackerman MJ, Crotti L, Schwartz PJ, On YK, Park JE, Nakamura K, et al. 2012. A novel disease gene for Brugada syndrome: sarcolemmal membrane-associated protein gene mutations impair intracellular trafficking of hNav1.5. *Circ Arrhythm Electrophysiol* **5**: 1098–1107. doi:10.1161/CIRCEP.111.969972
- Kang J, Zhang X, Chen H, Zhou Q, Tu H, Li WF, Wu YL, Yang J. 2018. Uncommon ALK fusion partners in advanced ALK-positive non-small-cell lung cancer. *J Clin Oncol* **36**: 8561. doi:10.1200/JCO.2018.36.15_suppl.8561
- Lindeman NI, Cagle PT, Aisner DL, Arcila ME, Beasley MB, Bernicker EH, Colasacco C, Dacic S, Hirsch FR, Kerr K, et al. 2018. Updated molecular testing guideline for the selection of lung cancer patients for treatment with targeted tyrosine kinase inhibitors: Guideline from the College of American Pathologists, the International Association for the Study of Lung Cancer, and the Association for Molecular Pathology. *Arch Pathol Lab Med* **142**: 321–346. doi:10.5858/arpa.2017-0388-CP
- Pareja F, Crapanzano JP, Mansukhani MM, Bulman W, Saqi A. 2015. Cytomorphological features of ALK-positive lung adenocarcinomas: psammoma bodies and signet ring cells. *Cancer Cytopathol* **123**: 162–170. doi:10.1002/cncy.21507
- Shi Z, Jiao S, Zhou Z. 2016. STRIPAK complexes in cell signaling and cancer. *Oncogene* **35**: 4549–4557. doi:10.1038/onc.2016.9
- Upadhyay R, Robay A, Fakhro K, Abi Khalil C, Zirie M, Jayyousi A, El-Shafei M, Kiss S, D'Amico DJ, Salit J, et al. 2015. Role of SLMAP genetic variants in susceptibility of diabetes and diabetic retinopathy in Qatari population. *J Transl Med* **13**: 61. doi:10.1186/s12967-015-0411-6
- Yoshida T, Oya Y, Tanaka K, Shimizu J, Horio Y, Kuroda H, Sakao Y, Hida T, Yatabe Y. 2016. Differential crizotinib response duration among ALK fusion variants in ALK-positive non-small-cell lung cancer. *J Clin Oncol* **34**: 3383–3389. doi:10.1200/JCO.2015.65.8732



Targeting SLMAP-ALK—a novel gene fusion in lung adenocarcinoma

Carlos Pagan, Subit Barua, Susan J. Hsiao, et al.

Cold Spring Harb Mol Case Stud 2019, **5**: a003939

Access the most recent version at doi:[10.1101/mcs.a003939](https://doi.org/10.1101/mcs.a003939)

Supplementary Material	http://molecularcasestudies.cshlp.org/content/suppl/2019/05/29/mcs.a003939.DC1
References	This article cites 9 articles, 4 of which can be accessed free at: http://molecularcasestudies.cshlp.org/content/5/3/a003939.full.html#ref-list-1
License	This article is distributed under the terms of the Creative Commons Attribution-NonCommercial License, which permits reuse and redistribution, except for commercial purposes, provided that the original author and source are credited.
Email Alerting Service	Receive free email alerts when new articles cite this article - sign up in the box at the top right corner of the article or click here .
