

Combination Therapy of Interventional Radiology and Surgery for Infarction of the Small Intestine Caused by Portal Vein and Mesenteric Vein Thrombosis: A Patient Report

Takayoshi Kimura,* Satoru Murata,† Shiro Onozawa,† Takahiko Mine,† Tatsuo Ueda,† Fumie Sugihara,† Daisuke Yasui,† Izumi Miki,† Shinichiro Kumita† and Toshihide Ogawa*

*Division of Radiology, Department of Pathophysiological and Therapeutic Science, School of Medicine, Tottori University Faculty of Medicine, Yonago 683-8503, Japan and †Department of Radiology, Nippon Medical School, Tokyo 113-8603, Japan

ABSTRACT

We report the case of a man in his 70s who suffered from intestinal infarction caused by acute portal vein and mesenteric vein thrombosis (PVMVT). Combination therapy with percutaneous transcatheter thrombectomy and surgical bowel resection was successfully performed, and a satisfactory outcome was achieved. Intestinal infarction caused by PVMVT can be fatal and has a high mortality rate even if surgical resection is performed. The combination therapy of interventional radiology and surgery might be a safe and effective method for patients with this life-threatening condition.

Key words interventional radiology; intestinal infarction; portal vein thrombosis; surgical resection

Acute portal vein and mesenteric vein thrombosis (PVMVT) is a rare and insidious disease that is associated with significant mortality and morbidity. Its clinical manifestations are often asymptomatic or nonspecific, such as nausea, anorexia, and abdominal distension. Thus, the diagnosis of PVMVT is frequently delayed, which can be fatal owing to complications such as mesenteric ischemia and infarction with multiorgan failure. In patients with PVMVT-related intestinal infarction, the mortality rate has been reported to be 37–76%.⁴ Therefore, early accurate diagnosis is very important. The traditional management of this condition has been anticoagulation therapy. Surgery is reserved for patients who have failed anticoagulation therapy or for those who present with signs of mesenteric ischemia and infarction. Due to recent advances in catheter-directed treatment, interventional radiology (IR) such as the percutaneous transhepatic technique has been recognized as an alternative, less invasive option with minimal complica-

tions.^{1–8} However, despite previous reports, a reliable therapeutic strategy for PVMVT-related with intestinal infarction is yet to be established.

We report here a case of PVMVT-related intestinal infarction that was successfully treated with a combination therapy of IR and surgical resection.

PATIENT REPORT

A man in his 70s with no significant medical history was hospitalized in the emergency department because of abdominal pain and bloody stool persisting for 4 days. On physical examination, abdominal rebound tenderness was found. Initial laboratory test results revealed a white blood cell count of 13100/μL and a C-reactive protein level of 2.41 mg/L. Abdominal enhanced computed tomography (CT) revealed extensive necrosis of the terminal ileum and continuous thrombus from the ileal branches via the superior mesenteric vein (SMV) to the main trunk of the portal vein (PV, Fig. 1). The condition was diagnosed as ileal necrosis due to venous thrombosis, and the combined treatment of IR and surgery was administered immediately.

First IR procedure: Under local anesthesia, using ultrasonographic guidance, percutaneous transhepatic access to the left portal vein was established and a 5-Fr vascular sheath was inserted. Direct portography revealed occlusion with extensive thrombosis from the ileal branches up to the main trunk of the PV. The thrombosed PV and SMV were passed through by a 0.035-inch guidewire, and catheter-directed thrombolysis was performed after injecting a high dose of urokinase (120000 units, Uronase; Mochida, Tokyo, Japan) via a pulse-spray catheter (Fountain; Merit Medical, South Jordan, UT; Figs. 2A and B).

Laparotomy: In the laparotomy performed immediately after the first IR procedure, infarction of the terminal ileum was recognized and approximately 50 cm of the small intestine was resected. Despite the presence of a large venous thrombus, surgical thrombectomy was not performed. At the completion of surgery, intravenous heparin infusion was maintained at the rate of 1000

Corresponding author: Takayoshi Kimura, MD

srkbc189@yahoo.co.jp

Received 2016 May 16

Accepted 2016 June 8

Abbreviations: CT, computed tomography; IR, interventional radiology; PVMVT, portal vein and mesenteric vein thrombosis; SMV, superior mesenteric vein

units per hour.

Second and third IR procedures: Transcatheter thrombectomy for the residual thrombus was performed on day 1 and 2 after the operation as the second and third IR procedure, respectively. Manual aspiration thrombectomy was performed using a 6-Fr guiding catheter (Launcher; Medtronic, Minneapolis, MN). Di-

rect thrombolysis was performed using 120000 units of urokinase. Angioplasty was performed using a balloon catheter of 8 mm diameter and 4 cm length (Mustang; Boston Scientific, Natick, MA). At the completion of IR therapy, urokinase administration (5000 units/hour) was continued for an additional 48 hours via the catheter placed in the SMV (Fig. 3).

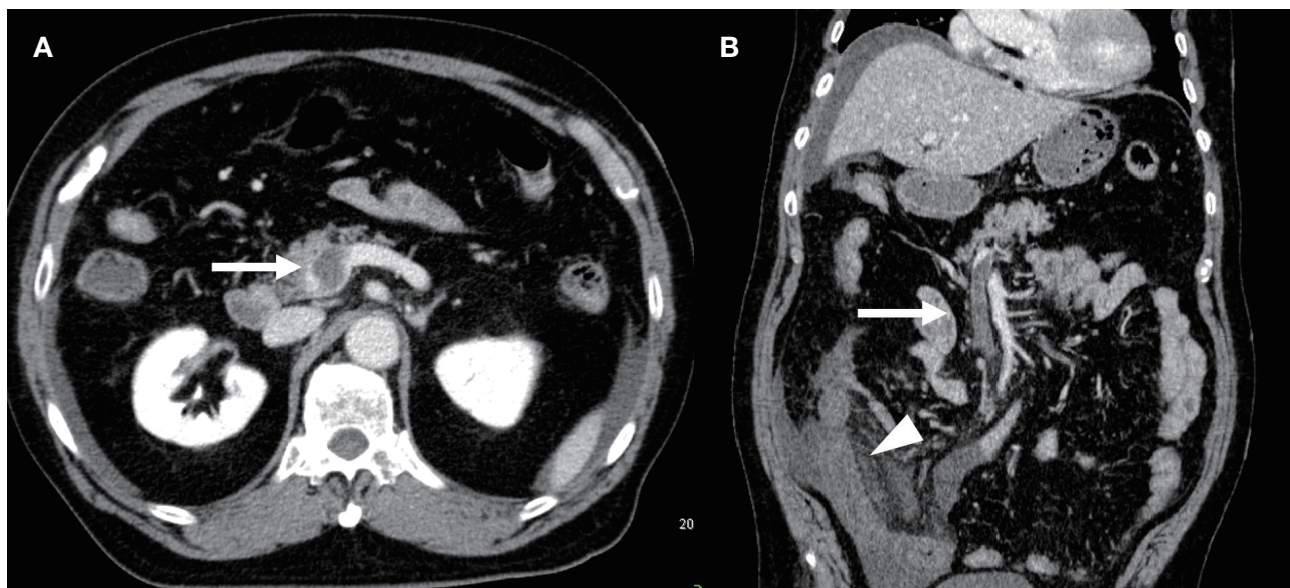


Fig. 1. First dynamic CT. (A) Initial CT shows intraluminal thrombosis in the PV and the mesenteric vein (arrow). (B) Jejunal loop dilatation and diffuse wall thickening with ascites are evident (arrow head). CT, computed tomography; PV, portal vein.

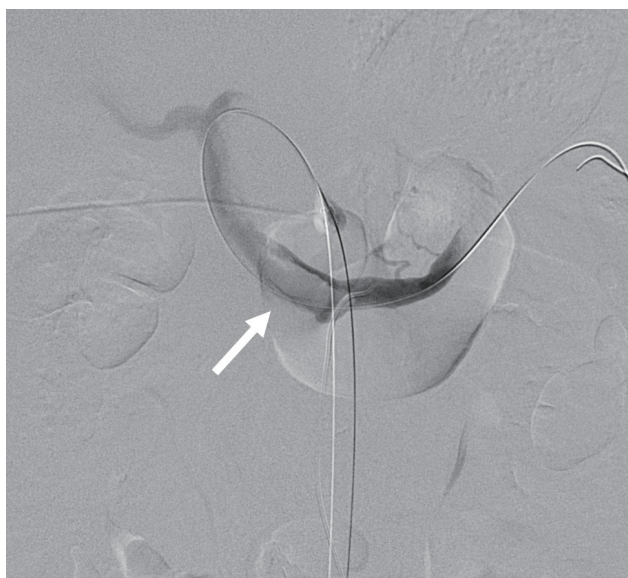

Fig. 2. Percutaneous transhepatic portography shows thrombus in the portal vein trunk (arrow) extending to the mesenteric vein.

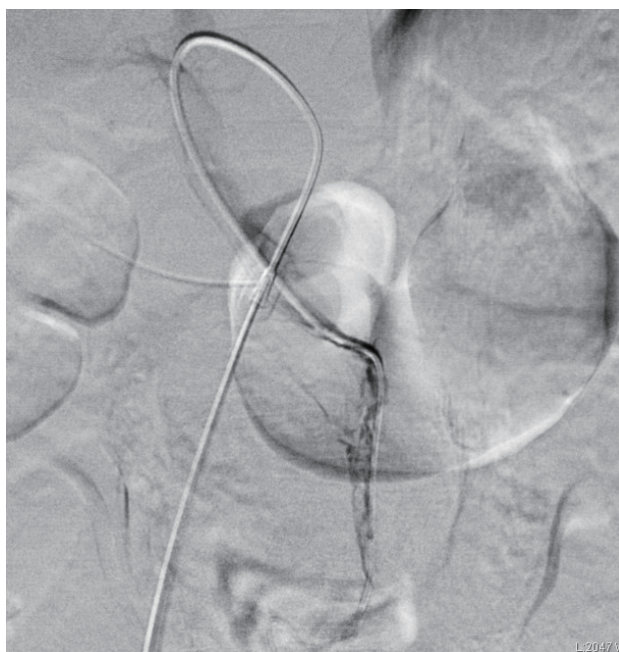


Fig. 3. Direct portography at the second and third IR sessions reveal residual thrombus in the PV and SMV. Percutaneous transhepatic thrombectomy, thrombolysis, and angioplasty were performed. IR, interventional radiology; PV, portal vein; SMV, superior mesenteric vein.

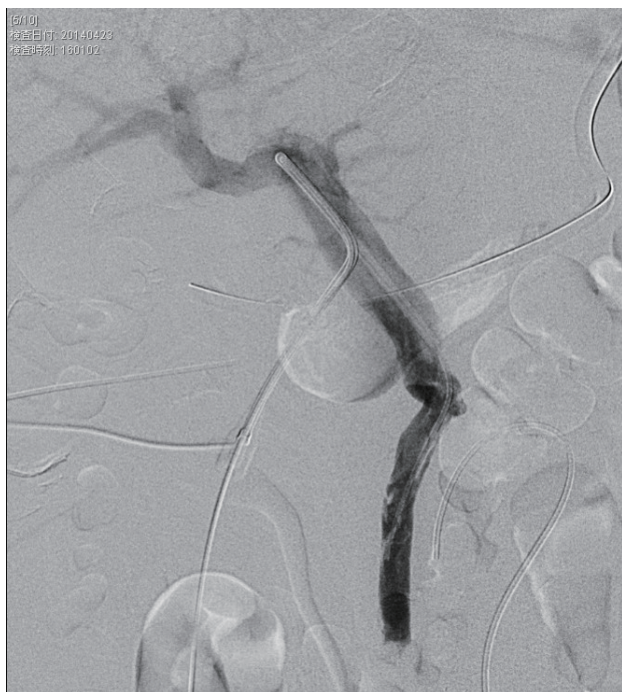

Fig. 4. Portography performed 4 days after IR procedure and surgery shows recanalization and antegrade hepatopetal flow in the SMV and PV. IR, interventional radiology; PV, portal vein; SMV, superior mesenteric vein.

Follow-up: Four days after the operation, sufficient blood flow and recanalization of the SMV and PV were confirmed by portography (Fig. 4). Follow-up CT performed 9 days after the first IR procedure revealed only a small amount of remnant thrombus in the SMV and PV (Fig. 5). No adverse event or complication occurred, and the patient was discharged on day 24 of hospitalization. He was followed up in the outpatient department with performing anticoagulant therapy using warfarin, and no complication was noted.

DISCUSSION

PVMVT is a relatively rare disease with an incidence of approximately 5–15% among mesenteric ischemic events.^{1,2} Myeloproliferative disease, intraabdominal infections or inflammations, septicemia, cirrhosis, intraabdominal surgery, trauma, hypercoagulable states (insufficiency of antithrombin III, protein C, protein S, etc.), oral contraceptives use, and liver tumors are the most common causes for PVMVT.³ However, our patient had none of these risk factors and the cause of thrombosis was not identified despite elaborate examinations.

The main goals of therapy for acute PVMVT are preventing extension of the thrombus, recanalization of the vessels in the short term, and preventing recurrence in the long term. Anticoagulation is the initial approach in

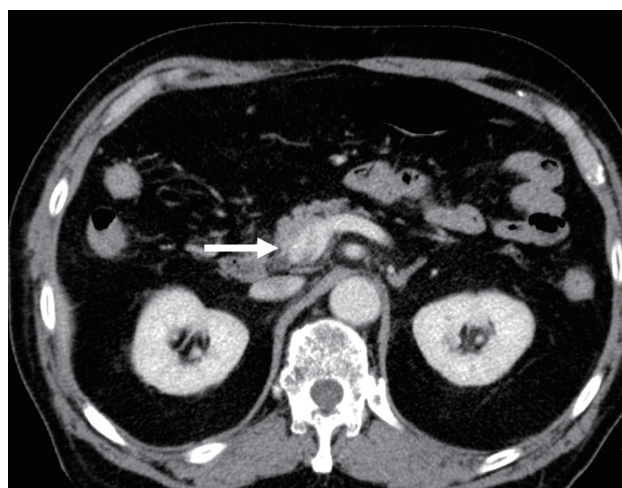


Fig. 5. Follow-up abdominal CT at day 10 after IR and surgery shows only a small amount of remnant thrombus in the PV and SMV (arrow). CT, computed tomography; IR, interventional radiology; PV, portal vein; SMV, superior mesenteric vein.

management. Acute PVMVT without bowel ischemia has traditionally been treated using systemic anticoagulation therapy with heparin and warfarin to prevent propagation of the thrombus and recanalize the occluded vessels. However, for patients with intestinal infarction, perforation, and peritonitis, emergency laparotomy with bowel resection may be essential and warranted for survival. Bowel resection and anastomosis are the standard procedures performed with the goal of conserving as much of the bowel as possible. In previous case series of PVMVT-related intestinal infarction, the average length of resected bowel has been 50–60 cm, which is as same as our base. Moreover, these series reported high mortality (37–76%) and high recurrence rates (11–29%).^{2,4,6,7} Here, we assumed that mortality and recurrence rate were associated with the volume of the resected intestine. Moreover, our patient had an extensive thrombosis extending from the ileal branches up to the main trunk of the PV. Hence, sufficient surgical thrombectomy was considered hazardous as it comes with a high risk of critical bleeding. Taking these factors into consideration, we employed an endovascular approach simultaneously with a surgical approach to recanalize the thrombosed vein considerably and reduce the volume of bowel resection.

Endovascular therapy for PVMVT has been recognized as a therapeutic alternative that is minimally invasive and has a relatively low mortality. In a retrospective study of 20 PVMVT patients with or without intestinal infarction who were treated with thrombolysis via the transhepatic route and/or superior mesenteric artery route, 75% experienced partial or complete clot reso-

lution and 85% experienced resolution of symptoms.⁸ The ratio of a bleeding complication is not so high as 0.06–15% in the previous reports.^{9–12} In the present case, we performed percutaneous transhepatic thrombolysis, thrombectomy, and angioplasty, which permits access to the PV and SMV system and thus allows for infusion of thrombolytic agents directly into the occluded vein with a limited amount of lytic agents and for longer durations.^{2,3} Using this method, recanalization from the ileal branch up to the PV was achieved safely, and adequate blood circulation was maintained without any adverse events. Moreover, the length of the resected intestine was limited to 50 cm, and thrombosis or bowel ischemia did not recur.

To the best of our knowledge, till date, no report has indicated the efficacy of combination therapy of IR and surgical resection for PVMVT-related intestinal infarction. Percutaneous transhepatic thrombolysis, thrombectomy, and angioplasty with surgical resection are valid strategies for recanalization, and they may be effective in reducing the mortality rate of patients with PVMVT-related intestinal infarction.

In conclusion, acute PVMVT-related intestinal infarction is a rare disease with high mortality; hence, early diagnosis and treatment are essential. We successfully saved this life-threatening case with the combination therapy of IR and surgical resection.

The authors declare no conflict of interest

REFERENCES

- 1 Kim HS, Patra A, Khan J, Arepally A, Streiff MB. Transhepatic catheter-directed thrombectomy and thrombolysis of acute superior mesenteric venous thrombosis. *J Vas Interv Radiol.* 2005;16:1685-91. PMID: 16371536.
- 2 Zhou W, Choi L, Lin PH, Dardik A, Eraso A, Lumsden AB. Percutaneous transhepatic Thrombectomy and pharmacologic thrombolysis of mesenteric venous thrombosis. *Vascular.* 2007;15:41-5. PMID: 17382054.
- 3 Ozkan U, Oguzkurt L, Tercan F, Tokmak N. Percutaneous transhepatic thrombolysis in the treatment of acute portal venous thrombosis. *Diagn Interv Radiol.* 2006;12:105-7. PMID: 16752359.
- 4 Jun KW, Kim MH, Park KM, Chun HJ, Hong KC, Jeon YS, Cho SG, Kim JY. Mechanical thrombectomy-assisted thrombolysis for acute symptomatic portal and superior mesenteric venous thrombosis. *Ann Surg Treat Res.* 2014;86:334-41. PMID: 24949327.
- 5 Adani GL, Baccarani U, Risaliti A, Sponza M, Gasparini D, Bresadola F, de Anna D, Bresadola V. Percutaneous transhepatic portography for the treatment of early portal vein thrombosis after surgery. *Cardiovasc Intervent Radiol.* 2007;30:1222-6. PMID: 17573552.
- 6 Ludwig DJ, Hauptmann E, Rosoff L Jr, Neuzil D. Mesenteric and portal vein thrombosis in a young patient with protein S deficiency treated with urokinase via the superior mesenteric artery. *J Vasc Surg.* 1999;30:551-4. PMID: 10477649.
- 7 Jun KW, Kim MH, Park KM, Chun HJ, Hong KC, Jeon YS, Cho SG, Kim JY. Mechanical thrombectomy-assisted thrombolysis for acute symptomatic portal and superior mesenteric venous thrombosis. *Ann Surg Treat Res.* 2014;86:334-41. PMID: 24949327.
- 8 Hollingshead M, Burke CT, Mauro MA, Weeks SM, Dixon RG, Jaques PF. Transcatheter thrombolytic therapy for acute mesenteric and portal vein thrombosis. *J Vasc Interv Radiol.* 2005;16:651-61. PMID: 15872320.
- 9 Ouriel K, Gray B, Clair DG, Olin J. Complications associated with the use of urokinase and recombinant tissue plasminogen activator for catheter-directed peripheral arterial and venous thrombolysis. *J Vasc Interv Radiol* 2000;11:295-8. PMID: 10735422.
- 10 Schäfer C, Zundler J, Bode JC. Thrombolytic therapy in patients with portal vein thrombosis: case report and review of the literature. *Eur J Gastroenterol Hepatol* 2000;12:1141-5. PMID: 11057461.
- 11 Parikh S, Shah R, Kapoor P. Portal vein thrombosis. *Am J Med.* 2010;123:111-9. PMID: 20103016.
- 12 Singal AK, Kamath PS, Tefferi A. Mesenteric venous thrombosis. *Mayo Clin Proc.* 2013;88:285-94. PMID: 23489453.