

## Associations between Systemic Markers of Bone Turnover or Bone Mineral Density and Anti-Resorptive Agent-Related Osteonecrosis of the Jaw in Patients Treated with Anti-Resorptive Agents

Kazuhiro Tohashi,\* Motoki Nakabayashi,\*† Isamu Kodani,\* Kazunori Kidani‡ and Kazuo Ryoke\*

\*Division of Oral and Maxillofacial Biopathological Surgery, Department of Medicine of Sensory and Motor Organs, School of Medicine, Tottori University Faculty of Medicine, Yonago 683-8504, Japan, †Department of Oral and Maxillofacial Surgery, Matsue Red Cross Hospital, Matsue 690-8506, Japan and ‡Department of Dentistry and Oral Surgery, Tottori Prefectural Central Hospital, Tottori 680-0901, Japan

### ABSTRACT

**Background** Some previous studies have examined anti-resorptive agent-related osteonecrosis of the jaw (ARONJ) prediction using systemic markers of bone turnover as risk factors. Radiographic imaging is also effective at detecting ARONJ. In this study, computed tomography (CT)-derived bone mineral density (BMD) values and the levels of systemic markers of bone turnover were evaluated, and then each parameter was compared between patients that developed ARONJ and those who did not after treatment with systemic anti-resorptive agents. The aim of this study was to determine whether systemic markers of bone turnover and/or BMD values can be used to predict the risk of ARONJ.

**Methods** The subjects' serum levels of cross-linked N-terminal telopeptide of type I collagen (NTX) and bone alkaline phosphatase (BAP) (systemic markers of bone turnover) were measured. BMD was calibrated to CT values using a medical imaging phantom. Then, the subjects' BMD were assessed using quantitative computed tomography. Fifty-six patients who had received systemic anti-resorptive agents were included in this study. Thirty-two of the patients developed ARONJ after receiving the drugs whereas the remaining 24 did not.

**Results** No correlation was observed between the serum levels of the systemic markers of bone turnover and the incidence of ARONJ. On the other hand, the ARONJ

patients exhibited higher mandibular BMD values than the control group. BMD was not associated with healing or the clinical stage of ARONJ.

**Conclusion** These results suggest that increased mandibular BMD values are associated with ARONJ. Furthermore, mandibular BMD might serve as a novel marker for predicting the risk of ARONJ in patients that are taking anti-resorptive agents and are about to undergo tooth extraction. Accordingly, mandibular BMD could be a useful tool for aiding risk assessments and guiding treatment decisions.

**Key words** anti-resorptive agent-related osteonecrosis of the jaw; bone mineral density; quantitative computed tomography; systemic markers of bone turnover

Bisphosphonates are potent inhibitors of osteoclast activity<sup>1–3</sup> and are widely used in the clinical setting to inhibit osteoclast activity in malignant and benign disorders that are characterized by excessive bone resorption, such as tumor-induced osteolysis and osteoporosis.<sup>4–15</sup> Worldwide, more than 200 million patients with common bone disorders are currently being treated with anti-resorptive agents.<sup>16</sup> However, the long-term administration of bisphosphonates adversely affects bone quality and metabolism. Since the first report of 3 cases of bisphosphonate-related osteonecrosis of the jaw (BRONJ) was published in 2003,<sup>17</sup> a growing number of studies have examined the condition.<sup>18–22</sup> In recent years, denosumab, an anti-resorptive agent with a novel mechanism of action, has been developed, and several reports have been published on osteomyelitis and/or necrosis of the jaw associated with the use of denosumab.<sup>23–25</sup> The receptor activator of nuclear factor κB ligand (RANKL) inhibitor is a fully humanized antibody against RANKL that acts as an anti-resorptive agent and inhibits osteoclast activity and the associated bone resorption. Due to the development of such drugs, the term BRONJ was changed to anti-resorptive agent-related osteonecrosis of the jaw (ARONJ), which encompasses the adverse effects of

Corresponding author: Motoki Nakabayashi, DDS, PhD  
nakabayashi\_motoki@matsue.jrc.or.jp

Received 2015 December 7

Accepted 2015 December 21

Abbreviations: AAOMS, American Association of Oral and Maxillofacial Surgeons; ARONJ, anti-resorptive agent-related osteonecrosis of the jaw; BAP, bone alkaline phosphatase; BCE, bone collagen equivalents; BMD, bone mineral density; BRONJ, bisphosphonate-related osteonecrosis of the jaw; CT, computed tomography; DICOM, Digital Imaging and Communications in Medicine; NTX, cross-linked N-terminal telopeptide of type I collagen; QCT, quantitative computed tomography; RANKL, receptor activator of nuclear factor kappa-B ligand; ROI, regions of interest

other anti-resorptive agents. There have been a number of studies on the incidence of ARONJ, but no consensus has been reached.<sup>18, 21, 26</sup> ARONJ is extremely intractable. In addition, there are no established therapies for the condition. Therefore, the prevention and early diagnosis of ARONJ are very important.

The use of anti-resorptive agents significantly reduces the risk of fractures and skeletal-related troubles. In addition, it increases the bone mineral density (BMD) of the lumbar vertebra, etc.<sup>27</sup> Systemic markers of bone turnover can provide clinically useful evidence of reflect bone cell activity in the skeleton during medical treatment. Such markers have gained widespread acceptance and are routinely used in the clinical setting. However, they are not currently employed in dentistry.

Although various radiological studies of ARONJ have been published, patients who had been administered anti-resorptive agents did not exhibit consistent radiological jaws changes. Thus, imaging tools that could aid the detection of bone changes associated with anti-resorptive agents are required.

In this study, computed tomography (CT)-derived BMD values and the levels of systemic markers of bone turnover were evaluated, and then each parameter was compared between patients that developed ARONJ and those who did not after treatment with systemic anti-resorptive agents.

## MATERIALS AND METHODS

### Patients

This present study was performed with patients who were referred to the Division of Oral and Maxillofacial Biopathological Surgery, Tottori University Faculty of Medicine from March 2008 to August 2014. The study group consisted of 32 patients who had been receiving anti-resorptive agents (administered intravenously and orally in 13 and 19 cases, respectively), had undergone a CT scan of their mandible and had a blood test at the first medical examination with or without developing ARONJ. ARONJ was diagnosed according to the criteria proposed by The American Association of Oral and Maxillofacial Surgeons (AAOMS) and the American Society for Bone and Mineral Research<sup>28</sup>: i) current or previous treatment with anti-resorptive agents; ii) exposed bone or bone that could be probed through an intraoral or extraoral fistula in the maxillofacial region that had persisted for more than 8 weeks and iii) no history of radiotherapy involving the jaws or obvious metastasis to the jaws. The criteria between the healing and non-healing groups were decided by the response from patients with conservative treatments such as antibiotic medication, irrigation and/or extirpation of separated

sequester.

The control group consisted of 24 patients who had a history of treatment with anti-resorptive agents, had never developed mandibular lesions or ARONJ, and had undergone a CT scan and blood sampling of their mandible prior to tooth extraction. In the control group, tooth extraction was clinically necessary in all subjects. Approval for the study was obtained from the institutional review board of the Faculty of Medicine, Tottori University.

### Staging categories

ARONJ was staged according to the 2007 AAOMS guidelines<sup>29</sup>:

Stage 1: Exposed/necrotic bone in patients who are asymptomatic and have no evidence of infection.

Stage 2: Exposed/necrotic bone in patients with pain and clinical evidence of infection.

Stage 3: Exposed/necrotic bone in patients with pain; infection; and one or more of the following: a pathological fracture, extraoral fistula, or osteolysis extending to the inferior border.

### Blood collection and measurement of systemic markers of bone turnover

We collected blood samples from each patient and measured the blood levels of cross-linked N-terminal telopeptide of type I collagen (NTX) and bone alkaline phosphatase (BAP).

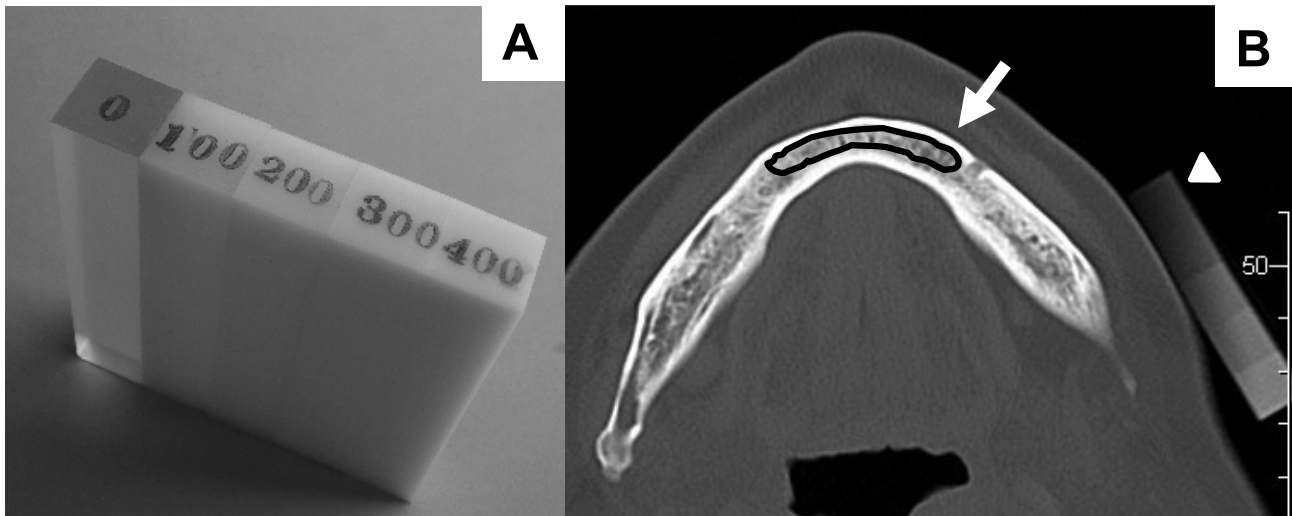
### CT and bone mineral density measurements

CT images were obtained using an Aquilion64 64-slice spiral CT scanner (Toshiba, Tokyo, Japan). A medical imaging phantom (Kyoto Kagaku, Kyoto, Japan) was employed during the CT imaging (Fig. 1A). The resultant Digital Imaging and Communications in Medicine (DICOM) data were evaluated with ImageJ (National Institute of Health, Bethesda, MD). BMD was measured using quantitative computed tomography (QCT). Regions of interest (ROI) were drawn on axial images that passed through the mental foramen (Fig. 1B). The ROI were drawn so that they only included spongiotic bone. In order to exclude soft tissue, bone was defined as tissue that exhibited attenuation values of  $\geq 300$  Hounsfield units.

### Statistical analysis

Statistical analyses were performed using Excel 2010 (Microsoft, Redmond, WA).

The correlation between control, ARONJ (healing) and ARONJ (non-healing) groups was calculated using the Tukey-Kramer test or Steel-Dwass test. Student's *t*-



**Fig. 1.** Use of the calibration phantom.

**A:** Photograph showing the calibration phantom. **B:** ROI (arrow) were drawn on an axial image passing through the mental foramen. The ROI were drawn so that they only included spongiosal bone. CT image showing the calibration phantom (arrowhead). CT, computed tomography; ROI, regions of interest.

**Table 1. Characteristics of the 32 patients with ARONJ and the 24 control patients**

		Control ( <i>n</i> = 24)	ARONJ ( <i>n</i> = 32)	
			Healing ( <i>n</i> = 15)	No healing ( <i>n</i> = 17)
Gender	Male	1	3	8
	Female	23	12	9
Mean age		67.6 y (48–83 y)	75.1 y (61–93 y)	69.0 y (40–80 y)
Disease	Bony metastasis	2	1	11
	Osteoporosis	20	12	3
	Multiple myeloma	0	1	1
	Other	2	1	2
Administration method	Intravenous	2	2	11
	Oral	22	13	6
Type of drug	Bisphosphonate	24	15	16
	Denosumab	0	0	1

ARONJ, anti-resorptive agent-related osteonecrosis of the jaw; y, year(s).

test was used for comparisons between pairs of categorical variables. *P*-values of < 0.05 were considered to be statistically significant.

## RESULTS

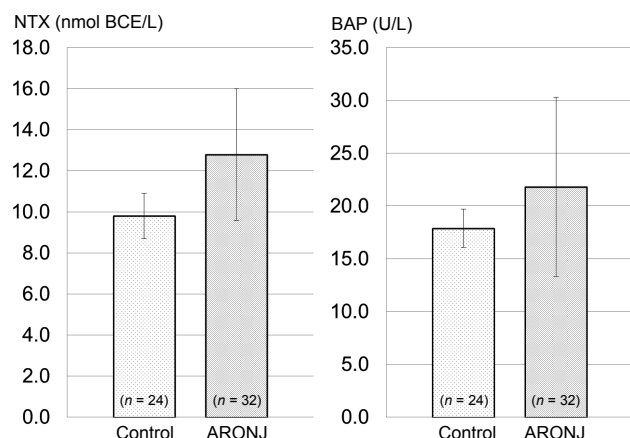
The control, ARONJ (healing), and ARONJ (non-healing) groups contained 24, 15, and 17 patients, respectively. The mean ages of the control, ARONJ (healing) and ARONJ (non-healing) groups were 67.6 years (range, 48–83 years), 75.1 years (range, 61–93 years) and 69.0 years (range, 40–80 years), respectively. No significant difference was detected among the mean ages of 3

groups. The patients' other characteristics are shown in Table 1. In addition, 4 patients (14.3%) that underwent tooth extraction subsequently developed ARONJ. These patients were not included in the control group. The mandibular BMD values of the 4 patients were 504 mg/mL, 564 mg/mL, 519 mg/mL and 412 mg/mL, respectively. 2 (50.0%) of 4 patients were healing.

### Patients' serum NTX and BAP levels

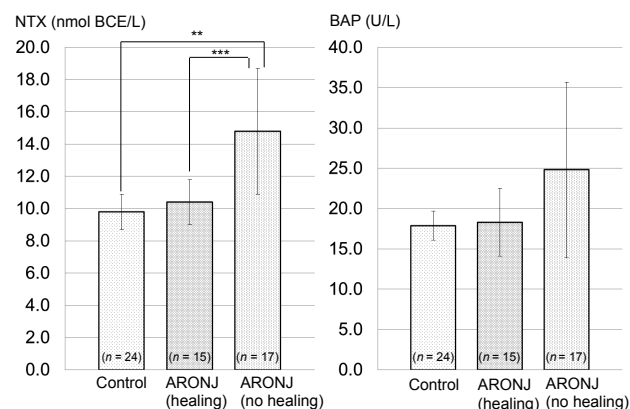
The mean serum NTX levels ( $\pm$  standard deviation) of the control and ARONJ groups were  $9.8 \pm 1.1$  nmol bone collagen equivalents (BCE)/L and  $12.8 \pm 3.2$  nmol

BCE/L, respectively. The mean serum BAP levels of the control and ARONJ groups were  $17.9 \pm 1.8$  U/L and  $21.8 \pm 8.5$  U/L, respectively (Fig. 2). The differences between the two groups were not significant.



**Fig. 2.** The levels of systemic markers of bone turnover in the control and ARONJ groups.

The left figure shows serum NTX levels, and the right figure shows serum BAP levels. The correlation between control and ARONJ group was calculated using the Student's *t*-test. No significant differences were detected between the local mandibular statuses of the two groups with regard to NTX or BAP. ARONJ, anti-resorptive agent-related osteonecrosis of the jaw; BAP, bone alkaline phosphatase; NTX, cross-linked N-terminal telopeptide of type I collagen.



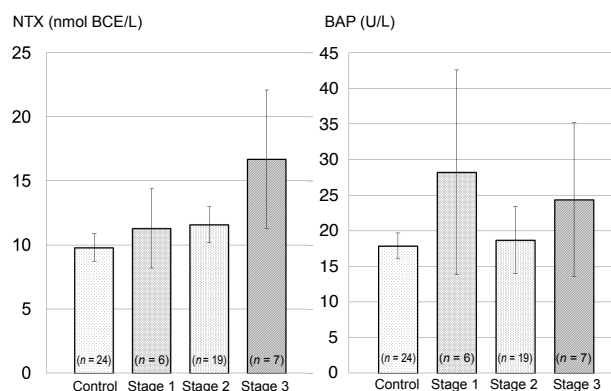
**Fig. 3.** Levels of systemic markers of bone turnover according to the outcome of ARONJ.

The left figure shows serum NTX levels and the right figure shows serum BAP levels. The correlation between control, ARONJ (healing) and ARONJ (no healing) groups was calculated using the Tukey-Kramer test. The NTX levels of ARONJ (no healing) groups were significantly higher than that of the control group and ARONJ (healing) group (\*\* $P < 0.01$ , \*\*\* $P < 0.05$ ). However, there was no significant difference among the BAP levels of the control, ARONJ (healing) and ARONJ (no healing) groups. ARONJ, anti-resorptive agent-related osteonecrosis of the jaw; BAP, bone alkaline phosphatase; NTX, cross-linked N-terminal telopeptide of type I collagen.

In addition, the mean NTX levels of the ARONJ (healing) and ARONJ (non-healing) groups were  $10.4 \pm 1.4$  nmol BCE/L and  $14.8 \pm 3.9$  nmol BCE/L, respectively, and the mean BAP levels of the ARONJ (healing) and ARONJ (non-healing) groups were  $18.3 \pm 4.2$  U/L and  $24.8 \pm 10.9$  U/L, respectively (Fig. 3). The NTX levels of non-healing ARONJ groups were significantly higher than that of control group ( $P < 0.01$ ) and similarly higher than that of healing ARONJ groups ( $P < 0.05$ ). However, there were no significant differences among the BAP levels of the control, ARONJ (healing) and ARONJ (non-healing) groups.

#### Levels of systemic markers of bone turnover according to the clinical stage of ARONJ

There were 6, 19, and 7 patients with stage 1, 2 and 3 ARONJ, respectively. The mean NTX levels of the stage 1, 2 and 3 patients were  $11.3 \pm 3.1$  nmol BCE/L,  $11.6 \pm 1.4$  nmol BCE/L and  $16.7 \pm 5.4$  nmol BCE/L, respectively. The mean BAP levels of the stage 1, 2, and 3 patients were  $28.2 \pm 14.4$  U/L,  $18.7 \pm 4.7$  U/L and  $24.4 \pm 10.8$  U/L, respectively (Fig. 4). No significant difference was detected among the systemic marker levels of the control, stage 1, stage 2, and stage 3 patients.



**Fig. 4.** Levels of systemic markers of bone turnover according to the clinical stage of ARONJ.

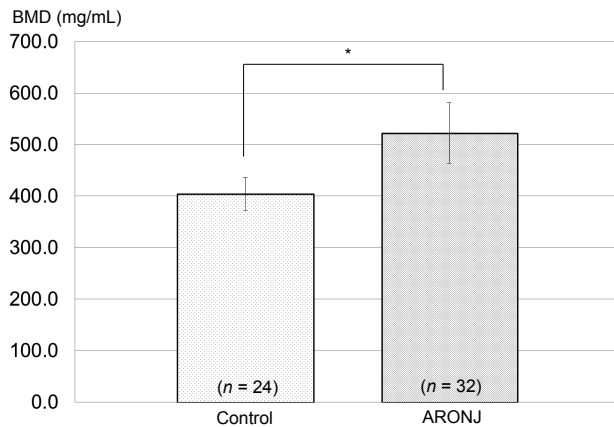
The left figure shows serum NTX levels and the right figure shows serum BAP levels. The correlation between control and each clinical stage of ARONJ was calculated using the Steel-Dwass test. No significant differences were detected among the 4 groups. ARONJ, anti-resorptive agent-related osteonecrosis of the jaw; BAP, bone alkaline phosphatase; NTX, cross-linked N-terminal telopeptide of type I collagen.

#### Patients' mandibular BMD values

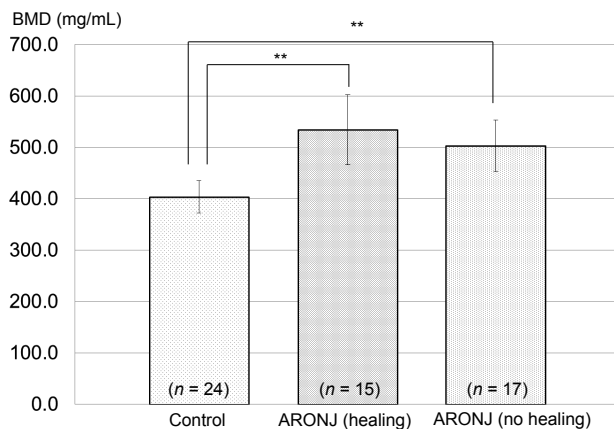
The mandibular BMD values of the control and ARONJ groups are shown in Fig. 5. The mean BMD values of the control and ARONJ groups were  $403.5 \pm 31.7$  mg/

mL and  $522.4 \pm 58.7$  mg/mL, respectively. The mean mandibular BMD value of the ARONJ group was significantly higher than that of the control group ( $P < 0.001$ ).

In addition, the mandibular BMD values of the ARONJ (healing) and ARONJ (non-healing) groups are shown in Fig. 6. The mean mandibular BMD values of the ARONJ (healing) and ARONJ (non-healing) groups were  $534.1 \pm 67.9$  mg/mL and  $512.2 \pm 51.1$  mg/mL, respectively. The BMD values of both groups were significantly higher than that of the control group ( $P < 0.01$ ). However, there was no significant difference between



**Fig. 5.** The correlation BMD values between control and ARONJ group was calculated using the Student's *t*-test. The mean BMD value of the ARONJ group was greater than that of the control ( $*P < 0.001$ ). ARONJ, anti-resorptive agent-related osteonecrosis of the jaw; BMD, bone mineral density.



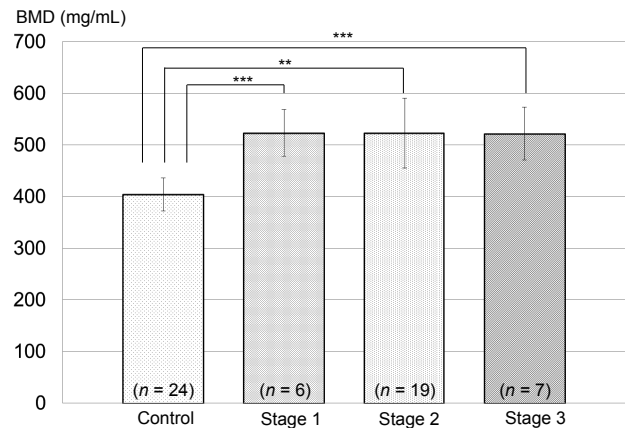
**Fig. 6.** The correlation BMD values between control, ARONJ (healing) and ARONJ (non-healing) groups was calculated using the Tukey-Kramer test. The BMD values of the ARONJ (healing) and ARONJ (non-healing) groups were higher than those of the control group ( $*P < 0.01$ ). In contrast, no significant difference was detected between the BMD values of the ARONJ (healing) and ARONJ (non-healing) groups. ARONJ, anti-resorptive agent-related osteonecrosis of the jaw; BMD, bone mineral density.

the BMD values of the ARONJ (healing) and ARONJ (non-healing) groups.

### Mandibular BMD values according to the clinical stage of ARONJ

The mean BMD values of the stage 1, 2 and 3 patients were  $522.7 \pm 45.2$  mg/mL,  $522.7 \pm 67.9$  mg/mL and  $522.0 \pm 51.4$  mg/mL, respectively (Fig. 7).

The BMD values of all ARONJ stages were significantly higher than that of the control group ( $P < 0.05$ ), but no significant differences were detected among the BMD values of the stage 1, 2 and 3 patients.



**Fig. 7.** The correlation BMD values according to the clinical stage of ARONJ was calculated using the Steel-Dwass test.

The BMD values of the patients with each clinical stage of ARONJ were significantly higher than that of the control group ( $**P < 0.01$ ,  $***P < 0.05$ ). However, the BMD values of the stage 1, 2 and 3 ARONJ patients did not differ significantly. ARONJ, anti-resorptive agent-related osteonecrosis of the jaw; BMD, bone mineral density.

## DISCUSSION

The first case of ARONJ was reported over a decade ago,<sup>17</sup> but the pathophysiology of the disease has not been fully elucidated. Various hypotheses have been proposed to explain the exclusive localization of ARONJ in the jaws, including altered bone remodeling or the excessive suppression of bone resorption, a reduction in blood supply, continuous dentoalveolar trauma, the suppression of innate or acquired immunity, vitamin D deficiency, soft tissue bisphosphonate toxicity, inflammation and infection.<sup>30–38</sup>

Patients that are treated with anti-resorptive agents and undergo dentoalveolar surgery are at least 7 times more likely to develop ARONJ than patients who do not undergo dentoalveolar surgery. However, patients who receive anti-resorptive agents and do not develop

ARONJ after undergoing dentoalveolar surgery remains unclear.<sup>39</sup> The present study is the first to examine ARONJ risk prediction using such patients as a control group.

The imaging findings of ARONJ are similar to those of common osteomyelitis of the jaw, and there is essentially no difference between the two conditions.<sup>40–42</sup> In addition, the hematological and histopathological findings of the two conditions are also similar. Thus, ARONJ is primarily diagnosed based on its clinical findings, but radiographic imaging is essential for determining the extent of the disease, diagnosing ARONJ in its early stages, identifying metastatic disease, and excluding fractures.<sup>42, 43</sup>

The main characteristic of ARONJ is that it is intractable. In this study, we noticed that many ARONJ patients with bone metastasis does not show a healing tendency especially when they receive intravenous anti-resorptive agents.

Furthermore, patients with cancer generally have a weakened immune system, so we thought that intractability was promoted by declining immunity. This makes early detection very important. Various methods for early diagnosis of ARONJ have been examined.

A number of studies have investigated ARONJ risk prediction based on serum NTX levels.<sup>40, 41, 44–46</sup> However, the utility of systemic markers of bone turnover for assessing the risk of jaw necrosis has not been validated. This study was not able to validate its utility either. Markers of bone turnover are influenced by both local and systemic factors. Moreover, NTX levels increase in patients who did not show any sign of healing. Generally, bone turnover is inhibited by anti-resorptive agents. We speculate that the systemic factors affecting such markers might include circadian rhythms, dietary effects, systemic bone disease and bone metastases. Therefore, systemic markers of the effects of bisphosphonates might not be indicative of the local bone changes that directly influence the risk of ARONJ or factors such as the regional toxic effects of bisphosphonate on bone quality and local circulation.<sup>47</sup>

Radiographic imaging is an effective method for diagnosing ARONJ as the BMD of the jaws is affected less by systemic factors than by bone turnover. In patients that have been treated with anti-resorptive agents, CT images of the mandible show osteosclerotic changes. Thus, the mandibular bone might reflect the effects of drugs to a greater extent than other bones. Several reports have evaluated the appearance of ARONJ on different imaging modalities.<sup>48–61</sup> However, there is no established method for diagnosing the condition.

We were concerned that our results might be af-

ected by inter-reader variability, such as that caused by vagueness regarding the location of the measurement site or the use of ROI that were too small. Therefore, we developed a measurement method to decrease inter-reader variability. The mental foramen is a characteristic anatomical feature of the mandible and is located below the roots of the teeth. Thus, an axial CT section that passed through the mental foramen was chosen, and the ROI was drawn so that it included the mental foramen. This approach makes sense as it has been reported that ARONJ most commonly affects sites in the mandibular molar region.<sup>56, 60</sup> In addition, we minimized the effects of inflammation caused by ARONJ or periodontal disease on our findings by obtaining measurements in the anterior mandible. In a pilot study, the results we obtained in the anterior mandible were more accurate than those obtained in the mandibular molar region (data not shown).

In the present study, the mandibular BMD of the ARONJ group was significantly greater than that of the control group. The 4 patients that developed ARONJ after undergoing tooth extraction exhibited a high mean pre-tooth extraction BMD (499 mg/mL), and 3 of these 4 patients displayed mandibular BMD values of  $\geq 500$  mg/mL. Our results support the findings of a previous study<sup>48, 50</sup> in which the ARONJ group exhibited higher BMD values than the control group. The control patients in the present study received an anti-resorptive agent before tooth extraction and did not develop ARONJ. This study demonstrated that patients with high BMD values are at a high risk for ARONJ. These results suggest that promotion of osteosclerosis of the jaw mainly due to treatment with systemic anti-resorptive agents. ARONJ may result from a decreased blood flow in the cancellous bone.

We did not detect a significant difference between the BMD values of patients with different stages of ARONJ or between those of the healing and non-healing groups, which agrees with the findings of previous studies.<sup>48, 50</sup> In addition, our findings are similar to those seen in cases of stage 1 to 3 ARONJ involving exposed bone.

Bone turnover occurs at a faster rate in cancellous bone than in cortical bone; thus, the BMD of cancellous bone is a good indicator of bone turnover and might offer a simple, quantitative means of detecting ARONJ early. Therefore, we examined cancellous bone in the present study. However, we were not able to detect the relationship between BMD and several stages of ARONJ. Thus, changes associated with the stages of osteosclerotic responses might not be detectable on imaging scans.<sup>63, 64</sup> Further studies are needed to examine the

pharmacokinetics of anti-resorptive agents and the local changes that they induce during the stages of ARONJ.

In conclusion, patients that had developed ARONJ after receiving systemic anti-resorptive agents exhibited higher mandibular BMD values than patients who had been treated with systemic anti-resorptive agents without developing ARONJ. These results suggest that increases in mandibular BMD are associated with ARONJ. Furthermore, mandibular BMD might be a useful marker for predicting the risk of ARONJ prior to tooth extraction or jaw surgery in patients that have been treated with anti-resorptive agents. Accordingly, mandibular BMD could be a useful clinical parameter for aiding risk assessment and guiding therapeutic decision-making.

*The authors declare no conflict of interest.*

## REFERENCES

- Allen MR, Burr DB. Bisphosphonate effects on bone turnover, microdamage, and mechanical properties: what we think we know and what we know that we don't know. *Bone*. 2011;49:56-65. PMID: 20955825.
- Arce K, Assael LA, Weissman JL, Markiewicz MR. Imaging findings in bisphosphonate-related osteonecrosis of jaws. *J Oral Maxillofac Surg*. 2009;67:75-84. PMID: 19371818.
- Greenspan SL, Perera S, Recker R, Wagner JM, Greeley P, Gomberg BR, et al. Changes in trabecular microarchitecture in postmenopausal women on bisphosphonate therapy. *Bone*. 2010;46:1006-10. PMID: 20051275.
- Berenson JR, Hillner BE, Kyle RA, Anderson K, Lipton A, Yee GC, et al. American Society of Clinical Oncology clinical practice guidelines: the role of bisphosphonates in multiple myeloma. *J Clin Oncol*. 2002;20:3719-36. PMID: 8559201.
- Berenson JR, Lichtenstein A, Porter L, Dimopoulos MA, Bordoni R, George S, et al. Efficacy of pamidronate in reducing skeletal events in patients with advanced multiple myeloma. Myeloma Aredia Study Group. *N Engl J Med*. 1996;334:488-93. PMID: 9469347.
- Berenson JR, Lichtenstein A, Porter L, Dimopoulos MA, Bordoni R, George S, et al. Long-term pamidronate treatment of advanced multiple myeloma patients reduces skeletal events. Myeloma Aredia Study Group. *J Clin Oncol*. 1998;16:593-602. PMID: 12202673.
- Hillner BE, Ingle JN, Chlebowski RT, Gralow J, Yee GC, Janjan NA, et al. American Society of Clinical Oncology 2003 update on the role of bisphosphonates and bone health issues in women with breast cancer. *J Clin Oncol*. 2003;21:4042-57. PMID: 12963702.
- Hortobagyi GN, Theriault RL, Lipton A, Porter L, Blayney D, Sinoff C, et al. Long-term prevention of skeletal complications of metastatic breast cancer with pamidronate. Protocol 19 Aredia Breast Cancer Study Group. *J Clin Oncol*. 1998;16:2038-44. PMID: 9626201.
- Hortobagyi GN, Theriault RL, Porter L, Blayney D, Lipton A, Sinoff C, et al. Efficacy of pamidronate in reducing skeletal complications in patients with breast cancer and lytic bone metastases. Protocol 19 Aredia Breast Cancer Study Group. *N Engl J Med*. 1996;335:1785-91. PMID: 8965890.
- Major P, Lortholary A, Hon J, Abdi E, Mills G, Menssen HD, et al. Zoledronic acid is superior to pamidronate in the treatment of hypercalcemia of malignancy: a pooled analysis of two randomized, controlled clinical trials. *J Clin Oncol*. 2001;19:558-67. PMID: 11208851.
- Nussbaum SR, Younger J, Vandepol CJ, Gagel RF, Zubler MA, Chapman R, et al. Single-dose intravenous therapy with pamidronate for the treatment of hypercalcemia of malignancy: comparison of 30-, 60-, and 90-mg dosages. *Am J Med*. 1993;95:297-304. PMID: 8368227.
- Rosen LS, Gordon D, Kaminski M, Howell A, Belch A, Mackey J, et al. Zoledronic acid versus pamidronate in the treatment of skeletal metastases in patients with breast cancer or osteolytic lesions of multiple myeloma: a phase III, double-blind, comparative trial. *Cancer J*. 2001;7:377-87. PMID: 15197804.
- Rosen LS, Gordon D, Tchekmedyian NS, Yanagihara R, Hirsh V, Krzakowski M, et al. Long-term efficacy and safety of zoledronic acid in the treatment of skeletal metastases in patients with non-small cell lung carcinoma and other solid tumors: a randomized, Phase III, double-blind, placebo-controlled trial. *Cancer*. 2004;100:2613-21. PMID: 11693896.
- Saad F, Gleason DM, Murray R, Tchekmedyian S, Venner P, Lacombe L, et al. Long-term efficacy of zoledronic acid for the prevention of skeletal complications in patients with metastatic hormone-refractory prostate cancer. *J Natl Cancer Inst*. 2004;96:879-82. PMID: 15173273.
- Bravenboer N, Papapoulos SE, Holzmann P, Hamdy NA, Netelenbos JC, Lips P. Bone histomorphometric evaluation of pamidronate treatment in clinically manifest osteoporosis. *Osteoporos Int*. 1999;9:489-93. PMID: 10624455.
- Licata AA. Discovery, clinical development, and therapeutic uses of bisphosphonates. *Ann Pharmacother*. 2005;39:668-77. PMID: 15755793.
- Marx RE. Pamidronate (Aredia) and zoledronate (Zometa) induced avascular necrosis of the jaws: a growing epidemic. *J Oral Maxillofac Surg*. 2003;61:1115-7. PMID: 12966493.
- Bagan JV, Jimenez Y, Murillo J, Hernandez S, Poveda R, Sanchis JM, et al. Jaw osteonecrosis associated with bisphosphonates: multiple exposed areas and its relationship to teeth extractions. Study of 20 cases. *Oral Oncol*. 2006;42:327-9. PMID: 16275156.
- Migliorati CA, Schubert MM, Peterson DE, Seneda LM. Bisphosphonate-associated osteonecrosis of mandibular and maxillary bone: an emerging oral complication of supportive cancer therapy. *Cancer*. 2005;104:83-93. PMID: 15929121.
- Pires FR, Miranda A, Cardoso ES, Cardoso AS, Fregnani ER, Pereira CM, et al. Oral avascular bone necrosis associated with chemotherapy and bisphosphonate therapy. *Oral Dis*. 2005;11:365-9. PMID: 16269027.
- Purcell PM, Boyd IW. Bisphosphonates and osteonecrosis of the jaw. *Med J Aust*. 2005;182:417-8. PMID: 15850440.
- Woo SB, Hellstein JW, Kalmar JR. Narrative [corrected] review: bisphosphonates and osteonecrosis of the jaws. *Ann Intern Med*. 2006;144:753-61. PMID: 16702591.
- Aghaloo TL, Felsenfeld AL, Tetradis S. Osteonecrosis of the jaw in a patient on Denosumab. *J Oral Maxillofac Surg*. 2010;68:959-63. PMID: 20149510.
- Lipton A, Fizazi K, Stopeck AT, Henry DH, Brown JE, Yardley DA, et al. Superiority of denosumab to zoledronic acid for prevention of skeletal-related events: a combined analysis of 3 pivotal, randomized, phase 3 trials. *Eur J Cancer*. 2012;48:3082-92. PMID: 22975218.
- Sinningen K, Tsourdi E, Rauner M, Rachner TD, Hamann C,

- Hofbauer LC. Skeletal and extraskeletal actions of denosumab. *Endocrine*. 2012;42:52-62. PMID: 22581255.
- 26 Ficarra G, Beninati F, Rubino I, Vannucchi A, Longo G, Tonelli P, et al. Osteonecrosis of the jaws in periodontal patients with a history of bisphosphonates treatment. *J Clin Periodontol*. 2005;32:1123-8. PMID: 16212571.
  - 27 Braga V, Gatti D, Colapietro F, Battaglia E, Righetti D, Prizzi R, et al. Intravenous intermittent neridronate in the treatment of postmenopausal osteoporosis. *Bone*. 2003;33:342-5. PMID: 13678775.
  - 28 Ruggiero SL, Dodson TB, Fantasia J, Goodday R, Aghaloo T, Mehrotra B, et al. American Association of Oral and Maxillofacial Surgeons position paper on medication-related osteonecrosis of the jaw--2014 update. *J Oral Maxillofac Surg*. 2014;72:1938-56. PMID: 25234529.
  - 29 Advisory Task Force on Bisphosphonate-Related Osteonecrosis of the Jaws AeAoOaMS. American Association of Oral and Maxillofacial Surgeons position paper on bisphosphonate-related osteonecrosis of the jaws. *J Oral Maxillofac Surg*. 2007;65:369-76. PMID: 17307580.
  - 30 Bamias A, Kastritis E, Bamia C, Mouloupoulos LA, Melakopoulos I, Bozas G, et al. Osteonecrosis of the jaw in cancer after treatment with bisphosphonates: incidence and risk factors. *J Clin Oncol*. 2005;23:8580-7. PMID: 16314620.
  - 31 Bi Y, Gao Y, Ehrchiou D, Cao C, Kikuri T, Le A, et al. Bisphosphonates cause osteonecrosis of the jaw-like disease in mice. *Am J Pathol*. 2010;177:280-90. PMID: 20472893.
  - 32 Hokugo A, Christensen R, Chung EM, Sung EC, Felsenfeld AL, Sayre JW, et al. Increased prevalence of bisphosphonate-related osteonecrosis of the jaw with vitamin D deficiency in rats. *J Bone Miner Res*. 2010;25:1337-49. PMID: 20200938.
  - 33 Mehrotra B, Ruggiero S. Bisphosphonate complications including osteonecrosis of the jaw. *Hematology Am Soc Hematol Educ Program*. 2006:356-60, 515. PMID: 17124083.
  - 34 Mortensen M, Lawson W, Montazem A. Osteonecrosis of the jaw associated with bisphosphonate use: Presentation of seven cases and literature review. *Laryngoscope*. 2007;117:30-4. PMID: 17202926.
  - 35 Reid IR, Bolland MJ, Grey AB. Is bisphosphonate-associated osteonecrosis of the jaw caused by soft tissue toxicity? *Bone*. 2007;41:318-20. PMID: 17572168.
  - 36 Sonis ST, Watkins BA, Lyng GD, Lerman MA, Anderson KC. Bony changes in the jaws of rats treated with zoledronic acid and dexamethasone before dental extractions mimic bisphosphonate-related osteonecrosis in cancer patients. *Oral Oncol*. 2009;45:164-72. PMID: 18715819.
  - 37 Ruggiero SL, Fantasia J, Carlson E. Bisphosphonate-related osteonecrosis of the jaw: background and guidelines for diagnosis, staging and management. *Oral Surg Oral Med Oral Pathol Oral Radiol Endod*. 2006;102:433-41. PMID: 16997108.
  - 38 Wood J, Bonjean K, Ruetz S, Bellahcène A, Devy L, Foidart JM, et al. Novel antiangiogenic effects of the bisphosphonate compound zoledronic acid. *J Pharmacol Exp Ther*. 2002;302:1055-61. PMID: 12183663.
  - 39 Badros A, Weikel D, Salama A, Goloubeva O, Schneider A, Rapoport A, et al. Osteonecrosis of the jaw in multiple myeloma patients: clinical features and risk factors. *J Clin Oncol*. 2006;24:945-52. PMID: 16484704.
  - 40 Fleisher KE, Welch G, Kottal S, Craig RG, Saxena D, Glickman RS. Predicting risk for bisphosphonate-related osteonecrosis of the jaws: CTX versus radiographic markers. *Oral Surg Oral Med Oral Pathol Oral Radiol Endod*. 2010;110:509-16. PMID: 20674404.
  - 41 Khosla S, Burr D, Cauley J, Dempster DW, Ebeling PR, Felsenberg D, et al. Bisphosphonate-associated osteonecrosis of the jaw: report of a task force of the American Society for Bone and Mineral Research. *J Bone Miner Res*. 2007;22:1479-91. PMID: 17663640.
  - 42 Morag Y, Morag-Hezroni M, Jamadar DA, Ward BB, Jacobson JA, Zwetchkenbaum SR, et al. Bisphosphonate-related osteonecrosis of the jaw: a pictorial review. *Radiographics*. 2009;29:1971-84. PMID: 19926757.
  - 43 Krishnan A, Arslanoglu A, Yildirm N, Silbergleit R, Aygun N. Imaging findings of bisphosphonate-related osteonecrosis of the jaw with emphasis on early magnetic resonance imaging findings. *J Comput Assist Tomogr*. 2009;33:298-304. PMID: 19346864.
  - 44 Marx RE, Cillo JE, Ulloa JJ. Oral bisphosphonate-induced osteonecrosis: risk factors, prediction of risk using serum CTX testing, prevention, and treatment. *J Oral Maxillofac Surg*. 2007;65:2397-410. PMID: 18022461.
  - 45 Kunchur R, Need A, Hughes T, Goss A. Clinical investigation of C-terminal cross-linking telopeptide test in prevention and management of bisphosphonate-associated osteonecrosis of the jaws. *J Oral Maxillofac Surg*. 2009;67:1167-73. PMID: 19446200.
  - 46 Lehrer S, Montazem A, Ramanathan L, Pessin-Minsley M, Pfail J, Stock RG, et al. Normal serum bone markers in bisphosphonate-induced osteonecrosis of the jaws. *Oral Surg Oral Med Oral Pathol Oral Radiol Endod*. 2008;106:389-91. PMID: 18554944.
  - 47 Takaishi Y, Ikeo T, Nakajima M, Miki T, Fujita T. A pilot case-control study on the alveolar bone density measurement in risk assessment for bisphosphonate-related osteonecrosis of the jaw. *Osteoporos Int*. 2010;21:815-25. PMID: 19705049.
  - 48 Bagan JV, Cibrian RM, Lopez J, Leopoldo-Rodado M, Carbonell E, Bagán L, et al. Sclerosis in bisphosphonate-related osteonecrosis of the jaws and its correlation with the clinical stages: study of 43 cases. *Br J Oral Maxillofac Surg*. 2015;53:257-62. PMID: 25560326.
  - 49 Bianchi SD, Scoletta M, Cassione FB, Migliaretti G, Mozzati M. Computerized tomographic findings in bisphosphonate-associated osteonecrosis of the jaw in patients with cancer. *Oral Surg Oral Med Oral Pathol Oral Radiol Endod*. 2007;104:249-58. PMID: 17560140.
  - 50 Hamada H, Matsuo A, Koizumi T, Satomi T, Chikazu D. A simple evaluation method for early detection of bisphosphonate-related osteonecrosis of the mandible using computed tomography. *J Craniomaxillofac Surg*. 2014;42:924-9. PMID: 24503386.
  - 51 Hutchinson M, O'Ryan F, Chavez V, Lathon PV, Sanchez G, Hatcher DC, et al. Radiographic findings in bisphosphonate-treated patients with stage 0 disease in the absence of bone exposure. *J Oral Maxillofac Surg*. 2010;68:2232-40. PMID: 20728032.
  - 52 O'Ryan FS, Khoury S, Liao W, Han MM, Hui RL, Baer D, et al. Intravenous bisphosphonate-related osteonecrosis of the jaw: bone scintigraphy as an early indicator. *J Oral Maxillofac Surg*. 2009;67:1363-72. PMID: 22595135.
  - 53 O'Ryan FS, Lo JC. Bisphosphonate-related osteonecrosis of the jaw in patients with oral bisphosphonate exposure: clinical course and outcomes. *J Oral Maxillofac Surg*. 2012;70:1844-53. PMID: 19531404.
  - 54 Popovic KS, Kocar M. Imaging findings in bisphosphonate-induced osteonecrosis of the jaws. *Radiol Oncol*. 2010;44:215-



9. PMID: 22933918.
- 55 Raje N, Woo SB, Hande K, Yap JT, Richardson PG, Vallet S, et al. Clinical, radiographic, and biochemical characterization of multiple myeloma patients with osteonecrosis of the jaw. *Clin Cancer Res.* 2008;14:2387-95. PMID: 18413829.
- 56 Rocha GC, Jaguar GC, Moreira CR, Neves EG, Fonseca FP, Pedreira EN. Radiographic evaluation of maxillofacial region in oncology patients treated with bisphosphonates. *Oral Surg Oral Med Oral Pathol Oral Radiol.* 2012;114:S19-25. PMID: 23083951.
- 57 Rugani P, Luschin G, Jakse N, Kirnbauer B, Lang U, Acham S. Prevalence of bisphosphonate-associated osteonecrosis of the jaw after intravenous zoledronate infusions in patients with early breast cancer. *Clin Oral Investig.* 2014;18:401-7. PMID: 23749244.
- 58 Stockmann P, Hinkmann FM, Lell MM, Fenner M, Vairaktaris E, Neukam FW, et al. Panoramic radiograph, computed tomography or magnetic resonance imaging. Which imaging technique should be preferred in bisphosphonate-associated osteonecrosis of the jaw? A prospective clinical study. *Clin Oral Investig.* 2010;14:311-7. PMID: 19513765.
- 59 Treister NS, Friedland B, Woo SB. Use of cone-beam computerized tomography for evaluation of bisphosphonate-associated osteonecrosis of the jaws. *Oral Surg Oral Med Oral Pathol Oral Radiol Endod.* 2010;109:753-64. PMID: 20303301.
- 60 Treister N, Sheehy N, Bae EH, Friedland B, Lerman M, Woo S. Dental panoramic radiographic evaluation in bisphosphonate-associated osteonecrosis of the jaws. *Oral Dis.* 2009;15:88-92. PMID: 18992020.
- 61 Walter C, Al-Nawas B, Grötz KA, Thomas C, Thüroff JW, Zinser V, et al. Prevalence and risk factors of bisphosphonate-associated osteonecrosis of the jaw in prostate cancer patients with advanced disease treated with zoledronate. *Eur Urol.* 2008;54:1066-72. PMID: 18602738.
- 62 Walter C, Laux C, Sagheb K. Radiologic bone loss in patients with bisphosphonate-associated osteonecrosis of the jaws: a case-control study. *Clin Oral Investig.* 2014;18:385-90. PMID: 23525860.
- 63 Matsuo A, Chiba H, Takahashi H, Toyoda J, Hasegawa O, Hojo S. Bone quality of mandibles reconstructed with particulate cellular bone and marrow, and platelet-rich plasma. *J Craniomaxillofac Surg.* 2011;39:628-32. PMID: 21419639.
- 64 Walter C, Grötz KA, Kunkel M, Al-Nawas B. Prevalence of bisphosphonate associated osteonecrosis of the jaw within the field of osteonecrosis. *Support Care Cancer.* 2007;15:197-202. PMID: 16941133.