

Tick Bite Granuloma: Recommendations for Surgical Treatment

Keisuke Hirota,* Yoshinaga Kurosawa,* Keisuke Goto, Koji Adachi, Yuichi Yoshida and Osamu Yamamoto

Division of Dermatology, Department of Medicine of Sensory and Motor Organs, School of Medicine, Tottori University Faculty of Medicine, Yonago 683-8504, Japan

ABSTRACT

Tick bite is known as a possible cause of some infectious diseases such as Lyme disease, spotted fever and related illnesses. The reaction to a tick bite may persist for several months to several years and can sometimes cause histopathological granuloma. The long-term reaction to salivary extracts from the tick could be responsible for development of granuloma in our patient. We recommended complete resection as the only sure way to treat formed granuloma.

Key words granuloma; histopathology; tick; treatment

Tick bite is known as a possible cause of Lyme disease and spotted fever related illnesses.¹ Sometimes it also causes an immune reaction resulting in granuloma formation, even in the absence of parts of the tick's mouth remaining in the skin.² We report a case of tick bite granuloma and discuss its pathogenesis and treatment.

PATIENT REPORT

A 3-year-old boy was referred to our clinic for evaluation of a red nodule on the right forehead. A tick on his forehead had been removed by hand 5 months before. Although he had been treated with topical steroid ointment for 2 months, the response was poor. Physical examination revealed a red nodule with crusts, 13 × 8 mm in diameter, on the right forehead (Fig. 1). His general condition was good and his personal past medical history was unremarkable. The lesion was excised under local anesthesia. Histopathological examination showed focal parakeratosis, spongiosis and acanthosis in the epidermis (Fig. 2). In addition, there were mixed cell granulomas composed of lymphocytes, eosinophils, plasma cells and histiocytes in the dermis (Fig. 3). Fragments of the tick were not involved in the resected tissue.

DISCUSSION

Tick bite rarely causes granuloma. The progression of tissue reaction can be classified into three stages: acute, subacute and chronic phases.³ Predominant features in

* Both authors contributed equally to this report.

Corresponding author: Yuichi Yoshida, MD

yxyhiful@med.tottori-u.ac.jp

Received 2014 November 20

Accepted 2014 December 10

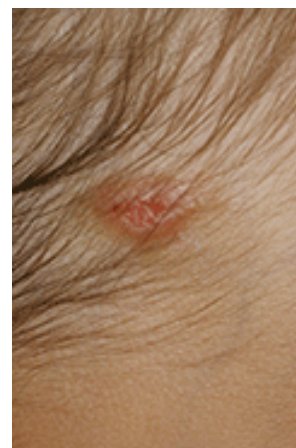

Fig. 1. A red nodule with crusts on the right forehead.

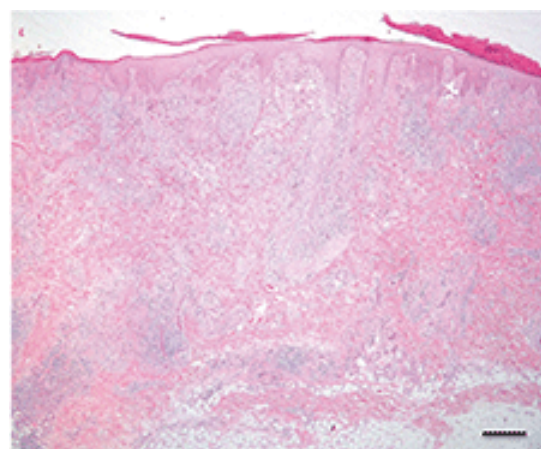


Fig. 2. Focal parakeratosis, spongiosis and acanthosis in the epidermis and granulomatous dermatitis (hematoxylin and eosin). Bar = 500 μ m.

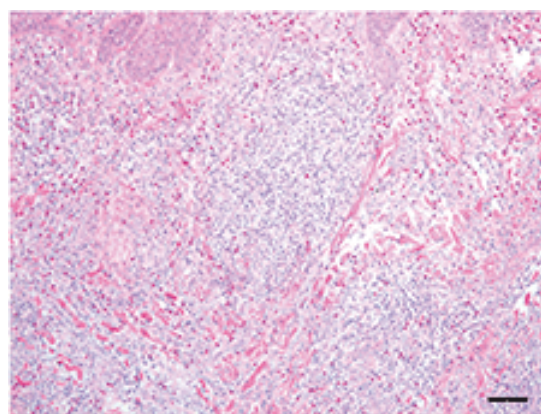


Fig. 3. Mixed cell granulomas composed with lymphocytes, eosinophils and histiocytes are seen (hematoxylin and eosin). Bar = 20 μ m.

the acute phase are dilation of superficial vessels, perivascular lymphocytic infiltrates, and intense epidermal and subepidermal infiltration of eosinophils. In the subacute phase, diffuse edema and dense infiltration of lymphocytes, neutrophils, eosinophils and histiocytes are seen, followed by an increase in fibrous tissue and the sporadic burst of giant cells in the chronic phase. The reaction to the bite of arthropods may persist for several months to several years. Stimulating agents of the arthropod somehow persist actively in these lesions for a remarkably long time. The history of an insect bite may not be reported by the patient after a lapse of many months. In such patients, it is possible for clinicians to misdiagnose the lesion as a malignant lymphoma, pyrexia Hodgkin's granuloma or pseudolymphoma (lymphadenosis benigna cutis). In our patient, atypical lymphocytes or lymphoid follicles were not seen in the lesion.

Attempts to remove the living tick often result in fragments of the tick being left in the skin. It has been speculated that the reaction to the fragments of the tick is related to the pathogenesis of granuloma.⁴ On the other hand, the long-term reaction to the salivary extracts from a tick can be responsible for development of the lesion. It has been reported that frequent biopsies contributed to the eventual disappearance of tick bite granuloma.⁵ In our patient, no fragments of the tick were found in the resected lesion. Therefore, salivary extracts might be related to the granuloma in our patient.

To our knowledge, there are few reports of treatment for tick bite granuloma. Treatment with topical steroid ointment was not effective at all in our patient. Although topical injection of corticosteroids to the granuloma can be used for treatment, it is likely that the effect would appear only temporally if the remaining fragments have not been removed. Oral administration of corticosteroid is less recommended due to its systemic side effects, particularly in children. Accordingly, we recommend complete resection as the only way for treating formed granuloma regardless of whether tick fragments remained or not since it is assumed that it takes a long time for spontaneous regression.

Owing to these facts, in unusual cases in which dermatitis follows a tick bite, excision of any remaining embedded tick fragments and associated lesion is needed in order to reduce the likelihood of the development of granulomas.

The authors declare no conflict of interest.

REFERENCES

- 1 Elston DM. Tick bites and skin rashes. *Curr Opin Infect Dis.* 2010;23:132-8. PMID: 20071986.
- 2 Castelli E, Caputo V, Morello V, Tomasino RM. Local reactions to tick bites. *Am J Dermatopathol.* 2008;30:241-8. PMID: 18496425.
- 3 Winter LH, Strakosch EA. Tick bites-dermacentor variabilis. *J Invest Dermatol.* 1941;4:249-58.
- 4 Patterson JW, Fitzwater JE, Connell J. Localized tick bite reaction. *Cutis.* 1979;24:168-9, 172. PMID: 477386.
- 5 Goldman L. Tick bite granuloma: failure of prevention of lesion by excision of tick bite area. *Am J Trop Med Hyg.* 1963;12:246-8. PMID: 13948766.