

Local Thrombolysis for Acute Massive Pulmonary Embolism using a Pulse-Infusion-Thrombolysis Catheter

Yujiro Ina*†, Katsuhiko Kondo*, Masashi Iwabuchi*, Masakiyo Nobuyoshi*, Toshio Kaminou† and Toshihide Ogawa†

*Clinic of Cardiology, Kokura Memorial Hospital, Kitakyushu 802-8555 and †Division of Radiology, Department of Pathophysiological Therapeutic Science, School of Medicine, Tottori University Faculty of Medicine, Yonago 683-8504, Japan

Acute massive pulmonary embolism (PE) is a common life-threatening condition requiring emergent and suitable treatment. The aim of this study is to assess the efficacy and safety of local thrombolysis with a pulse-infusion-thrombolysis (PIT) catheter in the management of acute massive PE. Thirty-nine patients with PE were treated with catheter directed intervention (CDI). CDI involves suction embolectomy and local thrombolysis with a PIT catheter. Procedural success was achieved in all patients (100%). After the CDI, a significant increase of mean systemic blood pressure was observed (93.8 ± 22.0 mmHg versus 100.8 ± 22.9 mmHg, $P = 0.02$), and pulmonary perfusion on the basis of Miller score was improved (19.6 ± 7.6 versus 16.3 ± 7.1 , $P = 0.04$). Clinical success was achieved in 36 of 39 patients (92.3%). Two patients died of PE after CDI despite a successful recanalization, and 1 patient died of disseminated intravascular coagulation after the CDI. No major complication occurred in the remaining 36 patients and minor complications developed in 3 patients (7.7%). Local thrombolysis using a PIT catheter for massive PE is safe and effective treatment with minimal complication.

Key words: catheter; pulmonary embolism; thrombolysis; tissue plasminogen activator

Acute massive pulmonary embolism (PE) is defined as a life-threatening condition with high mortality (Goldhaber et al., 1999; Kucher et al., 2006; Tapson, 2008). Especially, patients with massive PE are at serious risk of death due to right ventricular failure and the presence of hemodynamic instability within the first hour of onset (Adam et al., 2008). Survival depends on rapid recanalization of the pulmonary arterial occlusion and reduction of the right ventricular afterload. The standard medical management for patients with massive PE is systemic thrombolysis using a tissue plasminogen activator (t-PA) or a novel modified t-PA, mon-teplase (Buller et al., 2004). This treatment is as-

sociated with hemorrhagic risks, and some patients cannot receive systemic thrombolysis due to contraindications. Catheter directed intervention (CDI) is an alternative therapy for patients with massive PE with contraindications to systemic thrombolysis, and this method is considered to be much less invasive than the open surgery. CDI includes several interventional techniques, for example, suction embolectomy and local thrombolysis (Blaustein et al., 2004; Kuo et al., 2009). CDI with local administration of a thrombolytic agent, urokinase and t-PA has been used by several investigators (Verstraete et al., 1988; Gonzales-Juanatey et al., 1992; Kucher, 2007). A recent study (Yamamoto

Abbreviations: CDI, catheter directed intervention; PAP, pulmonary artery pressure; PE, pulmonary embolism; PIT, pulse infusion thrombolysis; RVD, right ventricular dysfunction; SBP, systolic blood pressure; t-PA, tissue plasminogen activator

et al, 2009) showed that CDI with montepase was effective for major PE; however, the safety and efficacy of local thrombolysis by CDI still remains controversial. Pulse infusion thrombolysis (PIT) is available for thrombotic diseases such as deep venous thrombosis, because of forceful delivery of thrombolytic agent in a spray-like fashion through multiple side holes (Hokimoto et al., 2008). This technique was first applied to peripheral artery and shunt thrombotic occlusion by Bookstein et al. (1989). In the present study, we used a PIT catheter (Senko Medical Instrument, Tokyo, Japan) for local thrombolysis of PE, and evaluated the safety and efficacy of CDI, and also demonstrated the early and late outcomes.

Materials and Methods

Subjects

Between January 2006 and August 2009, 113 consecutive patients referred to our department for suspected of acute PE, of whom 43 patients met criteria for acute massive PE confirmed by contrast-enhanced computerized tomography and one or

more criteria right ventricular dysfunction (RVD) without hypotension. We enrolled 39 patients for CDI using the PIT catheter, except 4 patients who had contraindication for thrombolysis.

The clinical definition of massive PE was established in the presence of cardiogenic shock or hypotension, the latter defined as systemic systolic blood pressure (SBP) < 90 mmHg, or a pressure drop > 40 mmHg for > 15 min not caused by arrhythmia, hypovolemia or sepsis (Adam et al., 2008). In all patients, RVD was confirmed by transthoracic echocardiography before angiography. The criteria applied for the diagnosis of RVD were a diastolic diameter of the right ventricle > 30 mm, a right ventricular diastolic diameter/left ventricular diastolic diameter ratio > 1, paradoxical septal movement, hypokinesia of the right ventricular free wall, loss of inspiratory collapse of the inferior vena cava, and tricuspid regurgitation at a velocity > 2.5 m/s in the absence of inspiratory collapse of the inferior vena cava or > 2.8 m/s (Wood, 2002).

Written informed consent for CDI and the potential use of the PIT was obtained in the early phase of admission. The study protocol was in agreement with the guidelines of Human Ethics Committee of the institution. If a patient was unconscious and receiving respiratory therapy at the time of inclusion in the study, the ethics committee was notified of the inclusion, and consent was initially obtained from the family.

Baseline characteristics of patients are described in Table 1. There were 15 men and 24 women with mean age of 67.9 ± 13.7 years. The most frequent risk factor was deep vein thrombosis (67%). Twelve were high-risk patients for PE with systemic SBP < 90 mmHg or shock index > 0.9. Two patients were in the state of cardiopulmonary arrest. RVD was observed in 26 patients (66.7%) by transthoracic echocardiology before procedure. Three patients became cardiopulmonary arrest and underwent cardiopulmonary resuscitation. Before local thrombolytics, 27 patients (69.2%) with deep venous thrombosis were implanted inferior vena cava filter to inhibit the recurrence of PE.

Table 1. Patients' baseline characteristics

	Patient <i>n</i> (%)
Male/female ratio	15/24
Age (year)	67.9 ± 13.7
Prior deep venous thrombosis	26 (66.7)
Cancer	3 (7.7)
Time after major surgery (< 15 days)	4 (10.3)
Smoking	7 (17.9)
Obesity	11 (28.1)
High risk pulmonary embolism	12 (30.8)
Cardiopulmonary arrest	2 (5.1)
Right ventricular dysfunction	26 (66.7)
Inferior vena cava filter	27 (69.2)
Treatment time (min)	89.2 ± 24.6

Data are number (*n*) and percentage of patients; except age and treatment time shown in mean \pm SD, and male/female ratio.

Total number of patients, 39.

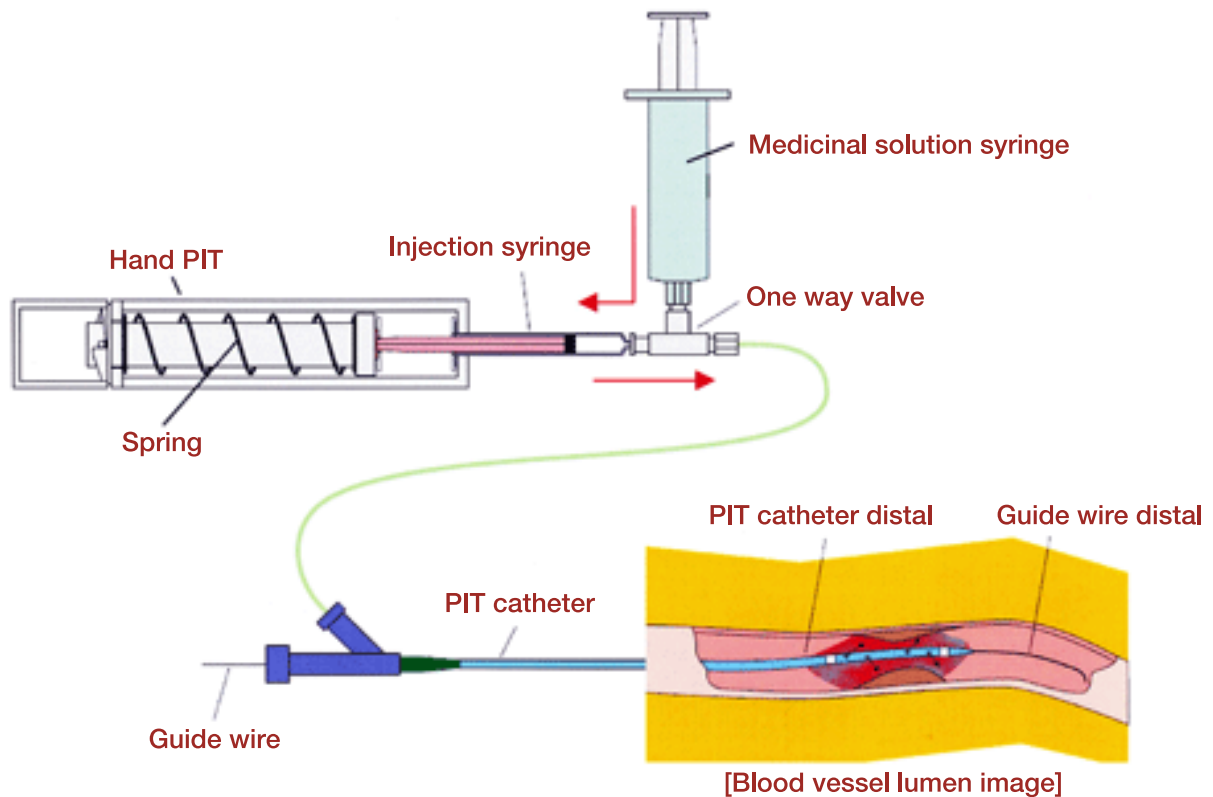


Fig. 1. Hand pulse-infusion-thrombolysis (PIT) system. The powered pump is attached to a 2.5-mL syringe. The T-shaped, one-way valve allows forceful propulsion of the thrombolytic drug and also aspiration of emboli through the PIT catheter.

Hand PIT system

The hand PIT system consists of a hand PIT pump and a PIT catheter (Fig. 1). The hand PIT pump allows intermittent spray-like drug delivery through


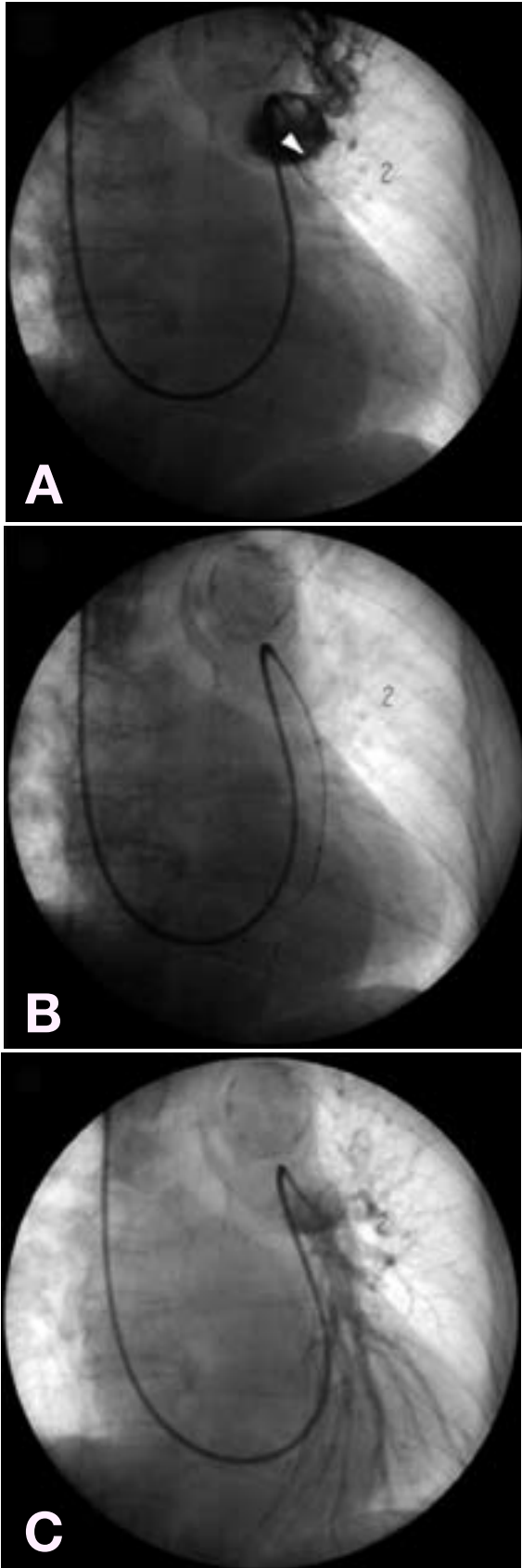


Fig. 2. Pulse-infusion-thrombolysis catheter. This catheter has spirally placed side-holes that make it possible to inject thrombolytic agent in a spray-like fashion.

a PIT catheter (Fig. 2). The side holes of the PIT catheter are placed into the thrombus and the hand PIT pump allows forcefully directed delivery of thrombolytic agent into the thrombus. This system makes it possible to increase the drug contact surface and to accelerate the thrombolytic process.

Procedure

In this study, CDI involves suction embolectomy and local thrombolysis with the hand PIT system. We used alteplase or urokinase as a thrombolytic agent on the basis of the severity of patient condition. Alteplase was used when the hemodynamic improvement of the patient was needed as soon as possible because of instable condition, otherwise urokinase was used (Sors et al., 1994). CDI was performed by a 6- to 8-Gauge French short sheath introduced into the femoral vein or internal jugular vein. When the transfemoral access was consid-



ered to be contraindicated in case of ilio caval or ipsilateral femoral venous thrombus, we selected the transjugular route. If deep venous thrombosis was confirmed by venous ultrasound or contrast-enhanced computerized tomographic images, an inferior vena cava filter was inserted through the delivering catheter and implanted below the level of the renal vein.

Immediately after the diagnosis of PE, intravenous unfractionated heparin was started with a bolus dose of 5,000 IU, followed by continuous infusion with 10,000 to 15,000 IU/day. Pulmonary artery pressure (PAP) was measured by Swan-Ganz-catheter (Baxter Healthcare, Irvine, CA) in the pulmonary artery trunk just before and immediately after CDI. After hemodynamic measurement had been taken, pulmonary angiography was performed in all patients using a combination of digital subtraction angiography and conventional film angiography through a 6- to 8-Gauge French Judkins right guide-catheter (Terumo, Tokyo, Japan) using iopromide 240 mgI/mL as a contrast medium. Angiography was performed with the catheter placed in the pulmonary trunk and selectively in the right and left main pulmonary arteries. We assessed the extent of thrombus formation by a scoring system of Miller et al. (1971). In this method, the right and left main pulmonary arteries are considered to have nine and seven major branches, respectively, and an embolus in any of these branches is scored as 1 point. The maximum possible score for involvement is 16 points. In addition, the effect of embolism on pulmonary artery flow is scored as follows: each lung is considered to

Fig. 3. Pulmonary angiograms in a 65-year-old woman with massive pulmonary embolism.

- A:** Pretreatment image shows emboli in the left lower lobe artery (arrowhead). The pulmonary artery pressure (PAP) was 33/19 mmHg (mean, 25 mmHg), and the Miller score was 14.
- B:** Local thrombolysis was performed using the pulse infusion thrombolysis catheter.
- C:** Posttreatment image shows complete recanalization of pulmonary artery occlusion. The PAP was 30/10 mmHg (mean, 18 mmHg), and the Miller score was 10.

have an upper, middle and lower zones, and in each of these 3 zones, the absence of pulmonary artery flow is scored as 3 points; severely reduced flow, 2 points; mildly reduced flow, 1 point; and normal flow; 0 point. The maximum score for reduction in pulmonary artery flow is therefore 9 points for each lung (total 18), and the maximum possible score for flow reduction and involvement of arteries by embolism is 34 points. Thus the Miller score ranges from 0 to 34 with higher scores reflecting greater pulmonary involvement.

After pulmonary angiography, suction embolectomy was performed for each pulmonary artery with the guide-catheter described above. Alteplase or urokinase was administered by the PIT system (Fig. 3). Dose of thrombolytic agent was adjusted at minimum according to the angiographic findings, hemodynamic status, and bleeding risk. The effectiveness of CDI was assessed by hemodynamic improvement and the Miller score. Finally, pulmonary angiography was performed for measurement of the postprocedure Miller score, and PAP was measured again.

After the CDI, all patients were usually sent to coronary care unit and monitored for the evaluation of complications. After stabilization of the patient's general condition, oral warfarin was also started and was continued for ≥ 6 months, with the adjustment to maintain the international normalized ratio between 2 and 3. Major procedural complications by CDI were defined as follows: hemorrhage requiring blood transfusion, cardiac tamponade, pulmonary artery perforation, cerebral vascular accident, and/or death. Minor procedural complications were defined as follows: catheter-related infection and hematoma at the puncture site or hemoptysis not requiring transfusion (Kucher, 2007).

Assessment of efficacy

The procedural success was evaluated by the Miller score after the therapy. The hemodynamic status of the patient was evaluated by the shock index obtained from dividing heart rate by systemic

SBP which is an indicator of acute critical illness (Rady et al., 1994). Other variables analyzed to evaluate the effect of the therapy were mean PAP, mean SBP and RVD on transthoracic echocardiography before and after treatment. Clinical success was defined as the stabilization of hemodynamic parameter, the resolution of shock, the complete weaning off ventilatory and inotropic support and survival until discharge from the hospital. Mid-term outcomes were defined as most recent patient's condition after discharge including analysis of occurrence of cardiovascular death, recurrent PE and RVD on transthoracic echocardiography (Liu et al., 2003).

Statistical analysis

The data were analyzed using the Student *t*-test for the comparison of paired samples. A *P* value < 0.05 was considered to be statistically significant.

Results

Procedure success rate

Procedural success was achieved in all patients (100%). As a thrombolytic agent, urokinase was used in 12 patients at mean dose of $340,000 \pm 177,866$ U, and alteplase in 27 patients with $12,836 \pm 5619$ IU/kg. Mean total procedure time was 89.2 ± 21.0 min.

Hemodynamic and angiographic parameters before and after the procedure are shown in Table 2. After CDI, a significant increase of mean SBP was observed (93.8 ± 22.0 mmHg versus 100.8 ± 22.9 mmHg, *P* = 0.02), and a significant decrease of the Miller score was observed (19.6 ± 7.6 versus 16.3 ± 7.1 , *P* = 0.04). On the other hand, systolic SBP, mean PAP and shock index were not significantly different.

In-hospital outcome

Clinical success was achieved in 36 of 39 patients (92.3%). Two patients died of PE after CDI despite

Table 2. Hemodynamic and angiographic parameters

	Before procedure	After procedure	<i>P</i> value
Systemic SBP (mmHg)	131.8 ± 30.1	138.9 ± 31.7	0.31
Mean SBP (mmHg)	93.8 ± 22.0	100.8 ± 22.9	0.02
Mean PAP (mmHg)	33.4 ± 10.4	33.1 ± 9.7	0.19
Miller score	19.6 ± 7.6	16.3 ± 7.1	0.04
Shock index	0.71 ± 0.28	0.64 ± 0.29	0.34

Shown are mean ± SD.

PAP, pulmonary artery pressure; SBP, systolic blood pressure.

a successful recanalization, and 1 patient died of disseminated intravascular coagulation 5 days after the treatment. Overall mortality was 7.7% (3/39 patients). No major complication such as perforation of pulmonary artery occurred in the remaining 36 patients. Minor complications developed in 3 of 39 patients (7.7%) (hematoma at the puncture site, 1 patient; hemothysis, 2 patients). Thirty-six patients survived and remained stable until the discharge (mean duration 18.1 ± 7.7 days). RVD was observed in 6 patients (15.4%) at the point of discharge, while observed in 24 patients (61.5%) at admission.

Mid-term outcome

Follow-up information after discharge was obtained from 33 patients (mean follow-up 25.3 ± 16.9 months). One patient died during follow-up period because of gynecological cancer (1/33 patients, 3.0%). Other patients were confirmed to be alive. Recurrent PE was not observed during follow-up period. RVD was observed in 4 patients (11.1%) after discharge.

Discussion

No randomized clinical trials have been undertaken to evaluate the efficacy and safety of local thrombolysis with the PIT system for massive PE. Acute massive PE is defined as a life-threatening condition with high mortality (Goldhaber et al., 1999). Patients with massive PE are at serious risk

of death due to RVD within the first hours of onset (Dalen and Alpert, 1975). Survival depends on rapid recanalization of the pulmonary arterial occlusion and reduction of the right ventricular afterload. The American College of Chest Physicians and the European Society of Cardiology have recommended thrombolytic therapy for these patients (Buller et al., 2004).

There are 2 approaches to administrate thrombolytic agent: systemic and local thrombolysis with CDI, which is controversial. The standard treatment for massive PE is systemic thrombolysis (Buller et al., 2004); however, some patients cannot receive systemic thrombolysis due to contraindications. Although some authors reported no difference for prognosis between these approaches, several reports showed that local thrombolysis improves severe hemodynamic impairment rapidly and safety in patients with acute PE (Tajima et al., 2004; Kuo et al., 2009; Yamamoto et al., 2009). In our series, local thrombolysis was adopted. In our study, 36 patients with acute PE were treated by CDI with a clinical success rate of 92.3% that is higher than previous review (Kuo et al., 2009). In-hospital mortality (7.7%) is lower than that reported by International Cooperative Pulmonary Embolism Registry investigation (11.4%, 2 weeks) (Goldhaber et al., 1999).

PIT has previously been described as an effective device for treating deep venous thrombosis or acute myocardial infarction (Hokimoto et al., 2008; Kuo et al., 2009). PIT catheter makes it possible to lyse thrombus using the synergetic mechanisms of mechanical maceration by direct

spray-like delivery of thrombolytic agent into the thrombus. Hence, a high concentration of drug is delivered into the thrombus, resulting in lower dose of the drug. In the present study, the use of a mean dose of thrombolytic agent was approximately half of the recommended dose. We consider that it contributes to reduce the risk of hemorrhage complication in our study.

Regression of right ventricular overload has been shown in previous studies after CDI, and rapid recovery from RVD is associated with reduced morbidity and mortality (Adam et al., 2008). In our study, PAP indicating right ventricular overload was not significantly different before and immediately after CDI. However, RVD confirmed by transthoracic echocardiography was significantly reduced at the discharge.

Reported complications associated with CDI include right ventricular perforation, significant bleeding at the puncture site (2%), mechanical hemolysis, and blood loss (Kucher, 2007; Skaf et al., 2007; Eid-Lidt et al., 2008). There were no major complications related to the catheter procedure in our study. Although disseminated intravascular coagulation occurred at 5 days after CDI in 1 patient, association with CDI is unclear. As minor complications, hematoma was documented in 1 patient. No recurrence of PE or cardiovascular death was documented in our study during follow-up. The absence of PE recurrence could probably be related to the use of inferior vena cava filter and oral warfarin administration in patients confirmed as with DVT (Adam et al., 2008).

The present study possesses some limitations regarding non-randomized study, small samples from a single institution and retrospective design, which may have introduced variability in the uniformity of data collection. Although prospective studies are needed to confirm the effectiveness of this local thrombolysis with the PIT system, we believe that this treatment should be effective for patients with massive PE accompanied by unstable hemodynamics when there is insufficient time to infuse intravenous thrombolytics.

In conclusion, local thrombolysis using a PIT catheter for massive PE is safe and effective treatment with minimal complication.

References

- 1 Adam T, Arnaud P, Stavros K, Giancarlo A, Nazzareno G, Piotr P, et al. Guidelines on diagnosis and management of acute pulmonary embolism: the task force for the diagnosis and management of acute pulmonary embolism of the European Society of Cardiology. *Eur Heart J* 2008;29:2276–2315.
- 2 Blaustein HS, Schur I, Shapiro JM. Acute massive pulmonary embolism in a Jehovah's witness: successful treatment with catheter thrombectomy. *Chest* 2000;117:594–597.
- 3 Bookstein JJ, Fellmeth B, Roberts AC, Valji K, Davis G, Machado T. Pulsed-Spray pharmacomechanical thrombolysis: preliminary clinical results. *AJR* 1989;152:1097–1100.
- 4 Buller HR, Agnelli G, Hull RD, Hyers TM, Prins MH, Raskob GE. Antithrombotic therapy for venous thromboembolic disease: the seventh ACCP conference on antithrombotic and thrombolytic therapy. *Chest* 2004;126(suppl):401S–428S.
- 5 Dalen JE, Alpert JS. Natural history of pulmonary embolism. *Prog Cardiovasc Dis* 1975;17:257–270.
- 6 Eid-Lidt G, Gaspar J, Sandoval J, Santos FD, Pulido T, Pacheco HG, et al. Combined clot fragmentation and aspiration in patients with acute pulmonary embolism. *Chest* 2008;134:54–60.
- 7 Goldhaber SZ, Visani L, De Rosa M. Acute pulmonary embolism: clinical outcomes in the International Cooperative Pulmonary Embolism Registry (ICOPER). *Lancet* 1999;353:1386–1389.
- 8 Gonzales-Juanatey JR, Valdes L, Amaro A, Iglesias C, Alvarez D, Garcia JM, et al. Treatment of massive pulmonary thromboembolism with low intrapulmonary dosages of urokinase: short term angiographic and hemodynamic evolution. *Chest* 1992;102:341–346.
- 9 Hokimoto S, Saito T, Oshima S, Ogawa H. Initial and mid-term outcomes of pulse infusion thrombolysis using a unique pump system and stent placement for deep vein thrombosis. *Inter Med* 2008;47:1663–1667.
- 10 Kucher N. Catheter embolectomy for acute pulmonary embolism. *Chest* 2007;132:657–663.
- 11 Kucher N, Rossi E, Rosa MD, Goldhaber SZ. Massive pulmonary embolism. *Circulation* 2006;113:577–582.
- 12 Kuo WT, Gould MK, Louie JD, Rosenberg JK, Sza DY, Hofmann LV. Catheter-directed therapy for the treatment of massive pulmonary embolism: systematic review and meta-analysis of modern techniques. *J Vasc Interv Radiol* 2009;20:1431–1440.
- 13 Liu P, Meneveau N, Schiele F, Bassan JP. Predictors of long-term clinical outcome of patients with acute mas-

- sive pulmonary embolism after thrombolytic therapy. *Chin Med J* 2003;116:503–509.
- 14 Miller GAH, Sutton GC, Kerr IH, Gibson RV, Honey M. Comparison of streptokinase and heparin in treatment of isolated acute massive pulmonary embolism. *BMJ* 1971;2:2681–2684.
 - 15 Rady MY, Smithline HA, Blake H, Nowak R, Rivers E. A comparison of the shock index and conventional vital signs to identify acute, critical illness in the emergency department. *Ann Emerg Med* 1994;24:685–690.
 - 16 Skaf E, Beemath A, Siddiqui T, Janjua M, Patel NR, Stein PD. Catheter-tip embolectomy in the management of acute massive pulmonary embolism. *Am J Cardiol* 2007;99:415–420.
 - 17 Sors H, Pacouret G, Azarian R, Meyer G, Charbonnier B, Bassand JP, et al. Hemodynamic effects of bolus versus two hour infusion of alteplase in acute massive pulmonary embolism. A randomized controlled multicenter trial. *Chest* 1994;106:712–717.
 - 18 Tajima H, Murata S, Kumazaki T, Nakazawa K, Abe Y, Komada Y, et al. Hybrid treatment of acute massive pulmonary thromboembolism: mechanical fragmentation with a modified rotating pigtail catheter, local fibrinolytic therapy, and clot aspiration followed by systemic fibrinolytic therapy. *AJR* 2004;183:589–595.
 - 19 Tapson VF. Acute pulmonary embolism. *N Engl J Med* 2008;358:1037–1052.
 - 20 Verstraete M, Miller GA, Bounameaux H, Charbonnier B, Colle JP, Lecorff G, et al. Intravenous and intrapulmonary recombinant tissue-type plasminogen activator in the treatment of acute massive pulmonary embolism. *Circulation* 1988;77:353–360.
 - 21 Wood KE. Major pulmonary embolism: review of a pathophysiologic approach to the golden hour of hemodynamically significant pulmonary embolism. *Chest* 2002;121:877–905.
 - 22 Yamamoto T, Murai K, Tokita Y, Kato K, Iwasaki Y, Sato N, et al. Thrombolysis with a novel modified tissue-type plasminogen activator, monteplase, combined with catheter-based treatment for major pulmonary embolism. *Circ J* 2009;73:106–110.
- Received January 12, 2010; accepted January 20, 2010*
- Corresponding author: Toshihide Ogawa, MD, PhD*