

Neurogenic Dumbbell Tumor Resected by Combined Posterior and Thoracoscopic Approaches

Makoto Wakahara, Hiroshige Nakamura*, Ken Miwa*, Yoshin Adachi*, Shinji Fujioka*, Tomohiro Haruki*, Yuji Taniguchi*, Masako Hayashibara†, Hideki Nagashima† and Ryota Teshima†

*Post-Graduate Clinical Research Center and *Division of General Thoracic Surgery, Tottori University Hospital and †Division of Orthopaedic Surgery, Department of Medicine of Sensory and Motor Organs, School of Medicine, Tottori University Faculty of Medicine, Yonago 683-8504 Japan*

The patient was a 51-year-old female with a chief complaint of numbness of the right thigh. A dumbbell tumor compressing the 11th thoracic spinal cord was present in the posterior mediastinum on chest computed tomography and myelography. In surgery, the tumor in the spinal canal was resected by a posterior approach, and the residual tumor was completely excised by thoracoscopic surgery. The tumor measured 78 × 48 mm, and histopathologically diagnosed as schwannoma. The surgical procedure for neurogenic dumbbell tumors should be decided based on Eden's classification. For types II and III, such as this patient, excision of the tumor in the spinal canal should be performed to avoid spinal cord damage, followed by thoracoscopic complete resection. Thoracoscopic surgery was applicable even though the tumor was large.

Key words: dumbbell tumor; neurogenic tumor; posterior approach; thoracoscopic surgery

Neurogenic tumors account for 12% to 21% of mediastinal tumors, and many are associated with the intercostal and sympathetic nerves (Ozawa et al., 2007). About 10% of neurogenic tumors invade the spinal canal (Cardillo et al., 2008), and are called dumbbell tumors because of their shape. Surgery is the first-choice treatment, but the surgical procedure for this type is difficult because it expands outside and inside the spinal canal via the intervertebral foramen. There are posterior and thoracic approaches employed individually or in combination, depending on tumor advancement (Nakamura et al., 2000; Grillo et al., 2003; Payer et al., 2006; Agrawal et al., 2008). We resected a large intrathoracic neurogenic dumbbell tumor classified type III on Eden's classification (Eden,

1941) by combined posterior and thoracoscopic approaches, and achieved a favorable outcome.

Patient Report

The patient was a 51-year-old female in whom a mass was discovered on chest computed tomography (CT) in 2000 during a medical checkup, and diagnosed as a thoracic spinal tumor by findings on chest magnetic resonance imaging (MRI). Since the tumor size had not changed from when chest CT was done in 1998, and symptoms were absent, course observation was selected. Since the tumor started to grow in 2003, and numbness appeared in the right thigh in April 2007, surgery was sched-

Abbreviations: CT, computed tomography; MRI, magnetic resonance imaging

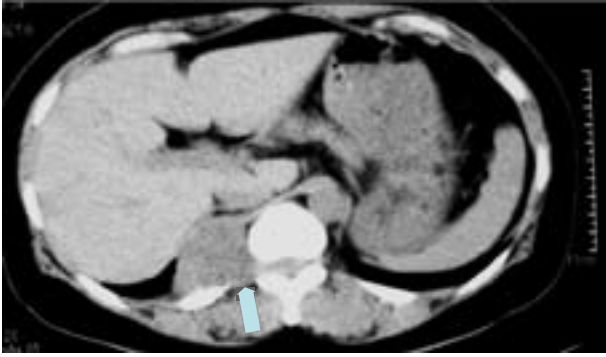


Fig. 1. Chest CT shows an approximately 60-mm in diameter dumbbell tumor (arrow) at the 11th thoracic vertebral level.

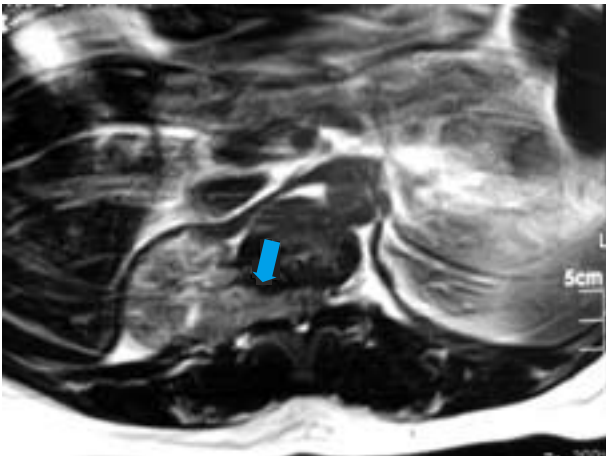


Fig. 2. Chest MRI shows a tumor invading the spinal canal (arrow) via the intervertebral foramen (Eden type III dumbbell tumor).

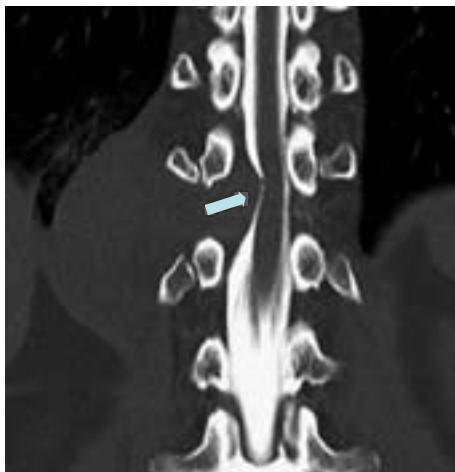


Fig. 3. CT myelography reveals that the thoracic spinal cord is markedly compressed by the tumor (arrow).

uled. A 60-mm Eden III dumbbell tumor was present at the 11th thoracic vertebral level on chest CT (Fig. 1) and chest MRI (Fig. 2), and the thoracic spinal cord was markedly compressed by the tumor on CT myelography (Fig. 3). In surgery, initially, laminectomy was performed by a posterior approach in the prone position, and the tumor in the spinal canal was resected. No tumor invasion in the dura mater was noted. The position was then changed to the lateral, and thoracoscopic surgery using 4 ports was performed. The tumor communicating with the 11th intercostal nerve was present (Fig. 4). The nerve was separated, and the tumor was completely excised. The tumor measured 78 × 48 mm (Fig. 5), and histopathologically diagnosed as schwannoma (Fig. 6). The symptoms resolved after surgery, the recovery was smooth, and the patient was discharged. No recurrence has occurred as of 1 and a half years after surgery.

Discussion

Regarding the incidence of neurogenic dumbbell tumor, Ozawa et al. observed 118 dumbbell tumors among 674 neurogenic tumors (18%); the incidence is not low, and surgical methods less invasive to prevent postoperative deformity are necessary (Ozawa et al., 2007). Generally, there are thoracic approaches, such as thoracotomy and thoracoscopic surgery, and posterior approaches, such as laminectomy and costotransversectomy, and these are employed individually or in combination (Nakamura et al., 2000; Grillo et al., 2003; Payer et al., 2006; Agrawal et al., 2008). Surgical procedure should be decided based on tumor extension, for which Eden's classification (Eden, 1941) is used. Resection of intrathoracic tumor by a posterior approach alone is difficult in some patients, and the frequency of spinal cord disorder associated with vertebral instability and epidural surgical scar increases as the resected area expands (Payer et al., 2006). When a thoracic approach alone is employed, resection of a spinal tumor may be difficult in some patients (Payer et al., 2006). Therefore, combined

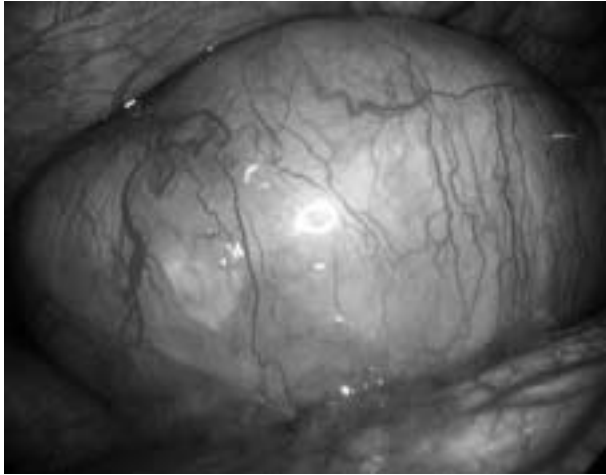


Fig. 4. Thoracoscopic findings shows a large intrathoracic tumor communicating with the 11th intercostal nerve.

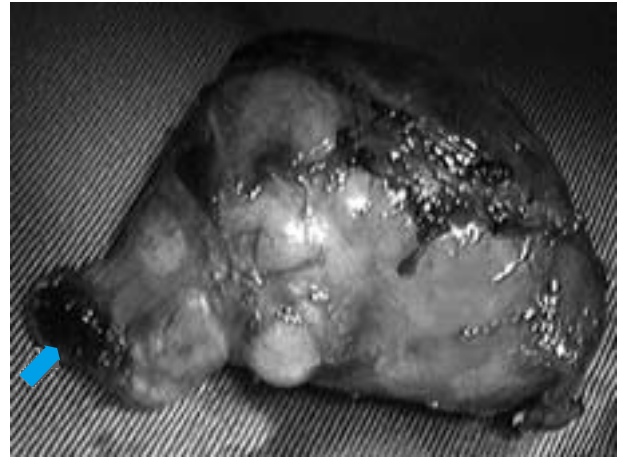


Fig. 5. The resected tumor measures 78 × 48 mm. The part of the tumor in the spinal canal is remarkably burned by electrocautery for marking (arrow).

posterior and thoracic approaches are suggested for Eden II and III types (Nakamura et al., 2000). When the tumor size is large, as in this patient, excision by a posterior approach alone is difficult, and a thoracic approach may also be necessary.

In comparing thoracotomy with thoracoscopic surgery for intrathoracic neurogenic tumors, thoracoscopic surgery was superior in the incidence of postoperative complications such as pain, duration of hospital stay after surgery and operation time

(Cardillo et al., 2008); however, they switched thoracoscopic surgery to thoracotomy in 13 of their 57 patients, and emphasized the need to pay attention to the apical region and costophrenic angle when the tumor size was larger than 6 cm (Cardillo et al., 2008). Thoracoscopic surgery is also useful for neurogenic dumbbell tumors, and recent advancements in the thoracoscopic surgical technique facilitated expansion of its indication, even for large sized tumors. This tumor was large, about 8 cm

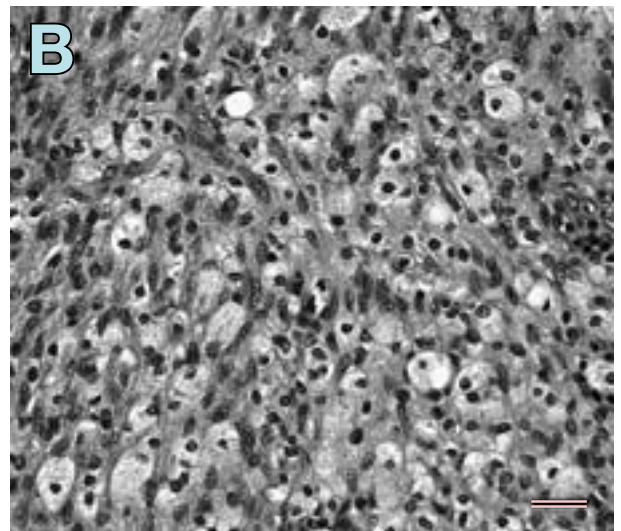
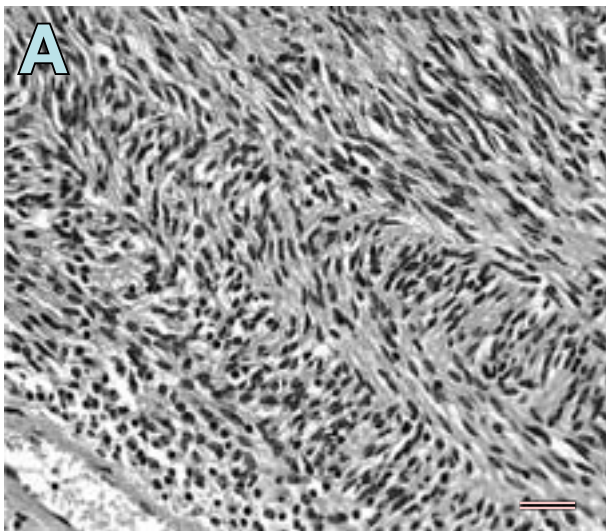


Fig. 6. In the pathological findings, 2 different patterns are recognized, designated by Antoni as A and B. The type A areas are composed of spindle cells arranged in a palisading fashion (A). In type B areas, isolated tumor cells with bizarre hyperchromatic nuclei are observed (B). Mitoses are extremely scanty in both patterns with hematoxylin and eosin staining under a high-power field. Bar = 50 μ m.

in diameter, but resection could be completed by thoracoscopic surgery. Considering thoracoscopic surgery based on Eden's classification, types II, III and IV are appropriate indications, but type I is not (Nakamura et al., 2000; Grillo et al., 2003). Type IV may be resectable by thoracoscopic surgery alone, but treatment of the region advancing into the intervertebral foramen requires consultation with apinal surgeons. Regarding the surgical procedure, an intraspinal procedure should be performed to avoid spinal cord damage, followed by complete thoracoscopic resection of the residual tumor so as to open the intervertebral foramen. The dura mater is resected in type II cases because it is invaded, for which attention should be paid in the occurrence of cerebrospinal fluid leakage as a postoperative complication.

For treatment of posterior mediastinal neurogenic tumor, the presence of the dumbbell type should be always considered, and when surgery is selected, the procedure should be based on Eden's classification. Thoracoscopic surgery may be applicable even for large tumors.

References

- 1 Agrawal A, Srivastava S, Johrapurkar SR, Gharde P, Ubeja G. Single stage complete excision of large thoracic dumbbell schwannoma by modified posterior approach. *Surg Neurol* 2008;70:432–436.
- 2 Cardillo G, Carleo F, Khalil MW, Carbone L, Treggiari S, Salvadori L, et al. Surgical treatment of benign neurogenic tumours of the mediastinum: a single institution report. *Eur J Cardio-thoracic Surg* 2008;34:1210–1214.
- 3 Eden K. The dumb-bell tumors of the spine. *Br J Surg* 1941;28:549–569.
- 4 Grillo HC, Borges LF, Mathisen DJ, Behgam M, Shadmehr MB, Gaissert HA, et al. The surgical approach to “dumbbell tumors” of the mediastinum. *Ann Thorac Surg* 2003;76:1650–1654.
- 5 Nakamura H, Makihara K, Taniguchi Y, Metsugi H, Ishiguro K, Ohgi S. Thoracoscopic surgery for three cases of dumbbell type neurogenic tumor. *Jpn Chest Surg* 2000;14:555–561.
- 6 Ozawa H, Kokubun S, Aizawa T, Hoshikawa T, Kawahara C. Spinal dumbbell tumors: an analysis of a series of 118 cases. *J Neurosurg Spine* 2007;7:587–593.
- 7 Payer M, Radovanovic I, Jost G. Resection of thoracic dumbbell neurinomas: single postero-lateral approach or combined posterior and transthoracic approach? *J Clin Neurosc* 2006;13:690–693.

Received March 18, 2009; accepted March 30, 2009

Corresponding author: Hiroshige Nakamura, MD