

Multiple Myeloma Presenting Symptoms in the Oral and Maxillofacial Region

Masami Shibata, Isamu Kodani, Rieko Doi, Kazuko Takubo, Kazunori Kidani, Hiroatsu Sakai, Masayuki Sonoda and Kazuo Ryoke

Division of Oral and Maxillofacial Biopathological Surgery, Department of Medicine of Sensory and Motor Organs, School of Medicine, Tottori University Faculty of Medicine, Yonago 683-8503 Japan

Four cases of multiple myeloma presenting symptoms in the oral and maxillofacial region are reported. The main complaints in 2 patients were macroglossia and dysphagia. We doubted these cases were amyloidosis, but examinations performed for possible amyloidosis led us to a diagnosis of multiple myeloma. The other 2 patients presented signs in the mandible. One of them had a mass-type lesion in the gingiva which upon X-ray revealed an osteolytic lesion in the mandible and multiple “punched-out” osteolytic lesions in the cranial bones. The other showed only a diffuse non-homogeneous radiolucent lesion and dental ankylosis. Medical history and biochemical and hematologic findings would be helpful in diagnosing multiple myeloma. Here, we report our summarization of these 4 cases.

Key words: amyloidosis; dysphagia; macroglossia; multiple myeloma

Multiple myeloma is a malignant disease characterized by multifocal proliferation of atypical plasma cells and, in most patients, by the presence in the serum of monoclonal gamma globulins and/or their subunits, often referred to as “M” or myeloma proteins (Lambertenghi-deliliers et al., 1988). Oral and maxillofacial manifestations as an initial sign or symptom of multiple myeloma are rare (Lee et al., 1996). The common clinical signs and symptoms of multiple myeloma include pain in the bone, fatigue, anemia and infectious diseases (Lee et al., 1996; Keung et al., 1998). Radiography frequently shows the typical “punched-out” osteolytic lesions.

Amyloidosis is a disease characterized by the deposition of an abnormal protein in a variety of organs. The infiltration can be local or systematic.

Amyloidosis as a complication has been reported in 6% to 15% of patients with multiple myeloma (Raubenheimer et al., 1986). This article reports 4 patients with multiple myeloma presenting symptoms in the oral and maxillofacial region.

Patient Report

Patient 1

A 55-year-old woman was referred to our hospital because of submental swelling and tongue stiffness on August 30, 1985. The symptoms were first noted by the patient 5 months prior to the referral, and progressed steadily since then. First physical

Abbreviation: Ig, immunoglobulin

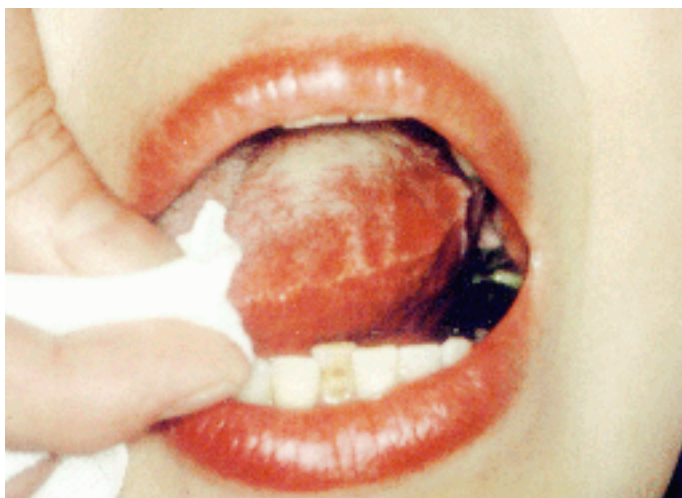

Fig. 1. Tongue showing macroglossia and indentations caused by the teeth (Patient 1).

examination showed a mass in the submental region. Intraoral examination revealed a firm diffuse swelling of the tongue. The patient's medical history included arthralgia. She did not return for medical follow-up, and no definite diagnosis was made. But 1 month later, she returned to our hospital because of rapid growth in tongue swelling. Upon intraoral examination, the tongue was significantly enlarged, firm, nodular and crenated (Fig. 1). The tongue was subjected to incisional biopsy: histological examination revealed a hyperplastic epithelium and atrophic muscle fibers. Amyloid deposits were distributed around the blood vessels.

Congo red staining of the muscle fibers revealed amyloid deposits. Upon the tentative diagnosis of amyloidosis of the tongue, further laboratory examinations were performed. The urine was positive for Bence-Jones protein. Immunoelectrophoresis of the serum showed a monoclonal IgA band with a κ light chain. Bone marrow aspiration revealed abundant plasma cells. These data helped to provide a final diagnosis of amyloidosis complicated by multiple myeloma. The patient was then referred to a hematologist for chemotherapy with melphalan and prednisolone. Swelling of the tongue was reduced temporarily. But 6 months later, a partial glossectomy was performed because the patient complained of difficulty with speaking, eating and swallowing. In the

following months there was no continuous enlargement of the tongue. Twenty-nine months after the surgical intervention, the patient died of heart failure.

Patient 2

An 81-year-old man visited our hospital after falling off of a bridge on September 27, 1996. Upon intraoral examination, the lower right 2nd premolar and 2nd molar were invaded with caries. Panoramic radiography showed an osteolytic lesion in the

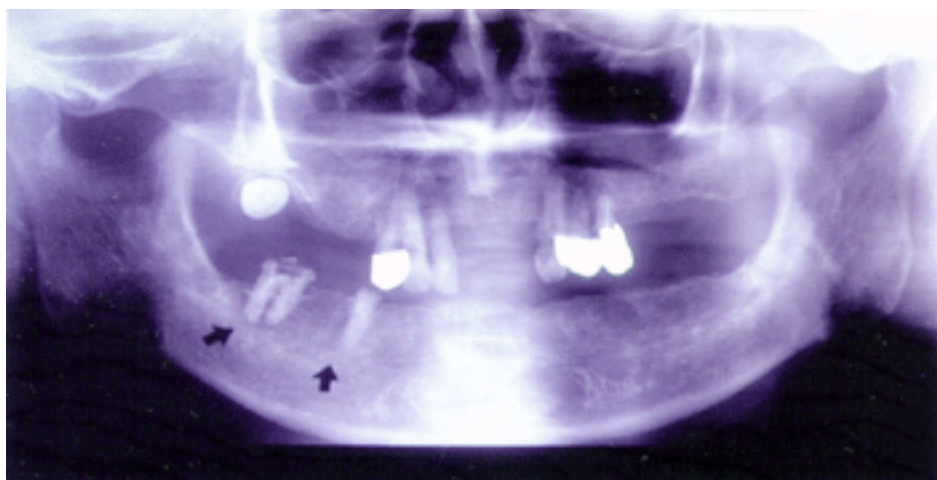


Fig. 2. Panoramic view showing osteolytic lesions on the right side of the mandibular body (Patient 2).

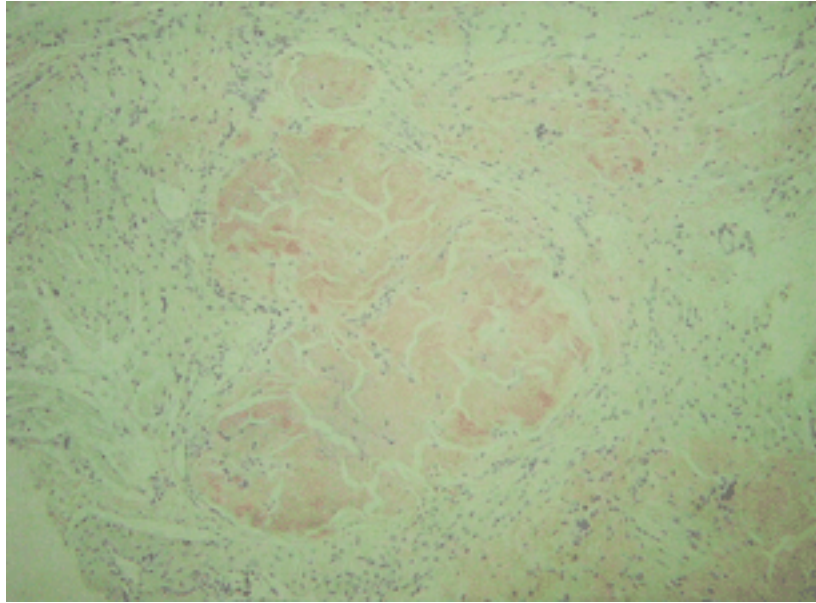


Fig. 3. Amyloid deposits in the tongue muscle (Patient 3) (Congo red stain, original magnification $\times 100$).

right mandibular body (Fig. 2). The medical history of this patient included herpes zoster in 1991, anemia and multiple myeloma treated with melphalan and prednisolone since 1995, and pneumonia and fracture of the lumbar vertebra in 1996. Biochemical and hematologic findings revealed anemia and elevation in serum IgG. We extracted his lower right 2nd premolar and 2nd molar, and observed during curettage that the jawbone was rough. The histological examination of the excised tissue revealed abundant atypical plasma cells. These results are consistent with a diagnosis of multiple myeloma.

Patient 3

An 83-year-old woman visited our hospital on April 6, 1994, because of tongue stiffness and dysphagia lasting for about 1 month. The patient's medical history included aspiration pneumonia. On the intraoral examination, we observed a firm nodular tongue with a diffuse swelling, and performed an incisional biopsy of the tongue. Congo red staining of the tissue revealed amyloid deposits in the muscle fibers (Fig. 3). Bence-Jones protein was detected in the urine. Serum protein immunoelectrophoresis revealed elevation in serum IgG with a κ chain.

The above-described results were compatible with the diagnosis of amyloidosis secondary to multiple myeloma. Because of her advanced age, active treatment against multiple myeloma was not performed.

Patient 4

A 66-year-old man visited our hospital on May 18, 1984, because of gingival swelling and bleeding in the lower right molar area for 1 month. Upon intraoral examination, we found 2 soft tissue masses located in the lower right 1st molar area ($38 \times 31 \times 28$ mm) and on the lower left 3rd molar area ($21 \times 12 \times 12$ mm). The masses were elastic, hard and pediculate (Fig. 4). Panoramic radiography showed an osteolytic lesion in the right mandibular body. The patient's medical history revealed hypertension. The mass was examined by an incisional biopsy: histologically, pleomorphic plasma cells were diffusely infiltrating. On the basis of the pathologic and clinical findings, the patient was diagnosed with multiple myeloma, and was subjected to hematologic screening and a radiographic survey. Skeletal radiographic survey of the skull revealed multiple "punched-out" osteolytic lesions (Fig. 5). Immunoelectrophoresis of the serum

protein revealed a monoclonal IgG with a κ chain. Chemotherapy with melphalan, cyclophosphamide, prednisolone and vincristine, and local radiotherapy for the mandibular mass were administered. The chemotherapy was replaced with melphalan and prednisolone. The patient was discharged following the disappearance of the mass. But 8 months later pancytopenia was noted. The patient was then referred to a hematologist for chemotherapy with a diagnosis of acute myelogenous leukemia. However, the patient died of acute renal insufficiency several months later.

Discussion

Although uncommon, an initial presentation of multiple myeloma may reveal oral or maxillofacial symptoms. These include swelling, mass forma-

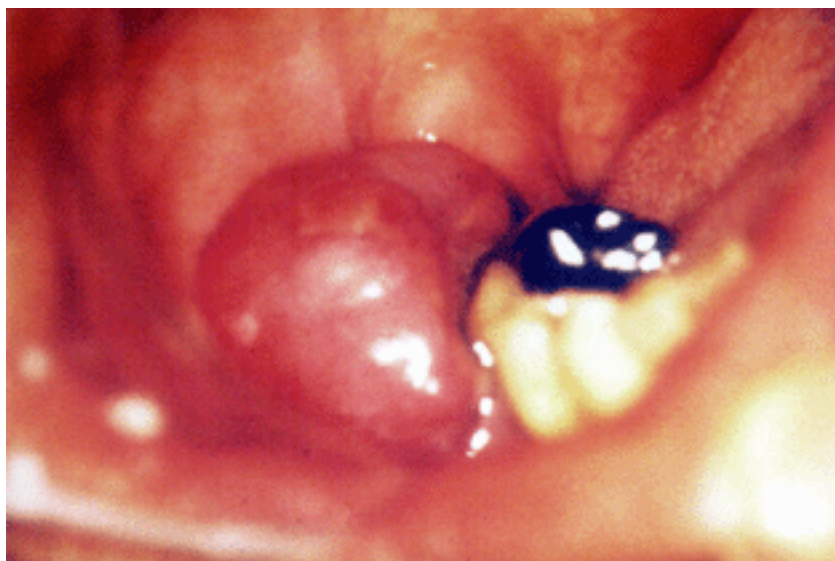


Fig. 4. Gingival mass located on the lower right 1st molar area (Patient 4).

tion, paresthesia of the lower lip, pain, bleeding and fracture of the jawbone, macroglossia and radiolucent lesions (Yaegaki et al., 1983). Osteolytic lesions are more frequent in the mandible than in the maxilla (Lee et al., 1996), especially in the posterior teeth region, ramus and condylar process, presumably because of greater hematopoietic activity in these areas (Lambertenghi-delilieri et al.,

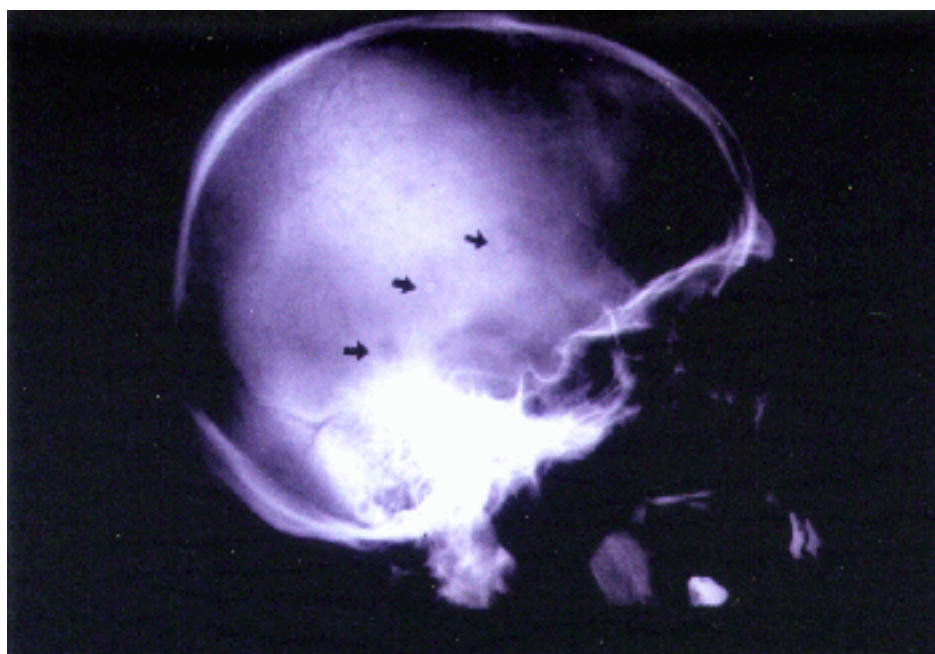


Fig. 5. Radiograph of a skull showing multiple "punched-out" osteolytic lesions (Patient 4).

1988; Lee et al., 1996). Oral lesions in patients with multiple myeloma are not uncommon, but multiple myeloma is often overlooked. Because the symptoms are various, it is very difficult to diagnose multiple myeloma in the oral and maxillofacial region. Amyloidosis as an additional complication has been reported in 6% to 15% of patients with multiple myeloma (Erich et al., 1986). Amyloid involvement of oral tissue is rather rare, and the tongue is the most encountered subsite (Rutger et al., 2002). Macroglossia, usually seen in primary amyloidosis, occurs in approximately 20% of patients (Smith and Speculand, 1985; Yusa et al., 2001). It seems that almost all secondary amyloidosis originates from reactive systematic conditions (Mardinger et al., 1999). Oral amyloidosis often comes along with various manifestations, such as multiple soft nodules, hemorrhagic-type raised lesions, rubbery swellings, with a normal overlying mucosa, with or without multiple nodules on the lateral borders of the tongue or with prominent crenation (Muto et al., 1991). In the present study, submental swelling, tongue stiffness, macroglossia and dysphagia were noted in Patient 1, and disturbed lingual mobility, induration of the tongue and dysphagia, in Patient 3. But there were no other abnormalities in the oral and maxillofacial region. The tongue is the organ which is comparatively easy to observe. Oral amyloidosis seems to be an important key in leading to a diagnosis of multiple myeloma. In Patient 1, we performed partial glossectomy to alleviate functional oral difficulty. The survival time of patients with amyloidosis associated with multiple myeloma is shorter than those without amyloidosis (Eddie et al., 1994). Patients with primary amyloidosis should be treated palliatively because of their short survival periods. Medical history and biochemical and hematologic findings would be helpful in diagnosing multiple myeloma in case of unexplained swelling and nodules in the oral region, even if radiography shows no osteolytic lesions. Furthermore, when a diagnosis of tongue amyloidosis is confirmed, dentists should start searching for underlying disorders, such as multiple myeloma.

References

- 1 Keung Y, Yung C, Wong J, Shah F. Association of temporal arteritis, retinal vasculitis and xanthomatosis with multiple myeloma: case report and literature review. *Mayo Clin Proc* 1998;73:657–60.
- 2 Lambertenghi-Deliliers G, Bruno E, Cortellezzi A, Fumagalli L, Morosini A. Incidence of jaw lesions in 193 patients with multiple myeloma. *Oral Surg Oral Med Oral Pathol* 1988;65:533–537.
- 3 Lee SH, Huang JJ, Pau WL, Chan CP. Gingival mass as the primary manifestation of multiple myeloma. *Oral Surg Oral Med Oral Pathol* 1996;82:75–79.
- 4 Mardinger O, Rotenberg L, Chaushu G, Taicher S. Surgical management of macroglossia due to primary amyloidosis. *Int J Oral Maxillofac Surg* 1999; 28:129–131.
- 5 Muto T, Sato K, Gregory J. Multiple nodules of the lip, cheeks, and tongue. *J Oral Maxillofac Surg* 1991;49:1003–1006.
- 6 Raubenheimer EJ, Dauth J, de Coning JP. Multiple myeloma presenting with extensive oral and perioral amyloidosis. *Oral Surg Oral Med Oral Pathol* 1986; 61:492–497.
- 7 Reinish EI, Raviv M, Srolovitz H, Gornitsky M. Tongue, primary amyloidosis, and multiple myeloma. *Oral Surg Oral Med Oral Pathol* 1994;77:121–125.
- 8 Rutger I, Martijn R, Peter C, Theo M. Amyloidosis of the tongue as a paraneoplastic marker of plasma cell dyscrasia. *Oral Surg Oral Med Oral Pathol* 2002;94:444–447.
- 9 Smith A, Speculand B. Amyloidosis with oral involvement. *Br J Oral Maxillofac Surg* 1985;23:435–444.
- 10 Yaegaki K, Kameyama T, Toyofuku S, Tanaka K, Yoshitake M, Kawashima R, et al. Clinicostatistical study of the multiple myeloma discovered from oral manifestation. *Nippon Koku Geka Gakkai Zasshi* 1983;29:2266–2272 (in Japanese).
- 11 Yusa H, Yoshida H, Kikuchi H, Onizawa K. Dialysis-related amyloidosis of the tongue. *J Oral Maxillofac Surg* 2001;59:947–950.

Received June 16, 2003; accepted July 31, 2003

Corresponding author: Masami Shibata