

Yonago Acta medica 2003;46:65–75

# Slow and Fast Oscillation Electrooculography in Central Retinal Vein Occlusion: A Comparison between Affected Eyes and Fellow Intact Eyes

Machiko Inoue, Akihiko Tamai\*, Shiro Hatta† and Yuji Sasaki†

*Clinic of Ophthalmology, Hamada National Hospital, Hamada 697-8511, \*Clinic of Ophthalmology, Hino Hospital Association Hino Hospital, Tottori 689-4504 and †Division of Ophthalmology and Visual Science, Department of Medicine of Sensory and Motor Organs, School of Medicine, Tottori University Faculty of Medicine, Yonago 683-8504 Japan*

Using an automated electrooculograph, the Nidek EOG-2, slow and fast oscillations (SO and FO) of an electrooculogram (EOG) were recorded in 21 patients with unilateral, ischemic central retinal vein occlusion (CRVO). Patient age ranged from 49 to 81 years (average: 68 years of age). Fellow eyes in all patients were intact, and served as controls. Results showed that the  $L/D_{SO}$  (the light peak/dark trough ratio of the SO), the  $Rf_{FO}$  [the average ratio in percentage of the maximum amplitude in the dark period (AD)/the minimum amplitude in the light period (AL) during FO measurement], the  $df_{FO}$  (the average difference in  $\mu V$  between AD and AL), and the  $df/m_{FO}$  [the percentage ratio of the  $df_{FO}$  to the average amplitude of AD + AL (m)] were significantly decreased in the affected eyes compared with the fellow eyes. These results suggest that with regard to SO and FO origin and occurrence, the outer layer of the retina, especially the basal membrane of the retinal pigment epithelium or the choroid may be involved in the etiology of CRVO. These findings correlate with the grade of microcirculatory disturbance or ischemia in the inner layer of the retina. Furthermore, a statistically significant difference was detected in the correlation between each FO parameter and corrected visual acuity at the time of examination of the affected eyes. There was no significance between the SO parameter and the visual acuity. Therefore, it might be possible to presume that the FO parameters can be used as indicators for detecting the severity of macular functional disturbance and predicting the visual outcome for this entity.

**Key words:** central retinal vein occlusion; electrooculogram; fast oscillation; retinal pigment epithelium; slow oscillation

Central retinal vein occlusion (CRVO) results from a thrombotic occlusion, most commonly due to arteriosclerosis-related thrombus at the level of the

lamina cribrosa. CRVO provides 2 forms of clinical presentation, that is, a mild form of non-ischemic CRVO (also known as partial, incomplete, hyper-

Abbreviations: AD, maximum amplitude in the dark period; AL, minimum amplitude in the light period during FO measurement; BRVO, branch retinal vein occlusion; CRAO, central retinal arterial occlusion; CRVO, central retinal vein occlusion;  $df_{FO}$ , average difference in  $\mu V$  between AD and AL during the FO measurement;  $df/m_{FO}$ , percentage ratio of the  $df_{FO}$  to the average amplitude of AD + AL (m); EOG, electrooculogram; ERG, electroretinogram; FO, fast oscillation;  $L/D_{SO}$ , light peak/dark trough ratio of the SO;  $Rf_{FO}$ , average ratio in percentage of AD/AL; SO, slow oscillation

permeable or venostatic retinopathy), and a severe form of ischemic CRVO (complete or hemorrhagic CRVO) (Hayreh, 1983; Ohba, 2002).

Clinical and experimental evidence indicates that non-ischemic CRVO is caused by a mild occlusion of the central retinal vein, but that ischemic CRVO is caused by a severe or complete occlusion of the central retinal vein associated with retinal ischemia or significant hypoxia (Hayreh et al., 1989). In a histopathologic study, Green and others (1981) found that 13.8% of CRVO patients were associated with central retinal arterial occlusion (CRAO), and 10.8% with branch retinal artery occlusion. Although the central retinal artery supplies blood only to the inner retinal layers, simultaneous occlusion of the central retinal vein and artery results in damage to all layers of the retina, including the retinal pigment epithelium.

The electroretinogram (ERG) is reported to be helpful in predicting a visual prognosis in CRVO because its response is sensitive to retinal ischemia (Henkes, 1953; Sabates et al., 1983; Sakane et al., 1989; Ohn et al., 1991) which may be one of the important factors for visual outcome. The ordinary slow oscillation (SO) of the electrooculogram (EOG) on the other hand reflects the function of the retinal pigment epithelium and photoreceptor complex, and appears to be unrelated to the neural network whose function is controlled mainly by retinal circulation. However, it is well established that the EOG becomes very abnormal in CRAO, the severest form of retinal ischemia, and therefore the EOG appears to be indirectly related to or governed by retinal circulation (Thaler and Heilig, 1977).

Branch retinal vein occlusion (BRVO) does not give proof of any abnormalities on the ERG or EOG unless the lesion is sufficiently large, because the ERG and EOG reflect the mass activity of the retina (Karpe and Uchermann, 1955; Arden et al., 1962; Hara and Nagatomo, 1995). On the contrary, in his original description of the EOG, Arden described a patient with CRVO whose EOG was severely deteriorated (Arden et al., 1962). Carr and Siegel (1964) found abnormal EOGs in CRVO where the ERG remained relatively normal. Ashworth (1966) reported 4 patients with CRVO,

all of whom had deteriorated EOGs in varying degrees. Papakostopoulos and others (1992) reported that the light peak/dark trough ratio of the SO ( $L/D_{SO}$ ) of the EOG (Arden et al., 1962) was significantly reduced in the affected eyes of a group of patients with CRVO compared with the unaffected fellow eyes.

The fast oscillation (FO) of the EOG, which is the rapid initial deflection of opposite polarity occurring at the initial stage of the light and dark periods in the EOG procedure (Kolder and Brecher, 1966) also showed abnormal FO patterns in patients with ischemic retinopathy or CRAO (Thaler et al. 1977; Tamai et al., 1997).

Our previous study in patients with BRVO or CRVO (Tamai et al., 1997) suggests that analysis of the SO and FO of the EOG may provide information regarding the dysfunction of the stratiform layer in the affected retina (Hara et al., 1991) and choroid.

In the present study, the SO and FO variables are compared with those of the contralateral intact eyes in patients with unilateral, ischemic CRVO, with special emphasis on the corrected visual acuity at the time of EOG examination of the affected eyes.

## Patients and Methods

### *Patient selection*

Twenty-one patients (12 men, 9 women; age range 49–81 years, mean 68 years) with unilateral, ischemic CRVO were randomly chosen for EOG recording over the past 4 years (August 1996 to September 2000) at the Department of Ophthalmology, Tottori University Hospital (Table 1). Under the ophthalmoscope, it was revealed that their fundi in the affected side showed a flame-shaped bleeding in the whole retina and a remarkable papilloedema, associated with dilated and tortuous retinal veins and lots of cotton-wool patches. Fluorescein angiography revealed evidence of extensive retinal capillary non-perfusion in their fundi. Duration from onset estimated to be 5 to 167 days averaging 30.9

**Table 1. Clinical data of 21 patients with unilateral, ischemic CRVO at the time of EOG examination**

Patient number	Age (year)	Sex	Affected eye	Duration from onset (day)	Corrected visual acuity	General complication
1	74	Female	Right	34	0.1	Hypertension
2	68	Male	Left	26	0.1	Hypertension
3	54	Female	Left	11	1.2	
4	71	Male	Left	58	0.01	
5	66	Male	Left	5	0.1	Hypertension
6	73	Female	Right	8	0.7	Hypertension
7	68	Female	Left	39	0.2	
8	60	Male	Right	10	0.3	Hypertension
9	71	Male	Right	21	0.02	
10	81	Female	Left	14	CF*	
11	78	Female	Right	123	0.5	
12	72	Male	Right	13	0.02	
13	49	Male	Right	32	0.04	Hypertension
14	63	Male	Left	12	0.4	
15	70	Female	Left	167	0.01	
16	59	Male	Right	8	0.01	Hypertension
17	71	Male	Left	17	0.06	Hypertension
18	81	Female	Right	6	0.04	
19	74	Female	Left	15	0.01	
20	68	Male	Right	16	0.1	
21	58	Male	Left	14	0.5	Hypertension

\*CF, counting figures: estimated to be 0.001.

days at the time of EOG examination. Nine out of the 21 patients had hypertension as a general complication (Table 1). Fellow eyes in all patients were ophthalmoscopically and fluorescein-angiographically intact, and served as controls.

Patients were excluded from this study if they had an opaque media, a bilateral refractive error difference of more than 3 diopters, diabetes mellitus or a history of ocular surgery, photocoagulation, anticoagulant therapy or fibrolytic therapy.

### **SO and FO recordings**

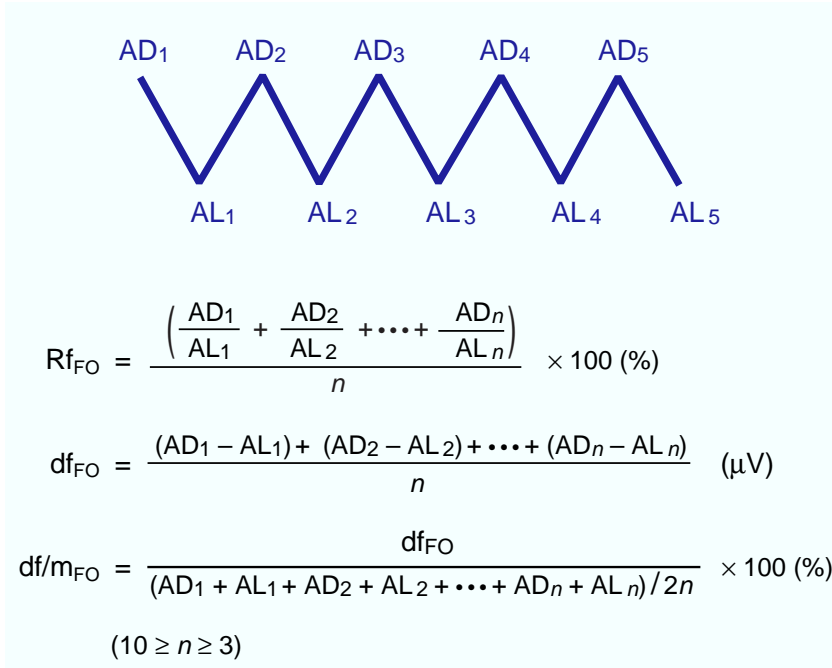
Using a newly devised automated electrooculograph, the Nidek EOG-2 (Nidek, Gamagori, Japan) (Nakao et al., 1995), the SO and FO were recorded in each patient. The EOG-2 consists of a dome, a personal computer, an index controller, an amplifier, a printer and an EOG pen recorder. Inside the dome is a hemispheric screen with a radius of 300 nm. Four tungsten lamps (115 V, 50 W) produce a

background luminance of 1,270 lux, when measured at the location of the patient's eyes.

For every patient, cup-shaped silver-silver chloride conductive electrodes, 8 mm in diameter, were placed beside both canthi of each eye on the orbital margin, and a grounding electrode, with the same cup shape, was placed on the left earlobe, as routinely used. Before setting these electrodes, the skin was cleaned with 90% alcohol, and then electrodes were applied with a conductive paste. Electrode resistance was below 10 k $\Omega$ .

Before SO recording, a 10-min adaptation period at a background luminance level of 1,270 lux was given to the patients. Then the patients were instructed to fixate alternately on a pair of targets on the screen inside the dome. The 2 targets subtended 40° to the eye, and were presented alternately with a frequency of 0.5 Hz.

On the SO recording, where 20 min of darkness was followed by 20 min of illumination, EOG measurements were started 40 s before the end of



**Fig. 1.** Fast oscillation (FO) parameters, the  $Rf_{FO}$ , the  $df_{FO}$  and the  $df/m_{FO}$ , calculated in this survey. AD, maximum amplitude during the dark period; AL, minimum amplitude in the light period during FO measurement;  $n$ , number of cycles (dark-light period of 1 min each), 10 cycles in total.

each 1-min period during the dark and light adaptations. Six out of 10 EOG amplitudes were automatically averaged and recorded every 1 min through the EOG artifact rejection system on the Nidek EOG-2. Twenty out of the 21 patients gave reliable data on the test.

The SO shows a trough in the dark adaptation (dark trough) and a peak in the light adaptation (light peak) in response to dark and light periods of approximately 12.5 min each. The  $L/D_{SO}$  developed by Arden and others (1962) was automatically calculated as an SO parameter in the present survey.

Then the FO was recorded in all patients. Before the FO recording, the patients were subjected to a 10-min pre-light adaptation in the same manner as in the SO recording. The 2 targets subtended 40° to the eye, and were presented alternately with a frequency of 0.5 Hz. The dome was periodically illuminated for 1 min followed by 1 min of darkness. The measurements were started 40 s after each dark or light period began. There were 10 measurements in each dark or light period as in the SO recording. The mean of the 6 EOG amplitudes recorded at the end of each dark or light period was automatically calculated.

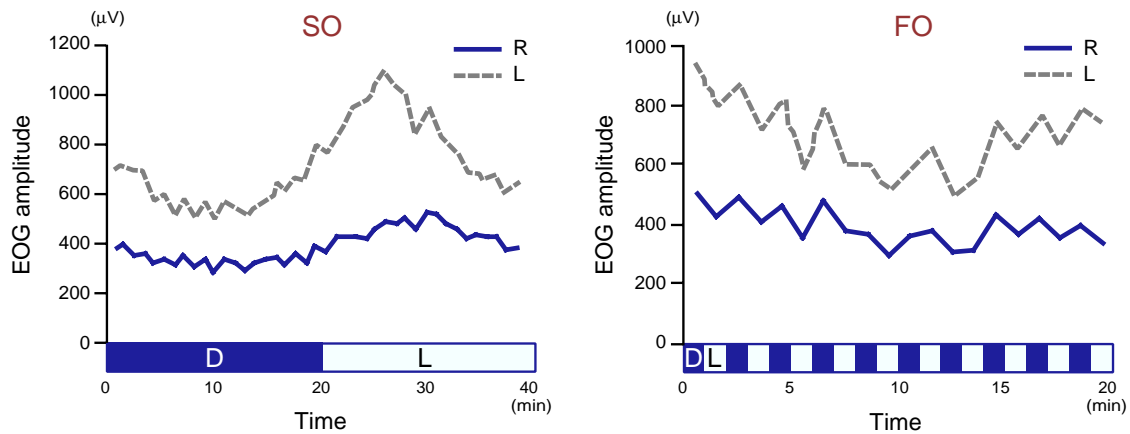
In this study, the calibration sensitivity for the pen recorder was 200  $\mu V$ /division on the printer.

The time constant of the amplifier was set at 3 s, and a high frequency cutoff of -3 dB was set at 20 Hz for both SO and FO recordings.

Pupillary dilation provides better control of retinal illumination levels, but prolongs the time for the EOG examination and may make the examination somewhat more uncomfortable for some patients. Therefore, the SO and FO recordings were performed with pupils undilated.

The FO parameters were calculated referring to the report by De Rouck and Kayembe (1981). Namely, the  $Rf_{FO}$ , which is the average ratio in percentage of the maximum amplitude in the dark period (AD)/the minimum amplitude in the light period (AL), and the  $df_{FO}$ , which is the average difference in  $\mu V$  between AD and AL during the FO measurement, were calculated in addition to a newly designed  $df/m_{FO}$ , which is the percentage ratio of the  $df_{FO}$  to the average amplitude of AD + AL (m), only if at least 3 successive steps showed some identical amplitude change (Fig. 1). Dated and occasional large amplitude changes were not taken into account. In the  $df/m_{FO}$ , the influence of fluctuation of the base value to the FO pattern is supposed to be minimized compared to the  $df_{FO}$  (Nakao et al., 1995; Tamai et al., 1997).

## EOG slow and fast oscillations in CRVO

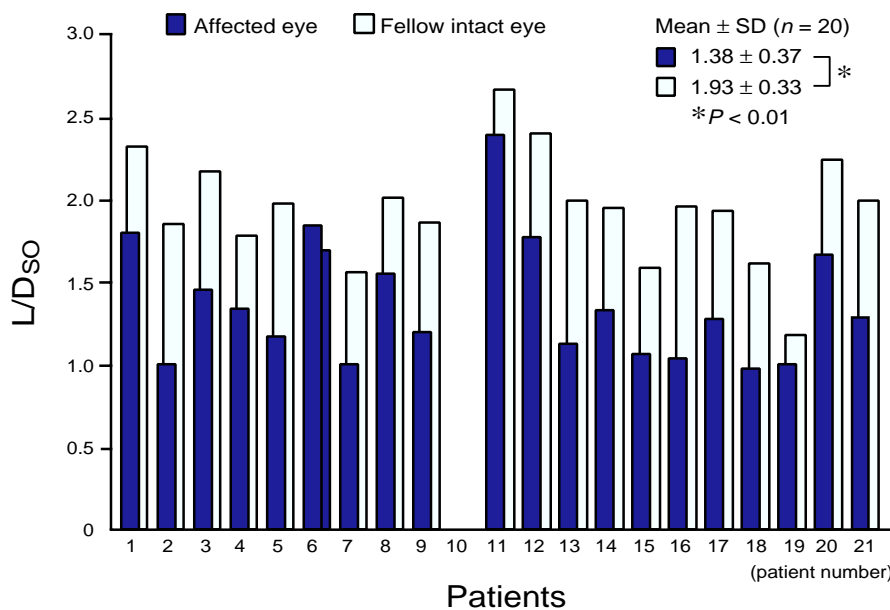


**Fig. 2.** EOG slow oscillation (SO) and fast oscillation (FO) patterns in both eyes of Patient 8 (60-year-old male, ischemic CRVO patient). R, right eye (affected side); L, left eye (fellow intact side). D, dark period; L, light period (horizontal axis).

All values were expressed as mean  $\pm$  SD. Statistical analysis was performed with Mann-Whitney's *U* test. Spearman's rank coefficient of correlation test was applied for correlation analysis. A *P* value of  $< 0.05$  was considered statistically significant.

## Results

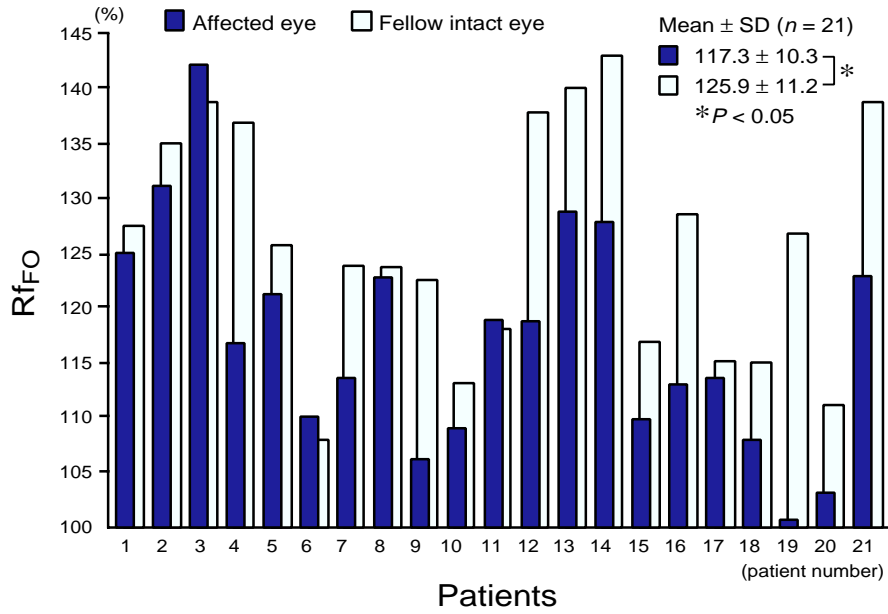
Practical EOG SO and FO patterns in both eyes of Patient 8 (a 60-year-old male patient with unilateral, ischemic CRVO) are demonstrated in Fig. 2. In this patient, reduced or deteriorated SO and FO patterns were observed in his affected eye (right eye), although his fellow intact eye (left eye) showed normal patterns in both recordings.



**Fig. 3.** Distribution of the  $L/D_{SO}$  of the EOG in 20 affected and fellow intact eyes of 20 patients with ischemic CRVO. The ratios in Patient 10 were omitted due to unreliable data.

### *L/D<sub>SO</sub>*

Figure 3 shows the distribution of the  $L/D_{SO}$  in 20 affected and fellow intact eyes of 20 patients with ischemic CRVO excluding 1 patient (Patient 10), whose data were unreliable. Nineteen out of

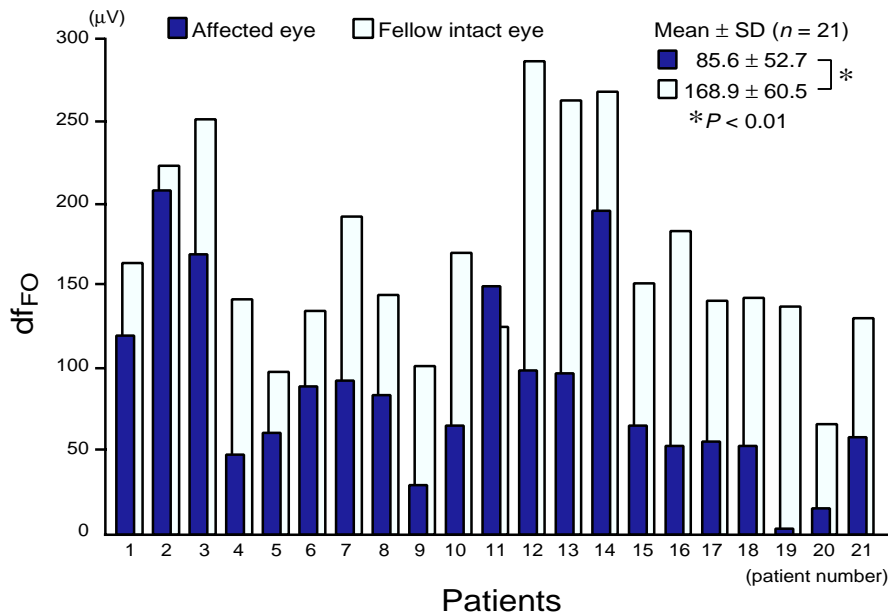


**Fig. 4.** Distribution of the  $Rf_{FO}$  of the EOG in 21 affected and fellow intact eyes of 21 patients with ischemic CRVO.

the 20 patients (95.0%) showed smaller ratios in the  $L/D_{SO}$  in the affected eyes than those in the fellow healthy eyes. The mean of the  $L/D_{FO}$  of all affected eyes was  $1.38 \pm 0.37$  (SD), and of all fellow intact eyes was  $1.93 \pm 0.33$ . This difference is statistically significant ( $P < 0.01$ ).

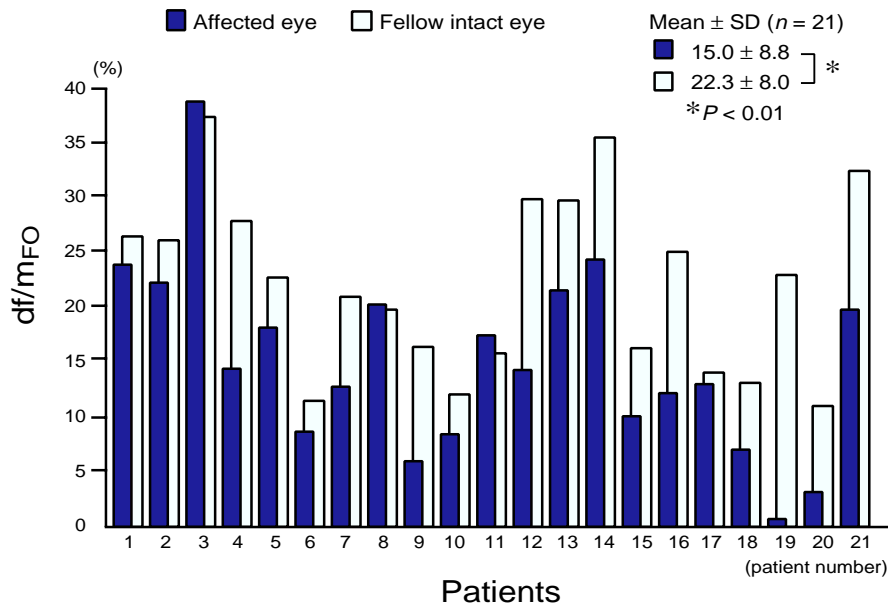
**$Rf_{FO}$**

Figure 4 shows the distribution of the  $Rf_{FO}$  in 21 affected and fellow intact eyes of the 21 patients with ischemic CRVO. Eighteen out of the 21 patients (85.7%) showed smaller values in the  $Rf_{FO}$



**Fig. 5.** Distribution of the  $df_{FO}$  of the EOG in 21 affected and fellow intact eyes of 21 patients with ischemic CRVO.

## EOG slow and fast oscillations in CRVO



**Fig. 6.** Distribution of the  $df/m_{FO}$  of the EOG in 21 affected and fellow intact eyes of 21 patients with ischemic CRVO.

in the affected eyes than those in the fellow healthy eyes. The mean of the  $Rf_{FO}$  of all affected eyes was  $117.3 \pm 10.3\%$ , and of all fellow intact eyes was  $125.9 \pm 11.2\%$ . This difference was statistically significant ( $P < 0.05$ ).

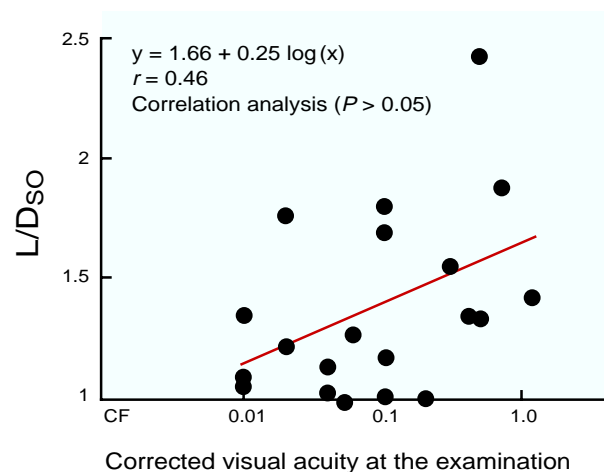
### $df_{FO}$

Figure 5 shows the distribution of the  $df_{FO}$  in 21 affected and fellow intact eyes of the 21 patients with ischemic CRVO. Twenty out of the 21 patients (95.2%) showed smaller values in the  $df_{FO}$  in the affected eyes than those in the fellow healthy eyes. The mean of the  $df_{FO}$  of all affected eyes was  $85.6 \pm 52.7 \mu V$ , and of all fellow intact eyes was  $168.9 \pm 60.5 \mu V$ . This difference was statistically significant ( $P < 0.01$ ).

### $df/m_{FO}$

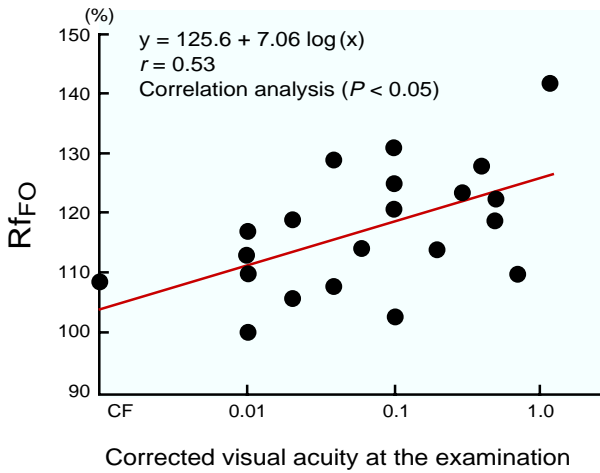
Figure 6 shows the distribution of the  $df/m_{FO}$  in 21 affected and fellow intact eyes of the 21 patients with ischemic CRVO. Eighteen out of the 21 patients (85.7%) showed smaller values in the  $df/m_{FO}$  in the affected eyes than those in the fellow healthy

eyes. The mean of the  $df/m_{FO}$  of all affected eyes was  $15.0 \pm 8.8\%$ , and of all fellow intact eyes was  $22.3 \pm 8.0\%$ . This difference was statistically significant ( $P < 0.01$ ).

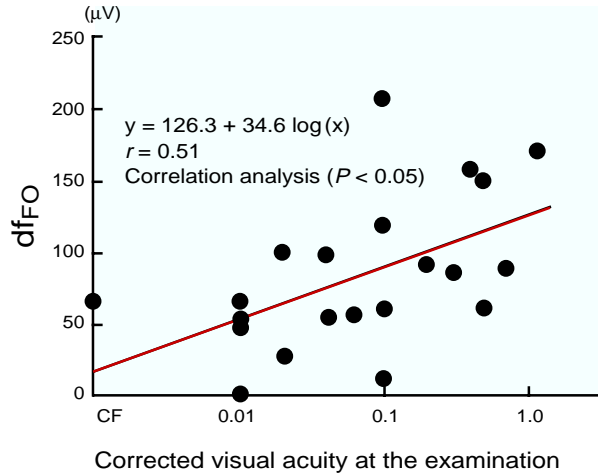


**Fig. 7.** Correlation between the  $L/D_{50}$  and corrected visual acuity at the time of EOG examination in 20 affected eyes of 20 patients with ischemic CRVO. CF, counting fingers (estimated to be 0.001).





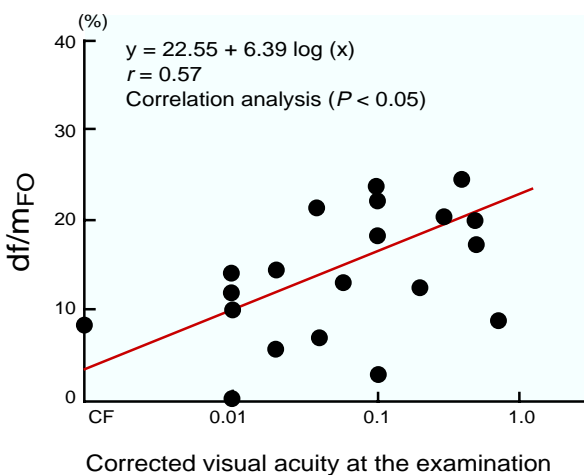
**Fig. 8.** Correlation between the  $Rf_{FO}$  and corrected visual acuity at the time of EOG examination in 21 affected eyes of 21 patients with ischemic CRVO. CF, counting fingers (estimated to be 0.001).



**Fig. 9.** Correlation between the  $df_{FO}$  and corrected visual acuity at the time of EOG examination in 21 affected eyes of 21 patients with ischemic CRVO. CF, counting fingers (estimated to be 0.001).

**Correlations between the SO parameter and corrected visual acuity and between each FO parameter and corrected vision**

No significant difference was detected in the correlation between the SO parameter ( $L/D_{SO}$ ) and corrected visual acuity at the time of EOG examination in the 20 affected eyes of the 20 patients with ischemic CRVO ( $P > 0.05$ ) (Fig. 7).



**Fig. 10.** Correlation between the  $df/m_{FO}$  and corrected visual acuity at the time of EOG examination in 21 affected eyes of 21 patients with ischemic CRVO. CF, counting fingers (estimated to be 0.001).

On the other hand, a statistically significant difference was detected in the correlation between each parameter ( $Rf_{FO}$ ,  $df_{FO}$  and  $df/m_{FO}$ ) and corrected visual acuity at the time of EOG examination in the 21 affected eyes of the 21 patients with ischemic CRVO ( $P < 0.05$ ) (Figs. 8 to 10).

**Discussion**

Arden and others (1962) postulated that the SO is related to slower changes in potential that occur as a result of alterations in the metabolism of the retinal pigment epithelium. They suggested that normal magnitudes of corneoretinal potential are dependent on i) normally functioning photoreceptors, ii) normally functioning retinal pigment epithelium, iii) normal contact between the sensory neuroepithelium and the retinal pigment epithelium and iv) adequate choroidal blood supply.

Concerning the origin and occurrence of the FO, Steinberg and others (1983) reported the involvement of the retinal pigment epithelium, mainly in its basal membrane. Joseph and Miller (1991) suggested that the FO might result from delayed hyperpolarization associated with increased electric resistance in the basal membrane of the retinal pig-



ment epithelium. This delayed basal membrane hyperpolarization may be caused by a decrease in intracellular chloride of the retinal pigment epithelium, which is linked to the light-induced drop in subretinal potassium concentration (Joseph and Miller, 1991).

In the present study, results showed that the  $L/D_{SO}$ , the  $Rf_{FO}$ , the  $df_{FO}$  and the  $df/m_{FO}$  were significantly decreased in the affected eyes of the patients as compared with the fellow intact eyes. These results suggest that with regard to SO and FO origin and occurrence, the outer layer of the retina, especially the basal membrane of the retinal pigment epithelium or the choroid may be involved in the etiology of CRVO. These findings correlate with the grade of microcirculatory disturbance or ischemia in the inner layer of the retina.

As for the influence of retinal bleeding, a decrease in illuminating volume may bring an indirect or direct influence on the EOG responses, especially in patients with hemorrhagic or ischemic CRVO. Its influence seems to be very small and negligible in these patients because their retinal bleeding remains flame-shaped in their fundi.

The EOG responses may be affected by changes in the retrobulbar circulation due to a systemic hypertensive condition more or less associated with occlusive retinal vascular diseases and/or arterial blood flow characteristics, that is, reduction of blood flow velocities in the central retinal and ophthalmic arteries especially in patients with ischemic CRVO, which may be partly related to secondary changes in the retrobulbar circulation as a result of enhanced arterial resistance following CRVO (Anunduk et al., 1999).

With regard to influences from anemia or ischemia, elevation of the osmotic pressure in the subretinal space may bring an unstable retinal pigment epithelium. Decrease of the oxygen quotient may bring a functional insufficiency in the outer retinal layers (Honda, 1996). An increase in the volume of ammonia in the ischemic retina may bring a functional insufficiency of the whole retina due to an overflow of glutamic acid. Oxidized stress after ischemic reperfusion may also bring the

same functional insufficiency of the whole retina due to an overflow of glutamic acid (Honda, 1996).

Furthermore, the participation of nitric oxide (NO) may disturb the condition of the retinal pigment epithelium and Müller's cell (Honda, 1996). An increase in concentration of intracellular calcium ( $[Ca^{2+}]_i$ ) may also bring about cellular damage in occlusive retinal vascular diseases (Honda, 1996). Other reasons, including morphological changes resembling apoptosis-like cell death, have been considered, but the real causes which bring about such EOG changes in these diseases have not yet been elucidated. In any case, the EOG changes may be helpful for better understanding of the pathogenesis of CRVO.

It is of note that a statistically significant difference was detected in the correlation between each FO parameter and corrected visual acuity at the time of EOG examination of the affected eyes of the patients. There was no significance between the SO parameter and the visual acuity. Rods as well as cones contribute to the FO (Welber, 1989), while cones as well as rods contribute to the SO (Arden and Kelsey, 1962; Gouras and Carr, 1965). Therefore, such a cone-dominated activity on the FO in this series is currently unexplainable, but it might be possible to presume that the FO parameters can be used as indicators for detecting the severity of macular functional disturbance and predicting the visual outcome for this entity.

Generally, visual prognosis is obviously poorer in ischemic CRVO than in non-ischemic CRVO due to severe retinal bleeding and edema especially in the macular area. Ischemic CRVO sometimes leads to the recovery of visual acuity in parallel with absorption of retinal bleeding and disappearance of cystoid macular edema after panretinal photocoagulation. Ischemic CRVO often leads to visual disturbance due to vitreous bleeding caused by neovascularization from the retina and optic disk as well as macular edema (Kanski, 1989), and may lead to rubeosis iridis and to potentially painful neovascular glaucoma resulting in visual loss in older persons (Deng et al., 1994; Papakostropoulos et al., 1992).

Further work is required to investigate these aspects and the variation of the EOG with time, for the results above represent readings taken at only one point in the natural history of the condition.

*Acknowledgments:* The authors thank Professor Yoshitsugu Inoue, Division of Ophthalmology and Visual Science, Department of Medicine of Sensory and Motor Organs, School of Medicine, Tottori University Faculty of Medicine, for his generous help.

### References

- 1 Arden GB, Barrada A, Kelsey JH. New clinical test of retinal function based upon the standing potential of the eye. *Br J Ophthalmol* 1962;46:449–467.
- 2 Arden GB, Kelsey JH. Some observations on the relationship between the standing potential of the human eye and the bleaching and regeneration of visual purple. *J Physiol* 1962;161:201–226.
- 3 Ashworth B. The electro-oculogram in disorders of the retinal circulation. *Am J Ophthalmol* 1966;61:505–508.
- 4 Avunduk AM, Dinç H, Kapicioğlu Z, Uğurlu S, Dayanir V, Korkmaz E. Arterial blood flow characteristics in central retinal vein occlusion and effects of panretinal photocoagulation treatment: an investigation by color Doppler imaging. *Br J Ophthalmol* 1999;83:50–53.
- 5 Carr RE, Siegel IM. Electrophysiologic aspects of several retinal diseases. *Am J Ophthalmol* 1964;58:95–107.
- 6 Deng Y, Zhou H, Duan J. Electro-oculogram of retinal vein occlusion. *Eye Science* 1994;10:60–64.
- 7 De Rouck, Kayembe D. A clinical procedure for the simultaneous recording of fast and slow EOG oscillations. *Int Ophthalmol* 1981;3:179–189.
- 8 Gouras P, Carr RE. Cone activity in the light-induced DC response of monkey retina. *Invest Ophthalmol Vis Sci* 1965;4:318–321.
- 9 Green WR, Chan CC, Hutchins GM, Terry JM. Central retinal vein occlusion: a prospective histopathologic study of 29 eyes in 28 patients. *Trans Am Ophthalmol Soc* 1981;79:371–422.
- 10 Hara A, Nagatomo M. Branch retinal vein occlusion decreases the potential of the inner retinal layer. *J Nippon Med Sch* 1995;62:50–54 (in English).
- 11 Hara A, Nohmi M, Sato M. Electrooculogram in retinal branch vein occlusion. *Ganka Rinsho Iho* 1991;85:123–126 (in Japanese with English abstract).
- 12 Hayreh SS. Classification of central retinal vein occlusion. *Ophthalmology* 1983;90:458–474.
- 13 Hayreh SS, Klugman MR, Podhajsky P, Kolder HE. Electroretinography in central retinal vein occlusion. Correlation of electroretinographic changes with pupillary abnormalities. *Graefes Arch Clin Exp Ophthalmol* 1989;27:549–561.
- 14 Henkes HE. Electroretinography in circulatory disturbances of the retina. I. Electroretinogram in cases of occlusion of the central retinal vein or one of its branches. *Arch Ophthalmol* 1953;49:190–201.
- 15 Honda Y. Cellular and molecular biology of ischemic retina. *Nippon Ganka Gakkai Zasshi* 1996;100:937–955 (in Japanese with English abstract).
- 16 Joseph DP, Miller SS. Apical and basal membrane ion transport mechanisms in bovine retinal pigment epithelium. *J Physiol* 1991;435:439–463.
- 17 Kanski JJ. Retinal vein occlusion. Clinical ophthalmology. 2nd ed. London: Butterworths; 1989. p. 318–328.
- 18 Karpe G, Uchermann A. The clinical electroretinogram. *Acta Ophthalmol* 1955;33:156–493.
- 19 Kolder HE, Brecher GA. Fast oscillations of the corneoretinal potential in man. *Arch Ophthalmol* 1966;75:232–237.
- 20 Nakao H, Miki N, Nagata M, Sasaki Y, Yamasaki A, Endo M, et al. Fast oscillations of the electro-oculogram in a series of normal subjects. *Jpn J Ophthalmol* 1995;39:113–119.
- 21 Ohba N. Central retinal vein occlusion. Essential atlas of retinal diseases. Kagoshima: Shibundo; 2002. p. 35–36.
- 22 Ohn Y-H, Katsumi O, Kruger-Leite E, Larson EW, Hirose T. Electrooculogram in central retinal vein occlusion. *Ophthalmologica* 1991;203:189–195.
- 23 Papakostopoulos D, Bloom PA, Gray RHB, Dean Hart JC. The electro-oculogram in central retinal vein occlusion. *Br J Ophthalmol* 1992;76:515–519.
- 24 Sabates R, Hirose T, McMeel JW. Electroretinography in the prognosis and classification of central retinal vein occlusion. *Arch Ophthalmol* 1983;101:232–235.
- 25 Sakane H, Katsumi O, Hirose T. Electroretinographic findings in fellow eyes of patients with central retinal vein occlusion. *Arch Ophthalmol* 1989;107:1459–1462.
- 26 Steinberg Rh, Linsenmeier RA, Griff ER. Three light-evoked responses of the retinal pigment epithelium. *Vision Res* 1983;23:1315–1323.
- 27 Tamai A, Sasaki Y, Inoue M, Hamamoto J, Kumagami T, Setogawa A, et al. Clinical application of fast oscillation of electro-oculogram. *Ganka*

## EOG slow and fast oscillations in CRVO

- Rinsho Iho 1997;91:535–538 (in Japanese with English abstract).
- 28 Thaler A, Heilig P. EOG and ERG components in ischemic retinopathy. *Ophthalmic Res* 1977;9:38–46.
- 29 Thaler A, Heilig P, Scheiver V. Fast oscillation of the corneoretinal potential in ischemic retinopathy. *Ophthalmic Res* 1977;9:324–328.
- 30 Welber RG. Fast and slow oscillations of the electro-oculogram in Best's macular dystrophy and retinitis pigmentosa. *Arch Ophthalmol* 1989;107: 530–537.

*Received May 28, 2003; accepted July 16, 2003*

*Corresponding author: Akihiko Tamai, MD*