

Bilateral Multiple Pulmonary Sclerosing Hemangioma in a Young Male Patient

Kenichiro Miyoshi, Hiroshige Nakamura*, Ken Miwa*, Yoshin Adachi*, Shinji Fujioka*, Yuji Taniguchi* and Yasushi Horie†

*Center for Clinical Residency Program, *Division of General Thoracic Surgery and †Pathology Division, Tottori University Hospital, Yonago 683-8504 Japan*

The patient was a 24-year-old male who visited our University Hospital complaining of chest pain, and chest computed tomography revealed multiple bilateral nodules. The chest pain disappeared almost immediately, but the tumor underwent no changes during the 3 years of follow-up observations. We used a thoracoscope to perform a partial lung resection of a nodule that reached a maximum diameter of 9 mm for the purpose of obtaining a definite diagnosis. From the pathological findings, the patient was diagnosed to have pulmonary sclerosing hemangioma in which circular tumor cells lacking nuclear atypia rose to papillary hyperplasia. The mindbomb homolog-1 positive rate (MIB-1 index) of the tumor cells was less than 1%, and it is believed to have a poor proliferation activity. Pulmonary sclerosing hemangioma is predominantly found in cases of middle-aged female patients and occurs unilaterally. Cases of bilateral multiple forms in young males are extremely rare. Some cases of enlargement, metastasis and relapse have also been reported, so in the future, careful follow-up is required.

Key words: bilateral multiple lung nodule; sclerosing hemangioma; video-assisted thoracic surgery; young male

Cases of pulmonary sclerosing hemangioma are commonly found to occur unilaterally in middle-aged females. In this study, we experienced an extremely rare case of bilateral multiple pulmonary sclerosing hemangioma in a young male, and we hereby present our results, together with a number of bibliographical considerations.

Patient Report

The patient was a 24-year-old male. By chest computed tomographic scan performed to address his major complaint of chest pain, well-circumscribed multiple small circular nodules with a maximum diameter of 9 mm were observed in

both lungs. There were no differences between the right and left nodules, but they were mostly found in the lower lobe, and their interiors were even and showed no calcification. No contrast effects were observed (Figs. 1A and B). The chest pain disappeared almost immediately, but there were no changes in the number or the size of the nodules during the 3 years of follow-up observation. All inflammatory reactions and tumor markers showed normal ranges in the blood examinations, and the patient tested negative for aspergillus antigen and cryptococcal antigen analyses. Upon obtaining the patient's informed consent, we performed surgery to obtain a definite diagnosis, because the patient was still young and we were unable to rule out the possibility of

Abbreviation: MIB-1 index, mindbomb homolog-1 positive rate

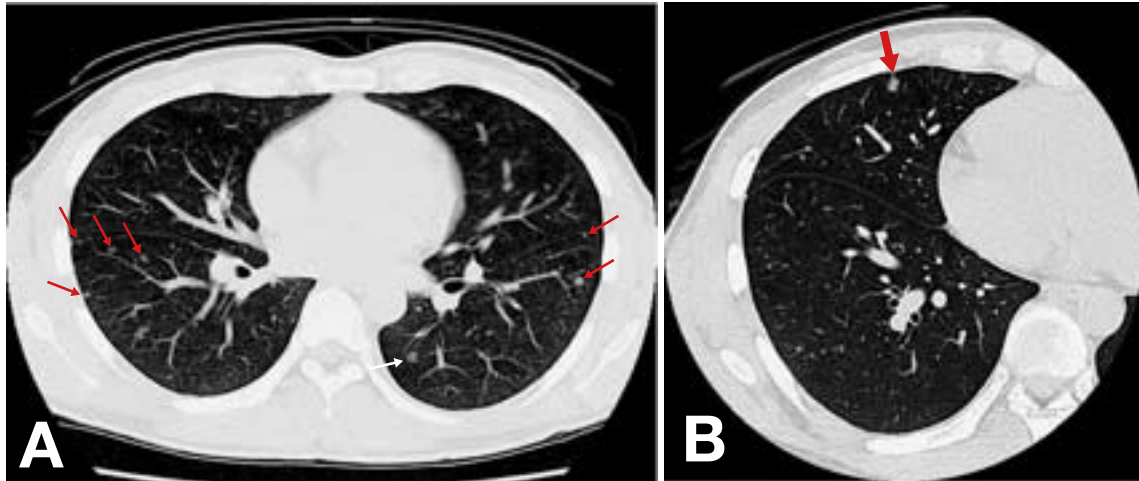


Fig. 1. Chest computed tomographic scan reveals well-circumscribed multiple small circular nodules (arrows) in both lungs (A). They are mostly found in the lower lobe (A). A nodule with the maximum diameter of 9 mm (arrow) is observed in the right middle lobe (B).

a malignant tumor or an infectious lesion. Thoracoscopic observations identified multiple small nodules with the same appearance that were 3 to 5 mm in size immediately under the pleural membrane, so using a thoracoscope, we performed the partial lung resection of a nodule with the largest diameter, located in the right median lobe. The resected tumor was 9 × 8 mm in size with a flat, smooth surface and a solid interior (Fig. 2). From

the histopathological findings, the patient was diagnosed with pulmonary sclerosing hemangioma, because the circular tumor cells that had poor nuclear atypia rose to papillary hyperplasia (Figs. 3A and B). In an immunohistochemical test, thyroid transcription factor-1 and surfactant apoprotein A tested positive, and the mindbomb homolog-1 positive rate (MIB-1 index) was less than 1%. No significant lesion has been observed, with respect to the size and the number of the remaining tumors, 6 months after surgery.

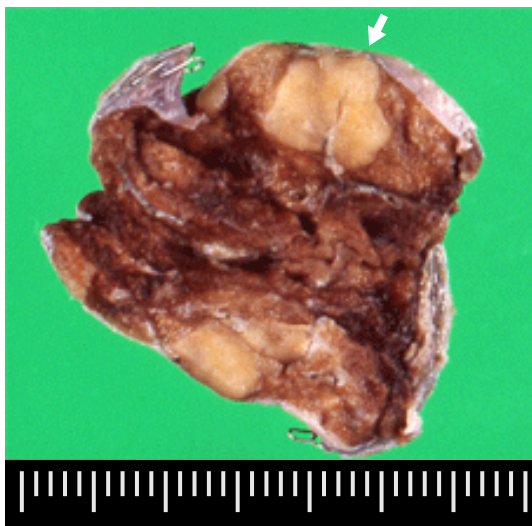


Fig. 2. The resected tumor (arrow) in the right middle lobe is 9 × 8 mm in size with a flat, smooth surface and a solid interior.

Discussion

Pulmonary sclerosing hemangioma was first reported by Liebow and Hubble in 1956. The frequency of the occurrence thereof accounted for approximately 1% of all pulmonary tumors, following hamartoma among the benign tumors, but more than 80% of all cases occur in female patients who are mostly in their 40s (Iyoda et al., 2004). The majority of these cases are asymptomatic, but coughing, chest pain and bloody sputum are also observed in symptomatic cases (Kaltzenstein et al., 1983; Iyoda et al., 2004). There are various views regarding the histogenesis such

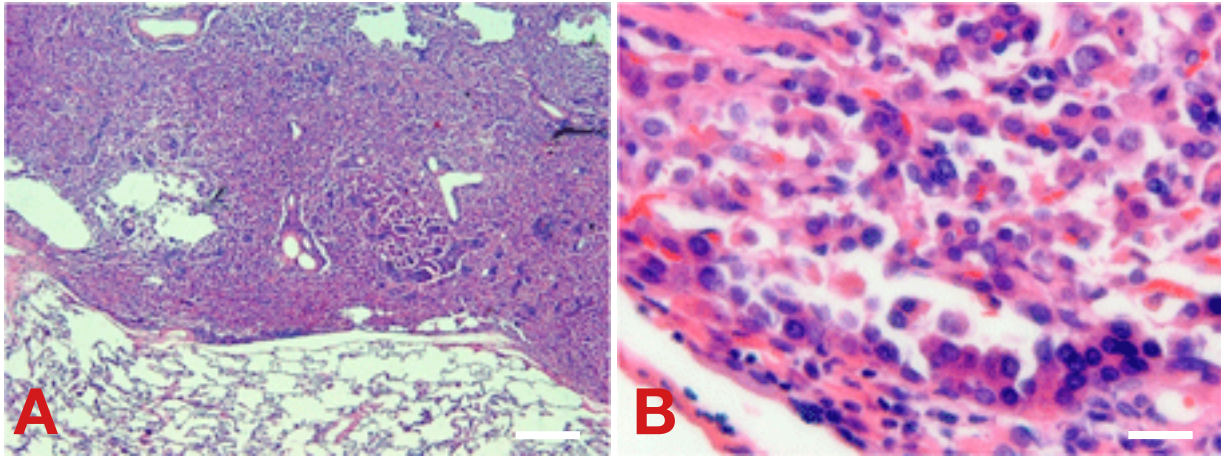


Fig. 3. Pathological examination shows circular tumor cells with poor nuclear atypia rising to papillary hyperplasia with hematoxylin and eosin staining of low power field (**A**: bar = 500 µm) and high power field (**B**: bar = 50 µm).

as mesothelial origin (Kaltzenstein et al., 1983), hystiocyte origin (Nagata et al., 1985) or alveolar epithelium origin (Yousem et al., 1988). This case also tested positive for thyroid transcription factor-1 and surfactant apoprotein A, and the findings could be defined as an alveolar epithelial tumor (Chan and Chan, 2000). The incidence rate of multiple occurrences is very low, accounting for approximately 5% of all occurrences (Liebow and Hubble, 1956; Noguchi et al., 1986). Hypotheses regarding cases of multiple occurrences include the multicentric occurrence hypothesis and the intrapulmonary metastasis hypothesis, but no specific conclusion has yet been reached (Noguchi et al., 1986; Hanaoka et al., 2005). In Japan, there have been 29 cases of multiple occurrences, of which only 5 cases were of male patients (Inoue et al., 2007). This is the 6th case of a multiple occurrence found in a male in Japan, but we believe that this is the 1st case of a bilateral occurrence in a patient in his 20s. It has been reported during follow-up after a resection that pulmonary sclerosing hemangioma can occasionally lead to the rapid enlargement and metastasis of lymph nodes and relapse (Tanaka et al., 1986; Katakura et al., 2005). Jungraithmayr et al. (2006) also described that sclerosing hemangioma of the lung is a benign tumor with potential for malignancy. The MIB-1 index of the tumor cells in this case was

less than 1%, and it is believed to have a low proliferation activity (Filiz et al., 2007). However, this was a case of early onset: we therefore need to perform careful follow-up examinations in the future.

Reference

- 1 Chan AC, Chan JK. Pulmonary sclerosing hemangioma consistently expresses thyroid transcription factor-1 (TTF-1): a new clue to its histogenesis. *Am J Surg Pathol* 2000;24:1531–1536.
- 2 Filiz G, Yalçinkaya O, Gürel S, Yerci O, Memik F. The relationship between MIB-1 proliferative activity and mitotic index in gastrointestinal stromal tumors. *Hepatogastroenterology* 2007;54:438–441.
- 3 Hanaoka J, Ohuchi M, Inoue S, Sawai S, Tezuka N, Fujino S. Bilateral multiple pulmonary sclerosing hemangioma. *Jpn J Thorac Cardiovasc Surg* 2005;53:157–161.
- 4 Inoue Y, Ohiwa K, Nakagawa T, Matsuda R, Maitani F, Yamada S, et al. Multiple sclerosing hemangiomas of the lung arising in a man. *Nippon Kokyukigeka Gakkai Zasshi* 2007;21:825–828 (in Japanese with English abstract).
- 5 Iyoda A, Hiroshima K, Shiba M, Haga Y, Moriya Y, Skine Y. Clinicopathological analysis of pulmonary sclerosing hemangioma. *Ann Thorac Surg* 2004;78:1928–1931.
- 6 Jungraithmayr W, Eggeling S, Ludwig C, Kayser G, Passlick B. Sclerosing hemangioma of the lung: a benign tumour with potential for malignancy? *Ann Thorac Cardiovasc Surg* 2006;12:352–354.
- 7 Kaltzenstein AL, Weise DL, Fulling K, Battifora H.

- So-called sclerosing hemangioma of the lung. Evidence for mesothelial origin. *Am J Pathol* 1983;7:3–14.
- 8 Katakura H, Sato M, Tanaka F, Sakai H, Bando T, Hasegawa S, et al. Pulmonary sclerosing hemangioma with metastasis to the mediastinal lymph node. *Ann Thorac Surg* 2005;80:2351–2353.
 - 9 Liebow AA, Hubble DS. Sclerosing hemangioma (histiocytoma, xantoma) of the lung. *Cancer* 1956;9:53–75.
 - 10 Nagata N, Dairaku M, Ishida T, Sueishi K, Tanaka K. Sclerosing hemangioma of lung. Immunohistochemical characterization of its origin as related to surfactant apoprotein. *Cancer* 1985;55:116–23
 - 11 Noguchi M, Kodama T, Morinaga S, Shimosato Y, Saito T, Tsuboi E. Multiple sclerosing hemangiomas of the lung. *Am J Surg Pathol* 1986;10:429–435.
 - 12 Tanaka I, Inoue M, Matsui Y, Oritsu S, Akiyama O, Takemura T, et al. A case of pneumocytoma (so-called sclerosing hemangioma) with lymph node metastasis. *Jpn J Clin Oncol* 1986 16:77–86.
 - 13 Yousem SA, Wick MR, Singh G, Katyal SL, Manivel JC, Mills SE, et al. So-called sclerosing hemangiomas of lung. An immunohistochemical study supporting a respiratory epithelial origin. *Am J Surg Pathol* 1988;12:582–90.

Received December 21, 2007; accepted January 11, 2008

Corresponding author: Hiroshige Nakamura, MD