

Vacuum-Assisted Closure (VAC) for Bilateral Severe Ischemic Foot after Revascularization: A Patient Report

Kengo Nishimura, Yasushi Kanaoka, Shingo Harada, Munehiro Saiki, Akira Marumoto, Yoshinobu Nakamura and Motonobu Nishimura

Division of Organ Regeneration Surgery, Department of Surgery, School of Medicine, Tottori University Faculty of Medicine, Yonago 683-8053 Japan

The Vacuum-Assisted Closure (VAC) Therapy (KCI, San Antonio, TX) is a unique system that helps promote wound healing. We report a case of severe ischemic foot in which VAC therapy markedly improved wound healing. A 73-year-old man underwent left axillopopliteal bypass and left 3rd, 4th and 5th digital amputations for gangrene. Although his amputation stumps were complicated with methicillin-resistant *Staphylococcus aureus* (MRSA) infection, the stumps were successfully healed by VAC. He also had gangrene in his right 1st toe, which could not be healed by VAC alone, and we performed right femoropopliteal bypass and right 1st digital amputation. The stump with MRSA infection was also successfully healed by VAC. Histopathologic examination revealed a lot of microvessels in the increased granulation tissue.

Key words: peripheral aortic disease; severe ischemic foot; vacuum-assisted closure

Patient Report

The patient was a 73-year-old man, who had a history of a right common iliac artery-right common femoral artery bypass in 1989. He had been treated medically for rest pain of his left foot in a local hospital since August, 2003. He was referred to our hospital on November 22, 2005. Physical examination was unremarkable except for gangrene in part of his left 3rd, 4th and 5th toes as well as a mild ulceration on the tip of his right 1st toe. No pulse was identified in either lower extremity except for the right femoral pulse. The Ankle Brachial Index (ABI) is a measure of the fall in blood pressure in the arteries supplying the legs and as such is used to detect evidence of blockages (peripheral vascular disease). It is calculated by dividing the systolic blood pressure in the ankle by the higher

of the two systolic blood pressures in the arms. His ABI was 0.34 on the right side and 0.31 on the left. Abdominal computerized tomography showed that abdominal aorta with severe calcification had a stenosis and that occlusion of bilateral common iliac arteries with a patent right common iliac artery-right common femoral artery bypass. Angiography of the lower extremities showed the right superficial femoral artery was occluded from its origin and the popliteal artery was enhanced by the branch of the profunda femoral artery. The left superficial femoral artery was also occluded from its origin, and the left profunda femoral artery and left popliteal artery were enhanced by the branch of the right profunda femoral artery. Bilateral peroneal arteries, and anterior and posterior tibial arteries were patent, although their walls were irregular. We decided to treat the bilateral severe ischemic foot due to arteriosclerotic obliteration.

Abbreviations: ABI, Ankle Brachial Index; MRSA, methicillin-resistant *Staphylococcus aureus*; VAC, vacuum-assisted closure

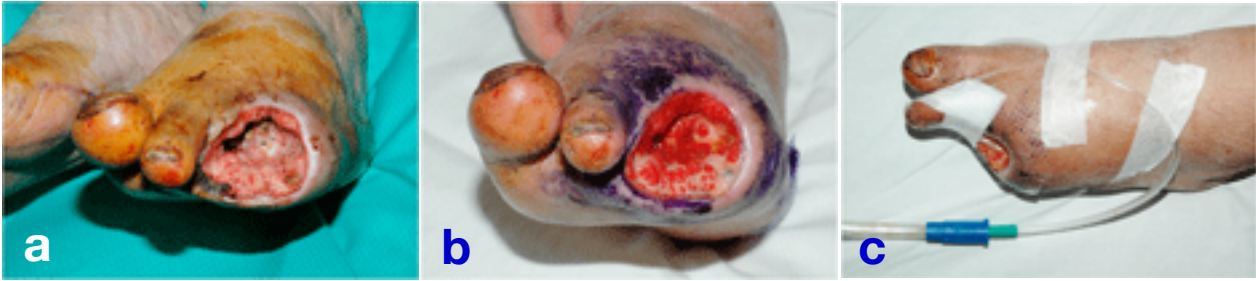

Fig. 1. Although we continued to disinfect and wash the open wound as usual for 30 days, it underwent methicillin-resistant *Staphylococcus aureus* (MRSA) infection and still remained open. **a:** 11 postoperative day. **b:** 30 postoperative day. **c:** A disposable exudates tube was placed at the wound site and a polyurethane film filled the wound including the tube.

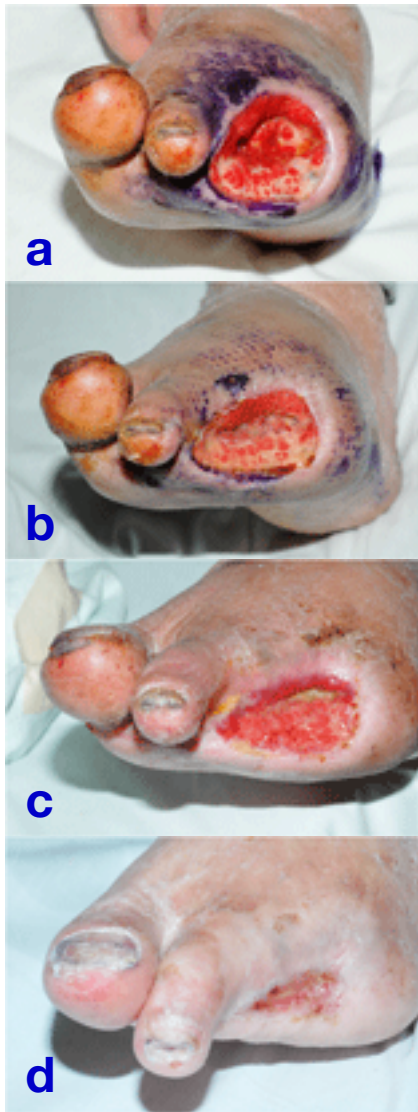

Fig. 2. Effect of the Vacuum-Assisted Closure (VAC) Therapy for the left leg. **a:** Before VAC. **b:** After 1 week of VAC. **c:** After 4 weeks of VAC. **d:** After 14 weeks of VAC.

Left lower extremity

As he had rest pain with gangrene of the left 3rd, 4th and 5th toes, revascularization of the left lower extremity and the resection of diseased toes were performed first. Under general anesthesia, a transverse incision of 10 cm was made below the left clavicle and a longitudinal incision of 7 cm was made in the left lower third of the thigh along the anterior border of the sartorius muscle. Revascularization between the left axillary artery and left proximal popliteal artery was performed with a knitted Dacron graft and resection of the left 3rd, 4th and 5th distal phalanges, middle phalanx and proximal phalanges with stumps open. There was no obvious abscess in the subcutaneous tissue around the distal phalanges.

Postoperative ABI was 1.07 on the left side. However, the stumps were complicated with methicillin-resistant *Staphylococcus aureus* (MRSA) infection and they still remained open 30 days after the operation (Figs. 1a and b). We decided to introduce VAC therapy after approval by the Ethics Committee of Tottori University Faculty of Medicine. A disposable exudates tube was placed at the wound site and a polyurethane film completely covered the wound including the tube (Fig. 1c). Continuous negative pressure of around 125 mmHg was applied to the wound via the tube. The polyurethane film and tube were changed twice a week. VAC rapidly accelerated wound closure in only one week. However, VAC

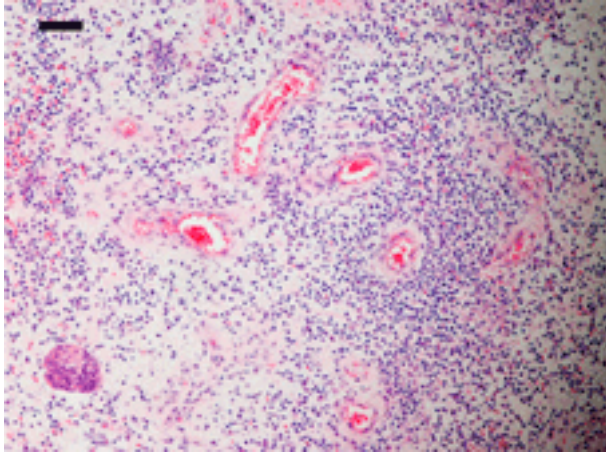


Fig. 3. There were a lot of capillary vessels in the granulation tissue taken from the left leg. The section was stained with hematoxylin-eosin. The degree was judged under a light microscope. The dark bar represents 100 μ m.

gradually enhanced wound closure thereafter, and the wound finally closed in 14 weeks (Fig. 2). Histopathologic examination revealed proliferated microvessels in the increased granulation tissue from the wound treated by VAC (Fig. 3).

Right lower extremity

Because the patient wanted us to treat the gangrene in his right foot, we first tried VAC. However, VAC alone did not enhance wound closure for the ulceration on the tip of his right 1st toe. We decided on revascularization for the right lower extremity and resection of the toe, just as for the left side. We performed revascularization between the right common femoral artery and right proximal popliteal artery with an 8 mm knitted Dacron graft and resection of the right 1st distal phalanges and proximal phalanx including the necrotic tissues. We kept the stumps open like the left lower extremity.

Postoperative ABI was 1.08 on the right side. VAC was started on the 4th postoperative day and it rapidly enhanced wound closure in only 1 week in spite of MRSA infection. However, VAC gradually enhanced wound closure thereafter. The wound finally closed after 6 weeks (Fig. 4).

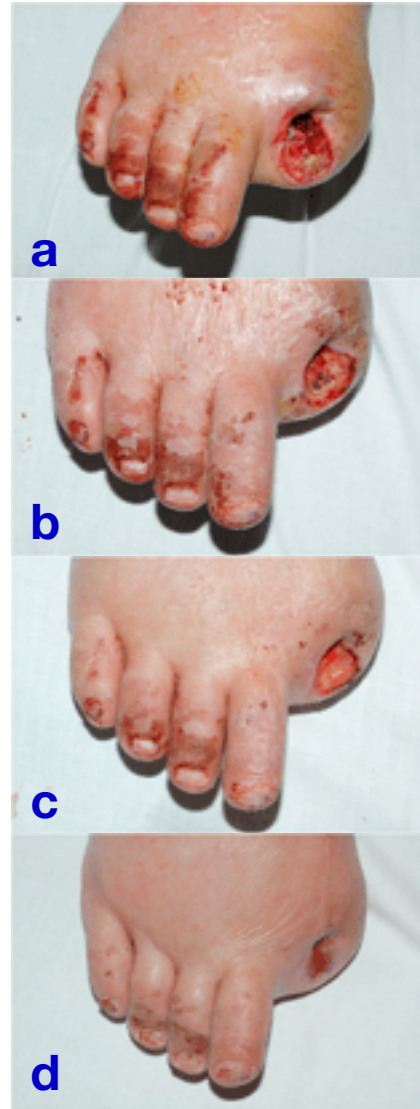

Fig. 4. Effect of the Vacuum-Assisted Closure (VAC) Therapy for the right leg. **a:** Before VAC. **b:** After 1 week of VAC. **c:** After 4 weeks of VAC. **d:** After 6 weeks of VAC.

Discussion

The VAC Therapy has been proven effective in treating both acute and chronic wounds regardless of infection (Argenta and Morykwas, 1997; McCallon et al., 2000; Armstrong and Lavery, 2005; Cowan et al., 2005). Haga et al. (2005) have reported that VAC is effective for diabetic foot wounds of patients with atherosclerosis. There were few reports on severe ischemic foot

in which VAC after revascularization facilitated wound healing. The mechanism of VAC is considered in part to act via the reduction of tissue edema, that may contain toxic by-products of infection and prolonged inflammation, and removal of factors that inhibit wound healing through the application of subatmospheric pressure with a vacuum (Argenta and Morykwas, 1997; Morykwas et al., 1997; McCallon et al., 2000), and also increase blood supply and reduce the incidence of infection in a porcine wound model (Morykwas et al., 1997). Tissue bacterial counts in infected wounds were also reduced by 21% with VAC compared with controls (Morykwas et al., 1997). VAC may also stimulate wound healing through the promotion of cell division, angiogenesis, and local proliferation of growth factors (Saxena et al., 2004). Nishimura et al. (2006) have reported that the effect of a high-frequency repetitive stretch or an intermittent stretch on the cell proliferation and survival of human dermal fibroblasts and the activation of any relevant signal pathways. In this case, histopathologic examination showed a lot of microvessels in the increased granulation tissue.

Femoral-femoral-popliteal artery bypass or right femoral-left popliteal artery bypass should have been considered initially as an appropriate treatment. However, in the present case, because the abdominal aorta had a stenosis and we may need to do a right axillo-femoral or femoral-femoral artery bypass in the near future, we performed a left axillo-popliteal artery bypass without exposure of the right femoral region. We also performed open minor amputation for fear of possible infection, even though there was no obvious sign of infection.

In the present case, VAC rapidly enhanced wound closure in only one week in spite of MRSA infection, and gradually enhanced wound closure thereafter. The wounds closed in 14 weeks on the left side and 6 weeks on the right side. Our case suggests that VAC may be effective even for infected wounds, especially within the 1st week after VAC started. On the other hand, as on the right side, this case also suggested that a lot of

microvessels in the increased granulation after VAC therapy may be related to facilitate wound healing as well as VAC may not be effective when the blood supply is insufficient. In treating ischemic foot with gangrene, revascularization should be performed first, before applying VAC therapy. Moreover, as we confirmed the effectiveness of VAC on the left side, we have had better earlier apply VAC on the right side, not but the 4th post-operative day.

The benefit of VAC therapy is also in its cost-effectiveness. The polyurethane film and tube were changed only twice a week. Whenever patients want to leave their beds, VAC can be easily disconnected and connected once they go back to bed. This is why patients don't have to be totally confined to bed during VAC. Ischemic foot with gangrene can be treated only with revascularization, but patients always need disinfection and/or washing as a usual treatment in the hospital for a long period. VAC might possibly shorten the length of hospital stay. In some cases, VAC failed to enhance wound closure in spite of increased granulation tissue (Armstrong and Lavery, 2005; Cowan et al., 2005). Further studies are warranted regarding the following: i) what is the indication for VAC?; ii) which is better, continuous or intermittent negative pressure?; iii) how long should VAC continue? and iv) how does VAC affect a superficial wound?

In conclusion, we report a case of severe ischemic foot in which VAC after revascularization facilitated wound healing in spite of MRSA infection.

References

- 1 Argenta LC, Morykwas MJ. Vacuum-assisted closure: a new method for wound control and treatment: clinical experience. *Ann Plast Surg* 1997;38: 563–577.
- 2 Armstrong DG, Lavery LA. Negative pressure wound therapy after partial diabetic foot amputation: multicentre, randomised controlled trial. *Lancet* 2005;366:1704–1710.
- 3 Cowan KN, Teague L, Sue SC, Mahoney JL. Vacuum-assisted wound closure of deep sternal infections

- in high-risk patients after cardiac surgery. *Ann Plast Surg* 2005;80:2205–2212.
- 4 Haga M, Inaba M, Azuma N, Akasaka N, Kadohama T, Kokubo T, et al. Vacuum-assisted closure on diabetic foot wounds of the patients with atherosclerosis. *Jpn J Vasc Surg* 2005;14:689–693.
 - 5 McCallon SK, Knight CA, Valiulus JP, Cunningham MW, McCulloch JM, Farinas LP. Vacuum-assisted closure versus saline-moistened gauze in the healing of postoperative diabetic foot wounds. *Ostomy Wound Manage* 2000;46:28–34.
 - 6 Morykwas MJ, Argenta LC, Shelton-Brown EI, McGuirt W. Vacuum-assisted closure: a new method for wound control and treatment: animal studies and basic foundation. *Ann Plast Surg* 1997; 38:553–562.
 - 7 Nishimura K, Blume P, Ohgi S, Sumpio BE. Effect of different frequencies of tensile strain on human dermal fibroblast proliferation and survival. *Wound Rep Reg* 2006; 15: 645–656.
 - 8 Saxena V, Hwang CW, Huang S, Eichbaum Q, Ingber D, Orgill DP. Vacuum-assisted closure: microdeformations of wounds and cell proliferation. *Plast Reconstr Surg* 2004;1086–1098.

Received December 17, 2007; accepted January 9, 2008

Corresponding author: Kengo Nishimura, MD