



This is a repository copy of *Chondroid tenosynovial giant cell tumour : a rarity in the temporomandibular joint.*

White Rose Research Online URL for this paper:
<http://eprints.whiterose.ac.uk/150420/>

Version: Accepted Version

Article:

Biyani, P., Khurram, S.A. orcid.org/0000-0002-0378-9380, Thomas, M. et al. (1 more author) (2019) Chondroid tenosynovial giant cell tumour : a rarity in the temporomandibular joint. *British Journal of Oral and Maxillofacial Surgery*, 57 (3). pp. 282-284. ISSN 0266-4356

<https://doi.org/10.1016/j.bjoms.2019.02.006>

Article available under the terms of the CC-BY-NC-ND licence
(<https://creativecommons.org/licenses/by-nc-nd/4.0/>).

Reuse

This article is distributed under the terms of the Creative Commons Attribution-NonCommercial-NoDerivs (CC BY-NC-ND) licence. This licence only allows you to download this work and share it with others as long as you credit the authors, but you can't change the article in any way or use it commercially. More information and the full terms of the licence here: <https://creativecommons.org/licenses/>

Takedown

If you consider content in White Rose Research Online to be in breach of UK law, please notify us by emailing eprints@whiterose.ac.uk including the URL of the record and the reason for the withdrawal request.



eprints@whiterose.ac.uk
<https://eprints.whiterose.ac.uk/>

Chondroid Tenosynovial Giant Cell Tumour – A rarity in the TMJ

Authors

Dr Prateek Biyani, Dental Core Trainee in Oral and Maxillofacial Surgery, Chesterfield Royal Hospital, Chesterfield, UK

Mr Mathew Thomas, Consultant Oral and Maxillofacial Surgeon, Royal Derby Hospital, Derby, UK

Dr Syed Ali Khurram, Senior Clinical Lecturer and Consultant Pathologist, School of Clinical Dentistry, University of Sheffield, UK

Mr Muzzammil Nusrath, Consultant Oral and Maxillofacial Surgeon, Royal Hallamshire Hospital, Sheffield, UK

Correspondence

Dr Prateek Biyani

Email: prateekbiyanibds@gmail.com

Abstract

Tenosynovial giant cell tumours (TGCT) of the temporomandibular joint (TMJ) are extremely rare, particularly the subset of chondroid tumours. TGCT can be broadly divided into localised and diffuse types (1), of which there have only been 116 reported cases in the TMJ. Rarer still are the subset of chondroid tenosynovial giant cell tumours (CTGCT), of which only 30 cases affecting the TMJ have been reported (2). We present a case of CTGCT involving the TMJ including discussion of presentation and management.

Case Report

A 67-year-old lady presented to the local oral and maxillofacial surgery department with a 7-8 years history of pain involving her left TMJ that restricted daily function. The pain was reasonably controlled with analgesia and a soft diet. She also reported a clicking noise on the affected side, as well as a significant deterioration in her hearing. There were no other associated symptoms or history. The patient was known to have medication-controlled hypertension and her social history was unremarkable.

Examination revealed a non-tender swelling in the left preauricular region, with associated mandibular deviation to the left side. Mild weakness of the buccal branch of her facial nerve was noted. Otoscopy demonstrated an obstructed ear canal.

Computerised tomography (CT) and Magnetic Resonance Imaging (MRI) scans identified a large, destructive bony lesion involving the left mastoid, TMJ and skull base regions (Figure 1). There was also evidence of abnormal soft tissue extending in to the left ear and a biopsy was recommended.

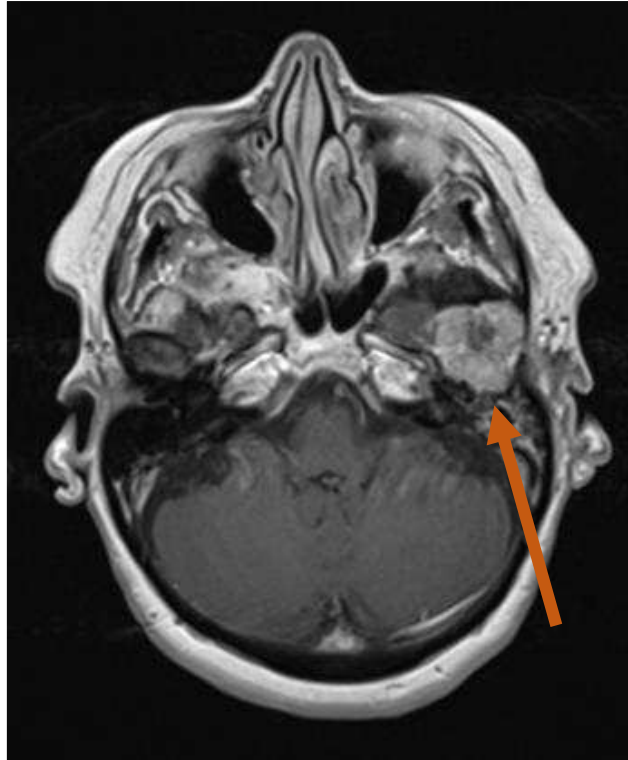


Figure 1 – Axial view of T1 weighted MRI with tumour evident in the left TMJ (arrow)

An open biopsy of the left TMJ was performed. Histopathology demonstrated eosinophilic ovoid and spindle cells with bland nuclei, with focal accumulations of multinucleated giant cells. There were also areas of lobular myxoid structure as well as chondroid tissue in keeping with a CTGCT (Figure 2). There was no evidence of malignancy.

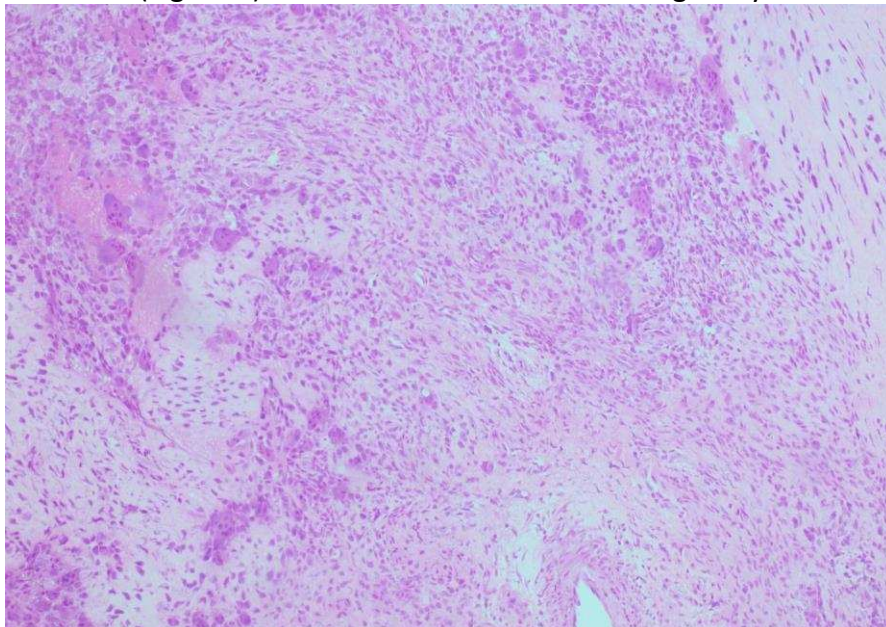


Figure 2 - Haematoxylin and eosin section with evidence of multinucleated giant cells, spindle cells and chondroid areas (original magnification x200).

The patient subsequently underwent a left condylectomy with left temporalis flap interposition (Figure 3). Histopathology confirmed the initial diagnosis though excision margins could not be determined due to the fragmented nature of the specimen.

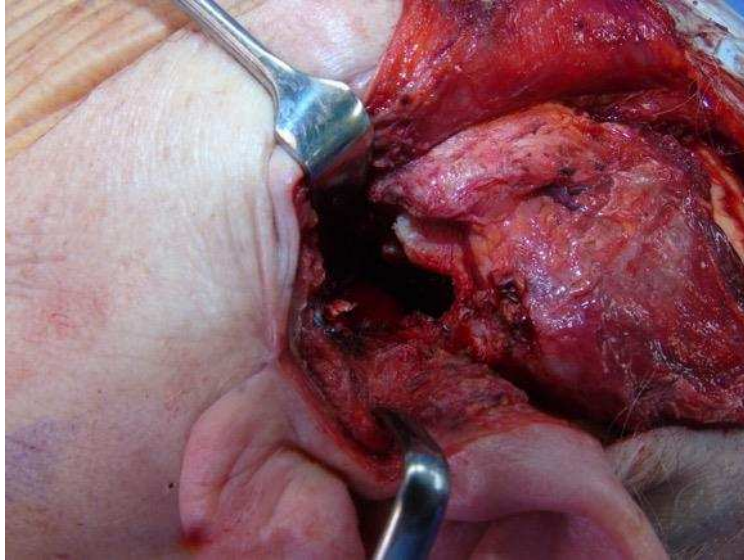


Figure 3 - Intra-operative view of tumour location

The patient's recovery has been uneventful with no evidence of recurrence at 15 months and excellent recovery of function.

Discussion

TGCT in the TMJ was first described by Lapayowker et al in 1973 (3). Though most often benign, 30 malignant cases of TGCT have been reported with only one affecting the TMJ. Benign forms may still prove to be locally destructive and may erode into the skull base (4). Typically, a TGCT presents with a preauricular mass, trismus/stiffness and clicking of the TMJ (5). TGCTs are often misdiagnosed – particularly as temporomandibular joint dysfunction (TMD). A review identified duration to diagnosis for these patients ranging from two months to 15 years, averaging at 30 months. Our patient had symptoms ongoing for eight years. There also appears to be no sex predilection (1). This highlights the importance of further investigations if conservative management is proving ineffective.

Panoramic radiographs are the first form of investigation. CT scans are useful in identifying the bony extent of the lesion, especially any skull base erosion. However, MRI scans are the imaging of choice for diagnosis and management. The presence of haemosiderin in these lesions causes a low signal intensity in the MRI resulting in a 'blooming effect' (6).

In the literature, various differential diagnoses have been considered, however, pre-auricular swellings are often benign but in many instances they can be malignant, including adenoid cystic carcinomas, mucoepidermoid carcinomas, primary and metastatic squamous cell carcinomas – hence requiring thorough consideration (7). Additionally, due to presence of chondroid metaplasia in CTGCTs, other lesions such as chondroblastomas and chondrosarcomas should also be considered (2).

Histologically, CTGCTs appear red-brown in colour with masses of villi, synovial folds and often chondroid tissue typically containing multinucleated giant cells (5).

Due to the destructive potential of CTGCTs, complete surgical resection is the ideal treatment, as seen in this case. In some cases, particularly in severe cases or incomplete resections, adjuvant treatment including radiotherapy may need to be considered (2,4). Though there was a lack of clarity of the resection margins in our case, close clinical follow-up was recommended. A variable recurrence rate (7-11%) of these lesions has been reported (1). This is comparatively lower than recurrence in other parts of the body. Close follow-up is necessary over a period of several years due to this risk.

CTGCTs, though rare, should be considered when dealing with preauricular swellings where common diagnoses have been disproven. A full work-up is required to assess the nature of the lesion, particularly any invasive growth. Complete surgical resection is the gold standard, with close clinical follow-up.

References

1. Zhang C, Zhu L, Wang L, Hu Y, Li J, Tian Z. Original Article Diffuse tenosynovial giant cell tumor in the temporomandibular joint area in a Chinese population: a clinicopathological analysis of 32 cases [Internet]. Vol. 9, *Int J Clin Exp Pathol*. 2016 [cited 2018 Aug 24]. Available from: www.ijcep.com/
2. Anbinder AL, Geraldo BMC, Guimarães Filho R, Pereira DL, Almeida OP de, Carvalho YR, et al. Chondroid Tenosynovial Giant Cell Tumor of the Temporomandibular Joint: A Rare Case Report. *Braz Dent J* [Internet]. Fundação Odontológica de Ribeirão Preto; 2017 Sep [cited 2018 Aug 24];28(5):647–52. Available from: http://www.scielo.br/scielo.php?script=sci_arttext&pid=S0103-64402017000500647&lng=en&tIng=en
3. Lapayowker MS, Miller WT, Levy WM, Harwick RD. Pigmented Villonodular Synovitis of the Temporomandibular Joint. *Radiology* [Internet]. The Radiological Society of North America ; 1973 Aug 1 [cited 2018 Aug 28];108(2):313–6. Available from: <http://pubs.rsna.org/doi/10.1148/108.2.313>
4. Bredell M, Schucknecht B, Bode-Lesniewska B. Tenosynovial, diffuse type giant cell tumor of the temporomandibular joint, diagnosis and management of a rare tumor. *J Clin Med Res* [Internet]. Elmer Press; 2015 Apr [cited 2018 Aug 24];7(4):262–6. Available from: <http://www.ncbi.nlm.nih.gov/pubmed/25699124>
5. Kim I-K, Cho H-Y, Cho H-W, Seo J-H, Lee D-H, Peng W. Pigmented villonodular synovitis of the temporomandibular joint - computed tomography and magnetic resonance findings: a case report. *J Korean Assoc Oral Maxillofac Surg* [Internet]. Korean Association of Oral and Maxillofacial Surgeons; 2014 Jun [cited 2018 Aug 28];40(3):140–6. Available from: <http://www.ncbi.nlm.nih.gov/pubmed/25045642>
6. Cheng XG, You YH, Liu W, Zhao T, Qu H. MRI features of pigmented villonodular synovitis (PVNS). *Clin Rheumatol* [Internet]. Springer-Verlag; 2004 Feb 1 [cited 2018 Aug 29];23(1):31–4. Available from: <http://link.springer.com/10.1007/s10067-003-0827-x>

7. Romañach MJ, Brasileiro BF, León JE, Alves DB, de Almeida OP, Vargas PA. Pigmented villonodular synovitis of the temporomandibular joint: case report and review of the literature. *Oral Surgery, Oral Med Oral Pathol Oral Radiol Endodontology* [Internet]. Elsevier; 2011 Mar 1 [cited 2018 Aug 29];111(3):e17–28. Available from: <http://linkinghub.elsevier.com/retrieve/pii/S1079210410009194>