



A Novel Mutation in the OFD1 Gene in a Family with Oral-Facial-Digital Syndrome Type 1: A Case Report

Masoud DEHGHAN TEZERJANI^{1,2}, Reza MAROOFIAN³, Mohammad Yahya VAHIDI MEHRJARDI^{1,4}, Barry A. CHIOZA³, Shiva ZAMANINEJAD⁵, Seyed Mehdi KALANTAR^{2,4}, Mahmoud NORI-SHADKAM⁶, Hamidreza GHADIMI⁷, Emma L. BAPLE⁸, Andrew H. CROSBY³, *Mohammadreza DEHGHANI^{1,2}

1. Medical Genetics Research Center, Shahid Sadoughi University of Medical Sciences, Yazd, Iran
2. Research and Clinical Center for Infertility, Shahid Sadoughi University of Medical Sciences, Yazd, Iran
3. Monogenic Molecular Genetics, University of Exeter Medical School, Exeter EX1 2LU, UK
4. Dept. of Medical Genetics, Shahid Sadoughi University of Medical Sciences, Yazd, Iran
5. Faculty of Dentistry, Golestan University of Medical Sciences, Gorgan, Iran
6. Dept. of Pediatrics, Shahid Sadoughi University of Medical Sciences, Yazd, Iran
7. Faculty of Medicine, Tehran University of Medical Sciences, Tehran, Iran
8. Human Genetics and Genomic Medicine, Faculty of Medicine, University of Southampton, and Wessex Clinical Genetics Service, Princess Anne Hospital, Southampton, UK

*Corresponding Author: Email: mrezdehghani@gmail.com

(Received 21 Dec 2015; accepted 12 May 2016)

Abstract

Oral-facial-digital syndrome as heterogeneous developmental conditions is characterized by abnormalities in the oral cavity, facial features and digits. Furthermore, central nervous system (CNS) abnormalities can also be part of this developmental disorder. At least 13 forms of OFDS based on their pattern of signs and symptoms have been identified so far. Type 1 which is now considered to be a ciliopathy accounts for the majority of cases. It is transmitted in an X-linked dominant pattern and caused by mutations in OFD1 gene, which can result in embryonic male lethality. In this study, we present a family suffering from orofacioidigital syndrome type I who referred to Medical Genetics Research Center, Shahid Sadoughi University of Medical Sciences in 2015. Two female siblings and their mother shared a novel 2-base pair deletion (c.1964-1965delGA) in exon 16 of OFD1 gene. Clinically, the sibling had oral, facial and brain abnormalities, whereas their mother is very mildly affected. She also had history of recurrent miscarriage of male fetus.

Keywords: OFD1, Oral-facial-digital syndrome, X-linked dominant, Miscarriage, Ciliopathy

Introduction

Orofaciodigital syndrome (OFDS) (OMIM 311200) is a general term for describing several distinctive developmental genetic diseases that are characterized by malformation of the mouth, face and digits. At least 13 different types of the syndrome have been recognized among which type 1 (OFD1) is the most common form with

an incidence of 1:50000 to 1:250000 live births (1, 2). The cardinal clinical features include craniofacial abnormalities (facial asymmetry, hypertelorism, frontal bossing, microretrognathia, broadened nasal bridge, cleft palate, multi-lobulated tongue with nodules, and abnormal dentition), and digital abnormalities including

brachydactyly, syndactyly, clinodactyly and pre- or post-axial polydactyly. In 60% of cases with OFD1, brain structural abnormalities, developmental delay and intellectual disabilities have been identified (3). Majority of cases with onset older than 18 years, suffer from renal cystic disease (4-6). The observation of multiple milia and hypotrichosis is remarkable skin abnormality for OFD1 which are not observed in other types of OFDS (7). Alopecia, deafness and trembling are expressed less frequently in OFD1.

Mutations in the OFD1 gene, which is mapped on chromosome Xp22, are responsible for OFD syndrome type 1. Therefore, OFD syndrome type 1 is inherited in X-linked dominant pattern and has prenatal lethality in the male fetus (5, 8, 9). A protein with 1011 amino acid expressed on the basal body of primary cilia and the centrosome is encoded by OFD1 gene. The protein also has a key role in the biogenesis of cilium and development by modulating Wnt signaling pathways (10-13). To date, over 130 different mutations have been identified in OFD1 with many truncating mutations. The location of mutations causing OFD1 extends to 17 exons of 23 coding exons. About 75% of cases with OFD1 are sporadic, and there are some reports about correlation of genotype with phenotype (12, 14). Mutations in OFD1 gene have also been identified in

association with four recessive X-linked phenotypes: Joubert syndrome, intellectual disability, type 2 Simpson-Golabi-Behmel syndrome and retinitis pigmentosa (15-19).

In this case study, we analyzed the sequences of the eight exons of the OFD1 gene in eight individuals from an Iranian family with X-linked dominant OFD1, and we identified a novel mutation. This family had a heterogeneous phenotypic findings ranging from being so mild in the mother that she was undiagnosed to severe neurodevelopmental delay, distinctive dysmorphic facial features, and multiple oral anomalies in her daughters.

Subjects

The study was approved by Ethics Committee of Yazd University of Medical Sciences and informed written consent was obtained from the all subjects participating in the study.

A female sibship was referred to the Medical Genetics Department of Yazd University of Medical Sciences due to craniofacial and oral dysmorphism in addition to neurodevelopmental delay. The patients were thoroughly examined and all their clinical records were reviewed by a physician. A three-generational pedigree for the family was constructed based on their family history obtained by a genetic counselor (Fig. 1).

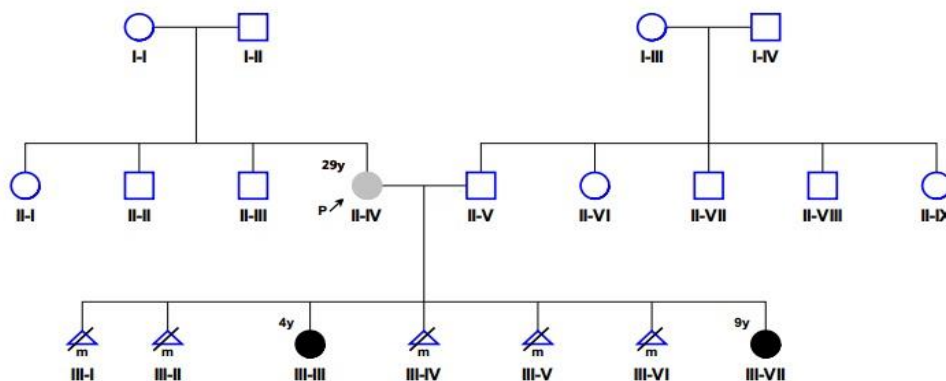


Fig.1: The pedigrees of family with OFD1 syndrome .This pedigree shows two females with OFD1 syndrome (Black symbols), five miscarriages of male fetus (slash lines), and mother with mild phenotype (Gray circle)

Patient 1 (III-VII)

The first patient was a 9-year-old girl with a birth weight of 3200 g who was born to a family with non-consanguineous parents at 37 wk gestation, because of the fourth pregnancy. At birth, she had ventricular septal defect (VSD) diagnosed with fetal ultrasonography, and deformities of the mouth, jaw, and palate were remarkable. The child could stand and walk without assistance at 29 month. She also started to speak her first words at the age of two. At the time of the study, oral abnormalities included cleft palate, malaligned, abnormal dentition, macroglossia, ankyloglossia, multiple hyperplastic frenulums, and a bifid, lobulated tongue. Facial abnormalities that could be seen in the patient were dolichocephaly, macrocephaly (54.3 cm- 88 percentile), saddle nose deformity, low set ears, downslant palpebral fissures, and thin hair and eyebrows (Fig. 2). The girl also had severe psychomotor delay, intellectual disability and seizures. There were no signs of malformation in her feet and hands. Brain magnetic resonance imaging (MRI) revealed heterotopia in right cingulate cortex and brain Computed Tomography (CT) Scan showed ectopic gray matter in right posterior parasagittal (Fig. 3). Abdominal MRI revealed that she had no sign of renal anomaly. A G-band karyotype performed on the patient showed no gross chromosomal aberrations. She had normal vision and hearing and laboratory tests could not detect anything abnormal.

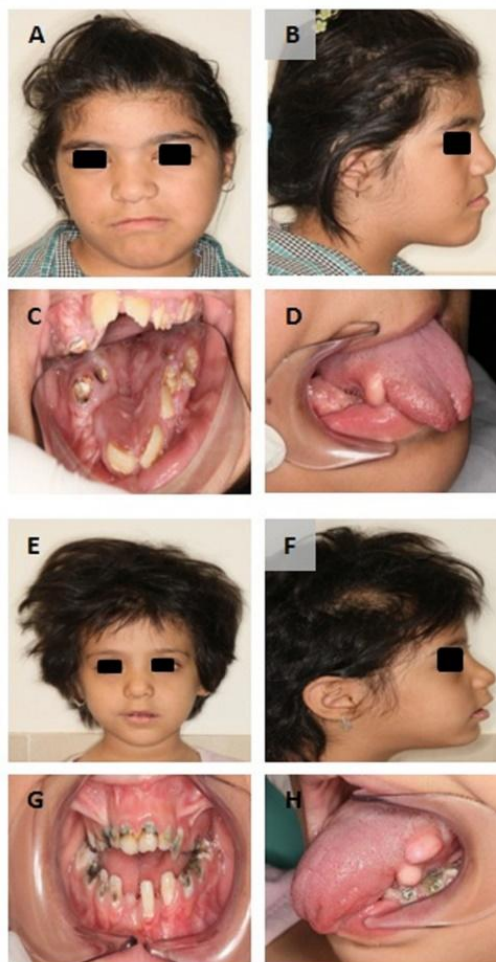


Fig. 2: Clinical features of case 1 & 2; **A, B, E & F:** Distinctive facial features, **C & G:** malaligned dentition, **D & H:** bifid tongue & nodules in the lateral border of tongue

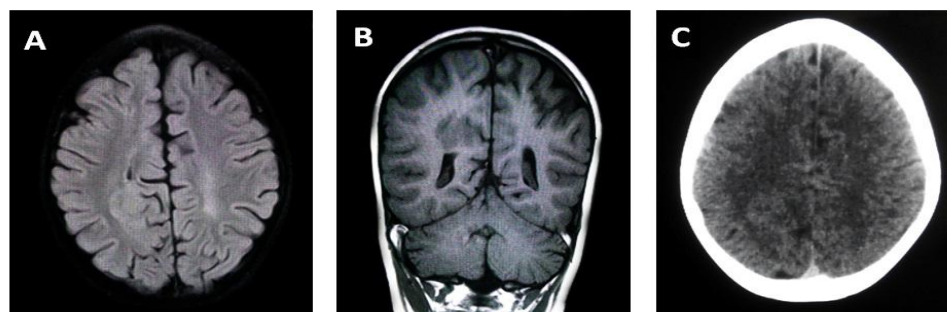


Fig. 3: Brain magnetic resonance imaging (MRI) findings of patient 1(III-IV), **A & B:** Axial and Coronal (FLAIR) view indicates heterotopia in right cingulate cortex. **C:** Computed Tomography (CT) Scan of the patient 1(III-IV) shows ectopic gray matter in right posterior parasagittal.

Patient 2 (III-III)

The second patient was a 4-yr-old girl born as the result of the seventh pregnancy at 36 wk of gestation with a birth weight of 3300 g. The patient could walk without support at 15 months. She had the following abnormalities: dolichocephaly, macrocephaly (51 cm- 66 percentile), multiple and malaligned dentition, cleft lip and palate, asymmetric, bifid and lobulated tongue, macroglossia, multiple hyperplastic frenulum, ankyloglossia, low set ears, downslant palpebral fissures, and thin hair and eyebrows (Fig. 2). She had moderate psychomotor delay and developmental delay. The patient did not have any symptoms of abnormality in hands and feet. She had normal vision and hearing. Her brain MRI and CT-scan had normal findings and no renal abnormalities such as poly-cystic kidney (PKD) were identified. Her karyotype and routine laboratory test results were also all normal.

Mother of the patients (II-IV)

The mother of patients 1 and 2 was 29 yr old. She had a history of five abortions of malformed male fetuses (III-I, III-II, III-IV, III-V and III-VI). The abortions of all male fetuses happened during her third month of pregnancy. She was born with bifid tongue that was surgically repaired. In addition, her dry and thin hair is remarkable. Although the mother experienced consecutive abortions with two affected daughters, she did not attend any genetic counseling, which caused delay in diagnosis of the disease.

We extracted genomic DNAs from the peripheral blood samples using the ReliaPrep™ kit (Blood gDNA Miniprep System, Promega). The mutational hotspot within 8 exons of OFD1 (including exons 2, 3, 7, 8, 9, 12, 13 and 16) were amplified based on standard protocols. Primer sequences are available upon request. Then, the study employed 3730 DNA Analyzer and BigDye Terminator v3.1 cycle sequencing kit (Applied Biosystems) for sequencing of the PCR products in both directions.

Our genetic studies identified a novel 2-base pair deletion (c.1964-1965delGA) in exon 16 of OFD1 leading to a frame shift (p.Arg654X) in

two patients and their mother (Fig. 4). The mutation has not been previously reported, nor is present in The NHLBI Exome Sequencing Project Exome Variant Server (September 2013), Complete Genomics (February 2012), dbSNP (134–137), 1000 Genomes (May 2012) and Exome Aggregation Consortium (ExAC), Cambridge, MA and as it was expected it was absent in the father and the brother of mother.

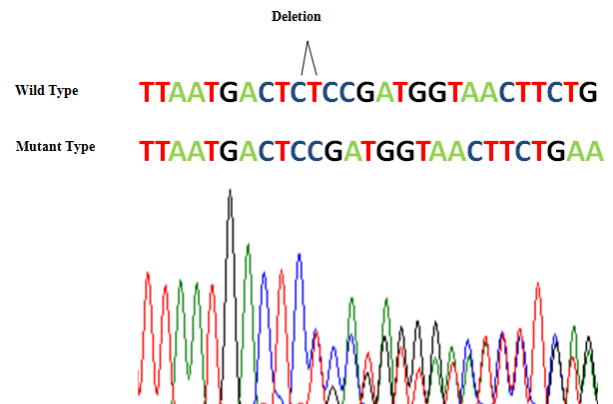


Fig. 4: Sequence analysis of the exon 16. Direct sequencing of the PCR products in affected individuals and wildtype. CT (GA in the sense strand) was deleted.

Discussion

We found a novel 2-base pair deletion (c.1964-1965delGA) in exon 16 of OFD1 gene causing abnormal phenotypes in two children and their mother, which affirmed the OFD1 syndrome.

Oral, facial and digital abnormalities are main criteria in the diagnosis of OFD1. In spite of the severe phenotypic picture observed in the affected sisters, a suspected diagnosis OFDS had not been suggested until thorough clinical examinations, in particular oral evaluation, of the sibling. The variable presentation of signs and symptoms in OFDS makes the diagnosis of each type very difficult. We could not distinguish X-linked OFDS from autosomal recessive variants just based on oral, facial and neurological features of the patients. The OFDS type 1 was established only after clinical findings in the sibling and their

mother, pedigree analysis and finally the genetic screening of the OFD1 gene. Although the findings described for OFD1 overlap with those observed in other OFDS types, in familial cases, it can be differentiated because of its X-linked dominant inheritance with multiple male lethality and absence of parental consanguinity from pedigree analysis (20).

Unsurprisingly, affected individuals in this family did not display all traditionally key features of OFDS, thus confirming once again the variable phenotypic spectrum of OFDS. For instances, in this family neither of the patients have digital abnormalities which occur in 88% of Patients with OFDS (12). In addition, polycystic kidney was not observed in the family which is almost present in all the affected individuals with OFDS in their adulthood (21). However, absence of the kidney features in the affected sisters can be due to their young age and there is a very high risk for PKD in the patients. Since PKD leads to renal failure careful morphological assessments and biochemical monitoring of renal function in the family is necessary. Structural brain malformation in patients with OFD1 has often been found in 88.7% among patients displaying neurological symptoms or/and cognitive/behavioral abnormalities. The most frequent anomalies of brain structure included disorders of neuronal migration and organisation, agenesis of the corpus callosum, intracerebral cysts, cerebellar malformations and porencephaly (3). Brain MRI analysis of the older sister did not find any abnormalities and younger affected individual only presented malformation of cortical development (MCD) including grey matter heterotopias.

Both affected sister presented mild macrocephaly and dolichocephaly. Although Macrocephaly is a cardinal clinical feature in X-linked recessive OFD1 neurodevelopmental syndromes in males, it has never been reported in OFDS type 1. This is the first report of macrocephaly in female patients with mutation in OFD1.

The mother of the patients was presented with a milder phenotype than that of her daughters (20). Clinical features in the mother of the patients were noticed only after presentation of severe symptoms in her daughters. Milder phenotype in the mother and clinical variability in the affected children, which is common for OFD1, poses challenges for accurate diagnosis and genetic counselling. It can be explained because of the different degree of somatic mosaicism X-inactivation (20). Modifier genes can also be important factor for variability in families with OFD1 patients (22). Male lethality in OFD1 usually occurs in the first or second trimester of pregnancy and only more than a dozen exceptional male cases with mutation in OFD1 have been reported to date. In this family, the mother had a history of five male miscarriages. Therefore, this mutation can also be responsible for lethality in male fetuses.

Mutation detection in OFD1 is necessary for definitive diagnosis, especially for genetic counselling, preimplantation genetic diagnosis (PGD) and/or prenatal diagnosis. Fig. 5 demonstrates the frequency of reported OFD1 mutations (6, 10, 14-17, 22-30). Majority of mutations in OFD1 have been identified in exons 3, 7, 8, 9, 12, 13 and 16, which may represent mutational hotspots. The mutation identified in this family is a two base-pair deletion mutation, which has not been previously reported, in exon 16 causing frameshift. As with most of the mutations that have been described in the gene, it is predicted to cause premature truncation of the protein that would probably result in loss of function. There is no correlation between OFD1 clinical features and type of mutations. However, a phenotype-genotype correlation between the location of mutations and some variable clinical features of OFD1 has been suggested. For example, Intellectual disability is more associated with mutations in exons 3, 8, 9, 13 and 16 (3).

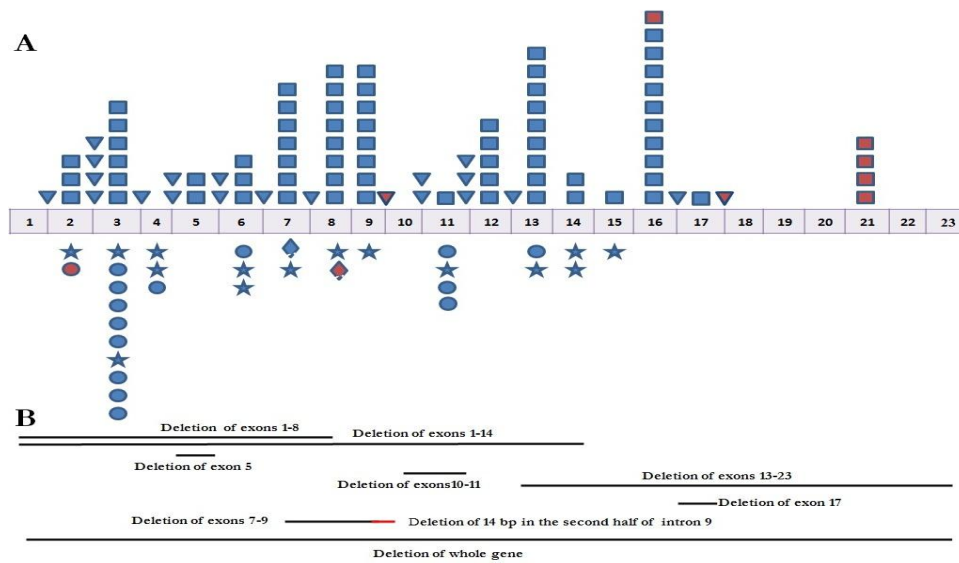


Fig. 5: Schematic representation of the reported OFD1 gene mutations (Last update; main source: Prattichizzo et al. 2008). A: Point mutations. B: Genomic deletions. Square (frame shift), Triangle (splice site), Star (nonsense), Circle (missense), Diamond (in-frame deletion) and Red symbols indicating mutations found in males with OFD1 X-linked recessive disorder.

Conclusion

We identified a novel truncating mutation in OFD1 in three female members of a family displaying variable symptoms and severity of clinical manifestation of OFDS type 1. As observed in previous cases with OFD1, phenotypic variability even within a family is possibly a rule rather than the exception. Hence, this report emphasizes importance as well as the challenges of genetic counseling for OFD1 patients and their relatives. In cases of OFDS, thorough physical examination, collecting the family history and genetic screening of the affected individuals and their female relatives, along with monitoring of renal function are mandatory.

Ethical considerations

Ethical issues (Including plagiarism, informed consent, misconduct, data fabrication and/or falsification, double publication and/or submission, redundancy, etc.) have been completely observed by the authors.

Acknowledgment

We are thankful to the family members for their willing participation in this study. The authors declare that they have no competing interests.

References

1. Gorlin RJ, Anderson VE, Scott CR (1961). Hypertrophied frenuli, oligophrenia, familial trembling and anomalies of the hand. Report of four cases in one family and a forme fruste in another. *N Engl J Med*, 264:486-489.
2. Toriello HV (2009). Are the oral-facial-digital syndromes ciliopathies? *Am J Med Genet A*, 149A(5):1089-1095.
3. Del Giudice E, Macca M, Imperati F, D'Amico A, Parent P, Pasquier L, Layet V, Lyonnet S, Stamboul-Darmency V, Thauvin-Robinet C, Franco B, Oral-Facial-Digital Type ICG (2014). CNS involvement in OFD1 syndrome: a clinical, molecular, and neuroimaging study. *Orphanet J Rare Dis*, 9:74.
4. Feather SA, Winyard PJ, Dodd S, Woolf AS (1997). Oral-facial-digital syndrome type 1 is another dominant polycystic kidney disease:

- clinical, radiological and histopathological features of a new kindred. *Nephrol Dial Transplant*, 12(7):1354-1361.
5. Feather SA, Woolf AS, Donnai D, Malcolm S, Winter RM (1997). The oral-facial-digital syndrome type 1 (OFD1), a cause of polycystic kidney disease and associated malformations, maps to Xp22.2-Xp22.3. *Hum Mol Genet*, 6(7):1163-1167.
 6. Ferrante MI, Giorgio G, Feather SA, Bulfone A, Wright V, Ghiani M, Selicorni A, Gammaro L, Scolari F, Woolf AS, Sylvie O, Bernard L, Malcolm S, Winter R, Ballabio A, Franco B (2001). Identification of the gene for oral-facial-digital type I syndrome. *Am J Hum Genet*, 68(3):569-576.
 7. Habib K, Fraïtag S, Couly G, de Prost Y (1992). [Cutaneous lesions in the orofacioldigital syndrome]. *Ann Pediatr (Paris)*, 39(7):449-452.
 8. Solomon LM, Fretzin D, Pruzansky S (1970). Pilosebaceous dysplasia in the oral-facial-digital syndrome. *Arch Dermatol*, 102(6):598-602.
 9. Franco B, Ballabio A (2006). X-inactivation and human disease: X-linked dominant male-lethal disorders. *Curr Opin Genet Dev*, 16(3):254-259.
 10. Romio L, Wright V, Price K, Winyard PJ, Donnai D, Porteous ME, Franco B, Giorgio G, Malcolm S, Woolf AS, Feather SA (2003). OFD1, the gene mutated in oral-facial-digital syndrome type 1, is expressed in the metanephros and in human embryonic renal mesenchymal cells. *J Am Soc Nephrol*, 14(3):680-689.
 11. Giorgio G, Alfieri M, Prattichizzo C, Zullo A, Cairo S, Franco B (2007). Functional characterization of the OFD1 protein reveals a nuclear localization and physical interaction with subunits of a chromatin remodeling complex. *Mol Biol Cell*, 18(11):4397-4404.
 12. Macca M, Franco B (2009). The molecular basis of oral-facial-digital syndrome, type 1. *Am J Med Genet C Semin Med Genet*, 15;151C(4):318-325.
 13. Hunkapiller J, Singla V, Seol A, Reiter JF (2011). The ciliogenic protein Oral-Facial-Digital 1 regulates the neuronal differentiation of embryonic stem cells. *Stem Cells Dev*, 20(5):831-841.
 14. Bisschoff IJ, Zeschnigk C, Horn D et al. (2013). Novel mutations including deletions of the entire OFD1 gene in 30 families with type 1 orofacioldigital syndrome: a study of the extensive clinical variability. *Hum Mutat*, 34(1):237-247.
 15. Budny B, Chen W, Omran H, Fliegau M, Tzschach A, Wisniewska M, Jensen LR, Raynaud M, Shoichet SA, Badura M, Lenzner S, Latos-Bielenska A, Ropers HH (2006). A novel X-linked recessive mental retardation syndrome comprising macrocephaly and ciliary dysfunction is allelic to oral-facial-digital type I syndrome. *Hum Genet*, 120(2):171-178.
 16. Coene KL, Roepman R, Doherty D et al. (2009). OFD1 is mutated in X-linked Joubert syndrome and interacts with LCA5-encoded lebercilin. *Am J Hum Genet*, 85(4):465-481.
 17. Field M, Scheffer IE, Gill D, Wilson M, Christie L, Shaw M, Gardner A, Glubb G, Hobson L, Corbett M, Friend K, Willis-Owen S, Gecz J (2012). Expanding the molecular basis and phenotypic spectrum of X-linked Joubert syndrome associated with OFD1 mutations. *Eur J Hum Genet*, 20(7):806-809.
 18. Webb TR, Parfitt DA, Gardner JC et al. (2012). Deep intronic mutation in OFD1, identified by targeted genomic next-generation sequencing, causes a severe form of X-linked retinitis pigmentosa (RP23). *Hum Mol Genet*, 21(16):3647-3654.
 19. Tenorio J, Arias P, Martinez-Glez V, Santos F, Garcia-Minaur S, Nevado J, Lapunzina P (2014). Simpson-Golabi-Behmel syndrome types I and II. *Orphanet J Rare Dis*, 9:138.
 20. Shimojima K, Shimada S, Sugawara M, Yoshikawa N, Nijima S, Urao M, Yamamoto T (2013). Challenges in genetic counseling because of intra-familial phenotypic variation of oral-facial-digital syndrome type 1. *Congenit Anom (Kyoto)*, 53(4):155-159.
 21. Gurrieri F, Franco B, Toriello H, Neri G (2007). Oral-facial-digital syndromes: review and diagnostic guidelines. *Am J Med Genet A*, 15;143A(24):3314-3323.
 22. Prattichizzo C, Macca M, Novelli V, Giorgio G, Barra A, Franco B, Oral-Facial-Digital Type ICG (2008). Mutational spectrum of the oral-facial-digital type I syndrome: a study on a large collection of patients. *Hum Mutat*, 29(10):1237-1246.

23. Rakkolainen A, Ala-Mello S, Kristo P, Orpana A, Jarvela I (2002). Four novel mutations in the OFD1 (Cxorf5) gene in Finnish patients with oral-facial-digital syndrome 1. *J Med Genet*, 39(4):292-296.
24. Thauvin-Robinet C, Cossee M, Cormier-Daire V et al. (2006). Clinical, molecular, and genotype-phenotype correlation studies from 25 cases of oral-facial-digital syndrome type 1: a French and Belgian collaborative study. *J Med Genet*, 43(1):54-61.
25. Chetty-John S, Piwnica-Worms K, Bryant J, Bernardini I, Fischer RE, Heller T, Gahl WA, Gunay-Aygun M (2010). Fibrocystic disease of liver and pancreas; under-recognized features of the X-linked ciliopathy oral-facial-digital syndrome type 1 (OFD I). *Am J Med Genet A*, 152A(10):2640-2645.
26. Diz P, Alvarez-Iglesias V, Feijoo JF, Limeres J, Seoane J, Tomas I, Carracedo A (2011). A novel mutation in the OFD1 (Cxorf5) gene may contribute to oral phenotype in patients with oral-facial-digital syndrome type 1. *Oral Dis*, 17(6):610-614.
27. Morisawa T, Yagi M, Surono A, Yokoyama N, Ohmori M, Terashi H, Matsuo M (2004). Novel double-deletion mutations of the OFD1 gene creating multiple novel transcripts. *Hum Genet*, 115(2):97-103.
28. Thauvin-Robinet C, Thomas S, Sinico M et al. (2013). OFD1 mutations in males: phenotypic spectrum and ciliary basal body docking impairment. *Clin Genet*, 84(1):86-90.
29. Juric-Sekhar G, Adkins J, Doherty D, Hevner RF (2012). Joubert syndrome: brain and spinal cord malformations in genotyped cases and implications for neurodevelopmental functions of primary cilia. *Acta Neuropathol*, 123(5):695-709.
30. Tsurusaki Y, Kosho T, Hatasaki K, Narumi Y, Wakui K, Fukushima Y, Doi H, Saitsu H, Miyake N, Matsumoto N (2013). Exome sequencing in a family with an X-linked lethal malformation syndrome: clinical consequences of hemizygous truncating OFD1 mutations in male patients. *Clin Genet*, 83(2):135-144.