

Case Report / *Olgu Sunumu*DOI: 10.5578/ced.67415 • *J Pediatr Inf* 2018;12(4):e161-e163

A Rare Case of *Clostridium difficile* Infection-Associated Reactive Arthritis

Clostridium difficile ilişkili Nadir Bir Reaktif Artrit OlgusuMeltem Polat¹, Anıl Tapısız², Betül Emine Derinkuyu³, Hasan Tezer²¹ Department of Pediatric Infectious Diseases, Pamukkale University School of Medicine, Denizli, Turkey² Department of Pediatric Infectious Diseases, Gazi University School of Medicine, Ankara, Turkey³ Division of Pediatric Radiology, Dr. Sami Ulus Obstetrics and Gynecology, Children's Health and Disease Training and Research Hospital, Ankara, Turkey**Makale atfı:** Polat M, Tapısız A, Derinkuyu BE, Tezer H. A rare case of *clostridium difficile* infection-associated reactive arthritis *J Pediatr Inf* 2018;12(4):e161-e163

Abstract

Clostridium difficile is an uncommon cause of reactive arthritis in children. We herein present a rare case of *C. difficile* infection-associated reactive arthritis (CDIAReA) in a child, who developed severe diarrhea and a knee effusion following a course of oral antibiotic treatment. Our report emphasizes that CDIAReA should be considered in the differential diagnosis of children presenting with acute and painful arthritis that develops in the setting of antibiotic associated diarrhea.

Keywords: Antibiotic associated diarrhea, *Clostridium difficile*, reactive arthritis

Öz

Clostridium difficile, çocuklarda nadir olarak bildirilmiş bir reaktif artrit nedenidir. Burada antibiyotik tedavisi sonrası ishal ve sol diz ekleminde efüzyon gelişen nadir bir *C. difficile* ilişkili reaktif artrit olgusu sunulmuştur. Bu olgu ile antibiyotik ilişkili ishal zemininde gelişen akut ve ağrılı artrit ile başvuran çocuklarda ayırıcı tanıda *C. difficile* ilişkili reaktif artrit de düşünülmesi gerektiği vurgulanmak istenmiştir.

Anahtar Terimler: Antibiyotik ilişkili ishal, *Clostridium difficile*, reaktif artrit

Introduction

Reactive arthritis (ReA) is an acute, aseptic, inflammatory arthritis triggered by several types of enteric and genital bacterial infections. The leading bacterial triggers are *Salmonella*, *Shigella*, *Yersinia*, and *Campylobacter* species. Unlike other enteric pathogens, *Clostridium difficile* does not commonly cause ReA (1-3). We herein present a rare case of *C. difficile* infection-associated reactive arthritis (CDIAReA) in a 10-year-old child, who developed severe diarrhea and a knee effusion following a course of oral antibiotic treatment.

Case Report

A 10-year-old boy with no history of trauma was admitted to a pediatric emergency department (PED) owing to a 3-day history of pain and swelling in his left knee. His parents stated that he had also complained of migratory pain in his ankles and right shoulder for 4 days. Two weeks before admission, he had completed a 7-day course of oral cefpodoxime for acute sinusitis. Five days after discontinuing the antibiotic treatment, he developed watery diarrhea persisting at the time of admission. In the PED, the patient was moderately ill-looking, with a

Geliş Tarihi: 25.04.2018

Kabul Tarihi: 09.10.2018

Correspondence Address / Yazışma Adresi

Meltem PolatPamukkale Üniversitesi Tıp Fakültesi,
Çocuk Enfeksiyon Hastalıkları Bilim Dalı,
Denizli-Türkiye**E-mail:** meltemtemizhan@gmail.com©Copyright 2018 by Pediatric
Infectious Diseases Society - Available online at
www.cocukenfeksiyon.org©Telif Hakkı 2018
Çocuk Enfeksiyon Hastalıkları Derneği -Makale metnine
www.cocukenfeksiyon.org web sayfasından ulaşılabilir

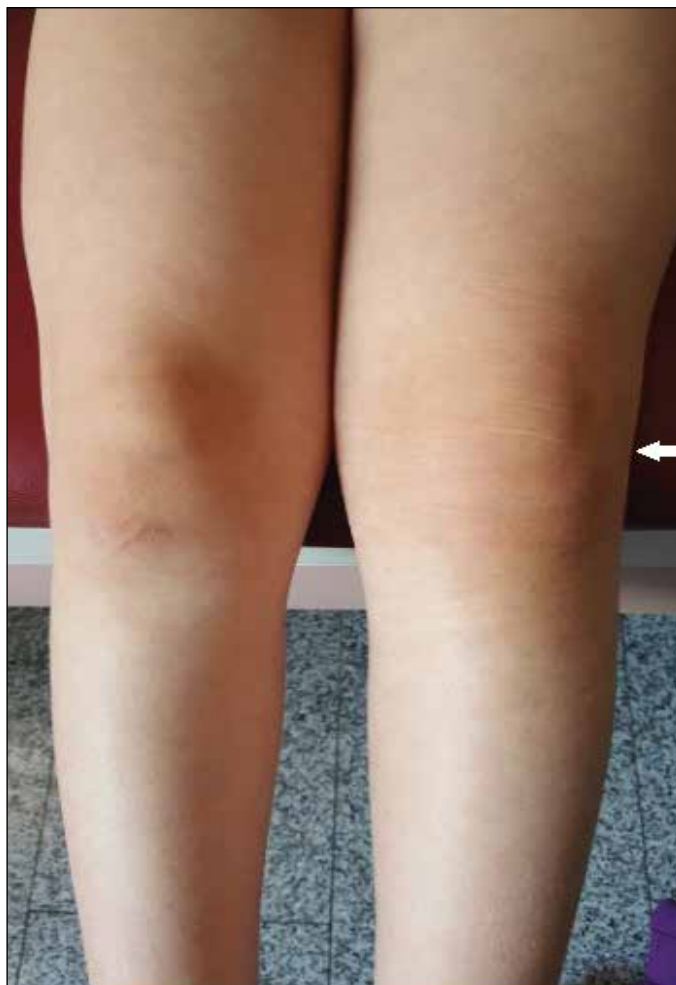

Figure 1. Left knee swelling (white arrow) at admission.

temperature of 39°C, a heart rate of 115 beats/minute, a respiratory rate of 22 breaths/minute, and a blood pressure of 115/80 mmHg. His left knee was swollen, warm to touch, and extremely tender upon palpation, with limited flexion and extension, owing to pain (Figure 1). There were no abnormalities in his other joints, eyes, skin, and genitourinary system.

Notable laboratory results were as follows: white blood cell (WBC) count, 22,400/ μ L with 84% neutrophils; hemoglobin, 12 g/dL; platelet count, 568,000/ μ L; erythrocyte sedimentation rate (ESR), 56 mm/h; and C-reactive protein (CRP), 18 mg/dL. A radiograph of the left knee showed a joint effusion without bony abnormalities, and subsequent magnetic resonance imaging revealed a large knee joint effusion (Figure 2). Joint aspiration yielded 8 mL of cloudy fluid. The WBC count of the synovial fluid was 1,980/ mm^3 with 78% neutrophils.

The patient was hospitalized, and empiric therapy with intravenous cefazolin (150 mg/kg per day in 3 divided doses) was administered for the presumptive diagnosis of septic arthritis. Blood culture and synovial fluid Gram stain and culture obtained at admission yielded negative results 2 days later. The antinuclear antibody, antistreptolysin O titer, and rheumatoid factor tests yielded negative results. The results of a urinalysis were normal, as were those of liver and kidney function tests.

Despite antibiotic treatment, the patient's fever and joint symptoms persisted, prompting a referral to our Pediatric Infectious Diseases Department. He continued to pass large amounts of watery stool (> 6 stools per day) and experienced lower abdominal cramping during hospitalization. Microscopic examination of his stool showed many leukocytes and erythrocytes. Stool cultures yielded negative results for

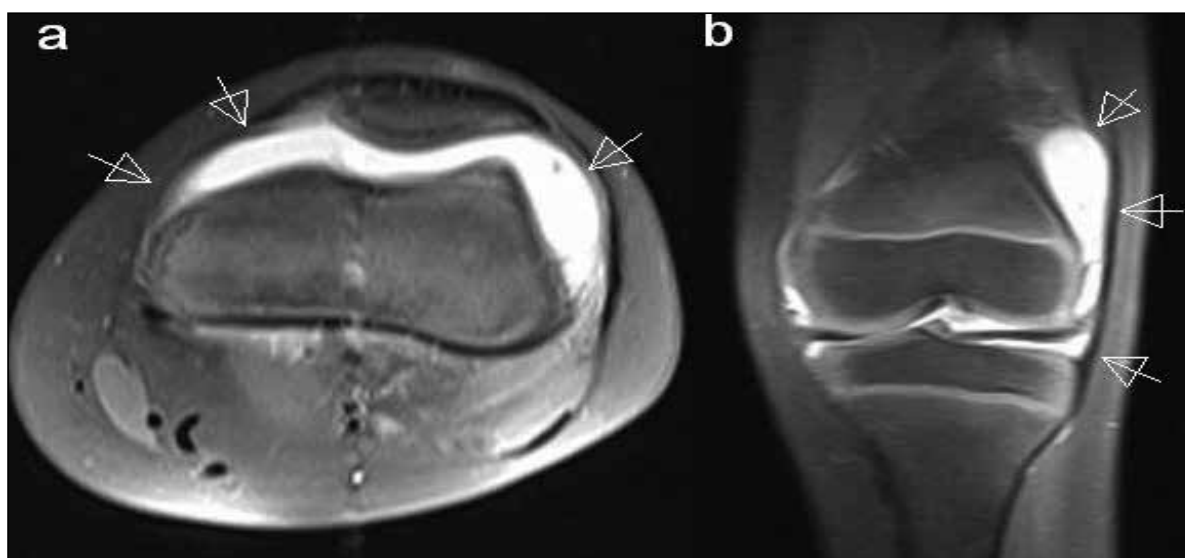


Figure 2. Axial (a) and coronal (b) plane fat-saturated T2-weighted magnetic resonance images of the left knee showed a large amount of joint effusion (white arrows).

Salmonella, *Shigella*, *Yersinia*, and *Campylobacter* species. On the fourth day of hospitalization, *C. difficile* toxin B was detected in the patient's stool sample by an immunochromatographic assay (Xpect *Clostridium difficile* Toxin A/B test). *C. difficile* toxin B gene (tcdB) was also subsequently detected by real-time polymerase chain reaction assay (Xpert; Cepheid, Sunnyvale, CA).

Based on the clinical features of the illness (diarrhea immediately following the antibiotic treatment and the positive stool test for *C. difficile* toxin B), we proposed a diagnosis of CDIAReA. Cefazolin was replaced by oral metronidazole (30 mg/kg/day in 4 divided doses), and oral ibuprofen (30 mg/kg/day in 3 divided doses) was also administered. Within 10 days, the patient's diarrhea and joint symptoms resolved, with normalization of the acute-phase response. The patient was discharged from the hospital after receiving oral metronidazole and ibuprofen for 10 days. An ultrasound scan of his left knee showed minimal effusion at the 3-week follow-up. The patient was asymptomatic over a follow-up period of 24 months.

Discussion

C. difficile infection-associated reactive arthritis (CDIAReA) has rarely been reported in children (4-8). In a recent study, the annual estimated incidence of CDIAReA among children in 3 pediatric health networks in the United States was 14/1000 (1). Children with CDIAReA present with pain, swelling, and limited movement in the joints, most commonly the knees and hips. The arthritis is asymmetric, migratory, and often accompanied by fever. Joint symptoms begin 1-2 weeks after the onset of diarrhea, and symptoms resolve within 1-3 weeks after treatment for *C. difficile* infection. Tell-tale signs of CDIAReA in children presenting with fever and severe joint pain include a history of migratory pain or polyarthralgia and preceding antibiotic associated diarrhea (1). Our patient's joint symptoms appeared 1 week after the onset of diarrhea and resolved within 10 days of initiating treatment for *C. difficile* infection.

Differentiating between septic arthritis and ReA of the knee in children can be challenging given their similar presentations: a non-traumatic, acutely painful knee accompanied by fever, joint effusion, and abnormalities in the blood and joint fluid (1,2). The initial clinical presentation in our case, which included fever, painful knee swelling, and elevated levels of inflammatory markers (CRP and the ESR), was suggestive of septic arthritis, which is mainly caused by *Staphylococcus aureus* in children.

It is essential to distinguish between septic arthritis and ReA in children since their treatments and complications differ. Septic arthritis requires prompt recognition and management; joint fluid drainage and antimicrobial therapy are the cornerstone strategies. ReA does not require a specific treatment in most cases. Antibiotics are usually not used in the treatment of ReA per se but might be indicated for the treatment of the underlying infection if there is evidence of an ongoing enteric or

genitourinary infection (2,3). The treatment protocol for *C. difficile* infection includes discontinuation of antimicrobial agents and administration of oral metronidazole (for mild-to-moderate disease) or oral vancomycin with or without intravenous metronidazole (for severe disease) (9). Nonsteroidal anti-inflammatory drugs can be helpful adjuncts for the management of joint pain and functional limitations (2). Our patient made a full recovery following discontinuation of cefazolin and administration of oral metronidazole and ibuprofen.

Conclusion

This case highlights that CDIAReA should be considered in the differential diagnosis of children presenting with acute and painful arthritis that develops in the setting of antibiotic associated diarrhea.

Informed Consent: The informed consent was given by the parents of the patient.

Peer-review: Externally peer-reviewed.

Author Contributions: Concept - MP, AT; Design - MP, AT; Supervision - AT, HT; Collection and/or Processing - MP, AT; Analysis and/or Interpretation - MP, AT, BED; Literature Review - MP, AT; Writing - MP, AT; Critical Review - MP, AT, BED, HT.

Conflict of Interest: No conflict of interest was declared by the authors.

Financial Disclosure: The authors declared that this study has received no financial support.

References

- Horton DB, Strom BL, Putt ME, Rose CD, Sherry DD, Sammons JS. Epidemiology of *Clostridium difficile* infection-associated reactive arthritis in children: an underdiagnosed, potentially morbid condition. *JAMA Pediatr* 2016;170:e160217.
- Burgos-Vargas R, Vazquez-Mellado J. Reactive arthritis. In: Petty RE, Laxer RM, Lindsley CB, Wedderburn LR (eds). *Textbook of Pediatric Rheumatology*. 7th ed. Philadelphia: Saunders Elsevier, 2016:563-9.
- Hill Gaston JS, Lillicrap MS. Arthritis associated with enteric infection. *Best Pract Res Clin Rheumatol* 2003;17:219-39.
- Cron RQ, Gordon PV. Reactive arthritis to *Clostridium difficile* in a child. *West J Med* 1997;166:419-21.
- Löffler HA, Pron B, Mouy R, Wulfraat NM, Prieur AM. *Clostridium difficile*-associated reactive arthritis in two children. *Joint Bone Spine* 2004;71:60-2.
- Durand CL, Miller PF. Severe *Clostridium difficile* colitis and reactive arthritis in a ten-year-old child. *Pediatr Infect Dis J* 2009;28:750-1.
- Dacheux C, Pruvost I, Herbaux B, Nectoux E. *Clostridium difficile* reactive arthritis in a 7-year-old child. *Arch Pediatr* 2012;19:607-11.
- Finger DR, Neubauer JV. Reactive arthritis following *Clostridium difficile* colitis in a 3-year-old patient. *J Clin Rheumatol* 1997;3:102-4.
- Schutze GE, Willoughby RE; American Academy of Pediatrics, Committee on Infectious Diseases. *Clostridium difficile* infection in infants and children. *Pediatrics* 2013;131:196-200.