

Missed Diagnosis of *Aspergillus Niger* Peritonitis in a Peritoneal Dialysis Patient with Standard Culture: Might Enriched Blood Culture Materials have an Advantage?

Bir Periton Diyalizi Hastasında Standart Kültür Materyalleriyle Tanı Konulamayan Aspergillus Niger Peritoniti: Zenginleştirilmiş Kan Kültürü Vasatları Avantaj Sağlayabilir mi?

ABSTRACT

Peritonitis is a major complication of peritoneal dialysis (PD). Although bacteria are the most responsible pathogens, fungi can also be the cause of this condition. *Candida* species (spp.) are common agents in fungal peritonitis with a rate of 70% while *Aspergillus* spp. is rare. *Aspergillus* spp. can lead to severe life threatening peritonitis in PD patients. Early diagnosis is essential for a good outcome but it may be difficult to detect the pathogen. Our observation in this case supports the hypothesis that the enriched culture materials designed for detecting blood pathogens can provide an advantage for determining the cause of peritonitis in peritoneal fluid. Clinicians should remember this clue when managing peritonitis, especially in patients who are refractory to empiric antibiotic therapy.

KEY WORDS: *Aspergillus niger*, Peritoneal dialysis, Peritonitis, Enriched blood culture materials

ÖZ

Peritonit periton diyalizinin en önemli komplikasyonlarından biridir. Sorumlu ajan çoğu zaman bakteriyel olsa da mantarlar da bu duruma neden olabilir. Mantar enfeksiyonlarının %70'inde *Candida* türleri sorumluyken *Aspergillus* türleri nadiren etkindir. Bu mantar ağır seyreden hayatı tehdit edebilen peritonit tablolarına yol açabilir. Erken tanı iyi klinik sonuç için çok önemlidir fakat bazen etkenin tespiti zor olabilir. Sunduğumuz bu olgudaki gözlemimiz zenginleştirilmiş kan kültür materyallerinin periton sıvısındaki etkenin tespitinde avantaj sağlayabileceği tezini desteklemiştir. Klinisyenler bu ipucunu özellikle ampirik antibiyotik tedavisine dirençli peritonitleri yönetirken hatırlamalıdır.

ANAHTAR SÖZCÜKLER: *Aspergillus niger*, Periton diyalizi, Peritonit, Zenginleştirilmiş kan kültürü materyalleri

INTRODUCTION

Peritonitis is a major complication of peritoneal dialysis (PD). Although bacteria are the most commonly responsible pathogens, fungi can also be a cause of this condition. *Candida* species (spp.) are the usual agents in fungal peritonitis with a rate of 70% while *Aspergillus* spp. is rare. *Aspergillus* spp. can lead to severe life threatening peritonitis in PD patients (1-3). Early diagnosis is essential for a good outcome but it may be difficult and may sometimes take a long time (3,4). Herein

we presented an *Aspergillus niger* (*A. niger*) peritonitis diagnosed with enriched blood culture materials in a PD patient while standard blood culture and Sabouraud-dextrose agar (SDA) were negative.

CASE REPORT

A 55-year-old man, who had end stage renal disease due to chronic glomerulonephritis and has been on continuous ambulatory peritoneal dialysis, was admitted with abdominal pain and cloudy peritoneal effluent. Peritonitis was established with the

İlhan KURULTAK¹

Mevlüt ÇERİ²

Kenan ARICAN³

Can KİNALP⁴

Salih CESUR⁵

T. Rıfık EVRENKAYA⁴

- 1 Trakya University Faculty of Medicine, Department of Nephrology, Edirne, Turkey
- 2 Pamukkale University Faculty of Medicine, Department of Nephrology, Denizli, Turkey
- 3 Haydarpaşa GATA Training Hospital, Department of Infectious Diseases, İstanbul, Turkey
- 4 Haydarpaşa GATA Training Hospital, Department of Nephrology, İstanbul, Turkey
- 5 Ankara Training and Research Hospital, Department of Infectious Diseases, Ankara, Turkey



Received : 24.05.2015

Accepted : 14.10.2015

Correspondence Address:

İlhan KURULTAK

Trakya Üniversitesi Tıp Fakültesi,

Nefroloji Bilim Dalı, Edirne, Turkey

Phone : +90 284 236 09 09

E-mail : ilhankurultak@yahoo.co.uk

symptoms, clinical findings and detection of 2540 leukocytes/mm³ in the peritoneal effluent. Giemsa stain revealed that 92% of the leukocytes were polymorphonuclear leukocytes. This was the fourth episode of peritonitis in fourteen years. The last peritonitis attack was approximately one year ago and the pathogen was *Staphylococcus epidermidis* that was treated with cefazolin 1 gr/d iv bd for 14 days. Laboratory data at last admission were 21 300 leukocytes/mm³, hematocrit 36%, platelet count 435 000/mm³, and CRP 36.8 (0-0.8) mg/dL. Peritoneal effluent samples were obtained for bacterial culture and empiric therapy with iv. ceftazidime/vancomycin was commenced. On the third day of the treatment, there was minimal clinical improvement and a significant decrease in the leukocyte count in the peritoneal effluent. The cultures taken on the first day of admission were negative. The bacterial cultures of peritoneal fluid were repeated with the samples that were obtained after centrifugation of the 50 cc effluent. Acid-resistant staining and fungal/tuberculosis cultures were also performed. No acid-resistant bacilli were found with the Ehrlich-Ziehlson stain. Upright X-ray and abdominal ultrasonography was normal. CRP was 18 mg/dL, peritoneal effluent was still cloudy and leukocyte count was 1590 leukocytes/mm³ on the sixth day. All cultures were negative at that time. The PD catheter was removed and renal replacement therapy was switched to hemodialysis on the seventh day. The microbial evaluation of the PD catheter was negative. Centrifuged peritoneal fluid culture was repeated with various specimens; three of

SDA, conventional blood cultures and automated blood culture systems (BD-BACTEC Peds Plus™, Aerobic/F Medium, Ireland). Black patched areas were detected in two of three automated blood culture systems (the remaining one was positive after 96 hours incubation) after 72 hours incubation on the ninth day of treatment while all of conventional blood cultures and SDA were negative. Direct microscopy revealed *A. niger* with typical angular dichotomously branching (with degrees of 45) narrow septated hyaline hyphae (3 to 6 microns wide) (Figure 1) (5,6). The SDA plates (Merck, Darmstadt, Germany) was inoculated with the sample obtained from the positive blood culture vial for confirmation (Merck, Darmstadt, Germany). At the end of three days *A. niger* colonies were observed all over the plate surface (Figure 2). The microbiology laboratory reported colonization by *A. niger*. The galactomannan (GM) antigen test (Platelia Aspergillus EIA; Bio-Rad, France) was also positive in the blood and peritoneal fluid. These culture, microscopy, GM levels and clinical findings led to the diagnosis of *A. niger* peritonitis. Thorax and abdomen tomography was performed to rule out the invasion of other organs and was normal. Amphotericin B was added to the current antibiotic regimen while antibacterial drugs were stopped at the end of two weeks. GM test levels were studied weekly and decreased to the cut off level (GI<0.8) after two months. Amphotericin B was administered for ten weeks. The patient was well at the end of the treatment. Hemodialysis was continued as the renal replacement therapy.

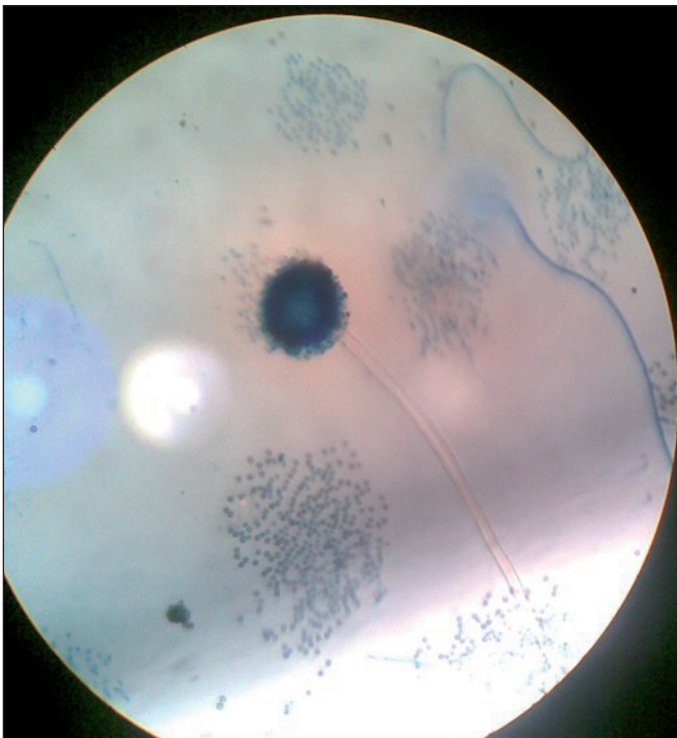


Figure 1: Appearance of the sample obtained from the automated blood culture system (BD-BACTEC plus, Aerobic/F culture vials, Ireland) on direct microscopy.

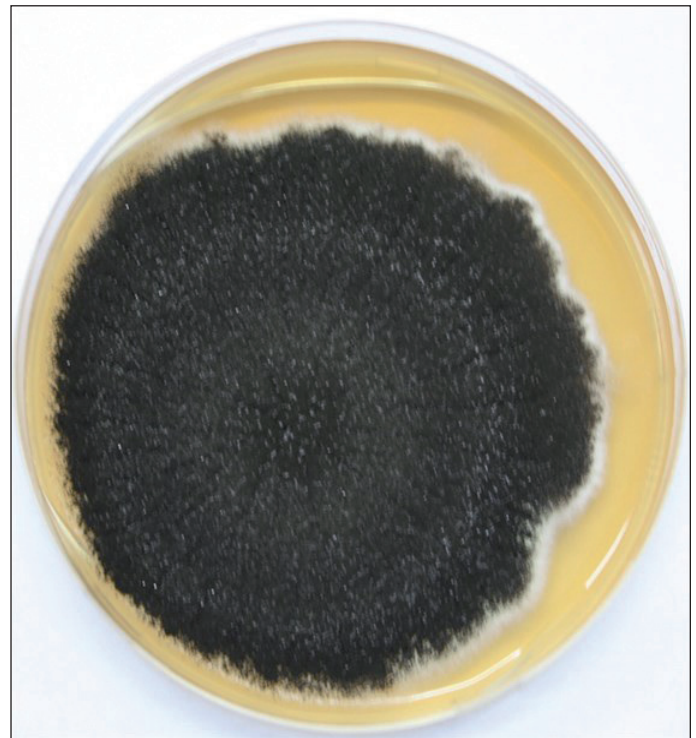

Figure 2: Appearance of standard plate culture after two days of inoculation with the same sample.

DISCUSSION

Immediate using of empiric antibiotic therapy is important in PD-related peritonitis but detection of the responsible pathogen is the most important factor for appropriate antimicrobial therapy and a good outcome. Although various cultures are available for this purpose, they can be insufficient in some conditions such as *A.niger* peritonitis in a PD patient.

The centrifugation of peritoneal fluid may increase the possibility of growing the infective agent (95% positivity while 80% in the standard manner) in case of peritonitis in PD patients (7). The culture type is also important for growing the microorganism. In the present case, fungal colonies were observed in two of three automated blood culture system vials (BD-BACTEC Peds Plus™, Aerobic/F Medium, Ireland) as black patched areas at the end of 72 hours incubation whereas the SDA plates and conventional blood cultures were all negative at that time. A positive culture is not enough by itself for a definitive diagnosis of aspergillosis. Demonstration of hyphal elements in affected tissues is essential (8). However, this invasive application cannot be performed in all patients like ours. Making the diagnosis is usually difficult in this condition. It requires both positive microbiological cultures from sterile body sites and positive serological tests such as specific antibodies and antigens (8,9). As molecular tests and advanced culture (Czapek yeast extract agar) were unavailable for definitive identification, the diagnosis in our case was made with the culture, microscopic evaluation, GM levels and clinical findings.

There are some difficulties because of the high contamination risk of culture specimens in microbiology laboratories. In addition, the lower sensitivity of serological tests (GM, beta-D-glucan, antibodies, etc.) is well known (3,8). GM is a component of the *Aspergillus* spp. cell wall and this antigen can be detected in infected sites in the body. The double-sandwich enzyme immunoassay has therefore been used in the last decade and the cut-off GM index has determined as 0.8 for significant sensitivity and specificity (9). However, it can be false positive in patients that were treated with beta-lactams, especially piperacillin-tazobactam, and in patients infected with filamentous fungi (*Fusarium* spp. and *Histoplasma capsulatum*) (10-12). In our case we obtained all cultures from the peritoneal fluid under sterile conditions and GM levels in both peritoneal fluid and blood continued to be high for six weeks after stopping the antibacterial treatment. Beta-D-glucan is a structural cell membrane polysaccharide in most fungal pathogens except *Mucor* and *Cryptococcus* species (9). The detection of this antigen can be effective in determining invasive fungal infections with a sensitivity of 90%, specificity of 100% and negative predictive value of 97% if 20 pg/mL is accepted as the plasma cut-off value (13). We were not able to use this antigen because the beta-D-glucan test was not available in our laboratory.

Automated blood culture systems such as BD-BACTEC plus and Aerobic/F culture vials contain large amounts of soybean-casein digest broth media and have resins for antibiotic neutralization. They therefore require little sample (≤ 3 mL of blood) compared with standard tests (14). One study showed that the blood culture bottles that include more resin have significantly higher rates of positivity than routine cultures (15). These data prompted us to use enriched blood culture materials although this matter is not clear for *A. niger* peritonitis. Further investigations are needed on whether BD-BACTEC plus culture vials are superior to other blood culture materials in *A. niger* cases.

CONCLUSION

In our opinion, this case is important to demonstrate that enriched culture materials designed for detecting blood pathogens can provide an advantage for determining the cause of peritonitis in peritoneal fluid. Clinicians should remember this clue when managing peritonitis, especially in cases refractory to empiric antibiotic therapy.

REFERENCES

1. Nagappan R, Collins JF, Lee WT: Fungal peritonitis in continuous ambulatory peritoneal dialysis: The Auckland experience. *Am J Kidney Dis* 1992;20:492
2. Tanis BC, Verburgh CA, van't Wout JW, van der Pijl JW: Aspergillus peritonitis in peritoneal dialysis: Case report and a review of the literature. *Nephrol Dial Transplant* 1995;10:1240
3. Geiss HK: Peritoneal aspergillosis: Pitfalls in the diagnosis of the rare disease. *Nephrol Dial Transplant* 1995;10:1124
4. Michel C, Courdavault L, al Khayat R, Viron B, Roux P, Mignon F: Fungal peritonitis in patients on peritoneal dialysis. *Am J Nephrol* 1994;14:113
5. De Hoog GS, Guarro J, Gené J, Figueras MJ: Atlas of Clinical Fungi, 2nd ed. Utrecht: Centraalbureau voor Schimmelcultures, 2000
6. Hope W W, Walsh TJ, Denning DW: Laboratory diagnosis of invasive aspergillosis. *Lancet Infect Dis* 2005;5:609-622
7. Li PK, Szeto CC, Piraino B, Bernardini J, Figueiredo AE, Gupta A, Johnson DW, Kuijper EJ, Lye WC, Salzer W, Schaefer F, Struijk DG; International Society for Peritoneal Dialysis: Peritoneal dialysis-related infections recommendations: 2010 update. *Perit Dial Int* 2010;30:393-423

8. De Pauw B, Walsh TJ, Donnelly JP, Stevens DA, Edwards JE, Calandra T, Pappas PG, Maertens J, Lortholary O, Kauffman CA, Denning DW, Patterson TF, Maschmeyer G, Bille J, Dismukes WE, Herbrecht R, Hope WW, Kibbler CC, Kullberg BJ, Marr KA, Muñoz P, Odds FC, Perfect JR, Restrepo A, Ruhnke M, Segal BH, Sobel JD, Sorrell TC, Viscoli C, Wingard JR, Zaoutis T, Bennett JE: Revised definitions of invasive fungal disease from the European Organization for Research and Treatment of Cancer/Invasive Fungal Infections Cooperative Group and the National Institute of Allergy and Infectious Diseases Mycoses Study Group (EORTC/MSG) Consensus Group. *Clin Infect Dis* 2008;46:1813
9. Ates O, Metan G, Dundar T, Kiziltepe M, Kocyigit I, Unal A, Sipahioglu M, Oymak O, Tokgoz B: Diagnosis of *Aspergillus niger* peritonitis in a peritoneal dialysis patient by peritoneal galactomannan and -D-glucan detection. *Perit Dial Int* 2013;33: 216-218
10. Tortorano AM, Esposto MC, Prigitano A, Grancini A, Ossi C, Cavanna C, Cascio GL: Cross-reactivity of *Fusarium* spp. in the *Aspergillus* Galactomannan enzyme-linked immunosorbent assay. *J Clin Microbiol* 2012;50:1051
11. Wheat LJ, Hackett E, Durkin M, Connolly P, Petraitiene R, Walsh TJ, Knox K, Hage C: Histoplasmosis-associated cross-reactivity in the BioRad Platelia *Aspergillus* enzyme immunoassay. *Clin Vaccine Immunol* 2007;14:638
12. Mennink-Kersten MA, Donnelly JP, Verweij PE: Detection of circulating galactomannan for the diagnosis and management of invasive aspergillosis. *Lancet Infect Dis* 2004;4:349
13. Obayashi T, Yoshida M, Mori T, Goto H, Yasuoka A, Iwasaki H, Teshima H, Kohno S, Horiuchi A, Ito A: Plasma (1→3)-β-D-glucan measurement in diagnosis of invasive deep mycosis and fungal febrile episodes. *Lancet* 1995;345:17-20
14. Becton Dickinson Company; Medical Supplies, Devices and Thecnology; laboratory Products, Antibodies. Erişim: <http://www.bd.com/ds/productCenter/BC-Bactec.asp> accessed in September 2015
15. Blondeau JM, Pylypchuk GB, Kappel JE, Pilkey B, Lawler C: Comparison of bedside- and laboratory-inoculated Bactec high- and low- volume resin bottles for the recovery of microorganisms causing peritonitis in CAPD patients. *Diagn Microbiol Infect Dis* 1998;31:281-287