

## Non-cardiac Tl-201 uptake on myocardial perfusion SPECT study

### *Miyokard perfüzyon SPECT çalışmasında ekstrakardiyak Tl-201 tutulumu*

Doğangün Yüksel, Olga Yaylalı, Turgut Serdaş, F Suna Kırac, Mustafa Kılıç\*

Departments of Nuclear Medicine and Cardiology\*, Medical School, Pamukkale University, Denizli, Turkey

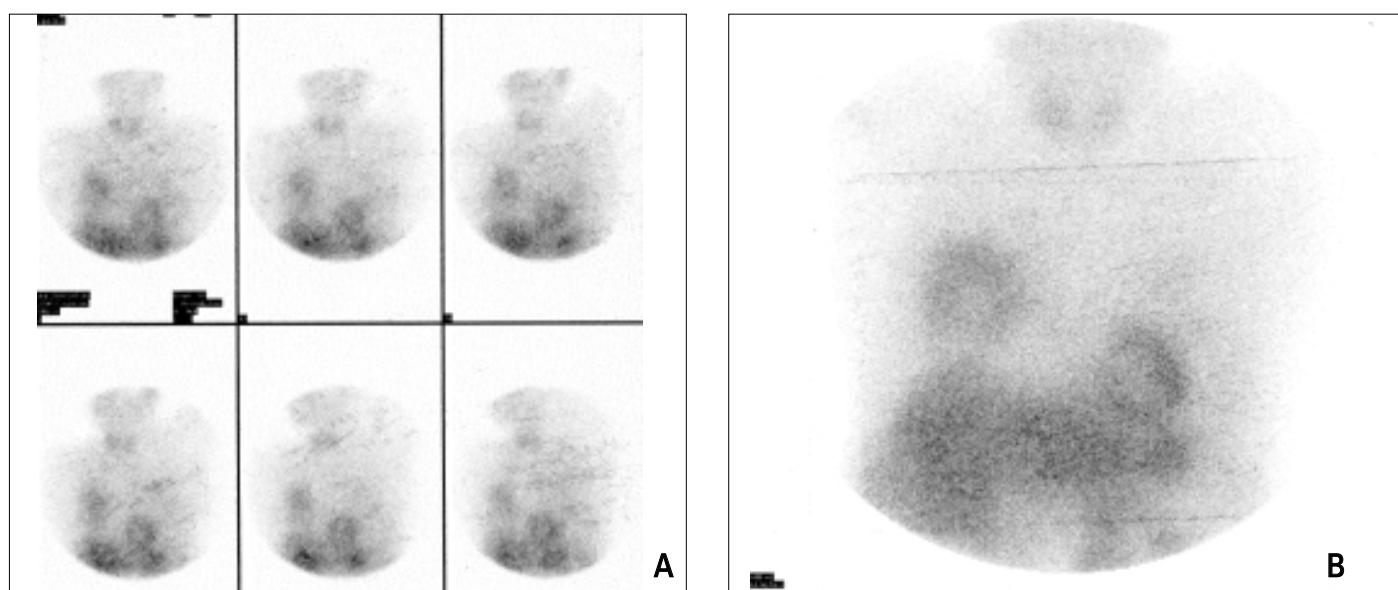
#### Introduction

An increased non-cardiac uptake of Thallium-201 (Tl-201) and Tc-99m sestamibi (MIBI) may be seen on the cine view of myocardial perfusion single photon emission computed tomography (SPECT). This unusual radiopharmaceutical accumulation may be resulted from malignant lesion or it may be a normal variation (1-3). In this case report, we presented the patient with the high extracardiac Tl-201 accumulation in the right parasternal region.

#### Case Report

A 70-year-old man with angina pectoris was admitted to the Department of Nuclear Medicine for the evaluation of isc-

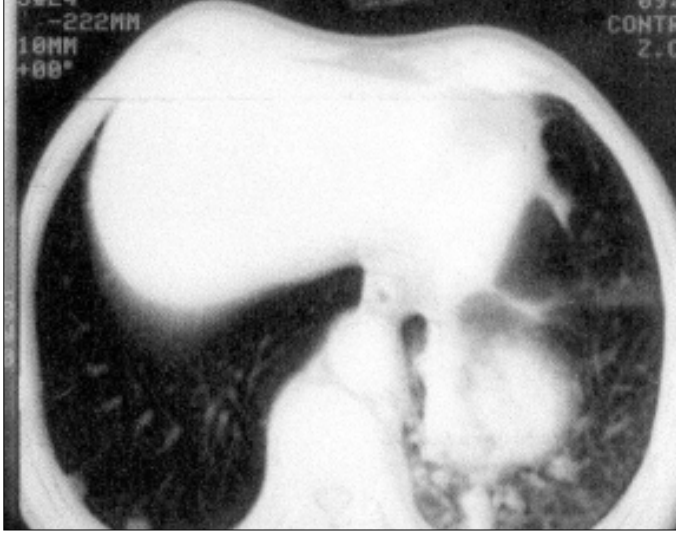
hemic heart disease. He has suffered from substernal chest pain, fatigue, dyspnea, cough with sputum for four months and has been smoking the two packets of cigarettes per day for forty years. Pharmacological stress-redistribution Tl-201 myocardial perfusion SPECT study was performed following 3 mCi Tl-201 intravenously injection. An intense Tl-201 uptake was observed on the lower region of right lung (Fig. 1) during the evaluation of stress and redistribution SPECT raw data. There were three focal opacifications in the inferior right lung on the patient's chest X-ray. After that, patient underwent thorax computerized tomography and the lesions with the probability of malignancy in the superior and middle segments of the right lung were detected (Fig. 2). The histopathological diagnosis was an adenocarcinoma. Despite therapy, the patient died two months later.



**Figure 1.** An increased extracardiac uptake pattern (black arrows) views in the right parasternal region of raw projection images with Tl-201 SPECT myocardial perfusion imaging (A) and anterior static image (B)

## Discussion

During the assessment of myocardial perfusion SPECT studies, the incidence of radiopharmaceutical uptake in extracardiac



**Figure 3.** Thorax computerized tomography image shows a malignant lesion with peripheral infiltration in the right lung.

diac regions is about 2.8 % and the probability of malignancy of these lesions is 8-10 %. The non-cardiac accumulations of both Tl-201 and Tc-99m MIBI are most frequently related with the lung and breast malignancies. Therefore, the raw data have to be carefully interpreted during evaluation of myocardial perfusion study. If increased radiopharmaceutical accumulations in the extracardiac areas are observed, they must be reported to provide the early diagnosis and treatment of malignant lesions (1-3).

## References

1. Williams KA, Hill KA, Sheridan CM. Noncardiac findings on dual-isotope myocardial perfusion SPECT. *J Nucl Cardiol* 2003; 10: 395-402.
2. Kim CK, Jung E, Yun M, et al. A normal variant on Tl-201 and Tc-99m MIBI whole-body imaging: the superior right atrial wall (auricle) and superoanterior right ventricular wall are often seen as mediastinal lesions. *Clin Nucl Med* 2001; 26: 412-8.
3. Yamamoto Y, Nishiyama Y, Satoh K, et al. Comparative evaluation of Tc-99m MIBI and Tl-201 chloride SPECT in non-small-cell lung cancer mediastinal lymph node metastases. *Clin Nucl Med* 2000; 25:29-32.