



## Costal Exostosis Leading Diaphragm Laceration and Bronchiectasis with Bronchial Web

### Diafragma Laserasyonu ve Bronşektaziye Yol Açan Bronşial Web ile Birlikteki Kostal Ekzositoz

Bronşial Weble Birlikteki Kostal Ekzositoz / Costal Exostosis with Bronchial Web

Gökan Yüncü<sup>1</sup>, Cansel Atinkaya<sup>1</sup>, Kiter Göksel<sup>2</sup>, Ayşe Kasal<sup>3</sup>, Figen Türk<sup>1</sup>

<sup>1</sup>Pamukkale University, Faculty of Medicine Department of Thoracic Surgery, <sup>2</sup>Pamukkale University, Faculty of Medicine Department of Chest Disease, <sup>3</sup>Ministry Hospital Of Denizli, Department of Chest Disease, Denizli, Turkey

14-17 Mayıs 2009 tarihleri arasında, Pine Bay Hotel, Kuşadası'nda gerçekleştirilen 5. Türk Cöğüs Cerrahisi Kongresi. Poster olarak sunulmuştur.

#### Özet

Diğer anomalilerle birlikte görülen ekzositoza ait torasik komplikasyonlar son derece nadirdir. 40 yaşında erkek hasta sağ yan ağrısı şikayeti ile başvurdu. Toraks bilgisayarlı tomografide plevrayı ve diafragmaı iterek komşu akciğer ve karaciğere bası oluşturan 2,5 cm uzunluğunda ekzositoz gözlemlendi. Orta ve alt lobta bronşektazi saptandı. Bronkoskopide orta lob lümeninde web lezyon mevcuttu. Operasyonda diafragma sütürlere onarıldı. Bilobektomi inferior uygulandı ve 10. kosta parsiyel olarak ekzositozla birlikte çıkarıldı. Literatürde kosta malformasyonuna bağlı diafragma laserasyonu ve bronşektaziye yol açan ve birlikte bronşial lümeninde web gözlenen ekzositozlu olgu oldukça nadirdir.

#### Anahtar Kelimeler

Kostal Ekzositoz; Diafragma Laserasyonu; Bronşial Web

#### Abstract

Thoracic complications belong to exostosis with the other abnormality are extremely rare. A 40 year-old man presented with right-sided pleuritic chest pain. Computed tomographic scan of the chest revealed exostosis length 2.5 cm pushing pleura and diaphragm and compressing adjacent to lung and liver. Middle and lower lobe bronchiectasis was also identified. There were a web lesion in bronchial lumen at the level of middle lobe at bronchoscopy. In operation, diaphragm laceration was repaired with sutures. Bilobectomy inferior was performed and 10th costa was partially resected together with exostosis. Exostosis cases which lead to diaphragm laceration and bronchiectasis in addition with bronchial web as we present in this case are quite rare.

#### Keywords

Costal Exostosis; Diaphragm Laceration; Bronchial Web

DOI: 10.4328/JCAM.365

Received: 06.10.2010 Accepted: 07.11.2010 Printed: 01.07.2012 J Clin Anal Med 2012;3(3): 334-5

Corresponding Author: Cansel Atinkaya, Pamukkale University, Faculty of Medicine, Department of Thoracic Surgery, 20020, Denizli, Turkey.

T.: +905446745053 F.: +90 25821 34922 E-Mail: catinkaya@gmail.com

## Introduction

Exostosis (osteochondroma) is the most common benign bone neoplasm [1]. The affected persons are generally short and those with multiple skeletal deformations. Several exostosis complications have been reported such as compressing or penetration to visceral organs and affecting nerves, vessels and surrounding tissues [2-3]. Such complications are generally observed in children and adolescents. Although hemothorax cases have been reported, exostosis cases which lead to diaphragm laceration and bronchiectasis in addition with endobronchial web as we present in this case are quite rare.

## Case Report

A 40 old-age male patient admitted with complaint of right side pain which has last for six months. His family history was negative in multiple exostoses. No palpable lesion was observed at physical examination of thorax including other skeleton system. Laboratory values were at the normal ranges. Density increase compatible with consolidation at right lower zone at postero-anterior chest radiography. In thorax computerised tomography, an accessory costa which originated from posterolateral section of right 10th rib pushing pleura and diaphragm, and compress adjacent lung and liver, and a lesion that suggesting osteochondroma with constant medullar cortex in 2,5 cm length were observed (Figure 1A). Bronchiectasis was defined at middle and lower lobes (Figure 1B).

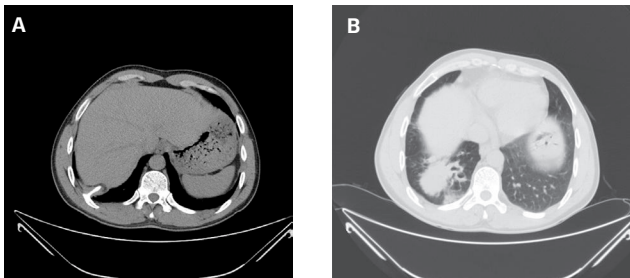


Figure 1. Exostosis at right 10th costa (A), Bronchiectasis area at right lower lobe and adjacent mass-like appearance. (B)

A web was identified bronchial lumen at the level of middle lobe and in particular left lower bronchial penetration was markedly narrowed during bronchoscopic examination. At operation, a bone tissue of about 5 cm length originated from 10th rib penetrating diaphragm, spread into lung parenchyma, bronchiectasis was observed possibility due to web lesion in bronchial lumen and it could be exerted from parenchyma only with sharp dissection. The diaphragm was repaired with primary sutures. Bilobectomy inferior was performed and 10th rib partially exerted together with exostosis (Figure 2). The patient was discharged at postoperative 8th day without any problem.

## Discussion

Although exostosis is seen in particular at long bones, yet it can often seen also at skull base, vertebrae, costas, spacula and pelvis. In general, it is well tolerated. Its complications are rare, but large multiple exostoses can cause to joint dislocation, compress to central or peripheral nerves or vascular structures. Costal exostosis often presents as a bone spur and it can mechanically damage surrounding structures through penetration [4-5]. Most common thoracic complication of the exostosis is to form laceration at parietal and visceral pleura.

Rupturing the diaphragm and pleura by the sharp edges of

intrathoracic exostosis can lead a situation that can cause to mortality. Recurrent chest infections and locular empyema are often observed. In our patient, there was also sacular bronchiectasis and intraoperatively defined diaphragm and lung parenchyma penetration. If the diagnosis was delayed, hemothorax or serious complications due to diaphragm rupture would be occurred at the patient. They should be removed surgically when compression or complication were observed. Exostosis is seen approximately 1 at 50.000. It is observed at 8, 11 and 19th chromosomes as a result of the mutations. Benign exostoses occasionally can transform to condrosarcom with a rate of %1-3 [3]. They present autosomal dominant transmission characteristic. The incidence is higher in males in the literature as seen in our patient.

Costa exostosis is seen relatively less and to diagnose it with plan radiography may be difficult. Chest tomography generally can help the diagnosis. It also shows whether there is a pleural or pulmonary abnormality or not. Gradually growing of costa exostoses over time and their asymptomatic progress lead to dramatic outcomes. It can also cause to localized bronchiectasis due to sneaking presentation. Localized bronchiectasis was observed as secondary to exostosis. Exostosis should be kept in the mind at the differential diagnosis at young patients with recurrent pneumonia and familial history.

It can damage the surrounding structure in long term. Progressing of the destructive processes can be prevented and curative treatment can be provided by early diagnosis in such cases.

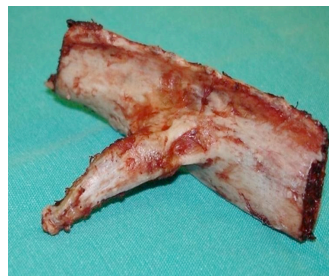

Figure 2. Exostosis appearance at the excised costal material.

Because of the presence of multiple damages and advanced bronchiectasis required bilobectomy at our patient, thoracotomy was chosen in first place.

Hemothorax cases have been most frequently reported in the literature. Pneumothorax accompanying to hemothorax cases and also in one patient

exostosis led to hiccup were observed [6]. Bronchiectasis and spinal cord compression are rarely seen complications [7]. Breast implantation rupture due to costal exostosis has been also reported [8].

While costal exostosis should be kept in mind at the differential diagnosis of pleuritic chest pain, recurrent pneumonia and spontaneous hemothorax cases, and also pulmonary and bronchial abnormalities and complications due to penetration should be considered at costal exostosis cases.

## References

- Hajjar WM, El-Medany YM, Essa MA, Rafay MA, Ashour MH, Al-Kattan KM. et al. Unusual Presentation of Rib Exostosis. *Ann Thorac Surg.* 2003;75:575-7.
- Hanrahan PS, Edelman J, Brash S. Spontaneous hemarthrosis associated with a exostosis of the talus. *J Rheumatol.* 1987; 14: 171.
- Schmale GA, Conrad EU, Raskind WH. The natural history of hereditary multiple exostoses. *J Bone Joint Surg.* 1994; 76A: 986-992.
- J. A. Nick, D. A. Lynch, M. I. Schwarz, M.E. Hanley. A Thoracic Complication Of Hereditary Multiple Exostoses In An Adult. *Respiratory Medicine.* 1999; 93, 217-21.
- Harrison NK, Wilkinson J, O'Donohue J, Hansell D., Sheppard M.N., Goldstraw P.G., et al. Osteochondroma of the rib: an unusual cause of haemothorax. *Thorax* 1994; 49:618-619.
- Marco Alifano, Mohib Morcos, Thierry Molina, Regnard JF. An unusual cause of hiccup: costal exostosis. Treatment by video-assisted thoracic surgery. *European Journal of Cardio-thoracic Surgery.* 2003;23: 1056-1058.
- Tang AT, Hulin SJ, Weeden DF. Surgical treatment of an unusual cause of localized bronchiectasis. *Ann Thorac Surg.* 2000;69:1586-7.
- Chiang YC, Johnson CS, Lin PY. Costal Exostosis as a Possible Cause of Breast Implant Rupture. *Plastic and Reconstructive Surgery.* 2009;123(6): 200e-202e.