

Protective effects of aspirin and vitamin C against corn syrup consumption-induced cardiac damage through sirtuin-1 and HIF-1 α pathway

Halil Aşçı, Mustafa Saygın*, Şükriye Yeşilot, Şenay Topsakal¹, Fatma Nihan Cankara, Özlem Özmen², Mehtap Savran³

Departments of Pharmacology *Physiology, Faculty of Medicine, Süleyman Demirel University; Isparta-Turkey

¹Department of Endocrinology and Metabolism, Faculty of Medicine, Pamukkale University; Denizli-Turkey

²Department of Pathology, Faculty of Veterinary Medicine, Mehmet Akif Ersoy University; Burdur-Turkey

³Provincial Directorate of Health, Republic of Turkey Ministry of Health; Antalya-Turkey

ABSTRACT

Objective: The aim of this study was to investigate the protective effects of aspirin (AS) and vitamin C (VC) against cardiac damage induced by chronic corn syrup (CS) consumption via a mechanism involving sirtuin-1 (ST-1), hypoxia-inducible factor-1 α (HIF-1 α), and the caspase-3 pathway in rats.

Methods: Forty male Sprague–Dawley rats (14–16 weeks) that weighed 250–300 g were randomly distributed into 5 groups, each containing 8 rats: control group, CS+AS group, CS+VC group, CS+AS+VC group, and CS group. AS (10 mg/kg/day) and VC (200 mg/kg/day) were orally given to the rats. F30 (30% fructose syrup solution) was given to the rats in drinking water for 6 weeks. The rats were sacrificed by exsanguination 24 h after the last administration. Blood samples and tissue were collected for biochemical, histopathological, and immunohistochemical examinations. Non-parametric Kruskal–Wallis test and Mann–Whitney U test used for the parameters without normal distribution and ANOVA and post-hoc LSD tests were used for parameters with a normal distribution to compare groups.

Results: Uric acid, creatine kinase (CKMB), and lactate dehydrogenase (LDH) levels were increased in the CS group compared with the control group (1.45 \pm 0.39 and $p=0.011$; 3225.64 \pm 598.25 and $p=0.004$; 3906.83 \pm 1064.22 and $p=0.002$, respectively) and decreased in all the treatment groups. In addition, increased levels of MDA and decreased activity of CAT in the CS group (0.172 \pm 0.03 and $p=0.000$; 0.070 \pm 0.005 and $p=0.007$, respectively) were reversed with AS and VC therapy. A decrease in ST-1 activity and increases in caspase-3 and HIF-1 activities corrected by VC and AS therapy were observed.

Conclusion: AS and VC, which display antioxidant and antiapoptotic activities, ameliorated cardiac damage induced by chronic fructose consumption by increasing the levels of ST-1 and decreasing the levels of HIF-1 α and caspase-3. (*Anatol J Cardiol* 2016; 16: 648-54)

Keywords: corn syrup, cardiac damage, ST-1, HIF-1 α , caspase-3, oxidative stress.

Introduction

In the United States, corn is used as the primary starch for producing fructose syrup (1). Corn syrup (CS) is used as an additional sweetener in snack foods, fruit juice, meat and fish products, dairy products, frozen dinners, and other products because it adds more sweetness, does not mask the original taste, is cheaper, and retards satiety (2). The wide usage of CS causes several adverse metabolic disorders, such as fatty liver disease, obesity, hypertension, type 2 diabetes mellitus, and metabolic syndrome (3).

Insulin resistance and increasing levels of uric acid in plasma, which contribute to the development of these diseases, have been observed during chronic consumption of CS (4). Similarly, both these metabolic problems are regarded as risk factors for coronary disorders (5, 6). Hyperuricemia increases

free oxygen radicals and causes oxidative stress via redox-dependent pathways in cells (7). These adverse effects reduce the production of nitric oxide on account of vascular endothelial damage. As a result, endothelial injury-induced nitric oxide deficiency can cause hypertension development. (8, 9). Cardiac damage markers such as creatine kinase (CKMB) and lactate dehydrogenase (LDH) also increased in hyperuricemia-related cardiac injuries (10, 11).

Sirtuin-1 (ST-1) is a member of the ST protein family and plays a crucial role in metabolic health by deacetylating many target proteins such as histones in muscles, adipose tissue, heart, and endothelium. ST-1 improves many degenerative diseases associated with neurodegeneration, cancer, and metabolic disorders including glucose intolerance and insulin resistance (12). ST-1 enhances endothelial nitric oxide synthase and performs anti-

Address for Correspondence: Dr. Mustafa Saygın, Süleyman Demirel Üniversitesi
Tıp Fakültesi, Fizyoloji Bölümü 32260 Isparta-Türkiye

Phone: +90 246 211 36 05 Fax: +90 246 237 11 65 E-mail: fizyolog@gmail.com

Accepted Date: 03.07.2015 **Available Online Date:** 15.09.2015

© Copyright 2016 by Turkish Society of Cardiology - Available online at www.anatoljcardiol.com
DOI:10.5152/AnatolJCardiol.2015.6418



inflammatory functions in endothelial cells and macrophages, downregulating the expression of various pro-inflammatory cytokines (13, 14). Activation of ST-1 regulates oxidative stress, inhibits some pro-inflammatory pathways, and reduces apoptosis, protecting the heart from cardiovascular diseases (15-17). Absence of ST-1 triggers chronic inflammation and insulin resistance (18).

Hypoxia-inducible factor-1 α (HIF-1 α) is a transcription factor that plays a regulatory role in hypoxia and is necessary for maintaining homeostasis in hypoxic conditions. Also, the levels of HIF-1 α increase in these conditions (19-22).

Aspirin (AS), which contains acetylsalicylic acid, is different from other non-steroidal anti-inflammatory agents due to an irreversible inhibition of cyclooxygenase that results in the inhibition of inflammatory mediators. Also, AS has antioxidant properties, as has been shown in many studies (23, 24).

Vitamin C (VC) is one of the most powerful antioxidant agents that can easily pass through membranes and is naturally important for body functions. It plays a role in several hydroxylation reactions and inhibits lipid peroxidation in human plasma and cell membranes (25, 26).

Although the antioxidant capacity of AS and VC has been well studied, there are not enough studies about the protective effects of these agents on hyperuricemia-related cardiac damage induced by CS consumption. This study aimed to investigate the protective effects of AS and VC on cardiac damage induced by chronic CS consumption via a mechanism involving ST-1, HIF-1 α , and caspase-3 immunoreactivity.

Methods

Study design

All experiments in this study were performed in accordance with the guidelines for animal research from the National Institutes of Health and were approved by the Committee on Animal Research at Süleyman Demirel University, Isparta (23/02/2012-01).

Forty male Sprague–Dawley rats weighing 250–300 g (14–16 weeks) were used in this study. The rats were placed in a temperature (21°C–22°C) and humidity (60% \pm 5%)-controlled room with a 12:12-h light:dark cycle. The rats were maintained in Euro type 2 cages during the 6 weeks of the study. All rats were fed with a standard commercial chow diet (Korkuteli Yem) composed of 88% dry material (mostly oat crust), 23% protein, 7% cellulose, 8% ash that does not dissolve in 2% HCl, 1%–1.8% Ca²⁺, 0.9% PO₄³⁻, 0.5%–0.8% Na, 1% NaCl, 0.3% methionine, and 1% lysine.

Chemicals

F30 CS was obtained from Toposmanoglu (Isparta, Turkey) and contained approximately 24% fructose and 28% dextrose in 73% syrup total solids. During the experiment, 30% F30 solution was added to drinking water for each CS-fed rat.

AS 500 mg tablets (Aspirin, Bayer, Turkey), which are a commercial form of acetylsalicylic acid, were used for treatment. The

single dose per day was 10 mg/kg orally during the experiment.

VC 1000 mg tablets (Redoxon, Bayer, Turkey), which are a commercial form of VC, were used for treatment. The single dose per day was 200 mg/kg orally during the experiment.

Study groups

The rats were randomly divided into 5 groups with 8 rats each. The groups were as follows:

- 1- Control group (Only provided unlimited feed and water)
- 2- CS+AS group (30% F30 in drinking water + 10 mg/kg/day AS, orally)
- 3- CS+VC group (30% F30 in drinking water + 200 mg/kg/day VC, orally)
- 4- CS+AS+VC group (30% F30 CS in drinking water + 10 mg/kg/day AS + 200 mg/kg/day VC, orally)
- 5- CS group (30% F30 in drinking water).

F30 (30% fructose syrup solution) was given to rats in drinking water for 6 weeks.

Twenty-four hours after the last administration of the drugs, all rats were sacrificed with intraperitoneal ketamine 10% (Alpha, Alfas IBV) and 2% xylazine (Alfaz's, Alfas IBV). After abdominal incision, blood samples were collected and cardiac tissues were quickly removed. Cardiac tissues were divided equally into 2 longitudinal sections. One-half of the cardiac tissues were placed in formaldehyde solution for routine histopathological and immunohistochemical examinations. The other half of the cardiac tissues were homogenized and kept at -80°C for biochemical studies. Blood samples were extracted to determine the serum levels of CKMB, LDH, and uric acid parameters.

Biochemical analysis

One-half of the heart tissue samples were collected for biochemical analyses. Tissues were homogenized in a motor-driven tissue homogenizer (IKA Ultra-Turrax T25 Basic, IKA Labortechnik, Staufen, Germany) and sonicated (UW-2070, Bandelin Electronic, Germany) with phosphate buffer (pH 7.4). Unbroken cells, cell debris, and nuclei were sedimented by centrifugation at 10000 g for 10 min. CAT activity was measured using the method described by Aebi (27) and expressed as kilo-units per gram protein. Protein levels in the homogenate and supernatant were determined according to the method of Bradford et al. (28). MDA levels in the tissues were determined from the homogenate by following the double-heating method of Draper and Hadley (29). An autoanalyzer (Beckman Coulter AU680, California, USA) was used to determine the activities of CKMB and LDH and uric acid levels in the supernatants of the blood samples.

Histopathological analysis

The other half of the heart samples were collected and fixed in 10% buffered formalin. After a routine procedure, the tissues were blocked in paraffin and cut to 5- μ m thickness. The tissue sections were stained with hematoxylin–eosin (H&E) and exam-

ined microscopically. The stained sections were evaluated by an experienced pathologist, who was uninformed about the groups, from Mehmet Akif Ersoy University. The severity of heart lesions was evaluated by scoring edema, hemorrhages, and leukocyte infiltration. Histopathological lesions were graded on a scale of 0 to 3, as shown in Table 1 (30).

Immunohistochemical analysis

The heart samples were immunostained with caspase-3 antiserum [anti-caspase-3 antibody (ab4051), 1/100 diluted; Abcam, Cambridge, UK], ST-1 [anti-SIRT1 antibody (E104) (ab32441), 1/100 diluted; Abcam, Cambridge, UK], and HIF-1 α [anti-HIF-1 α (H1 α 67) antibody-ChIP Grade ab1, 1/100 diluted; Abcam, Cambridge, UK] according to the manufacturer's instruction. All the slides were evaluated for immunopositivity and a semiquantitative analysis was carried out as detailed below. The overall number of positive cells in 1 high-power field was noted. An attempt was made to quantify the percentage of cells positive for each marker. For the determination of positive cell numbers, at least 5 low-power fields (40 \times) were selected and the total number of cells was calculated. Data from each animal were analyzed statistically.

Statistical analysis

Variables were presented as frequencies, percentages, mean \pm standard deviations, medians with interquartile range, or min–max. The Shapiro–Wilk test was used to test for a normal distribution of continuous variables and for the homogeneity of variance. Data characterized by a normal distribution were

Table 1. Histopathological scoring criteria (30)

Score	Grade	
0	No structural damage	No lesion
1	Minimal damage	Hyperemia in vessels, slight margination of neutrophils
2	Moderate damage	Infiltrations at myocardium
3	Severe damage	Degeneration of myocardial cells

Table 2. Biochemical markers of blood samples

Groups	CKMB (U/L)		LDH (U/L)		Uric acid (mg/dL)	
	Mean \pm SD	P	Mean \pm SD	P	Mean \pm SD	P
Control	1910.71 \pm 353.32		2155.65 \pm 363.87		0.97 \pm 0.09	
CS+AS	1677.69 \pm 542.69 ^b	<0.001	1947.68 \pm 556.96 ^b	0.001	0.89 \pm 0.15 ^b	0.001
CS+VC	1194.85 \pm 416.50 ^b	<0.001	1485.44 \pm 600.54 ^b	<0.001	1.14 \pm 0.29	
CS+AS+VC	1204.93 \pm 396.11 ^b	<0.001	1359.23 \pm 481.99 ^b	<0.001	1.02 \pm 0.27 ^b	0.002
CS	3225.64 \pm 598.25 ^a	0.004	3906.83 \pm 1064.22 ^a	0.002	1.45 \pm 0.39 ^a	0.011

AS - Aspirin; CKMB - creatine kinase; CS - corn syrup; LDH - lactate dehydrogenase; VC - vitamin C. Values are presented as mean \pm SD. The relationships between groups and results of biochemical markers are assessed by one-way ANOVA. ^aP<0.05 compared with Control, ^bP<0.05 compared with CS.

expressed as the mean \pm standard deviation. Parameters without such a distribution were expressed as the median with the interquartile range. Groups were compared using the non-parametric Kruskal–Wallis test and Mann–Whitney U-test. Biochemical parameters showed a normal distribution. ANOVA and post-hoc LSD tests were used to compare the groups. Data were analyzed with the computer software SPSS 15.0 for Windows (SPSS Inc., Chicago, IL, USA). Differences were considered as significant for p<0.05. All results were expressed as mean \pm SD.

Results

Biochemical analysis

The power analysis of biochemical markers was found to be over 0.90.

Levels of the cardiac enzymes CKMB and LDH were increased in the CS group compared with the control group (p=0.004 and p=0.002, respectively) and decreased in all the treatment groups.

Uric acid levels were also increased in the CS group (p=0.011) and decreased in all the treatment groups, but this was found to be significant only in the CS+AS and CS+AS+VC groups (p=0.001 and p=0.002, respectively) (Table 2).

As a marker of oxidative stress, MDA levels were increased in the CS group (p<0.001) and decreased in the CS+VC and CS+AS+VC groups (p=0.030 and p=0.004, respectively) but the reduction in this level was not significant in the CS+AS group. CAT activities were decreased in the CS group compared with the control group (p=0.007) and increased in the AS, VC, and AS+VC-treated groups compared with the CS group [p=0.001, p<0.001, and p=0.549, respectively], but this was significant only in the treatment groups in which these agents were used alone (Table 3).

Histopathological analysis

The power analysis of histopathological markers was found to be over 0.90 for the effects of AS and VC on CS-induced pathological findings in the hearts of the examined rats. Histopathological examination of the hearts in the groups treated with CS revealed a slight hemorrhage and a small amount of neutrophil leukocyte

margination in the venules of the myocardium, but AS and VC prevented or reduced heart lesions that were induced by CS (Fig. 1). Immunohistochemical examinations of the hearts revealed slight increases in caspase-3 and HIF-1 α activities along with a decrease in ST-1 activity in myocardial cells after CS administration (Fig. 2–4). Both VC and AS had an ameliorative effect on CS-induced heart lesions in the rats. The group with the most effective treatment was the CS+AS+VC group. The results of the statistical analysis are shown in Table 4.

Discussion

The aim of this study was to investigate the protective effects of AS and VC against cardiac damage induced by excessive fructose intake during chronic CS consumption via activation of ST-1 and inhibition of HIF-1 α . Long-term consumption of fructose causes several metabolic problems such as insulin resistance and hyperuricemia, which lead to an increase in reactive oxygen radicals and oxidative stress (31). Moreover, cardiac damage occurs under these conditions (32). As shown in this study, the elevated levels of uric acid and the specific cardiac biochemical markers CKMB and LDH reflected cardiac cell damage and cardiotoxicity in the CS group, and the positive responses of both drugs against this cardiac damage were significant. Moreover, according to the biochemical findings, con-

comitant usage of both drugs had better results than using them separately. Sakr (33) determined that levels of the cardiac markers CKMB and LDH increased in a group of rats given high-fructose diets. In a study of myocardial ischemia reperfusion injury in rats, elevated levels of coronary LDH and CKMB and high oxidative stress were noted in the high-fructose group compared with the control group (34). Geetha et al. (35) studied cardiac damage induced by a high-fructose diet in rats and found beneficial effects of troxerutin against cardiac damage induced by high-fructose CS. Sanchez et al. (36) and Khosla et al. (37) demonstrated the cardiovascular toxicity of hyperuricemia that induced oxidative stress. In this study, uric acid levels were increased in the hearts of the CS group and administration of AS and VC decreased these levels. There are not enough studies in the literature about the underlying mechanism of hyperuricemia-induced cardiac pathologies that are related to high fructose intake. An increase in MDA levels proved the oxidative damage in the CS group. These levels decreased in VC-treated groups, indicating that VC exerted a more powerful antioxidant effect on lipid peroxidation. Also, activities of the antioxidant enzyme CAT decreased in the CS group and increased in the AS- or VC-treated groups significantly. Cavarape et al. (38) found decreases in the expression levels of CAT mRNA in high fructose-fed rats, supporting the findings of the present study. In another study, researchers found that CAT levels decreased in high fructose-fed rats (39).

According to the histopathological and immunohistochemical findings of this study, fructose feeding disrupted the structure of the heart. There was slight neutrophil margination in the venous vessels of the myocardium and treatment with AS, VC or AS+VC had a significant inhibitory effect on this pathology due to the antioxidant properties of these agents. There have been several studies about these agents and their antioxidant activity. For example, researchers have found that pre- and posttreatment with ascorbic acid protected the myocardium from the toxic effect of doxorubicin by increasing CAT activities and decreasing MDA levels. Although disruption of myofibrils, vacuolization of the cytoplasm, necrosis, and inflammatory cells were observed in the doxorubicin-administered group, there was a reduced loss of myofibrils, vacuolization of the cytoplasm, and inflammatory cells in groups that were pre- or post-treated with ascorbic acid (40).

ST-1 plays an important role in regulating the degeneration, growth, and survival of cells. It enhances inflammation and the activity of antioxidant enzymes by inhibiting free radical-mediated oxidative stress via decreasing the activation of nicotinamide adenine dinucleotide phosphate (NADPH) oxidase (41). Besides, ST-1 protects the physiology of muscles against hypertrophy and increases mitochondrial biogenesis and fatty acid oxidation according to nutrient availability by deacetylating and activating the nuclear receptor peroxisome proliferator-activated receptor-alpha (PPAR α) and peroxisome proliferator-activated receptor-gamma coactivator 1-alpha (42, 43). On the other hand, promoting the entry of ST-1 into the nucleus induces the expression

Table 3. Oxidative stress markers of cardiac tissues

Groups	MDA, $\mu\text{mol}/\text{mg}$ protein		CAT, ku/mg protein	
	Mean \pm SD	P	Mean \pm SD	P
Control	0.079 \pm 0.03		0.085 \pm 0.005	
CS+AS	0.129 \pm 0.04a	0.003	0.089 \pm 0.009b	0.001
CS+VC	0.101 \pm 0.01b	0.030	0.092 \pm 0.004b	<0.001
CS+AS+VC	0.102 \pm 0.03b	0.004	0.074 \pm 0.000	0.549
CS	0.172 \pm 0.03a	<0.001	0.070 \pm 0.005a	0.007

AS - Aspirin; CAT - catalase; CS - corn syrup; MDA - malondialdehyde; VC - vitamin C. Values are presented as means \pm SD. The relationships between groups and results of biochemical markers are assessed by one-way ANOVA. ^aP<0.05 compared with Control, ^bP<0.05 compared with CS.

Table 4. Results of statistical analysis of histopathological and immunohistochemical findings

	Histopathological scores	Sirtuin-1 (+) cells (%)	HIF-1 α (+) cells (%)	Caspase-3 (+) cells (%)
Control	0.00 \pm 0.00 ^a	7.40 \pm 5.39 ^a	0.10 \pm 0.31 ^a	0.40 \pm 0.69 ^a
CS+AS	0.40 \pm 0.51 ^b	3.60 \pm 1.89 ^b	0.40 \pm 0.69 ^b	0.50 \pm 0.84 ^b
CS+VC	0.30 \pm 0.48 ^b	4.60 \pm 2.17 ^b	0.40 \pm 0.69 ^b	0.40 \pm 0.69 ^b
CS+AS+VC	0.10 \pm 0.31 ^b	7.80 \pm 2.93 ^b	0.40 \pm 0.51 ^b	0.20 \pm 0.42 ^b
CS	0.80 \pm 0.42 ^a	1.80 \pm 1.39 ^a	2.80 \pm 2.14 ^a	1.80 \pm 2.04 ^a

AS - Aspirin; CS - corn syrup; HIF-1 α - hypoxia-inducible factor-1 α ; VC - vitamin C. Values are presented as means \pm SD. Differences between the means of groups carrying different superscripts in the same column are statistically significant (P<0.05) by one-way ANOVA. ^aP<0.05 compared with Control, ^bP<0.05 compared with CS.

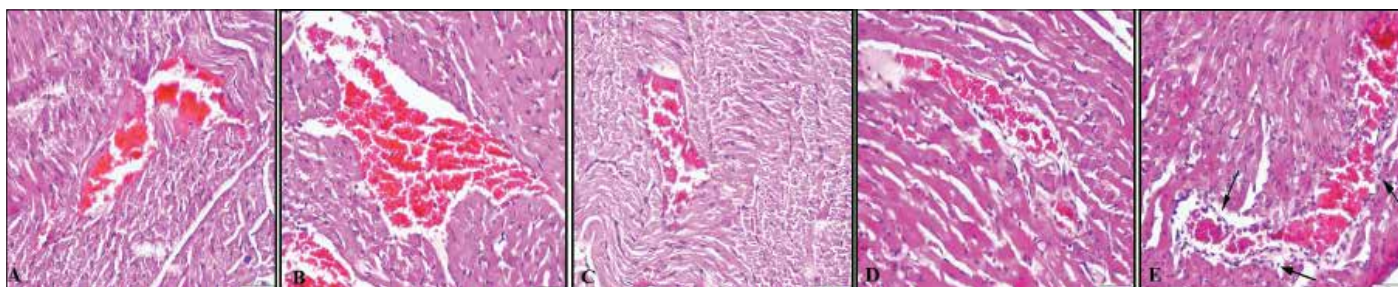


Figure 1. a-e. Histopathology of the heart: (a) normal histology of Control group heart; (b) normal appearance of heart in CS+AS group; (c) normal histological appearance of heart from CS+VC group; (d) no pathological finding in heart from CS+AS+VC group; (e) slight neutrophil margination (arrows) in the venous vessels of the myocardium in heart of CS+AS group. HE, Bar=50 μ m.

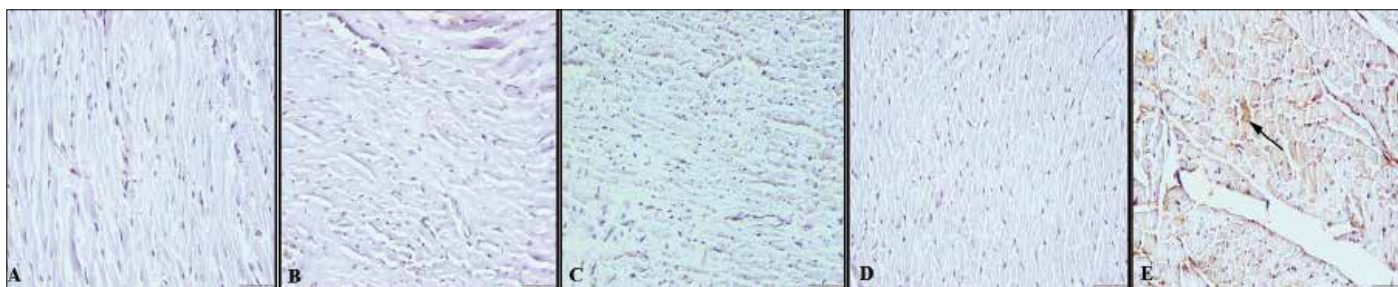


Figure 2. a-e. Caspase immunoreaction of the heart: (a) caspase-3-negative immunoreaction of Control group heart; (b) no caspase-3 expression of heart in CS+AS group; (c) negative caspase-3 immunoreaction of heart from CS+VC group; (d) negative reaction in heart from CS+AS+VC group; (e) slight caspase-3-positive immunoreaction in myocardial cells of heart in CS group (arrows). Streptavidin-biotin-peroxidase method, Bar=50 μ m.

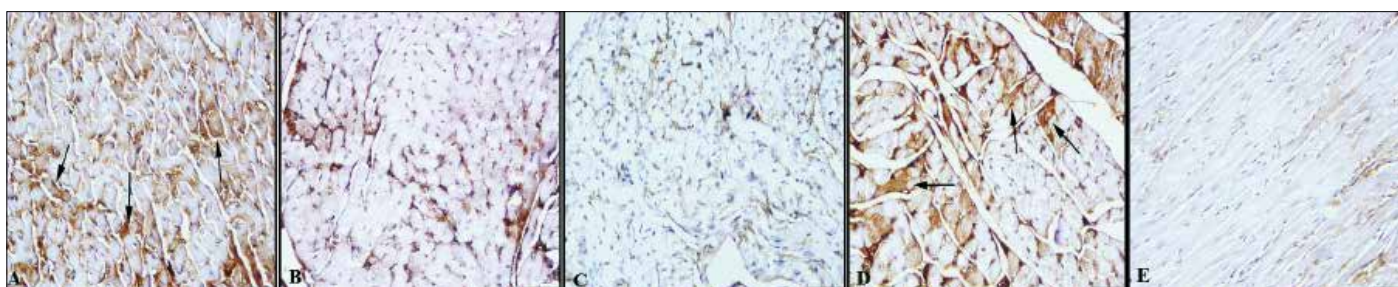


Figure 3. a-e. ST-1 immunoreactions of the heart: (a) marked positive immunoreaction of Control group heart; (b) ST-positive immunoreaction of heart in CS+AS group; (c) positive ST expression in heart from CS+VC group; (d) positive reaction in heart from CS+AS+VC group; (e) decreased ST immunoreaction in myocardial cells of heart in CS group (arrows). Streptavidin-biotin-peroxidase method, Bar=50 μ m.

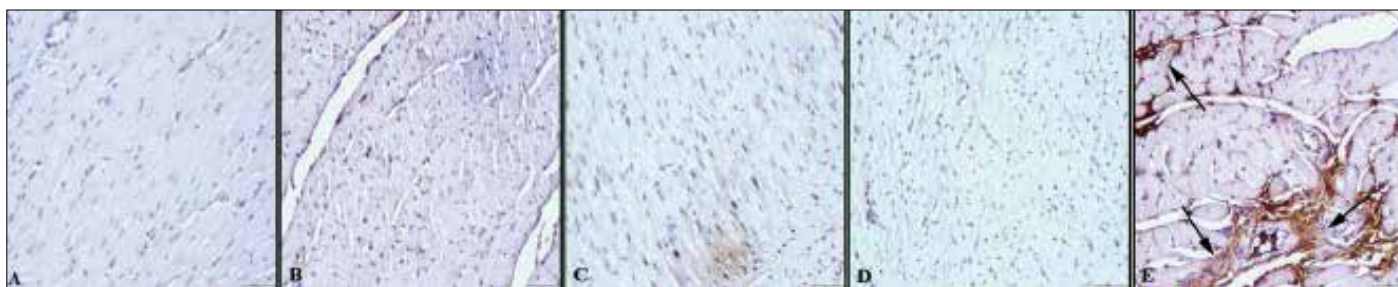


Figure 4. a-e. HIF-1 α immunoreactions of the heart: (a) HIF-1 α -negative immunoreaction of Control group heart; (b) no HIF-1 α reaction of heart in CS+AS group; (c) negative HIF-1 α expression in heart from CS+VC group; (d) negative reaction in heart from CS+AS+VC group; (e) slight increase in positive immunoreaction in myocardial cells of heart in CS group (arrows). Streptavidin-biotin-peroxidase method, Bar=50 μ m.

of endothelial nitric oxide synthase (eNOS), which plays a role in responding to calorie restriction, increasing myocardial ischemic tolerance in the heart (44). In this study, ST-1 staining levels significantly decreased in the CS group compared with the control group. This could be explained in 2 ways. Firstly, the oxidative stress capacity in cardiac damage in the CS group was

more than the antioxidant activity of cells. Secondly, the positive effect on the cells and inhibitory effect on oxidative stress of ST-1 may be suppressed due to decreases in ST-1 levels with high-dose fructose syrup. ST-1 levels increased significantly in groups that were given AS, VC, and both AS and VC. This situation can be explained as follows: either treatment with AS or VC

increased the levels of ST-1 expression directly or both these drugs protected ST-1 cells against oxidative stress induced by CS. In a study, the authors reported that AS enhanced the activation of ST-1 and AMP-activated protein kinase signaling pathways in endothelial cell toxicity caused by vinorelbine due to its anti-inflammatory activity (45). Also, in another study VC stimulated the activity of ST-1, which deacetylated 7-amino-4-methylcoumarin-labeled acetylated peptide, supporting our study (46). Staining levels of the indicator of hypoxia HIF-1 α increased in the CS group and decreased in all the treatment groups, as in caspase-3 staining, in our study. In an ischemic myocardium study, immunohistochemical expression of HIF-1 α occurred in the marginal area of ischemia, similar to caspase-3 expression (47). On the other hand, there was another relationship or interaction between ST-1 and HIF-1 α . When a redox change was restricted by blocking glycolysis, ST-1 was upregulated, which led to the deacetylation and inactivation of HIF-1 α , even in hypoxia (48). In addition, ST-1 restricted the formation of neointima in wire-injured femoral arteries by inhibiting HIF-1 α expression in hypoxic conditions (49). Similarly, the findings of our study supported this study, as the decrease in HIF-1 α levels was parallel to the increase in ST-1 levels.

Study limitations

The exogenous administration of CS, in particular, as a cause of insulin resistance does not necessarily mimic the physiopathological conditions in diabetes mellitus type II. This may affect the development of hyperglycemic conditions and, after that, the occurrence of insulin resistance. This chronic condition causes much tissue damage. It is recognized as an accurate model for insulin resistance that is related to cardiovascular diseases.

Despite these potential limitations, we feel that this approach is useful for assessing the pharmacological roles of AS and VC with the aim of determining the protective effects of AS and VC, via regulating ST-1 and HIF-1 α , against cardiovascular diseases during their therapeutic use.

Our protocol was specifically designed to define and characterize the cardiovascular effects of CS rather than to address pathophysiological mechanisms. Once the effects of ST-1 and HIF-1 α are clearly demonstrated, hypotheses should be generated to stimulate the additional research that is needed to clarify the inflammatory mechanism involved.

Conclusion

In accordance with our findings, ST-1 and HIF-1 α can be useful for investigation of the oxidative-state apoptotic properties of cardiovascular drugs on cardiac toxicity. ST-1 and HIF-1 α should be investigated, especially targeting the inflammatory processes in the intracellular mechanisms by second messenger regulation in cardiovascular diseases.

Conflict of interest: None declared.

Peer-review: Externally peer-reviewed.

Authorship contributions: Concept - H.A., Ş.Y., M.S.; Design- H.A., M.S.; Supervision- H.A., Ş.Y.; Funding-Ş.Y., F.N.C.; Materials- M.S., Ö.Ö.; Data collection &/or processing – Ş.T., Ö.Ö., Ş.Y., M.S.; Analysis and/or interpretation– F.N.C., M.S., Ö.Ö.; Literature search

References

- Vuilleumier S. Worldwide production of high-fructose syrup and crystalline fructose. *Am J Clin Nutr* 1993; 58: 733-6.
- Tappy L, Le KA, Tran C, Paquot N. Fructose and metabolic diseases: New findings, new questions. *Nutrition* 2010; 26: 1044-9.
- Johnson RJ, Segal MS, Sautin Y, Nakagawa T, Feig DI, Kang DH, et al. Potential role of sugar (fructose) in the epidemic of hypertension, obesity and the metabolic syndrome, diabetes, kidney disease, and cardiovascular disease. *Am J Clin Nutr* 2007; 86: 899-906.
- Nakagawa T, Hu H, Zharikov S, Tuttle KR, Short RA, Glushakova O, et al. A causal role for uric acid in fructose-induced metabolic syndrome. *Am J Physiol Renal Physiol* 2006; 290: 625-31. [Crossref](#)
- Kim SY, Guevara JP, Kim KM, Choi HK, Heitjan DF, Albert DA. Hyperuricemia and risk of stroke: a systematic review and meta-analysis. *Arthritis Rheum* 2009; 61: 885-92. [Crossref](#)
- Larghat AM, Swoboda PP, Biglands JD, Kearney MT, Greenwood JP, Plein S. Themicrovascular effects of insulin resistance and diabetes on cardiac structure, function, and perfusion: a cardiovascular magnetic resonance study. *Eur Heart J Cardiovasc Imaging* 2014; 15: 1368-76. [Crossref](#)
- Kanellis J, Kang DH. Uric acid as a mediator of endothelial dysfunction, inflammation, and vascular disease. *Semin Nephrol* 2005; 25: 39-42. [Crossref](#)
- Mahmoud MF, El Bassossy HM. Curcumin attenuates fructose-induced vascular dysfunction of isolated rat thoracic aorta rings. *Pharm Biol* 2014; 52: 972-7. [Crossref](#)
- Al-Awwadi NA, Araiz C, Bornet A, Delbosc S, Cristol JP, Linck N, et al. Agric extracts enriched in different polyphenolic families normalize increased cardiac NADPH oxidase expression while having differential effects on insulin resistance, hypertension, and cardiac hypertrophy in high-fructose-fed rats. *Food Chem* 2005; 53: 151-7. [Crossref](#)
- Maksin-Matveev A, Kanfi Y, Hochhauser E, Isak A, Cohen HY, Shainberg A. Sirtuin 6 protects the heart from hypoxic damage. *Exp Cell Res* 2015; 330: 81-90. [Crossref](#)
- Saygın M, Aşçı H, Çankara FN, Bayram D, Yeşilot S, Candan IA, et al. The impact of high fructose on cardiovascular system: Role of α -lipoic acid. *Hum Exp Toxicol* 2015; Epub ahead of print.
- Yamamoto H, Schoonjans K, Auwerx J. Sirtuin functions in health and disease. *Mol Endocrinol* 2007; 21: 1745-55. [Crossref](#)
- Mattagajasingh I, Kim CS, Naqvi A, Yamamori T, Hoffman TA, Jung SB, et al. SIRT1 promotes endothelium-dependent vascular relaxation by activating endothelial nitric oxide synthase. *Proc Natl Acad Sci USA* 2007; 104: 14855-60. [Crossref](#)
- Zhang QJ, Wang Z, Chen HZ, Zhou S, Zheng W, Liu G, et al. Endothelium-specific overexpression of class III deacetylase SIRT1 decreases atherosclerosis in apolipoprotein E-deficient mice. *Cardiovasc Res* 2008; 80: 191-9. [Crossref](#)
- Pfluger PT, Herranz D, Velasco-Miguel S, Serrano M, Tschop MH. Sirt1 protects against high-fat diet-induced metabolic damage. *Proc Natl Acad Sci USA* 2008; 105: 9793. [Crossref](#)

16. Alcendor RR, Gao S, Zhai P, Zablocki D, Holle E, Yu X, et al. Sirt1 regulates aging and resistance to oxidative stress in the heart. *Circ Res* 2007; 100: 1512-21. **Crossref**
17. Yu W, Fu YC, Zhou XH, Chen CJ, Wang X, Lin RB, et al. Effects of resveratrol on H(2)O(2)-induced apoptosis and expression of SIRT5 in H9c2 cells. *Cell Biochem* 2009; 107: 741-7. **Crossref**
18. Yoshizaki T, Schenk S, Imamura T, Babendure JL, Sonoda N, Bae EJ, et al. SIRT1 inhibits inflammatory pathways in macrophages and modulates insulin sensitivity. *Am J Physiol Endocrinol Metab* 2010; 298: 419-28. **Crossref**
19. Wang GL, Semenza GL. General involvement of hypoxia-inducible factor 1 in transcriptional response to hypoxia. *Proc Natl Acad Sci USA* 1993; 90: 4304-8. **Crossref**
20. Greijer AE, van der Groep P, Kemming D, Shvarts A, Semenza GL, Meijer GA, et al. Up-regulation of gene expression by hypoxia is mediated predominantly by hypoxia-inducible factor 1 (HIF-1). *J Pathol* 2005; 206: 291-304. **Crossref**
21. Blanco Pampín J, García Rivero SA, Otero Cepeda XL, Va'zquez Boquete A, Forteza Vila J, Hinojal Fonseca R. Immunohistochemical expression of HIF-1alpha in response to early myocardial ischemia. *J Forensic Sci* 2006; 51: 120-4. **Crossref**
22. Marti HJ, Bernaudin M, Bellail A, Schoch H, Euler M, Petit E, et al. Hypoxia induced vascular endothelial growth factor expression precedes neovascularization after cerebral ischemia. *Am J Pathol* 2000; 156: 965-76. **Crossref**
23. Qian MJ, Chen M, Wang HM, Gao F, Wu Y, Yang XZ. The effect on anti-oxidative damage with Aspirin pretreatment in primary cultured rat type II alveolar epithelial cell. *Zhongguo Wei Zhong Bing JiJiu Yi Xue* 2011; 23: 247-30.
24. Yeşilot S, Özer MK, Bayram D, Öncü M, Karabacak HI, Çiçek E. Effects of Aspirin and nimesulide on tissue damage in diabetic rats. *Cytokine* 2010; 52: 163-7. **Crossref**
25. Marzban G, Kinaciyar T, Maghuly F, Brunner R, Gruber C, Hahn R, et al. Impact of sulfur and vitamin C on the allergenicity of mald 2 from apple (*Malus domestica*). *J Agric Food Chem* 2014; 62: 7622-30. **Crossref**
26. Frei B, Stocker R, England L, Ames BN. Ascorbate: the most effective antioxidant in human blood plasma. *Adv Exp Med Biol* 1990; 264: 155-63. **Crossref**
27. Aebi H. Catalase in vitro. *Methods Enzymol* 1984; 105: 121-6.
28. Bradford MM. A rapid and sensitive method for the quantitation of microgram quantities of protein utilizing the principle of protein-dye binding. *Anal Biochem* 1976; 72: 248-54. **Crossref**
29. Drapper HH, Hadley M. Malondialdehyde determination as index of lipid peroxidation. *Methods Enzymol* 1990; 186: 421-31. **Crossref**
30. Abdel-Wahhab MA, Nada SA, Arbid MS. Ochratoxicosis: prevention of developmental toxicity by L-methionine in rats. *J Appl Toxicol* 1999; 19: 7-12. **Crossref**
31. Tapia E, Cristóbal M, García-Arroyo FE, Soto V, Monroy-Sánchez F, Pacheco U, et al. Synergistic effect of uricase blockade plus physiological amounts of fructose-glucose on glomerular hypertension and oxidative stress in rats. *Am J Physiol Renal Physiol* 2013; 304: 727-36. **Crossref**
32. Chaudhary K, Malhotra K, Sowers J, Aroor A. Uric Acid key ingredient in the recipe for cardiorenal metabolic syndrome. *Cardiorenal Med* 2013; 3: 208-20. **Crossref**
33. Sakr HF. Modulation of metabolic and cardiac dysfunctions by swimming in overweight rats on a high cholesterol and fructose diet: possible role of adiponectin. *J Physiol Pharmacol* 2013; 64: 231-40.
34. Babbar L, Mahadevan N, Balakumar P. Fenofibrate attenuates impaired ischemic preconditioning-mediated cardioprotection in the fructose-fed hypertriglyceridemic rat heart. *Naunyn Schmiedeberg Arch Pharmacol* 2013; 386: 319-29. **Crossref**
35. Geetha R, Yogalakshmi B, Sreeja S, Bhavani K, Anuradha CV. Troxerutin suppresses lipid abnormalities in the heart of high-fat-high-fructose diet-fed mice. *Mol Cell Biochem* 2014; 387: 123-34.
36. Sánchez-Lozada LG, Lanasma MA, Cristóbal-García M, García-Arroyo F, Soto V, Cruz-Robles D, et al. Uric acid-induced endothelial dysfunction is associated with mitochondrial alterations and decreased intracellular ATP concentrations. *Nephron Exp Nephrol* 2012; 121: 71-8. **Crossref**
37. Khosla UM, Zharikov S, Finch JL, Nakagawa T, Roncal C, Mu W, et al. Hyperuricemia induces endothelial dysfunction. *Kidney Int* 2005; 67: 1739-42. **Crossref**
38. Cavarape A, Feletto F, Mercuri F, Quagliari L, Daman G, Ceriello A. High-fructose diet decreases catalase mRNA levels in rat tissues. *J Endocrinol Invest* 2001; 24: 838-45. **Crossref**
39. Munshi RP, Joshi SG, Rane BN. Development of an experimental diet model in rats to study hyperlipidemia and insulin resistance, markers for coronary heart disease. *Indian J Pharmacol* 2014; 46: 270-6. **Crossref**
40. Viswanatha Swamy AH, Wangikar U, Koti BC, Thippeswamy AH, Ronad PM, Manjula DV. Cardioprotective effect of ascorbic acid on doxorubicin-induced myocardial toxicity in rats. *Indian J Pharmacol* 2011; 43: 507-11. **Crossref**
41. Zarzuelo MJ, Lopez-Sepulveda R, Sanchez M, Romero M, Gomez-Guzman M, Ungvary Z, et al. SIRT1 inhibits NADPH oxidase activation and protects endothelial function in the rat aorta: implications for vascular aging. *Biochem Pharmacol* 2013; 85: 1288-96. **Crossref**
42. Gerhart-Hines Z, Rodgers JT, Bare O, Lerin C, Kim SH, Mostoslavsky R, et al. Metabolic control of muscle mitochondrial function and fatty acid oxidation through sirt1/pgc-1 alpha. *EMBO J* 2007; 26: 1913-23. **Crossref**
43. Planavila A, Iglesias R, Giral M, Villarroya F. Sirt1 acts in association with PPARα to protect the heart from hypertrophy, metabolic dysregulation, and inflammation. *Cardiovasc Res* 2011; 90: 276-84.
44. Shinmura K, Tamaki K, Bolli R. Impact of 6-mo caloric restriction on myocardial ischemic tolerance: possible involvement of nitric oxide-dependent increase in nuclear sirt1. *Am J Physiol Heart Circ Physiol* 2008; 295: 2348-55. **Crossref**
45. Tsai KL, Huang PH, Kao CL, Leu HB, Cheng YH, Liao YW, et al. Aspirin attenuates vinorelbine-induced endothelial inflammation via modulating SIRT1/AMPK axis. *Biochem Pharmacol* 2014; 88: 189-200. **Crossref**
46. Feng Y, Wu J, Chen L, Luo C, Shen X, Chen K, et al. A fluorometric assay of SIRT1 deacetylation activity through quantification of nicotinamide adenine dinucleotide. *Anal Biochem* 2009; 395: 205-10.
47. Güven Bağla A, Ercan E, Asgun HF, İçkin M, Ercan F, Yavuz O, et al. Experimental acute myocardial infarction in rats: HIF-1α, caspase-3, erythropoietin and erythropoietin receptor expression and the cardioprotective effects of two different erythropoietin doses. *Acta Histochem* 2013; 115: 658-68. **Crossref**
48. Lim JH, Lee YM, Chun YS, Chen J, Kim JE, Park JW. SIRT1 modulates cellular responses to hypoxia by deacetylating hypoxia inducible factor 1 alpha. *Mol Cell* 2010; 38: 864-78. **Crossref**
49. Bae JU, Lee SJ, Seo KW, Kim YH, Park SY, Bae SS, et al. SIRT1 attenuates neointima formation by inhibiting HIF1α expression in neointimal lesion of murine wire-injured femoral artery. *Int J Cardiol* 2013; 168: 4393-6. **Crossref**