

# An Extensive Calcified Left Ventricular Aneurysm: Case Report

## Yaygın Kalsifik Sol Ventrikül Anevrizması

İhsan ALUR,<sup>a</sup>  
Tevfik GÜNEŞ,<sup>a</sup>  
Gökhan Yiğit TANRISEVER,<sup>a</sup>  
Bilgin EMRECAN<sup>a</sup>

<sup>a</sup>Department of Cardiovascular Surgery,  
Pamukkale University  
Faculty of Medicine, Denizli

Geliş Tarihi/Received: 12.02.2016  
Kabul Tarihi/Accepted: 04.04.2016

Yazışma Adresi/Correspondence:  
İhsan ALUR  
Pamukkale University  
Faculty of Medicine,  
Department of Cardiovascular Surgery,  
Denizli,  
TÜRKİYE/TURKEY  
alur\_i@hotmail.com

**ABSTRACT** A calcified left ventricular aneurysm (CLVA) is a rare, serious complication of acute myocardial infarction. It can lead to angina pectoris, thromboembolism of ventricular origin, ventricular arrhythmia, ventricular pseudoaneurysm or rupture, progressively enlarging aneurysms, congestive heart failure, and death. Treatment is surgical for symptomatic or asymptomatic LVAs larger than 5 cm, particularly when there is comorbid coronary artery disease. Its standard treatment is a ventriculoplasty and aneurysmectomy using the Dor technique. The aim of surgical treatment of an LVA is to reduce oxygen consumption in the LV by reducing end-diastolic volume (EDV), creating the ideal ventricle geometry, and preventing thrombus formation. The surgical results are often good. This article presents a patient with CLVA in whom we performed surgery.

**Key Words:** Heart ventricles; heart aneurysm; thoracic surgery

**ÖZET** Kalsifik sol ventrikül anevrizması (KSVA) akut miyokard infarktüsünün nadir ve ciddi bir komplikasyonudur. Bu komplikasyon anjina pektoris, ventriküler kaynaklı tromboemboli, ventriküler aritmi, ventriküler psödoanevrizma veya rüptür, progresif genişleyen anevrizma ve konjestif kalp yetersizliği gibi fatal kardiyak olaylara yol açabilir. Semptomatik veya asemptomatik, 5 cm'den büyük SVA'ların, özellikle eşlik eden koroner arter hastalığı da varsa tedavisi cerrahidir. Standart tedavisi anevrizmektomi ve Dor tekniği ile yapılan ventriküloplastidir. Sol ventrikül anevrizmalarında cerrahi tedavinin amacı, end-diyastolik hacmi (EDH) küçültürerek sol ventrikülün oksijen tüketimini (talebini) azaltmak, ventrikülün ideal geometrisini oluşturmak ve trombüs oluşumunu engellemektir. Cerrahi sonuçları çoğunlukla yüz güldürücüdür. Bu yazıda KSVA tanısıyla cerrahi uyguladığımız olgu sunuldu.

**Anahtar Kelimeler:** Kalp ventrikülleri; kalp anevrizması; göğüs cerrahisi

Türkiye Klinikleri J Cardiovasc Sci 2016;28(1):39-42

A calcified left ventricular aneurysm (CLVA) is a mechanical complication that develops after acute transmural necrosis of the myocardium.<sup>1</sup> It can lead to angina pectoris, thromboembolism of ventricular origin, ventricular arrhythmia, ventricular pseudoaneurysm or rupture, progressively enlarging aneurysms, congestive heart failure, and death. Its standard treatment is surgical.<sup>1-4</sup> The aim of surgical treatment of an left ventricular aneurysm (LVA) is to reduce oxygen consumption in the left ventricular (LV) by reducing end-diastolic volume (EDV), creating the ideal ventricle geometry, and preventing thrombus formation.<sup>1-4</sup> The surgical results are generally good. This article presents a patient with CLVA in whom we performed surgery.

doi: 10.5336/cardiosci.2016-50856

Copyright © 2016 by Türkiye Klinikleri

## CASE REPORT

A 66-year-old man presented with shortness of breath. Three weeks earlier, he required cardiopulmonary resuscitation (CPR) following cardiac arrest. On physical examination, his pulse rate was 84/min, he had a blood pressure of 90/60 mmHg, and peripheral pulses were palpable. The electrocardiogram showed sinus rhythm. Transthoracic echocardiography showed dilated cardiomyopathy, severe LV systolic dysfunction, a large left atrium (52 mm), and an ejection fraction (EF) of 10-15%. Cardiac magnetic resonance imaging indicated that his LV was markedly enlarged (axial transverse diameter 87 mm), had severely reduced contraction, was hypofunctioning, and had reduced wall thickness at the apex; he also showed pronounced enlargement of the left atrium (Figure 1A/1B). On coronary angiography, the left anterior descending artery (LAD) was narrow with 80% stenosis proximally, and pericardial calcification was seen (Figure 1C). Aneurysmectomy, ventriculoplasty, and single-vessel coronary artery bypass grafting (CABG) were planned for the patient. Informed consent was obtained from the patient.

## SURGICAL METHOD

A standard median sternotomy was performed under general anesthesia. A left internal mammary artery (LIMA) graft was prepared. After opening the pericardium and suspending it, the patient was heparinized. Arterial cannulation from the ascending aorta and two-stage venous cannulation from the right atrium were performed. After cannulation, cardiopulmonary bypass (CPB) was initiated at the appropriate activated clotting time. Using a cross-clamp, cardiac arrest was induced via isothermic hyperkalemic antegrade blood cardioplegia. A large calcified aneurysm was seen involving a large area of the LV apex (Figure 2A). A ventriculotomy was performed and sutured internally with a 4×3 cm Dacron patch. Then the opened aneurysm was closed externally using the Dor procedure with Teflon felt (Figure 2B, 2C).<sup>2</sup> Subsequently, an LIMA-LAD distal anastomosis was performed. The cross-clamp was removed, and the CPB was gradually ended with inotropic support. The patient was transferred to the intensive care unit and discharged without any problems on the seventh post-operative day.

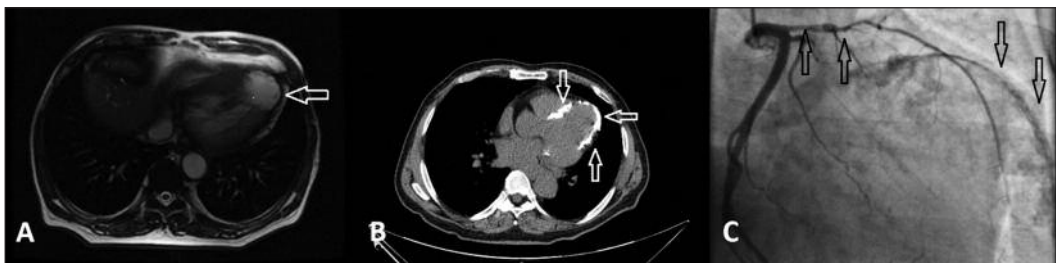

FIGURE 1: A) MRI image (aneurysmal sac), B) CT image, C) Coronary angiogram (LAD proximal lesion and calcification line).

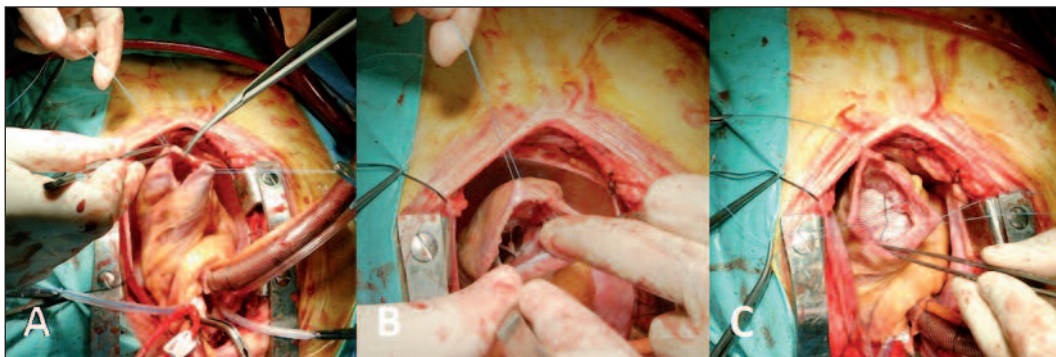


FIGURE 2: A) Incision of aneurysm sac, B) Ventricular cavity, C) Endoventricular patch.

## DISCUSSION

During an LVA, the ventricular diameter increases while the wall thickness decreases. Increasing wall tension increases both oxygen consumption and the demand on the previously infarcted ischemic myocardium, causing ischemia in non-aneurysmal segments. In patients with an LVA, death of cardiac origin generally results from malignant ventricular arrhythmias, congestive heart failure, or recurrent acute myocardial infarction.<sup>1</sup> Our patient suffered a sudden cardiac arrest requiring CPR three weeks earlier.

There is no standard surgical treatment for a calcified LVA. It has been suggested that the results of surgery in patients who respond to medical treatment are worse than those of the medical treatment.<sup>3</sup> Nevertheless, the 5-year survival of LVA with medical treatment is 8-12%, and surgery increases this to 75-90%.<sup>2</sup> Systemic embolization, recurrent arrhythmias, congestive heart failure, and angina pectoris are all indications for surgical treatment. Methods used for the surgical treatment of an LVA include plication, linear suture repair, placement of a circular patch, and the Dor procedure.<sup>1,4</sup>

**Plication:** This is used for small, thrombus-free aneurysms, which can be pliated from the outside without opening the aneurysm sac.<sup>1,4</sup>

**Linear suture repair:** The aneurysm sac is opened. If there is a thrombus, a thrombectomy is performed. The aneurysm tissue is resected so that a 3 cm rim remains. Supporting the defect from outside, a horizontal mattress suture technique is used and the two vertical surfaces are closed primarily with a continuous suture. The results are often unsatisfactory because this technique causes LV distortion and leaves akinetic/dyskinetic areas in the septum.<sup>5</sup> It cannot adequately improve cardiac function. To overcome these problems, Dor et al. removed all of the akinetic/dyskinetic myocardial tissue, including the septum, and isolated the aneurysm cavity from the LV cavity, thereby reducing the dead space and end-diastolic volume of the LV.<sup>5</sup>

**Circular patch:** A convenient method for the back or bottom wall of an LVA. A thrombectomy is done by opening the aneurysm sac and resecting it so that a 2 cm margin remains. The defect is closed using a synthetic patch.<sup>1,4</sup>

**Dor procedure (endoventricular patch technique):** The Dor procedure is a convenient method for treating aneurysms in the anterior wall of the LV. It gives good results when used for aneurysms larger than 8 cm diameter. The aneurysm sac is opened; the wall is left where it is. A patch suitable for the normal tissue border is prepared (generally from Teflon felt) and sutured continuously to the normal tissue and aneurysm tissue border from the endocardial surface with a Prolene suture; then the native aneurysm sac is closed over the patch with a Prolene suture. The most important feature of an endoventricular circular patch-plasty is that it improves the function of the LV by preserving its geometry. The main objective of the aneurysmectomy is to reduce the LVEDV and regional wall stress.<sup>1,4,5</sup> The Dor procedure has some advantages compared to a linear repair; it eliminates the septal akinetic areas and allows reorganization of the remaining viable myocardium (like its positive effect on the remodeling of the LV muscle fibers, and causes no restrictions or bending). Finally, without narrowing the LV cavity, it allows complete resection of the aneurysm, including subendocardial scar tissue.<sup>5</sup>

**The surgical anterior ventricular restoration (SAVER) technique:** This is a form of the Dor procedure. In this technique, the infarcted tissue in the anterior wall of the LV is cut parallel to the LAD and the intraventricular space is examined. The live and scarred myocardium tissue border is palpated transmurally. This border is excluded from the ventricular cavity with an approximately 2-3 cm sewing ring, using a Dacron patch. Finally, the scar tissue is tucked and closed over the patch for hemostasis.<sup>6</sup> The Reconstructive Endoventricular Surgery returning Torsion Original Radius Elliptical shape to the left ventricle (RESTORE) study had good postoperative results using the SAVER technique, reporting that the preoperative LV end-systolic volume index improved from 109 to 69 mL/m<sup>2</sup>

and the global LV EF improved from 29% to 39%.<sup>6</sup> Despite poor preoperative LV systolic function, they reported that the requirement for postoperative mechanical support decreased by 9%. After being discharged from the hospital, only 15% of the patients presented to the hospital during an 18-month follow-up period.<sup>6</sup> For patients with an aneurysmectomy and endoventricular circular patch-plasty, Tekümit et al. reported that at the end of 1 year, the mean LVEDV decreased from 88.9 to 56.1 mL/m<sup>2</sup> and the mean EF improved from 30.8% to 42.6%.<sup>5</sup>

It has been reported that patient mortality increases when CABG and aneurysmectomy are performed simultaneously in patients with a calcified LVA.<sup>7</sup> CABG is an important component of LVA surgery and it is performed in 68-100% of patients with an LVA. Most authors recommend performing simultaneous CABG in these patients, particularly in multi-vessel coronary artery disease (CAD).<sup>5</sup>

In comparison, positive results for rupture CLVA aneurysmectomy have been reported.<sup>8</sup>

Treatment is surgical for symptomatic or asymptomatic LVAs larger than 5 cm, particularly when there is comorbid CAD. If these patients are treated medically rather than surgically, LV contractility decreases progressively. Surgery should be performed if the EF is 25–30%, the mean pulmonary artery pressure is less than 40 mmHg, and the cardiac index is 2 L/dk.m<sup>2</sup> or higher. Patients should be placed into a transplantation program if the contractile EF is lower than 25%, there is severe mitral regurgitation, and the coronary arteries are unsuitable for bypass with right heart failure.<sup>1,4</sup>

Our patient had a low EF (10-15%), dilated LV (8.7 cm), and CLVA. Ventricle repair was performed using an aneurysmectomy and the Dor technique. The patient was discharged without any postoperative problems.

Treatment is surgical for symptomatic or asymptomatic LVAs larger than 5 cm, particularly if there is comorbid CAD. The Dor procedure (endoventricular patch technique) is a suitable method for treating CLVA.

## REFERENCES

1. Tiryakioğlu O, Kenar Tiryakioğlu SK, Özyazıcıoğlu AF. [Surgical treatment of left ventricular aneurysms]. *Türk Göğüs Kalp Damar Cer Derg* 2009;17(1):69-72.
2. Dor V, Saab M, Coste P, Kornaszewska M, Montiglio F. Left ventricular aneurysm: a new surgical approach. *Thorac Cardiovasc Surg* 1989;37(1):11-9.
3. Karaahmet T, Tigen K, Gurel E, Tanalp AC, Basaran Y. Dystrophic calcification of the aneurysmatic left ventricular apex. *Congest Heart Fail* 2009;15(4):196-8.
4. Tiryakioğlu O, Kaya U, Kenar Tiryakioğlu S, Vural H, Gücü A, Yavuz Ş, et al. [Left ventricular aneurysms: long-term echocardiographic results of two types of repair]. *Türkiye Klinikleri J Cardiovasc Sci* 2007;19(2):121-7.
5. Tekümit H, Polat A, Uyar I, Uzun K, Tataroğlu C, Cenal AR, et al. Left ventricular aneurysm using the Dor technique: mid-term results. *J Card Surg* 2010;25(2):147-52.
6. Athanasuleas CL, Stanley AW Jr, Buckberg GD, Dor V, DiDonato M, Blackstone EH. Surgical anterior ventricular endocardial restoration (SAVER) in the dilated remodeled ventricle after anterior myocardial infarction. RESTORE group. Reconstructive Endoventricular Surgery, returning Torsion Original Radius Elliptical Shape to the LV. *J Am Coll Cardiol* 2001;37(5):1199-209.
7. Gopal AK, Roe MT. Calcified cardiac lesion. *Chest* 1996;110(4):1097-8.
8. Demir T, Sezer H, Şahin M, Sezer S, Kuzucan S. A massive calcified left ventricular aneurysm. *Türk Göğüs Kalp Dama* 2014;22(4):876-7.