



## Case Report

# An Unusual Complication of Otitis Media: Luc's Abscess

Erdem Mengi , Funda Tümkaya , Ergin Sağtaş , Fazıl Necdet Ardiç 

Department of Otolaryngology, Head and Neck Surgery, Pamukkale University School of Medicine, Denizli, Turkey (EM, FT, FNA)  
Department of Radiology, Pamukkale University School of Medicine, Denizli, Turkey (ES)

ORCID IDs of the authors: E.M. 0000-0001-8813-2443; F.T. 0000-0002-3213-8106; E.S. 0000-0001-6723-6593; F.N.A. 0000-0003-4230-3141.

Cite this article as: Mengi E, Tümkaya F, Sağtaş E, Ardiç FN. An Unusual Complication of Otitis Media: Luc's Abscess. J Int Adv Otol 2018; 14(3): 497-500.

Luc's abscess is an extremely rare complication of otitis media, caused by the spread of the middle ear infection to the subperiosteal area and its accumulation beneath the temporal muscle. Unlike other subperiosteal abscesses relating to otitis media, infection may not be associated with mastoid bone involvement. Therefore, it is defined as a benign complication of otitis media. However, its rare occurrence may lead to delayed diagnosis and treatment. Here we report a case of an 11-year-old boy diagnosed with Luc's abscess with mastoid involvement. We discuss its clinical presentation and treatment with a review of the literature.

**KEYWORDS:** Otitis media, complication, subperiosteal abscess

## INTRODUCTION

Otitis media is one of the most frequently diagnosed and treated childhood diseases. Although it is often self-limited, there are important complications of the disease due to its proximity to the intracranial and intratemporal compartments. Subperiosteal abscesses are extracranial and extratemporal complications of otitis media, which are termed according to location. When the infection spreads deep to the sternocleidomastoid muscle, it is called *Bezold's abscess*, and when located in the digastric triangle, it is called *Citelli's abscess*. In the case of Luc's abscess, the infection is located beneath the temporal muscle <sup>[1]</sup>. Many clinicians have a little experience in the diagnosis and treatment of this disease due to its rare nature.

Subperiosteal abscesses of otitic origin usually occur following the spread of infection to the subperiosteal area from the cortical bone destruction often secondary to acute mastoiditis. Luc's abscess is different from the other subperiosteal abscesses in that respect. It usually occurs not through the mastoid bone but by spreading of the middle ear infection through a pre-existing pathway in the external ear canal. Therefore, the disease may not be accompanied by acute mastoiditis <sup>[2]</sup>. A rare route of infection spreading to the temporal fossa is by the pneumatized zygomatic arch. Under this condition, subperiosteal abscesses may be observed along with acute mastoiditis <sup>[3]</sup>. Computed tomography (CT) of the temporal bone would give very useful information under such conditions. Here, we present a case of Luc's abscess with mastoid bone involvement associated with acute otitis media, following parental approval.

## CASE PRESENTATION

An 11-year-old boy presented to the emergency department with complaints of painful swelling on the right half of the face, difficulty in opening his mouth, and high fever, which started a day before. He also presented with complaints of right ear pain and hearing loss for the past 2 days. There was no previous medical history of any ear disease or trauma. Physical examination revealed that the patient had trismus and that the swelling originating from the right temporal region extended toward the cheek and inferior palpebra. The tympanic membrane was not clearly evaluated due to severe edema in the right external ear canal, as observed on otoscopic examination.

Laboratory analysis revealed leukocytosis (26.84 K/uL), neutrophilia (%87.5), and increased C-reactive protein (CRP: 21.74 mg/dL; normal<0.5). Pure tone audiogram revealed a moderate conductive-type hearing loss in the right ear. After obtaining these findings, the patient was scheduled for CT of the paranasal sinuses and temporal bone and cranial magnetic resonance imaging (MRI).

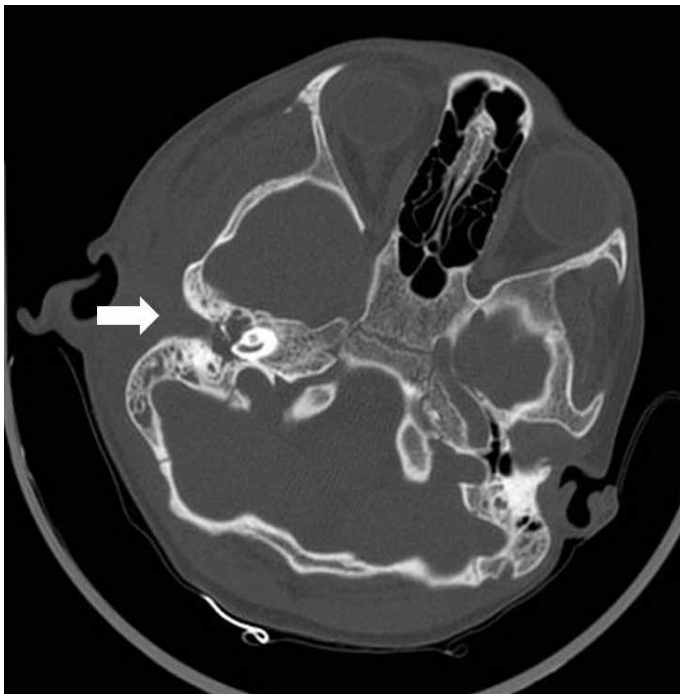This study was presented at the 39<sup>th</sup> Turkish ENT and HNS Congress, 8-12 November 2017, Antalya, Turkey.

Corresponding Address: Erdem Mengi E-mail: [emengi@hotmail.com](mailto:emengi@hotmail.com)

Submitted: 05.11.2017 • Revision Received: 23.01.2018 • Accepted: 01.02.2018 • Available Online Date: 15.10.2018

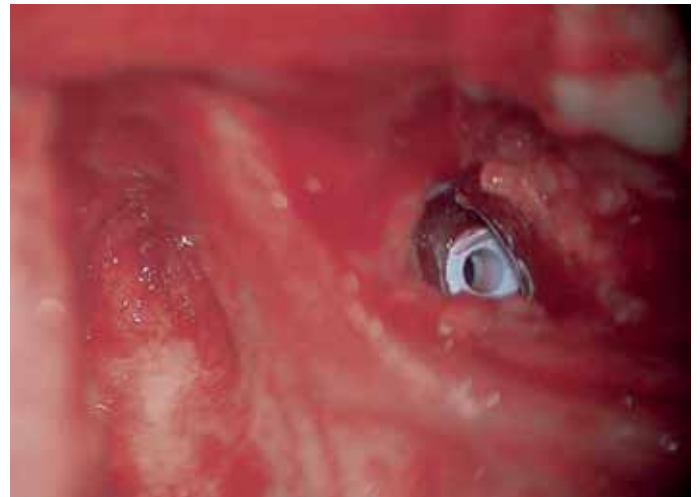
©Copyright 2018 by The European Academy of Otolology and Neurotology and The Politzer Society - Available online at [www.advancedotology.org](http://www.advancedotology.org)

CT examination revealed soft tissue density completely filling the right external auditory canal, middle ear, and mastoid bone along with marked edema in the right masticator and buccal space (Figure 1). There were no pathological findings in the paranasal sinuses. Cranial MRI revealed a 38x5-mm contrast enhancement of the loculated collection extending from the right external auditory canal anteriorly to the vicinity of the temporomandibular joint and edema in the right pterygoid muscles (Figure 2).

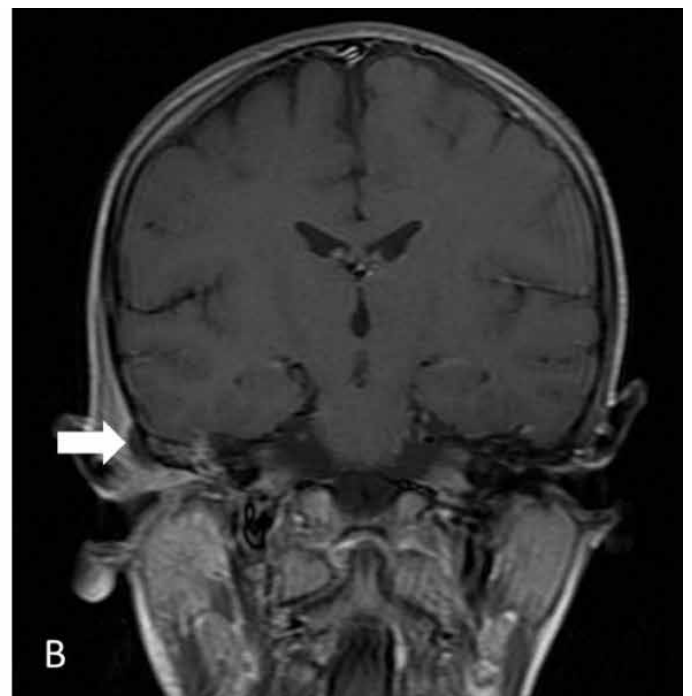
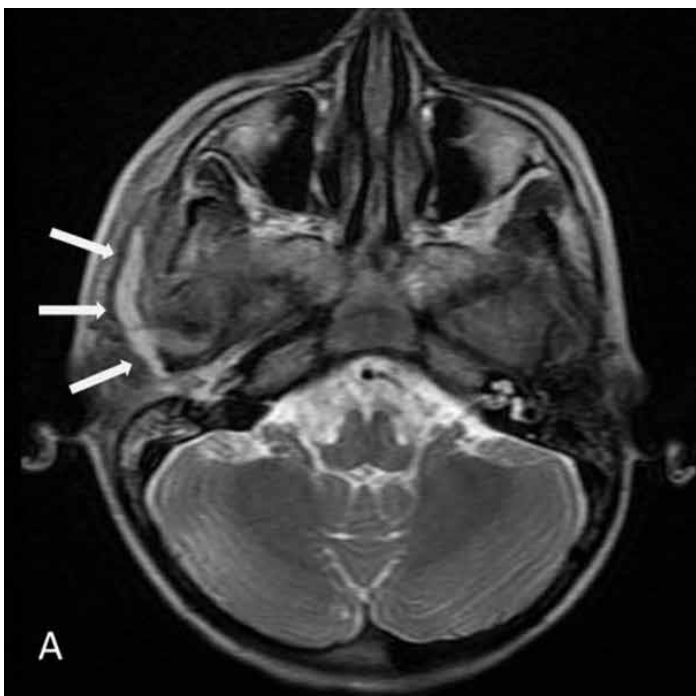


**Figure 1.** A CT scan of temporal bone: Soft tissue density completely filling the right external ear canal, middle ear, and mastoid bone (white arrow), and marked edema in the right masticator and buccal space.

Based on these findings, the patient was hospitalized with the diagnosis of otitis media complicated by Luc's abscess. He was commenced on intravenous (IV) vancomycin and ampicillin/sulbactam treatment following recommendation from the infectious disease clinic. The patient was observed to have intubation difficulty due to trismus. As a result, no emergency surgery was scheduled. Following regression of the findings of trismus by the 5<sup>th</sup> day of medical treatment, myringotomy and a grommet insertion, cortical mastoidectomy and abscess drainage were performed, under general anesthesia after a written informed consent was obtained from the parents of the patient (Figure 3). During the surgery, no direct relationship between the temporal abscess and the mastoid bone was detected. The mastoid cavity and cavity of the middle ear were observed to be filled with hemorrhagic granulation tissue. No cholesteatoma was observed in the mastoid. Pathological examination of the material



**Figure 3.** The hemorrhagic granulation tissue filled the mastoid cavity and the tympanostomy tube in the tympanic membrane.



**Figure 2. a, b.** (a) Axial T2-weighted, (b) post-contrast coronal T1-weighted scan of cranial MRI. Abscess formation extending from the right external ear canal anteriorly to the vicinity of the temporomandibular joint (white arrows).

**Table 1.** Reported cases of Luc's abscess

	Age/Sex	Etiology	Treatment	Mastoiditis	Culture
Knappe et al. [4] 1997	15-year-old female	-	Mastoidectomy, IV antibiotherapy	No	-
Weiss et al. [5] 2010	5-year-old male	AOM	Abscess drainage, tympanostomy tube insertion, IV antibiotherapy	No	<i>Streptococcus pyogenes</i>
	5-year-old male	AOM	Abscess drainage, tympanostomy tube insertion, cortical mastoidectomy, IV antibiotherapy	No	<i>Fusobacterium necrophorum</i>
Asha'ari et al. [12] 2012	73-year-old male	AOM	Abscess drainage, cortical mastoidectomy IV antibiotherapy	Yes	<i>Klebsiella ozaenae</i>
Santhi et al. [9] 2012	5-year-old male	Congenital cholesteatoma	Modified radical mastoidectomy	Yes	-
Garner et al. [3] 2013	5-month-old male	AOM	Abscess drainage, myringotomy, cortical mastoidectomy, IV antibiotherapy	Yes	<i>Streptococcus constellatus</i>
Scrafton et al. [8] 2014	4-year-old male	AOM	Abscess drainage, tympanostomy tube insertion, cortical mastoidectomy, IV antibiotherapy	Yes	<i>Streptococcus pyogenes</i>
Er et al. [6] 2016	9-year-old male	AOM	Abscess drainage, tympanostomy tube insertion, IV antibiotherapy	No	No growth
This report	11-year-old male	AOM	Abscess drainage, tympanostomy tube insertion, cortical mastoidectomy, IV antibiotherapy	Yes	No growth

AOM: acute otitis media; IV: intravenous

obtained from the operation was reported as chronic active inflammation. Culture of the abscess showed no growth. Following the surgical operation, IV antibiotic treatment was completed within 14 days, and the patient was discharged following recovery. The post-operative 1<sup>st</sup> month follow-up demonstrated that his ventilation tube was still in place and that his hearing completely recovered.

## DISCUSSION

Subperiosteal temporal abscess relating to acute otitis media was first described in 1913 by Henri Luc [2]. According to Luc, the disease differs from other subperiosteal abscesses in that it develops without the mastoid bone involvement and that the infection spreads through the notch of Rivinus and branches of the deep auricular arteries located between the roof of the middle ear and the external ear canal, and the subperiosteal area. Consequently, Luc suggests that in the absence of findings of mastoiditis such as retroauricular swelling and persistent otorrhea, there is no need for these patients to undergo mastoidectomy, which is a risky and dangerous surgical intervention.

A very limited number of cases of Luc's abscess have been reported in the literature, particularly following the widespread use of antibiotics. Literature cases of Luc's abscess are shown in Table 1. In the case presented by Knappe et al. [4], a 15-year-old girl underwent mastoidectomy following the diagnosis of Luc's abscess; however, no bony involvement was observed. Consequently, they reported that temporal abscesses had a much better course than other otitic subperiosteal abscesses and that a conservative approach should be considered in its treatment management. Similarly, Weiss et al. [5] presented two 5-year-old boys with Luc's abscess, and no mastoid bone involvement was observed in both cases. In the case presented by Er

et al. [6], no mastoid bone involvement was observed in the temporal CT. Therefore, only needle aspiration of the abscess and a grommet insertion were performed in this case.

Unlike these cases, patients have been reported who have Luc's abscess with mastoid bone involvement. Asha'ari et al. [7] and Garner et al. [3] presented two cases of Luc's abscess relating to acute otitis media. Upon the detection of mastoid bone defect with subperiosteal abscess on CT, cortical mastoidectomy was performed in both cases. Similarly, Scrafton et al. [8] presented a case in which a 6x2 cm temporal abscess with acute mastoiditis on CT was detected. Only a single case with Luc's abscess associated with congenital cholesteatoma was presented by Santhi et al. [9]. Modified radical mastoidectomy operation was performed in this patient.

Review of the literature shows that Luc's abscess often occurs in the pediatric age group and that it develops as a complication of acute otitis media. Only one adult case has been reported in the literature [7], and congenital cholesteatoma has been reported only in one case [9]. It is also noteworthy that Luc's abscess usually affects male patients. However, this has been considered to be a coincidence. Both aerobic and anaerobic bacteria have been found as the causative agents in the abscess cultures. Therefore, broad spectrum antibiotics should be used for the empirical treatment until the final aspirate culture and microbiological advice reports return.

The results of clinical and temporal CT show that Luc's abscess with concomitant mastoiditis has been reported in 3 cases of acute otitis media [3, 7, 8]. Scrafton suggested that cases in which mastoiditis was observed with temporal abscess should be considered as a differ-

ent patient group, unlike described by Luc, and that temporal CT might be a guide<sup>[8]</sup>. In our case, MRI results showed that the abscess reached the temporal region from the external ear canal. Therefore, it followed the dissemination path described by Luc. In addition, cortical mastoidectomy was added to the treatment protocol due to the accompanying mastoid involvement as seen on CT.

In addition, the limitation of jaw movement was priority complain in our patient. The presence of trismus resulted in intubation difficulty. Therefore, unlike the other Luc's abscesses described in the literature, our patient was not scheduled for an emergency surgery. The patient was only able to be taken for surgical operation due to trismus regression following IV antibiotherapy. Trismus, a finding observed in temporal abscesses, occurs as a result of the abscess draining into the mandibular fossa. The presence of an abscess near the temporomandibular joint and edema in the pterygoid muscles on MRI defined the trismus in our patient.

### CONCLUSION

Luc's abscess is a rare but serious complication of otitis media. Although its prognosis is better than other subperiosteal abscesses, it may be life-threatening if the abscess reaches the mandibular fossa by causing trismus. The lack of adequate experience of the clinician may lead to delayed diagnosis and treatment. Temporal CT is a useful imaging tool in determining the spread of the disease and its treatment strategy. Furthermore, cranial MRI may clearly demonstrate the spread of the abscess. The main point in this case is to decide whether mastoidectomy will be added to treatment protocol. Surgical findings in our case support the idea that CT scan is an important factor in this critical decision.

**Informed Consent:** Written informed consent was obtained from the parents of the patient who participated in this study.

**Peer-review:** Externally peer-reviewed.

**Author Contributions:** Concept – E.M., F.N.A.; Design – E.M., F.N.A.; Supervision – E.M., F.T.; Resources – E.M., F.N.A.; Materials - E.M., E.S.; Data Collection and/or Processing – E.M., F.T., E.S.; Analysis and/or Interpretation – E.M., F.N.A.; Literature Search – E.M.; Writing Manuscript – E.M., F.T., E.S., F.N.A.; Critical Review – E.M., F.N.A.

**Conflict of Interest:** The authors have no conflict of interest to declare.

**Financial Disclosure:** The authors declared that this study has received no financial support.

### REFERENCES

1. Spiegel JH, Lustig LR, Lee KC, Murr AH, Schindler RA. Contemporary presentation and management of a spectrum of mastoid abscesses. *Laryngoscope* 1998; 108: 822-8. [\[CrossRef\]](#)
2. Luc H. Sub-periosteal temporal abscess of otic origin without intra-osseous suppuration. *Laryngoscope* 1913; 23: 999-1003. [\[CrossRef\]](#)
3. Garner EF, McKinnon BJ. Luc's abscess-a case report. *Int J Pediatr Otorhinolaryngol Extra* 2013; 8: e5-7. [\[CrossRef\]](#)
4. Knappe MV, Gregor RT. Luc's abscess--a rare complication of middle-ear infection. *J Laryngol Otol* 1997; 111: 461-4.
5. Weiss I, Marom T, Goldfarb A, Roth Y. Luc's abscess: the return of an old fellow. *Otol Neurotol* 2010; 31: 776-9. [\[CrossRef\]](#)
6. Er A, Erdağ TK, Çağlar A, Kümüş O, Duman M. Luc abscess: an extraordinary complication of acute otitis media. *Am J Emerg Med* 2016; 34: 117. e1-3. [\[CrossRef\]](#)
7. Asha'ari ZA, Shiyuti MI, Zihni M. Luc's abscess: a reminder of potential complication of otitis media. *Brunei Int Med J* 2012; 8: 261-4.
8. Scrafton DK, Querishi A, Nogueira C, Mortimore S. Luc's abscess as an unlucky complication of mastoiditis. *Ann R Coll Surg Engl* 2014; 96: e28-30. [\[CrossRef\]](#)
9. Santhi K, Tang IP, Nordin A, Prepageran N. Congenital cholesteatoma presenting with Luc's abscess. *J Surg Case Rep* 2012; 2012: rjs026.