

## ARTICLE

## Value of p53 Protein in Biological Behavior of Basal Cell Carcinoma and in Normal Epithelia Adjacent to Carcinomas

Nese CALLI DEMIRKAN, Nagihan COLAKOGLU, Ender DÜZCAN

Department of Pathology, Pamukkale University, Turkey

Mutations in p53 gene are the most frequent gene alterations in human cancer. In this study, we have used the monoclonal antibody (DO7) to evaluate the role of the p53 gene mutation in the progression of basal cell carcinomas towards invasion. We tested the positivity for p53 protein in tumor cells in six cases of basosquamous cell carcinoma (BSCC), in twelve cases of infiltrative basal cell carcinoma (IBCC) and twenty-four cases of non-infiltrative basal cell carcinoma (NIBCC) in order to evaluate its potential prognostic significance. We also tested the expression of p53 protein in normal epithelia adjacent to carcinomas in order to determine its role in tumor progres-

**Keywords:** ageing, basal cell carcinoma, p53 protein

sion. p53 protein staining with some peripheral accentuation was identified in 42,9% of all groups. No correlation was found between the immunoreactivity of p53 protein and recurrence, pattern of tumor, diameter of the tumors and sex. However, there were statistically significant differences in positivity of p53 protein in normal epithelia adjacent to carcinomas and age of patients (t value: 2,21; p: 0,034). Results of the study suggest that the increase in p53 mutation frequency of morphologically normal epidermis was related to age and was independent of the degree of differentiation of BCC. (Pathology Oncology Research Vol 6, No 4, 272-274, 2000)

### Introduction

Mutations in p53 may occur early or late in the stepwise development of epithelial malignancy. The chronic exposure to sunlight has been found to be responsible for accumulation of p53 mutation in cutaneous carcinogenesis.<sup>2,8,11</sup> We tested positivity for p53 protein in non-infiltrative (NIBCC) and infiltrative basal cell carcinoma (IBCC) and basosquamous cell carcinoma (BSCC). We evaluated also the expression of p53 protein in normal epithelia adjacent to carcinomas in order to determine its role in tumor progression. There was no significant correlation between the degree of positivity of p53 protein and tumor progression in all the three groups of BCC. However, the relationship between age of patients and expression of p53 protein in normal epithelia adjacent to carcinomas seems to support the role of the p53 mutation in early BCC progression.

*Received:* March 3, 2000; *revised:* Nov 8, 2000; *accepted:* Dec 1, 2000

*Correspondence:* Nese Calli DEMIRKAN, 269 sok. No: 46-8 Ucyol 35280 Izmir, Turkey; Tel: +90 232 2273603; Fax: +90 232 8539220; e-mail: nesebahir@hotmail.com

### Materials and Methods

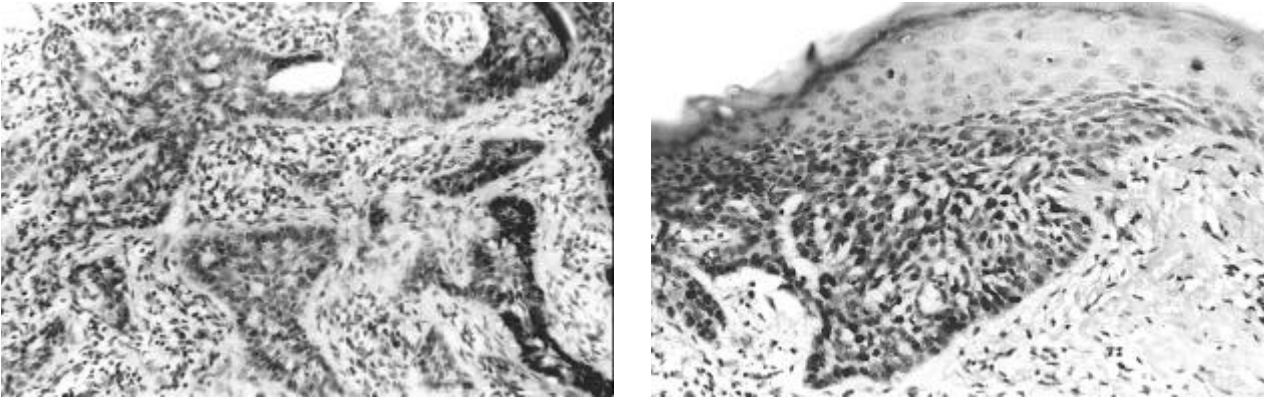
From January 1996 to June 1999, a total of 42 consecutive BCC's were examined in Pathology Department of Pamukkale University, and by subtype 6 cases of BSCC, 12 cases of infiltrative BCC and 24 cases of non-infiltrative BCC were identified. The three groups studied were defined as follows:

**NIBCC** – Aggregates of uniform basophilic cells originating from the epidermis, showing well-defined peripheral contours.

**IBCC** – Irregular, jagged and spiked configuration of the peripheral contours of tumor islands of basaloid cells.<sup>4,13</sup>

**BSCC** – Dermal infiltration of nests of basaloid cells, with peripheral palisading demonstrating foci of squamous cells with intercellular bridges and epithelial pearls. Both pseudoepithelial hyperplasia associated with BCC and the keratinizing form of BCC were excluded.<sup>7</sup>

Sections (4 microns) of routinely processed specimens from each case were dewaxed in xylene and brought to distilled water through ethanol. Sections were treated with anti-p53 (DO-7) monoclonal antibodies (DAKO) and incubated for 30 min at room temperature. To assess p53



**Figure 1, 2.** p53 Protein positivity in the tumoral nests x100, x200. At higher magnification, the BCC nest positivity is accompanied by two positive keratinocytes in the adjacent epidermis.

staining, sections were scored as: 0: tumor cells not exhibiting nuclear reactivity, 1+: <10 %, 2+: 10-50%; 3+: 50-70%; and 4+: >70%.<sup>3</sup>

Methods used for statistical analysis included: Chi-Square test for analysis of differences in degree of positivity of p53 among groups, paired t-test and Mann-Whitney's U test for analysis of differences between unpaired and paired groups; probability values less than 0.05 were considered statistically significant.

### Results

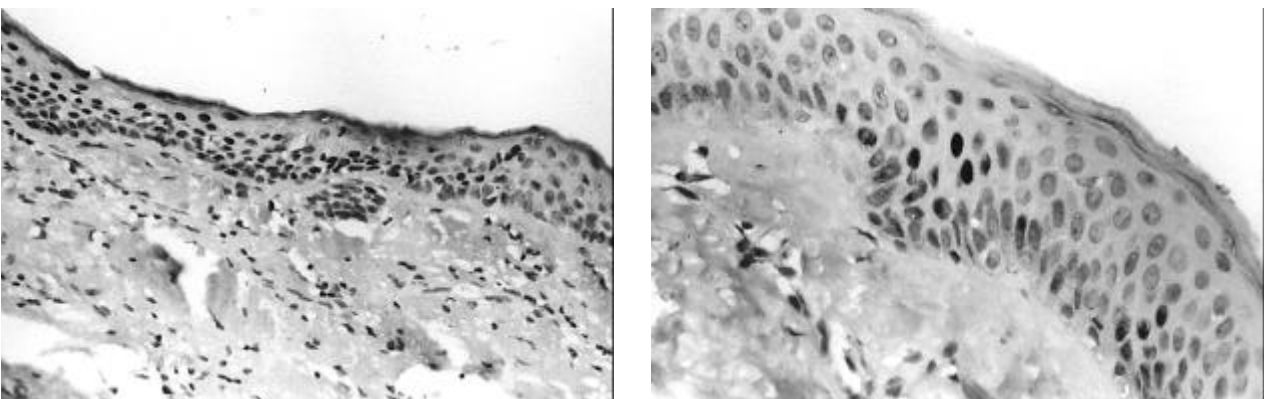
The mean age of study cases was 65 years old and with the exception of one tumor, all were localized to sun exposed areas. The distribution of p53 protein positive cells was predominantly at the periphery of carcinoma nests with palisade-arranged cells. Rates of positivity for p53 expression in the different groups are shown in *Table 1*. Of 18 cases (42,9%) with p53-positivity BCCs, 2 cases of NIBCC (2/24), 2 cases of IBCC (2/12) and 2 cases of BSCC (2/6) demonstrated immunoreactivity of (+3). Among IBCC, 3 cases of 12 showed a low positivity (+1). There was no significant correlation between the degree of positivity of p53 protein in all

the three groups of BCC ( $p>0.05$ ). Clinically there was recurrence in 19% of all cases independent of the histological subtype. The correlation between p53 immunoreactivity and the parameters sex, recurrence, pattern of tumor, diameter of tumor was not significant ( $p>0.05$ ).

The positivity of p53 in normal epithelia adjacent to carcinomas was found in 26,1% (total of 42 cases). The mean age in this group was statistically higher than the mean of the study group (t value:2,21,  $p: 0.034$ ) (*Figure 5*).

### Discussion

BCC is a multifactorial disease in which both environmental factors and host genetic factors are implicated in tumorigenesis. Mutation of the p53 gene may result in a loss of tumor suppressor activity resulting in increased oncogenic potential. In fact a high prevalence (12-58%) of p53 mutations has been reported in BCC (2). We found 42,3% nuclear positivity of p53 in all groups. Ro et al observed p53 positivity in 42% of basal cell carcinomas.<sup>12</sup> They concluded that detectable p53 protein is a common occurrence in malignant epithelial lesions, but it does not correlate with the malignant phenotype or with metastatic



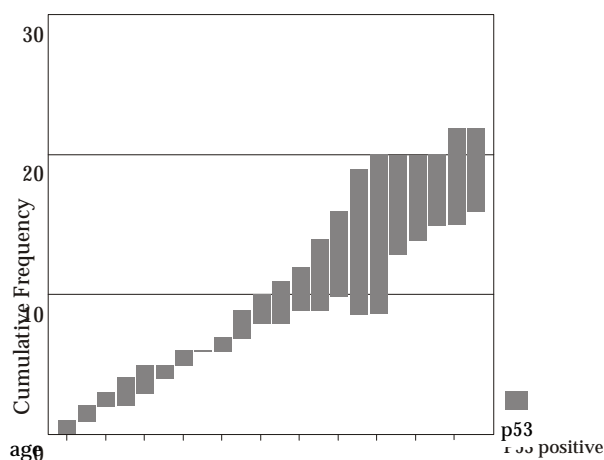
**Figure 3, 4.** p53 Positivity in the normal epithelium adjacent to BCC x100, x200.

**Table 1. p53 Expression in each BCC groups**

	NIBCC (%)	IBCC (%)	BSCC (%)	Total (%)
Normal epidermis	6 (14,3)	4 (9,5)	1 (2,3)	11 (26,1)
Tumor nests	8 (19,1)	8 (19,1)	2 (4,7)	18 (42,9)

potential. In our study, the distribution of positivity of p53 protein in each of the three groups was: 4,7% of BSCC, 19,1% of IBCC, 19,1% of NIBCC. There were no statistically significant differences among them. Our results suggest that the overexpression of p53 protein does not always reflect the degree of malignancy in neoplasms which conflicts with the observations of De Rosa et al.<sup>3</sup>

In this study, we also observed focal positivity in normal epithelia adjacent to carcinomas in 26,1 % of all cases. There was no correlation between p53 immunoreactivity of tumoral cells and nontumoral keratinocytes. However the positivity of p53 in normal epithelia adjacent to BCC was significant in the cases with age greater than 65 (mean age of the study group). Similarly, Gunterson et al found p53 mutations at multiple foci in mucosal cells adjacent to SCC.<sup>5</sup> Shea et al also detected focal positivity in keratinocytes of chronically sun-exposed epidermis adjacent to BCCs.<sup>14</sup> Sunlight exposure is the most important environmental factor in BCC development as shown by the accumulation of typical UV-induced mutations in the p53 gene of late onset tumors.<sup>1,10,15</sup> The advanced aged groups in our study lead us to conclude that chronic UV light exposure induces both p53 accumulation in the epidermis and frequent clonal expansion of p53 mutant cells in the epidermis adjacent to BCCs. However it is not certain whether the mutation of p53 gene actually occurs early or late in the developmental process of epithelial malignancy.<sup>2,6</sup>



**Figure 5.** Cumulative frequency of p53 protein positivity in the normal epithelia adjacent to carcinoma.

The study of Liang et al have shown a marked correlation between p53 expression and patient age especially in BCC, similar to our findings. But they suggest that, contrary to our results, the p53 score in nests of BCC tended to be higher in the more highly differentiated adenoid type than in the less well-differentiated solid type.<sup>9</sup>

Our findings in the normal epithelia adjacent to BCC suggest that further investigation should be carried out to determine the frequency of p53 mutation in morphologically normal epidermis following chronic UV exposure and its relationship to non-melanoma skin cancer.

### References

- <sup>1</sup>Barret TL, Smith KJ, Hodge JJ, et al: Immunohistochemical nuclear staining for p53, PCNA and Ki-67 in different histologic variants of basal cell carcinoma. *J Am Acad Dermatol* 37:430-437, 1997.
- <sup>2</sup>D'Errico M, Calcagnile AS, Corona R, et al: p53 Mutations and chromosome instability in basal cell carcinoma s developed at an early or late age. *Cancer Res* 57:747-752, 1997.
- <sup>3</sup>De Rosa G, Staibano S, Barra E, et al: p53 Protein in aggressive and non-aggressive basal cell carcinoma. *J Cutan Pathol* 20:429-434, 1993.
- <sup>4</sup>Dixon AY, Lee SH, McGregor DH: Histologic evolution of basal cell carcinoma recurrence. *Am J Dermatopathol* 13:241,1991.
- <sup>5</sup>Gunterson BA, Anbazhagan R, Warren W: Expression of p53 in premalignant and malignant squamous epithelium. *Oncogene* 6:1785-1789, 1986.
- <sup>6</sup>Helander SD, Peters MS, Pittelkow MR: Expression of p53 protein in benign and malignant epidermal conditions. *J Am Acad Dermatol* 29:741-748, 1993.
- <sup>7</sup>Jones MS, Helm KF, Maloney ME: The immunohistochemical characteristics of the basosquamous cell carcinoma. *Dermatol Surg* 23:181-184, 1997.
- <sup>8</sup>Kirkham N: Tumors and cysts of the epidermis. In: Lever's histopathology of the skin (Eds: Elder D, Elenistas R, Jaworsky C, Johnson B). 1997, pp 719-731. Philadelphia New York, Lippincott-Raven.
- <sup>9</sup>Liang SB, Ohtsuki Y, Furihata M, et al: Sun-exposure and ageing-dependent p53 protein accumulation results in growth advantage for tumour cells in carcinogenesis of nonmelanocytic skin cancer. *Virchows Arch* 434:193-199, 1999
- <sup>10</sup>Matsumura Y, Nishigori C, Yagi T, et al: Characterization of p53 gene mutations in basal-cell carcinomas: comparison between sun-exposed and less-exposed skin areas. *Int J Cancer* 65:778-780, 1996.
- <sup>11</sup>Onodera H, Nakamura S, Sugai T: Cell proliferation and p53 protein expressions in cutaneous epithelial neoplasms. *Am J Dermatopathol* 18:580-588, 1996.
- <sup>12</sup>Ro YS, Cooper PN, Lee JA, et al: p53 protein expression in benign and malignant skin tumours. *Br J Dermatol* 128:237-241, 1993.
- <sup>13</sup>Sexton M, Jones DB, Maloney ME: Histologic pattern analysis of basal cell carcinoma. *J Am Acad Dermatol* 23:1118-1126, 1990.
- <sup>14</sup>Shea CR, McNutt NS, Volkenandt M, et al: Overexpression of p53 protein in basal cell carcinomas in human skin. *Am J Pathol* 141:25, 1992.
- <sup>15</sup>Urano Y, Asano T, Yoshimoto K, et al: Frequent p53 accumulation in the chronically sun-exposed epidermis and clonal expansion of p53 mutant cells in the epidermis adjacent to basal cell carcinoma. *J Invest Dermatol* 104:928-932, 1995.