

Broken and scattered sternal wires

Yusuf Izzettin Alihanoglu, Ismail Dogu Kilic* and Bekir Serhat Yildiz

Faculty of Medicine, Department of Cardiology, Pamukkale University, Denizli, Turkey

* Corresponding author. Faculty of Medicine, Department of Cardiology, Pamukkale University, Kinikli, 20070 Denizli, Turkey. Tel: +90-532-6434948; fax: +90-258-2134922; e-mail: idogukilic@gmail.com (I. D. Kilic).

Received 24 June 2013; accepted 22 July 2013

Keywords: Sternal dehiscence • Wire • Long term

An 80-year old woman underwent coronary artery bypass graft surgery 10 years ago and developed sternal dehiscence; however, she strictly denied surgical repair. X-ray interestingly

demonstrated that sternal wires were broken and scattered over the chest (Fig. 1). This is a rare example showing the effect of dehiscence to the sternal wires in the long term.

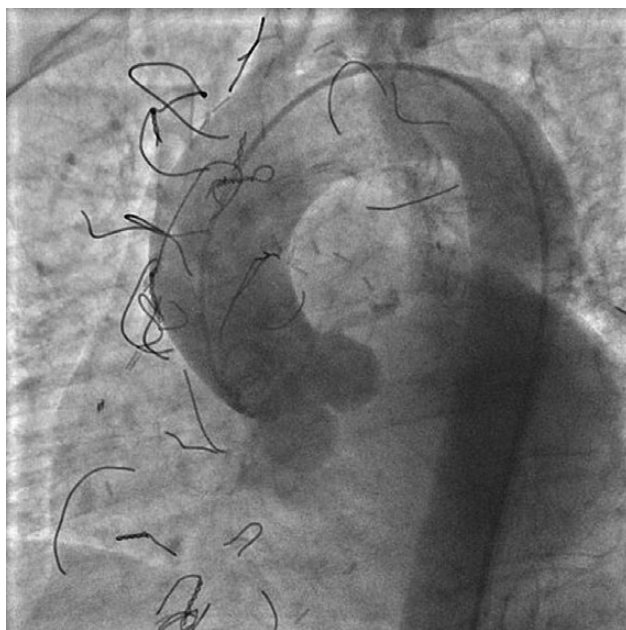


Figure 1: Sternal wires were broken and migrated over the chest.