

## CASE REPORT

# An unexpected long-term complication of genital burn in a child: Secondary cryptorchidism

Mustafa Öksüz, M.D.,<sup>1</sup> Hasan Deliağa, M.D.,<sup>2</sup> Adem Topkara, M.D.,<sup>3</sup> Ömer Faruk Koçak, M.D.<sup>4</sup>

<sup>1</sup>Department of Plastic, Reconstructive and Aesthetic Surgery, Servergazi State Hospital, Denizli-Turkey

<sup>2</sup>Department of Pediatric Surgery, Servergazi State Hospital, Denizli-Turkey

<sup>3</sup>Department of Plastic, Reconstructive and Aesthetic Surgery, Pamukkale University Faculty of Medicine, Denizli-Turkey

<sup>4</sup>Department of Plastic, Reconstructive and Aesthetic Surgery, Yüzüncü Yıl University Faculty of Medicine, Van-Turkey

## ABSTRACT

Genital and perineal burns are rare and challenging injuries with serious long-term complications. Involvement of the testes is a sign of severity. There is limited knowledge in the literature about the management of complications and testes involvement in genital and perineal burns. In this report, we present the case of an 8-year-old boy with secondary cryptorchidism due to burn contracture who was treated by increasing the scrotal volume by Z-plasties, skin graft, and orchidopexy.

**Keywords:** Burn scar; cryptorchidism; genital burn; perineal burn; skin graft.

## INTRODUCTION

Genital and perineal burns generally accompany extensive burns.<sup>[1-3]</sup> They are seldom detected as isolated injuries.<sup>[1-3]</sup> General causes of genital and perineal burns are hot liquids and flames both in children and adults.<sup>[1-4]</sup> Testes involvement is extremely rare and is a sign of high morbidity and even mortality.<sup>[2]</sup> The leading long-term complication is burn scar contracture in genital and perineal burns.<sup>[4,5]</sup> The main problematic issue is to manage it and is still an unsettled question.

## CASE REPORT

An 8-year-old boy was admitted to our hospital because of genital and perineal burn contractures. He had a scald burn injury 3 years ago and was treated by grafting the burned areas. There were constrictive bands passing from the perineum to the groin. The right hemiscrotum was fused with the right thigh. The right testis was not in the scrotum and

palpated in the groin entrapped under the constrictive bands. It was stated by the parents that the right testis was located in the scrotum prior to injury. The left testis was normal. The range of motion of the right leg was limited, especially during abduction (Fig. 1a).

The constrictive bands were released, and groin exploration was performed. The scar tissue did not extend through the inguinal canal. The testis was dissected and prepared for orchidopexy procedure. There was no sign of persistent processus vaginalis or a hernia sac (Fig. 1b). The scrotum was separated from the thigh and was expanded with multiple Z-plasties. The orchidopexy procedure was completed after gaining enough volume into the scrotum for the testis. The skin defects of the thigh and groin were covered by split-thickness skin grafts (Fig. 1c).

The postoperative period was uneventful, and 1 year postoperatively, the results were satisfactory (Fig. 1d).

Cite this article as: Öksüz M, Deliağa H, Topkara A, Koçak ÖF. An unexpected long-term complication of genital burn in a child: Secondary cryptorchidism. *Ulus Travma Acil Cerrahi Derg* 2018;24:85-7

Address for correspondence: Mustafa Öksüz, M.D.

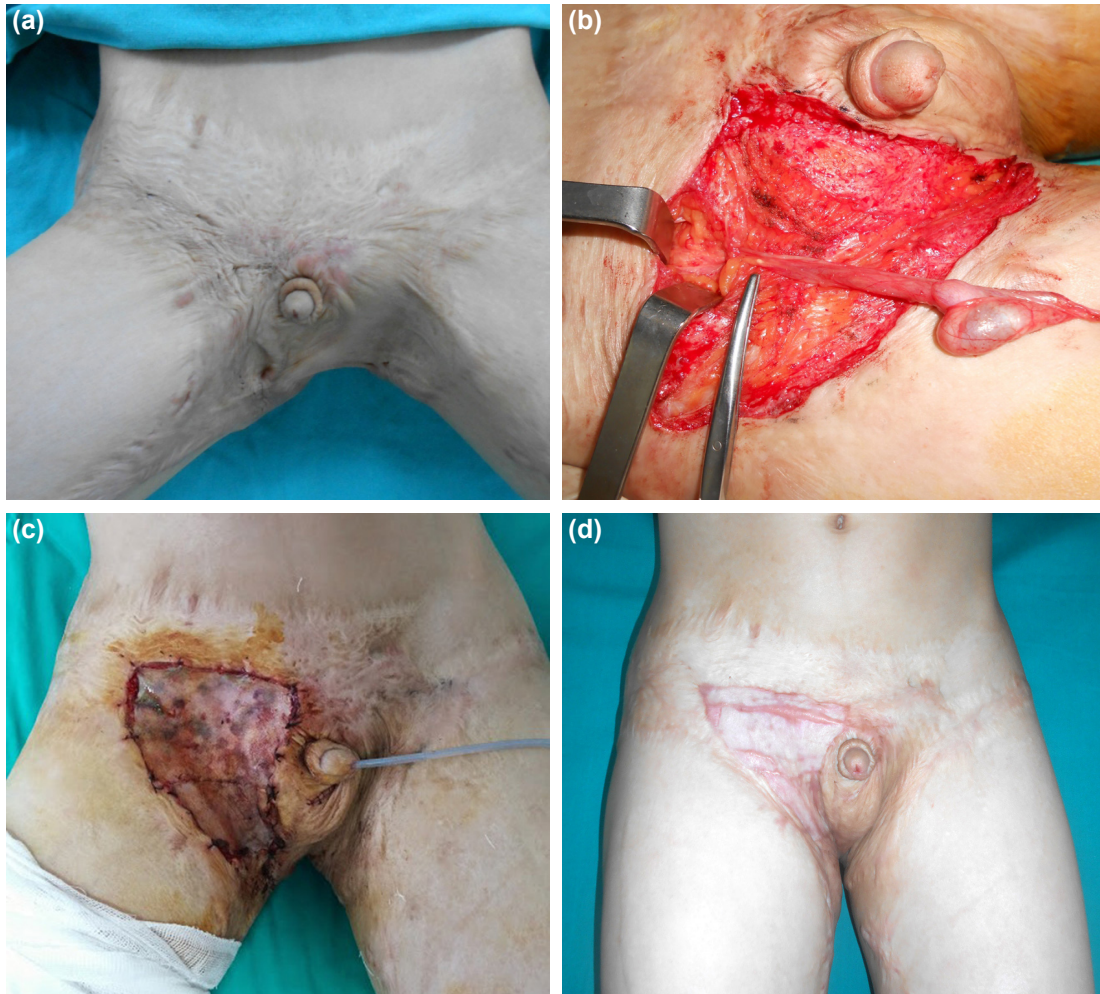
Adres bilgisi: Servergazi Devlet Hastanesi, Plastik, Rekonstrüktif ve Estetik Cerrahi Kliniği, 20000 Denizli, Turkey

Tel: +90 258 - 361 32 32 E-mail: drmustafaoksuz@gmail.com

*Ulus Travma Acil Cerrahi Derg* 2018;24(1):85-87 DOI: 10.5505/tjes.2017.93027 Submitted: 14.04.2016 Accepted: 07.09.2017

Copyright 2018 Turkish Association of Trauma and Emergency Surgery





**Figure 1.** (a) The range of motion of the right leg was limited especially in abduction, and the right hemiscrotum was fused with the right thigh. (b) Image after the right testis is prepared for orchidopexy procedure. There was no sign of a hernia sac or a patent processus vaginalis. (c) The skin defect of the thigh and the groin are covered by split-thickness skin grafts, and the orchidopexy procedure is completed. (d) One year postoperatively, the right hemiscrotum is free from the thigh and the cosmetic result is satisfactory.

## DISCUSSION

Genital and perineal burns are rare injuries because of the secure and protected anatomic location provided by the thighs and abdomen.<sup>[1-3]</sup> They generally accompany extensive burns and are seldom detected solely.<sup>[1-3]</sup> Despite this protection, the reported occurrence is 8.3% in children and 1.7% in adults;<sup>[4]</sup> among these, the occurrence of isolated cases is 0.6%–4%.<sup>[1,2]</sup> Scalds are the primary cause followed by flames, contact, and electrical burns.<sup>[1,2,4]</sup>

The most frequent complication of genital and perineal burns is scar contracture, which causes movement disorders, cosmetic problems, and testes entrapment.<sup>[2,4-7]</sup> Children are more prone to contracture formation because of growth process.<sup>6</sup> Contracture release and coverage of the defect even with skin grafts or local skin flaps is the preferred treatment.<sup>[8-10]</sup> The reported postoperative results are generally satisfactory and complication-free.

The preferred surgical procedures for contracture release in genital and perineal regions are triangular plasty transposition or advancement flaps of local tissue such as Z-plasty.<sup>[6,9]</sup> A musculocutaneous flap is not advised because of possible harm to spermatogenesis due to increase in temperature of testes caused by the flap.<sup>[10]</sup> We performed multiple Z-plasties to release the scrotal contracture and increase the volume of the scrotum in order to prevent re-ascent or compartment syndrome.

Testes involvement in genital and perineal burns is extremely rare because of the mobility provided by the cremasteric reflex and thick cover provided by the scrotal skin, dartos muscle, and tunica albuginea, as well as the protection provided by the anatomic location.<sup>[2,7,8]</sup> It is stated that testes involvement is directly correlated with increased morbidity and even mortality in genital and perineal burns.<sup>[2]</sup> This is probably because testicular involvement is almost always associated with the most severe burns.<sup>[2]</sup>

There are four pediatric testes burns reported in two established studies about testes burns in children.<sup>[2,7]</sup> Three of these cases were diagnosed early and treated with orchiectomy in two patients and orchidopexy in one.<sup>[2]</sup> The fourth case was a long-term complication caused by constrictive bands restricting the testes above the scrotum; the scrotal skin was preserved. Bilateral orchidopexy was the choice of treatment after the release of the constrictive bands.<sup>[7]</sup> The burned scrotum in our patient did not allow us to directly perform orchidopexy because of limited volume of the scrotum; therefore, we had to carry out Z-plasty to expand the scrotum before establishing orchidopexy.

Acquired undescended testes demonstrate the same germ cell maldevelopment that is observed in congenital cryptorchidism because of the increased heat of the testis. The increased heat of the effected testis causes germ cell apoptosis by direct and indirect mechanisms and defective germ cell maturation by heat shock proteins, reactive oxygen species, and Sertoli cell damage. There is also evidence that the risk of testicular malignancy in cryptorchidism is increased by four- to eight-fold. Irrespective of the underlying reason of cryptorchidism, in order to prevent permanent damage to the effected testes, suitable surgical procedures should be performed to protect the testes from germ cell maldevelopment and possible malignancy.<sup>[11–13]</sup>

## Conclusion

Although the long-term functional and cosmetic outcome of burns to the genitals and perineum in children is a challenging problem, there is lack of information in the medical literature to constitute a treatment algorithm.

There is no single perfect genital and perineal skin reconstruction technique defined for burn contractures. The diversity of techniques to reconstruct genital and perineal contracture reflects the challenge and complexity of these defects. The choice of suitable reconstruction modality depends on the surgeon's preference to achieve best reconstructive results with acceptable morbidity.

Although testes burn is a very rare entity, it is a sign of severity when included. Careful examination of the testes should be performed in all children with genital and perineal burns to ensure not missing an entrapped testis as a long-term complication. Orchidopexy should be performed to prevent germ cell maldevelopment and malignancy.

Conflict of interest: None declared.

## REFERENCES

1. Klaassen Z, Go PH, Mansour EH, Marano MA, Petrone SJ, Houg AP, et al. Pediatric genital burns: a 15-year retrospective analysis of outcomes at a level 1 burn center. *J Pediatr Surg* 2011;46:1532–8. [CrossRef]
2. Angel C, Shu T, French D, Orihuela E, Lukefahr J, Herndon DN. Genital and perineal burns in children: 10 years of experience at a major burn center. *J Pediatr Surg* 2002;37:99–103. [CrossRef]
3. Abel NJ, Klaassen Z, Mansour EH, Marano MA, Petrone SJ, Houg AP, et al. Clinical outcome analysis of male and female genital burn injuries: a 15-year experience at a level-1 burn center. *Int J Urol* 2012;19:351–8.
4. Harpole BG, Wibbenmeyer LA, Erickson BA. Genital burns in the national burn repository: incidence, etiology, and impact on morbidity and mortality. *Urology* 2014;83:298–302. [CrossRef]
5. Alghanem AA, McCauley RL, Robson MC, Rutan RL, Herndon DN. Management of pediatric perineal and genital burns: twenty-year review. *J Burn Care Rehabil* 1990;11:308–11. [CrossRef]
6. Grishkevich VM. Burned perineum reconstruction: a new approach. *J Burn Care Res* 2009;30:620–4. [CrossRef]
7. Kara IG, Sarioğlu A. Cryptorchidism as a result of burn injury. *Burns* 1999;25:663–5. [CrossRef]
8. Agarwal P. Scrotal Reconstruction: Our Experience. *Journal of Surgery Pakistan (International)* 2012;17:32–5.
9. Huang T. Management of perineal burn complications in children. *Burns* 2007;33S:S23–4. [CrossRef]
10. Huang T. Management of burn injuries of the perineum. In: Herndon D, editor. *Total Burn Care*. 3rd ed. Elsevier; 2007. p. 749–58. [CrossRef]
11. Barthold JS, González R. The epidemiology of congenital cryptorchidism, testicular ascent and orchioepexy. *J Urol* 2003;170:2396–401. [CrossRef]
12. Ong C, Hasthorpe S, Hutson JM. Germ cell development in the descended and cryptorchid testis and the effects of hormonal manipulation. *Pediatr Surg Int* 2005;21:240–54. [CrossRef]
13. Setchell BP. The Parkes Lecture. Heat and the testis. *J Reprod Fertil* 1998;114:179–94. [CrossRef]

## OLGU SUNUMU - ÖZET

### Yanık skarına bağlı gelişen sekonder kriptorşidizm olgusu

Dr. Mustafa Öksüz,<sup>1</sup> Dr. Hasan Deliağa,<sup>2</sup> Dr. Adem Topkara,<sup>3</sup> Dr. Ömer Faruk Koçak<sup>4</sup>

<sup>1</sup>Servergazi Devlet Hastanesi, Plastik, Rekonstrüktif ve Estetik Cerrahi Kliniği, Denizli

<sup>2</sup>Servergazi Devlet Hastanesi, Çocuk Cerrahisi Kliniği, Denizli

<sup>3</sup>Pamukkale Üniversitesi Tıp Fakültesi, Plastik, Rekonstrüktif ve Estetik Cerrahi Kliniği, Denizli

<sup>4</sup>Yüzüncü Yıl Üniversitesi Tıp Fakültesi, Plastik, Rekonstrüktif ve Estetik Cerrahi Kliniği, Van

Genital ve perianal yanıklar ciddi ve zorlu uzun dönem komplikasyonları ile ortaya çıkabilmektedir. Literatüründe herhangi bir bildirilmiş yanık sekeli olarak oluşan kriptorşidizm olgusuyla karşılaşmadık. Kriptorşidizmde yanıkların rolünü göstermek için, sekiz yaşında yaygın perineal ve inguinal yanıkları sonucu kriptorşidizm olan çocuk bildirilmiştir. Azalan skrotal völüm skarlı doku üzerine z-plasti, deri grefti ve inmemiş testis onarımı ile gerçekleştirildi.

Anahtar sözcükler: Deri grefti; genital yanık; kriptorşidizm; perianal yanık; yanık skar.

Ulus Travma Acil Cerrahi Derg 2018;24(1):85–87 doi: 10.5505/tjtes.2017.93027