



Acute Myeloid Leukemia with Hypothalamic Involvement Causing Central Diabetes Insipidus

Akut Miyeloid Löseminin Hipotalamus Tutulumuna Bağlı Santral Diabetes İnsipidus

✉ Furkan Ufuk¹, ✉ Mehmet Duran¹, ✉ Mehmet Sercan Ertürk²

¹Pamukkale University Faculty of Medicine, Department of Radiology, Denizli, Turkey

²Pamukkale University Faculty of Medicine, Department of Endocrinology, Denizli; Mus State Hospital, Department of Endocrinology, Mus, Turkey

Keywords: Acute myeloid leukemia, hypothalamus, magnetic resonance imaging, central diabetes insipidus

Anahtar Kelimeler: Akut miyeloid lösemi, hipotalamus, manyetik rezonans görüntüleme, santral diabetes insipidus

Dear Editor,

A 37-year-old man presented to the emergency department with symptoms of high fever, polyuria, and polydipsia. A physical examination revealed body temperature of 37.8 °C, heart rate of 118 beats per minute, blood pressure of 95/60 mmHg, and oxygen saturation of 97% in room air. The patient had pale conjunctiva. He had no past medical history. A detailed recent history showed that the patient had unintentional weight loss of 20 pounds in the past 1 month.

Laboratory tests revealed low white blood cell count ($2 \times 10^3/\mu\text{L}$; normal range $4-10 \times 10^3/\mu\text{L}$), low hemoglobin count (10.2 g/dL; normal range 14-16 g/dL), elevated C-reactive protein level (2.6 mg/dL; normal range 0-0.5 mg/dL), high erythrocyte sedimentation rate (80 mm/h; normal range 0-15 mm/h), high mean cell volume (132 fL; normal range 80-96 fL), high platelet count ($603 \times 10^3/\mu\text{L}$; normal range $150-400 \times 10^3/\mu\text{L}$), and elevated serum sodium level (157 mEq/L; normal range 135-145 mEq/L). The physical examination, clinical history, and laboratory findings suggested diabetes insipidus. Hormone analysis showed decreased pituitary hormones levels (thyroid-stimulating hormone 0.04 $\mu\text{IU/mL}$; normal range 0.2-4.2 $\mu\text{IU/mL}$, free-T₄ 0.801 ng/dL; normal range 0.99-1.65 ng/dL, cortisol 3.21 $\mu\text{g/dL}$; normal range 10-20 $\mu\text{g/dL}$, adrenocorticotropin 7.3 pg/mL; normal range 8-50 pg/mL). The clinical and laboratory findings of the patient showed panhypopituitarism.

The patient underwent hyponatremic intravenous hydration (0.45% saline and 5% dextrose). After this treatment, the 24-hour urine volume was 6000-7000 cc. A water deprivation

test demonstrated worsening of hypernatremia. The serum osmolality test showed hyperosmolality with inappropriate low urine osmolality. Urinary osmolality was increased two-fold following vasopressin administration. Nasal 1-deamino-8-D-arginine vasopressin was started with the diagnosis of central diabetes insipidus (CDI). Polydipsia and polyuria were improved.

The serum total protein level was decreased (52 g/L; normal range 65-85 g/L) and beta-2 microglobulin level was elevated (6.3 mg/L; normal range <2 mg/L). Serum immunoglobulin levels were normal. A smear of bone marrow aspirate showed sheets of myeloid cells that accounted for 82% of the overall nucleated cell population. Large, bi-nucleate and trinucleate forms were noted. Many of these atypical myeloid cells contained small, inconspicuous nucleoli. The patient was diagnosed as having acute myeloid leukemia (AML). Genetic analysis showed monosomy of chromosome 7.

The patient underwent contrast-enhanced cranial magnetic resonance imaging (MRI) to investigate the cause of CDI and panhypopituitarism. MRI showed hypothalamic hyperintensity on fluid attenuation inversion recovery images and contrast enhancement on T1-weighted images (Figure 1, 2).

CDI is an unusual complication of AML and is seen in less than 1% of patients with AML. The pathogenesis of CDI in patients with myeloid leukemia is unclear. It has been reported that CDI associated with AML may develop due to different mechanisms such as leukemic infiltration, chromosomal abnormalities, thrombocytosis, and dysmegakaryopoiesis. Peri pituitary leukemic

Address for Correspondence/Yazışma Adresi: Furkan Ufuk MD, Pamukkale University Faculty of Medicine, Department of Radiology, Denizli, Turkey

Phone: +90 554 511 50 88 E-mail: furkan.ufuk@hotmail.com ORCID ID: orcid.org/0000-0002-8614-5387

Received/Geliş Tarihi: 14.06.2017 **Accepted/Kabul Tarihi:** 27.07.2017

©Copyright 2018 by Turkish Neurological Society
Turkish Journal of Neurology published by Galenos Publishing House.

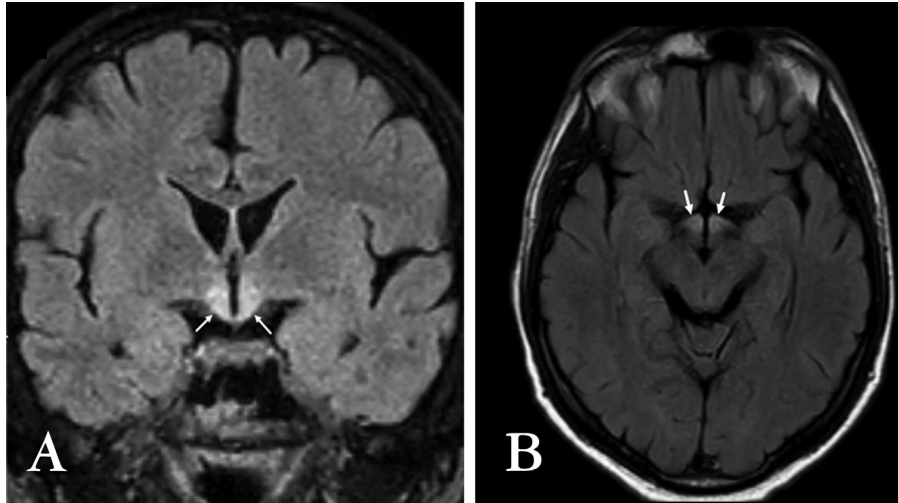


Figure 1. A) Coronal and B) axial fluid attenuation inversion recovery images shows hyperintensity in hypothalamic areas consistent with edema (white arrows)

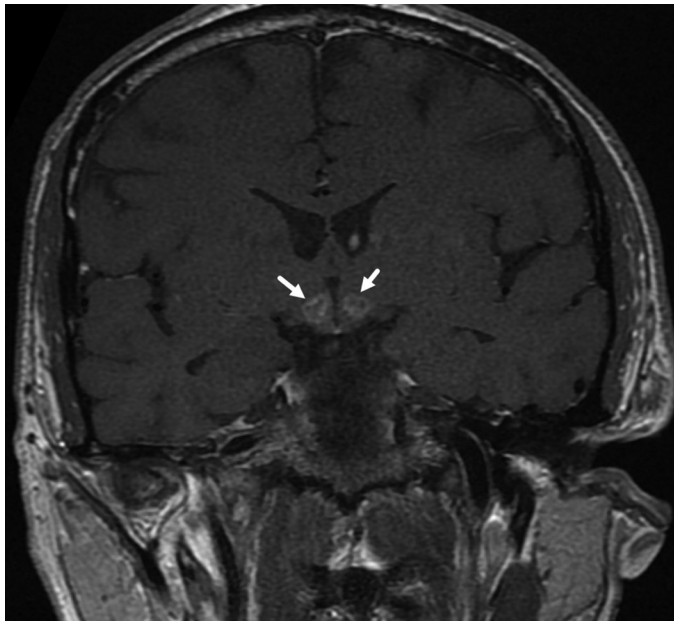


Figure 2. Contrast-enhanced T1-weighted image shows contrast enhancement in hypothalamus (white arrows)

infiltrations have been shown in postmortem studies in patients with AML without clinical CDI (1,2).

Ethics

Informed Consent: Written informed consent was taken from patient.

Peer-review: Internally peer-reviewed.

Authorship Contributions

Surgical and Medical Practices: M.S.E., M.D., Concept: M.S.E., M.D., Design: M.S.E., M.D., Data Collection or Processing: M.D., F.U., Analysis or Interpretation: F.U., Literature Search: M.D., F.U., Writing: F.U.

Conflict of Interest: No conflict of interest was declared by the authors.

Financial Disclosure: The authors declared that this study has received no financial support.

References

1. Dy P, Chua P, Kelly J, Liebman S. Central diabetes insipidus in the setting of acute myelogenous leukemia. *Am J Kidney Dis* 2012;60:998-1001.
2. Yamagami K, Yoshioka K. Central diabetes insipidus presenting as an early sign of acute myeloid leukemia. *Clin Adv Hematol Oncol* 2012;10:400-401.