



6-2019

## Patent foramen ovale closure in young Patients with cryptogenic stroke: a case series and follow up from Saudi population.

Aishah Albakr

*Imam Abdulrahman Bin Faisal University, Dammam, Kingdom of Saudi Arabia*

Noman Ishaque

*Imam Abdulrahman Bin Faisal University, Dammam, Kingdom of Saudi Arabia.*

Rizwana Shahid

*Imam Abdulrahman Bin Faisal University, Dammam, Kingdom of Saudi Arabia.*

Alaa Jamal Al Obaidli

*Imam Abdulrahman Bin Faisal University, Dammam, Kingdom of Saudi Arabia*

Noora Waleed Alayyaf

*Imam Abdulrahman Bin Faisal University, Dammam, Kingdom of Saudi Arabia.*

*See next page for additional authors*

Follow this and additional works at: <https://ecommons.aku.edu/pjns>

 Part of the [Neurology Commons](#)

### Recommended Citation

Albakr, Aishah; Ishaque, Noman; Shahid, Rizwana; Al Obaidli, Alaa Jamal; Waleed Alayyaf, Noora; AlMansoori, Mohammed; and Saleh Al Amri, Sarah Ali (2019) "Patent foramen ovale closure in young Patients with cryptogenic stroke: a case series and follow up from Saudi population.," *Pakistan Journal of Neurological Sciences (PJNS)*: Vol. 14 : Iss. 2 , Article 7.

Available at: <https://ecommons.aku.edu/pjns/vol14/iss2/7>

---

# Patent foramen ovale closure in young Patients with cryptogenic stroke: a case series and follow up from Saudi population.

## **Authors**

Aishah Albakr, Noman Ishaque, Rizwana Shahid, Alaa Jamal Al Obaidli, Noora Waleed Alayyaf, Mohammed AlMansoori, and Sarah Ali Saleh Al Amri

# PATENT FORAMEN OVALE CLOSURE IN YOUNG PATIENTS WITH CRYPTOGENIC STROKE: A CASE SERIES AND FOLLOW UP FROM SAUDI POPULATION

Aishah Albakr<sup>1</sup>, Noman Ishaque<sup>1</sup>, Rizwana Shahid<sup>1</sup>, Alaa Jamal.Al Obaidli<sup>2</sup>, Noora Waleed Alayyaf<sup>3</sup>, Mohammed AlMansoori<sup>4</sup>, Sarah Ali Saleh Al Amri<sup>5</sup>

1. Assistant Professor, Department of Neurology, College of Medicine, Imam Abdulrahman Bin Faisal University, Dammam, Kingdom of Saudi Arabia.

2. Undergraduate medical student, Imam Abdulrahman Bin Faisal University, Dammam, Kingdom of Saudi Arabia. 3. Undergraduate medical student, Imam Abdulrahman Bin Faisal University, Dammam, Kingdom of Saudi Arabia.

4. Assistant Professor, Department of Cardiology, College of Medicine, Imam Abdulrahman Bin Faisal University, Dammam, Kingdom of Saudi Arabia.

5. Resident, Department of Neurology, King Fahd Hospital of University, Al Khobar, Kingdom of Saudi Arabia

**Correspondence to:** Noman Ishaque Assistant Professor, Department of Neurology, College of Medicine, Imam Abdulrahman Bin Faisal University, Dammam, Kingdom of Saudi Arabia  
Email: nishaque@iau.edu.sa

**Date of submission:** December 13, 2018 **Date of revision:** March 21, 2019 **Date of acceptance:** March 29, 2019

## ABSTRACT:

One quarter of cerebral infarctions are cryptogenic and most of these patients are young. Patent Foramen Ovale (PFO) is found to be more prevalent in young persons with cryptogenic stroke and risk of stroke recurrence in such patients ranges from as low as 2% per annum to as high as 12% per annum. Since patients with PFO and cryptogenic stroke are young they need more effective ways to reduce risk of stroke recurrence hence percutaneous closure of PFO seems reasonable approach to deal with this etiology of stroke in such population. We report four cases of cryptogenic stroke in young Saudi patients. PFO closure was performed in all. After closure, none of them developed either recurrence of symptoms or any complication on follow up for more than one year.

**Conclusion:** PFO closure can be considered for preventing stroke recurrence in selected young persons with both cryptogenic stroke and PFO.

**Keywords:** Cryptogenic, Young, Stroke, PFO, Closure

**INTRODUCTION:** One quarter of cerebral infarctions is cryptogenic and Patent Foramen Ovale (PFO) is highly prevalent in such patients especially those less than 50 years. PFO is a persistent passage between two atria and is visualized in about 25% of general population. PFO is considered to cause stroke either by paradoxical embolism or by in situ thrombus formation. Recently published three randomized trials have demonstrated efficacy of PFO closure in preventing stroke recurrence in patients with PFO and cryptogenic cerebral infarction. We report four cases of cryptogenic cerebral infarction in young patients in whom PFO was found and closure of PFO was performed with follow up.

## Case presentation

### Case 1:

43 years old gentleman, smoker, no known medical illness reported to emergency department complaining of weakness of left side of body. His neurologic examination revealed decreased sensation on left side of body. MRI head showed acute infarction of right thalamocapsular junction. CT angiogram of head and neck as well as 24 hour holter monitoring were

unremarkable .His HbA1c was normal and lipid profile revealed high cholesterol and LDL. His work up for thrombophilia as well as autoimmune disease was negative. His trans-esophageal echo showed Patent Foramen Ovale. During hospitalization, his blood pressure readings were within normal ranges. His PFO was closed one week later without any complication. He was discharged on dual antiplatelet therapy and statin. He followed up in clinic for 14 months without new neurologic symptoms or signs.

### Case 2:

36 years old gentleman, smoker, no known medical illness presented with complaint of left sided body weakness. His neurologic examination revealed mild weakness of left side involving face, arm and leg. His MRI head showed acute infarction involving right periventricular area. MR angiogram of head and neck was unremarkable. His ECG showed normal sinus rhythm. His lipid profile and HbA1c were normal. His thrombophilic work up as well as autoimmune work up was negative. His trans-esophageal echo showed PFO with mobile interatrial septum. During hospitalization,

his blood pressure readings were within normal ranges. He underwent closure of PFO 10 days later without any complication. He was discharged on dual antiplatelet therapy for 6 months and statin. He was followed up in clinic for 12 months without any complaints of recurrence of symptoms.

### Case 3:

44 years old gentleman, tobacco chewer, no previous known medical illness came to emergency department complaining of weakness of right side of body. His neurologic examination was positive for ataxia of right upper and lower limbs and mild right lower extremity weakness. His head MRI showed acute infarction of posterior limb of left internal capsule. MR angiograms of head and neck as well as 24 hour holter monitoring were unremarkable. His HbA1c was normal and lipid profile showed high cholesterol and LDL. His autoimmune work up as well as thrombophilic work up were negative. His transesophageal echo showed PFO. He was normotensive. He underwent percutaneous closure of PFO. He was discharged on dual antiplatelet therapy for 6 months and statin. He followed in clinic for 12 months without recurrence of symptoms.

### Case 4:

44 years old gentleman, non-smoker, hypertensive presented to outpatient clinic with sudden onset left sided weakness lasting 30 minutes. His neurologic examination was unremarkable at time of presentation. His non contrast CT scan of head was unremarkable. His ultrasound Doppler of carotids and ECG were unremarkable. MR or CT angiogram was not done. His HbA1c was normal and lipid profile showed high LDL. His echo showed Patent Foramen Ovale. He was treated with dual antiplatelet therapy, statin and anti-hypertensive medication. 2 weeks later, he underwent percutaneous PFO closure and was kept on dual antiplatelet therapy for 6 months then switched to clopidogrel. He was followed up in clinic for 24 months without any complication.

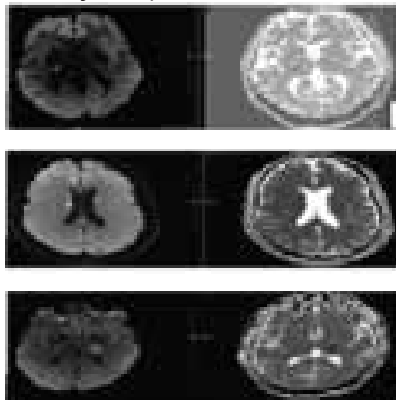


Figure 1. a) Diffusion weighted imaging (DWI) and adjusted Diffusion Coefficient (ADC) of case 1, showing acute infarction of right thalamo-capsular junction/ b) Diffusion weighted imaging (DWI) and adjusted diffusion coefficient (ADC) of case 2, showing acute infarction of right periventricular region. c) Diffusion weighted imaging (DWI) and adjusted diffusion coefficient (ADC) of caes 3, shwoing acute infarction of posterior limb of left internal capsule.

### Discussion

Cryptogenic strokes comprise one fourth of all ischemic strokes and most of them are embolic in nature. Case-control studies have demonstrated that PFO is more frequent in subjects with cryptogenic cerebral infarction than in age-matched subjects without cerebral infarction.<sup>1</sup> The foramen ovale is passage that exists in the wall between the two atria of every human fetus. It normally shuts during infancy but in approximately one quarter of general population it remains patent<sup>2</sup>. In an autopsy based study, overall incidence of PFO was 27% and incidence decreased with increasing age whereas size of defect increased with increased age.<sup>3</sup> In population based study Meissner et al have reported that 24.3% of their sample population had PFO.<sup>4</sup> The correlation of PFO with stroke was first described by Cohnheim in year 1877.<sup>5</sup> Meta-analysis of case-control studies has demonstrated that likelihood of finding PFO was twice in subjects with cerebral infarction as compared to control subjects and this association was three times more likely in group of subjects with cryptogenic cerebral infarction whose ages were less than 55 years.<sup>6</sup> Similar findings have been reported in another meta-analysis of case-control studies demonstrating that likelihood of finding PFO in patients with stroke of unknown etiology was three times higher as compared to age matched control subjects and it increased to fivefold in patients of young age group with cryptogenic cerebral infarction.<sup>7</sup> Prevalence of PFO in subjects with cryptogenic stroke reaches up to 34% to 40%.<sup>7,8</sup> Annual risk of stroke recurrence in patients with PFO has been reported to be ranging from 2% over three year follow up duration to as high as 12.5% at 3 years follow up in high risk patients.<sup>9-13</sup> Two possible mechanisms have been hypothesized by which PFO can cause stroke, one is susceptibility of such patients to atrial arrhythmias with thrombus formation and other is paradoxical embolization.<sup>14</sup> Likelihood that PFO can be cause of stroke increases as patient's age decreases as well as if conventional risk factors for stroke are absent.<sup>15</sup> Younger patients in whom usual risk factors for stroke are not found, such subjects are much more

likely to have PFO than those patients with usual risk factors. Kent et al suggested 10-point Risk of Paradoxical Embolism score (RoPE score) to divide patients with cryptogenic stroke and PFO into high or low likelihood proposing that PFO can be cause of stroke or is incidental finding.<sup>16</sup> This score uses patient's age, cortical infarction on neuroimaging and conventional risk factors of stroke. Higher the RoPE score, higher likelihood that PFO can be cause of stroke. Increased use of saline contrast TEE has increased the frequency of detection of PFO in stroke patients. Three randomized trials published previously addressing hypothesis that PFO closure is better than medical therapy in secondary stroke prevention came out to be negative.<sup>17-19</sup> However, recently published three randomized trials addressing similar question came out to be positive demonstrating that PFO closure is better than medical therapy for secondary stroke prevention in patients with stroke of unknown etiology and PFO. In a randomized, multicentre trial PFO closure along with antiplatelet therapy was found to be significantly better for secondary stroke prevention in patients with stroke whose stroke was attributed to PFO with atrial septal aneurysm or large inter-atrial shunt as compared to antiplatelet therapy alone (Hazard ratio, 0.03; 95% confidence interval, 0-0.26;  $P < 0.001$ ).<sup>20</sup> Also, in extended follow up for a median of 6 years of RESPECT trial cases, recurrence of cerebral infarction was 45% less in patients with cryptogenic stroke and PFO for whom PFO closure was performed.<sup>21</sup> REDUCE trial showed that patients with cryptogenic stroke with PFO who underwent FO closure had 67% lower risk of recurrent ischemic stroke during a median follow up of 3.2 years (HR 0.23%, 95% CI 0.09 to 0.62;  $P = 0.002$ ).<sup>22</sup> All of our cases were less than 45 years of age and their routine stroke work up including CT/MR angiogram of head and neck, 24 hour holter monitor as well as work up for thrombophilia and autoimmune diseases was negative. This fits into description of cryptogenic stroke. Their echocardiograms showed patent foramen ovale. As discussed above, there is strong association of PFO with stroke in such patient population. Therefore, in our cases PFO can be considered as likely source of stroke. So, PFO closure was performed for our cases for secondary stroke prevention. All our cases received medical therapy along with PFO closure as was done in recently published randomized trials of PFO closure. None of our cases had either procedure related complication or recurrence of stroke symptoms during follow up period ranging from 12 months to 24 months.

## Conclusion

Patent foramen ovale can be a cause of stroke in young patients in whom no other cause of stroke can be found on work up. Recent literature has shown efficacy of PFO closure in such patient population. Our cases also demonstrate that PFO closure can be considered in young patients with cryptogenic stroke for secondary prevention of stroke.

## References:

1. Hart RG, Diener HC, Coutts SB, et al. Embolic strokes of undetermined source: the case for a new clinical construct. *Lancet Neurol*, 2014;13(4):429-38
2. Bang OY, Lee MJ, Ryoo S, Kim SJ, Kim JW. Patent Foramen Ovale and Stroke-Current Status. *J Stroke*. 2015;17(3):229-237
3. Hagen PT, Scholz DG, Edwards WD. Incidence and size of patent foramen ovale during first 10 decades of life: an autopsy study of 965 normal hearts. *Mayo Clin Proc* 1984;59:17-20
4. Irene Meissner, Bijoy K. Khandheria, John A. Heit, George W. Petty and Sheldon G. Sheps et al. Patent Foramen Ovale: Innocent or Guilty?: Evidence From a Prospective Population-Based Study. *Journal of the American College of Cardiology*. 2006;47(2):440-445
5. Cohnheim J. Thrombose und embolie. In: *Vorlesungen über Allgemeine Pathologie*. Berlin, Germany: Hirschwald, 1877;1:134
6. Overell JR, Bone I, Lees KR. Interatrial septal abnormalities and stroke: a meta-analysis of case-control studies. *Neurology* 2000;55:1172-1179
7. Alsheikh-Ali AA, Thaler DE, Kent DM. Patent foramen ovale in cryptogenic stroke: incidental or pathogenic? *Stroke* 2009; 40:2349-55.
8. Homma S, Sacco RL, Di Tullio MR, Sciacca RR, Mohr JP. Effect of medical treatment in stroke patients with patent foramen ovale: patent foramen ovale in Cryptogenic Stroke Study. *Circulation*. 2002 Jun 4;105(22):2625-31

9. Homma S, Sacco RL. Patent foramen ovale and stroke. *Circulation*. 2005;112:1063–1072.
10. Mas JL, Arquizan C, Lamy C, Zuber M, Cabanes L, Derumeaux G, Coste J. Recurrent cerebrovascular events associated with patent foramen ovale, atrial septal aneurysm, or both. *N Engl J Med*. 2001;345:1740–1746.
11. Bogousslavsky J, Garazi S, Jeanrenaud X, Aebischer N, Van Melle G, for the Lausanne Stroke with Paradoxical Embolism Study Group. Stroke recurrence in patients with patent foramen ovale: the Lausanne Study. *Neurology*. 1996;46:1301-1305.
12. Mas JL, Zuber M, for the French Study Group on Patent Foramen Ovale and Atrial Septal Aneurysm. Recurrent cerebrovascular events in patients with patent foramen ovale, atrial septal aneurysm or both and cryptogenic stroke or transient ischemic attack. *Am Heart J*. 1995;130:1083-1088
13. De Castro S, Cartoni D, Fiorelli M, Rasura M, Anzini A, Zanette EM, et al. Morphologica and functional characteristics of patent foramen ovale and their embolic implications. *Stroke* 2000;31:2407-2413.
14. Laperche T, Laurian C, Roudaut R, et al. Mobile thromboses of the aortic arch without aortic debris: a transesophageal echocardiographic finding associated with unexplained arterial embolism. *Circulation* 1997;96:288-94
15. Kent DM, Thaler DE. Is patent foramen ovale a modifiable risk factor for stroke recurrence? *Stroke* 2010;41:S26-30
16. Kent DM, Ruthazer R, Weimar C, Mas JL, Serena J, Homma S, et al. An index to identify stroke-related vs incidental patent foramen ovale in cryptogenic stroke. *Neurology* 2013;81:619-625
17. Furlan AJ, Reisman M, Massaro J, et al. Closure or medical therapy for cryptogenic stroke with patent foramen ovale. *N Engl J Med* 2012; 366: 991-9.
18. Carroll JD, Saver JL, Thaler DE, et al. Closure of patent foramen ovale versus medical therapy after cryptogenic stroke. *N Engl J Med* 2013; 368: 1092-100.
19. Meier B, Kalesan B, Mattle HP, et al. Percutaneous closure of patent foramen ovale in cryptogenic embolism. *N Engl J Med* 2013; 368: 1083-91.
20. Mas JL, Derumeaux G, Guillon B, Massardier E, Hosseini H and Mechtouff L et al. Patent Foramen Ovale Closure or Anticoagulation vs. Antiplatelets after Stroke. *N Engl J Med*. 2017 Sep 14;377(11):1011-1021
21. Saver JL, Carroll JD, Thaler DE, Smalling RW et al. Long-Term Outcomes of Patent Foramen Ovale Closure or Medical Therapy after Stroke. *N Engl J Med*. 2017 Sep 14;377(11):1022-1032.
22. Søndergaard L, Kasner SE, Rhodes JF, Andersen G et al. Patent Foramen Ovale Closure or Antiplatelet Therapy for Cryptogenic Stroke. *N Engl J Med*. 2017;377(11):1033-1042
- dysfunction, cytokines and diabetes mellitus. *Hum Health*, 2007a; 3(7 & 8):3-4.

**Conflict of interest:** Author declares no conflict of interest.

**Funding disclosure:** Nil

**Author's contribution:**

**Alishah Albakr;** concept, data collection, data analysis, manuscript writing, manuscript review

**Noman ishaque;** data collection, data analysis, manuscript writing, manuscript review

**Rizwana Shahid;** concept, data collection, data analysis, manuscript writing, manuscript review

**Alaa Jamal.Al Obaidli;** data collection, data analysis, manuscript writing, manuscript review

**Noora Waleed Alayyaf;** data analysis, manuscript writing, manuscript review

**Mohammed AlMansoori;** manuscript writing, manuscript review

**Sarah Ali Saleh Al Amri;** data collection, manuscript writing, manuscript review