

Case Report

OPEN

Entrapment of the Sciatic Nerve Over the Femoral Neck Stem After Closed Reduction of a Dislocated Total Hip Arthroplasty

Benoît Maeder, MD
Patrick Goetti, MD
Jaad Mahlouly, MD
Laurent Mustaki, MD
Thomas Buchegger, MD
Olivier Guyen, MD

From the Department of Orthopaedics and Traumatology, Lausanne University Hospital (CHUV), Lausanne, Switzerland (Dr. Maeder, Dr. Goetti, Dr. Mahlouly, Dr. Mustaki, and Prof. Guyen), and the EHC Ensemble Hospitalier de la Côte, Morges, Switzerland (Dr. Buchegger).

Correspondence to Dr. Maeder: benoit.maeder@gmail.com

JAAOS Glob Res Rev 2019;3:e081

DOI: 10.5435/
JAAOSGlobal-D-18-00081

Copyright © 2019 The Authors. Published by Wolters Kluwer Health, Inc. on behalf of the American Academy of Orthopaedic Surgeons. This is an open-access article distributed under the terms of the Creative Commons Attribution-Non Commercial-No Derivatives License 4.0 (CCBY-NC-ND), where it is permissible to download and share the work provided it is properly cited. The work cannot be changed in any way or used commercially without permission from the journal.

Abstract

Sciatic nerve injury is a rare but potentially extremely disabling complication of posterior dislocated total hip arthroplasty. Initial closed reduction is recommended followed by a careful neurovascular examination. This procedure and the following stability testing are usually safe and typically associated with a very low complication rate. We report the case of sciatic nerve entrapment around the neck of the femoral stem after closed reduction of a posteriorly dislocated total hip arthroplasty. Immediate postreduction palsy led to surgical exploration, identification, neurolysis of the sciatic nerve and safe reduction was performed. Patient outcome was marked by complete sensitive sciatic nerve recovery, but complete loss of motor sciatic nerve function. This case highlights the importance of careful postreduction neurovascular assessment and prompt surgical exploration when indicated.

The risk of instability after total hip arthroplasty (THA) ranges between 1% and 3.2% after primary surgery, and can reach 7% or even more after revision THA.¹⁻³

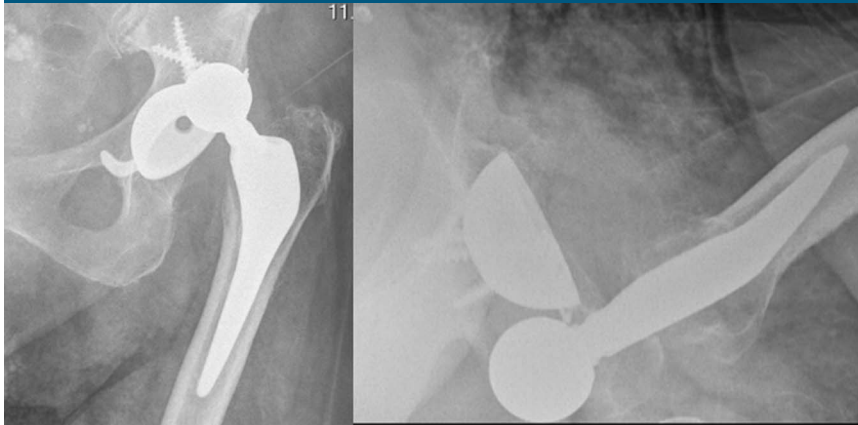
The sciatic nerve originates from the L4 to S3 segments of the lumbosacral plexus and travels through the greater sciatic notch to reach the posterior compartment of the thigh just beneath the piriformis tendon. Anatomical variants do exist, and in 10% to 15%, one division of the sciatic nerve passes through the piriformis muscle and the other below it.⁴ Sciatic nerve lesion will lead to a disabling loss of sensitivity over the top of the foot and inability to extend the foot dorsally (known as foot drop).

Posterior approach to the hip (Moore or Southern approach) is one of the most popular approaches to the hip for primary and revision THA. Through this approach, the sciatic nerve can be identified but is also at risk of iatrogenic lesions.

The incidence of sciatic nerve lesions during a THA is around 1% to 3%.⁵ Prevalence of sciatic nerve lesions (entrapment, incomplete tear, stretching) secondary to THA dislocation has been reported to be approximately 3%.^{6,7} In the absence of previous lesion to the nerve, iatrogenic risk of lesion after closed reduction is rare.

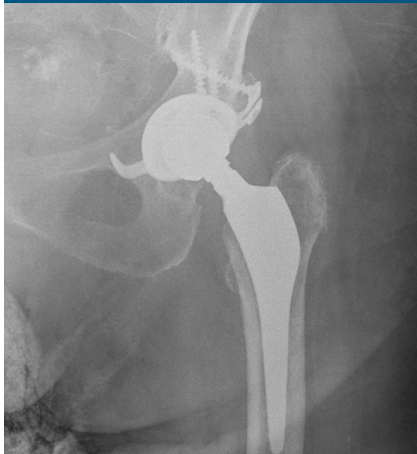To our knowledge, there are less than 10 cases of sciatic nerve entrapment

Figure 1



AP and axial radiographs of the left hip showing a dislocated total hip arthroplasty.

Figure 2



Postoperative radiograph after closed reduction.

around the femoral neck stem after closed reduction of dislocated THA reported in the literature.^{2,8-12}

We report the case of sciatic nerve entrapment after closed reduction of posteriorly dislocated THA with the aim of highlighting the importance of careful postreduction neurovascular assessment and prompt surgical management in case of nerve injury.

Case Report

An 87-year-old woman was referred to our university hospital emergency department because of sudden disabling pain in the left buttock following an attempt to stand up from a sitting position.

On clinical examination, she presented with a shortened, flexed, and internally rotated left leg without any neurovascular impairment. Standard radiographs confirmed a posterior-superior dislocated left THA (Figure 1).

THA was implanted 13 years earlier through a posterior Moore approach. She sustained a revision surgery 3 years earlier through the same posterior approach for mobile implants exchange secondary to three episodes of posterior instability. Since the last revision, the patient did not experience any further episode of instability.

Given the circumstances, it was decided to perform a closed reduction of the left THA under general anesthesia using the Bigelow maneuver (traction in line followed

Figure 3

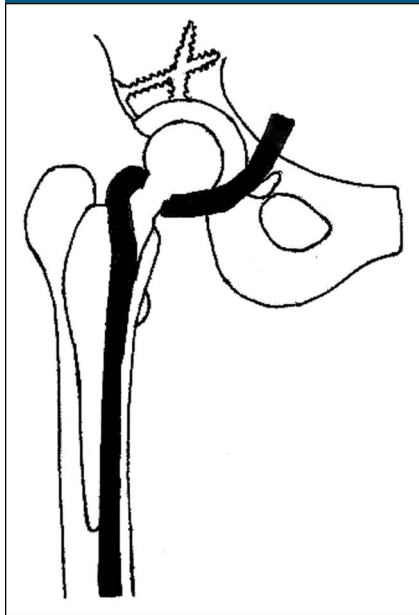


Diagram showing a sciatic nerve entrapment around a total hip arthroplasty (posterior view).

by abduction and external rotation). Postreduction stability was tested immediately after the reduction and the hip redislocated at 90° of flexion and 45° of internal rotation. A second closed reduction was performed. According to the surgeon, the second closed reduction was much more difficult than the previous one. Nonetheless, immediate operating room control radiograph showed a reduced left THA (Figure 2).

As soon as the patient was awake, she reported of severe radiating left lower limb pain with plantar flexion of the foot. Neurologic examination confirmed a complete sciatic nerve palsy. One hour after the second closed reduction, we performed an iatrogenic dislocation of the left THA under light sedation and obtained a relief of the pain, but no improvement of the neurologic symptoms.

Prof. Guyen or an immediate family member has received IP royalties from Dediene company and Amplitude company. None of the following authors or any immediate family member has received anything of value from or has stock or stock options held in a commercial company or institution related directly or indirectly to the subject of this article: Dr. Maeder, Dr. Goetti, Dr. Mahloulou, Dr. Mustaki, and Dr. Buchegger.

A CT was not sensitive enough to rule out a sciatic nerve lesion due to the radiologic artifacts. Sciatic nerve entrapment was highly suspected based on the symptoms. Open exploration was performed. The surgery was performed through a posterior approach. The sciatic nerve was identified enrolled around the neck of the femoral stem (Figures 3 and 4). The sciatic nerve was swollen along 3 cm, without discoloration or crushing. A neurolysis was performed along the path of the nerve up to the quadratus femoris muscle and the external rotators muscles of the hip. The nerve was then unrolled over the femoral neck and gently put back in an anatomical position (Figure 5).

After the neurolysis, open reduction of the left dislocated THA was performed. Postoperative radiograph done on the day of surgery showed a suitable reduction of the left THA.

The postoperative course was characterized by the persistence of a foot drop. She was discharged from our unit 10 days after the surgery. A partially recovering foot drop was present 6 months after the surgery. She was walking using a foot drop splint and one cane. Radiograph showed no sign of complication.

Discussion

This lavishly illustrated case highlights the importance of meticulous neurovascular assessment after closed reduction of a dislocated THA, which also questions the relevance of post-reduction stability testing of the hip after closed reduction of THA dislocation. This testing procedure seems to have a low impact on the modalities of treatment and does not come without any complication as dramatically shown in this case.

To our knowledge, there are six cases of sciatic nerve entrapment after closed reduction of dislocated THA

reported in the literature.^{2,8-12} Dislocation after revision THA seems to be at higher risk of sciatic nerve entrapment. The higher rate of dislocation and the presence of scar tissues are two reasons to explain this higher risk. In our case, the entrapment was responsible for a permanent deficit to the sciatic nerve by traction and compression.¹³

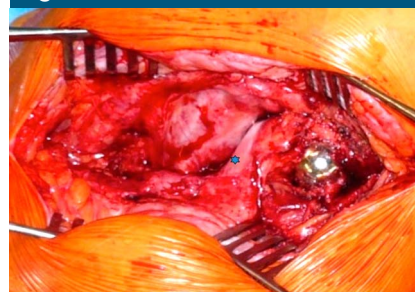
Nerve compression by a hematoma is part of the differential diagnosis and advocates early exploration and drainage.^{12,14} CT could show such a lesion. Hemostasis disruption could orientate the diagnosis, and coagulation analysis is required.

We assume that the manoeuvre of stability testing after the first closed reduction has probably led to the sciatic nerve entrapment. This complication could have been avoided with adequate sedation and complete muscular relaxation. Abstaining from stability testing would also have probably averted the nerve damage. Stability testing after closed reduction should be done with restriction because accurate measurement of the articular range-of-motion to the limit of stability has low impact on the modalities of treatment. Repeated attempts to reduce a THA dislocation come with an increased risk of complications.

Difficulty in reduction of a dislocated THA could indicate a sciatic nerve impingement. If suspected, performing an open reduction should be recommended. In case of difficult reduction or previously revised THA, the use of live low-dose fluoroscopy might reduce the risk of dislocation or could show soft-tissue impingement.

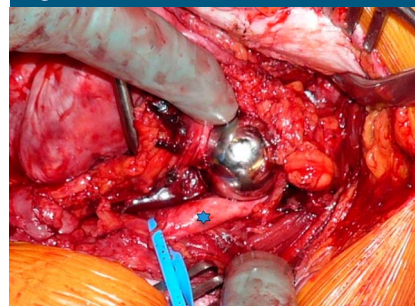
Studies showed that at the time of the THA procedure, intraoperative stability tests were effective and suggested that reaching 50° of internal rotation with a flexed hip should assure a stable hip.¹⁵ As it is an intraoperative procedure, it offers a direct view of the femoral neck in the event of a sciatic nerve entrapment.

Figure 4



Photograph showing entrapment of the sciatic nerve around the left total hip arthroplasty neck (sciatic nerve marked by asterisk).

Figure 5



Photograph showing physiologic position of the sciatic nerve after open exploration and repositioning of the nerve (sciatic nerve marked by asterisk).

In the presence of clinical signs, suggesting a sciatic nerve lesion after a closed reduction of THA dislocation, we do recommend prompt open exploration and reduction. This risk of open conversion should be explained to each patient in the pre-operative consent.

Our institution guidelines were modified after this case because we now avoid stability testing after reduction of THA dislocation. This testing procedure comes with substantial risk and has a low impact on the modalities of treatment.

References

1. Alberton GM, High WA, Morrey BF: Dislocation after revision total hip

- arthroplasty: An analysis of risk factors and treatment options. *J Bone Joint Surg Am* 2002;84-A:1788-1792.
2. Chan JH, Ballal MS, Dheerendra S, et al: Entrapment of the sciatic nerve following closed reduction of a dislocated revision total hip replacement. *J Bone Joint Surg Br* 2011;93-B:274-276.
 3. Woo RY, Morrey BF: Dislocations after total hip arthroplasty. *J Bone Joint Surg Am* 1982;64-A:1295-1306.
 4. Varenika V, Lutz AM, Beaulieu CF, Bucknor MD: Detection and prevalence of variant sciatic nerve anatomy in relation to the piriformis muscle on MRI. *Skeletal Radiol* 2017;46:751-757.
 5. DeHart MM, Riley LH Jr: Nerve injuries in total hip arthroplasty. *J Am Acad Orthop Surg* 1999;7:101-111.
 6. Weber ER, Daube JR, Coventry MB: Peripheral neuropathies associated with total hip arthroplasty. *J Bone Joint Surg Am* 1976;58-A:66-69.
 7. Wilson JN, Scales JT: The Stanmore metal on metal total hip prosthesis using a three pin type cup: A follow-up of 100 arthroplasties over nine years. *Clin Orthop Relat Res* 1973;95:239-249.
 8. Haque S, Sundararajan S: Entwinement of sciatic nerve around a total hip prosthesis following closed reduction of dislocated total hip replacement. *Pol Orthop Traumatol* 2013;78: 273-275.
 9. Lazansky MG: Complications revisited: The debit side of total hip replacement. *Clin Orthop Relat Res* 1973;95:96-103.
 10. Leversedge FJ, Gelberman RH, Clohisy JC: Entrapment of the sciatic nerve by the femoral neck following closed reduction of a hip prosthesis: A case report. *J Bone Joint Surg Am* 2002;84-A: 1210-123.
 11. Ng J, Marson BA, Broodryk A: Foot drop following closed reduction of a total hip replacement. *BMJ Case Rep* 2016;2016: bcr2016215010.
 12. Stockley I, Bickerstaff D: Sciatic nerve palsy following reduction of a dislocated prosthesis: Brief report. *J Bone Joint Surg Br* 1988;70-B:329-330.
 13. Lundborg G, Rydevik B: Effects of stretching the tibial nerve of the rabbit: A preliminary study of the intraneural circulation and the barrier function of the perineurium. *J Bone Joint Surg Br* 1973;55-B:380-401.
 14. Fleming RE Jr, Michelson CB, Stinchfield FE: Sciatic paralysis: A complication of bleeding following hip surgery. *J Bone Joint Surg Am* 1979;61-A:37-39.
 15. Tanino H, Sato T, Nishida Y, Ito H: Intraoperative stability test of total hip arthroplasty. ORS 2014 Annual meeting. Poster No 1808, New Orleans, Louisiana.