

2019

# Sensitivity of single organ versus multiorgan point-of-care ultrasound compared to computed tomography pulmonary angiography in detecting pulmonary embolism in adult patients

Jessica Stangenes  
*Augsburg University*

Follow this and additional works at: <https://idun.augsburg.edu/etd>



Part of the [Pulmonology Commons](#)

---

## Recommended Citation

Stangenes, Jessica, "Sensitivity of single organ versus multiorgan point-of-care ultrasound compared to computed tomography pulmonary angiography in detecting pulmonary embolism in adult patients" (2019). *Theses and Graduate Projects*. 940.  
<https://idun.augsburg.edu/etd/940>

This Open Access Thesis is brought to you for free and open access by Idun. It has been accepted for inclusion in Theses and Graduate Projects by an authorized administrator of Idun. For more information, please contact [bloomber@augburg.edu](mailto:bloomber@augburg.edu).

Sensitivity of single organ versus multiorgan point-of-care ultrasound compared to computed tomography pulmonary angiography in detecting pulmonary embolism in adult patients

By

Jessica Stangenes, PA-S

Eric Barth, PA-C

Paper Submitted in Partial Fulfillment

Of the Requirements for the Degree

Of Master of Science

Physician Assistant Studies

Augsburg University

August 9, 2019

**Table of Contents**

Abstract	Page 3
Introduction	Page 4
Background	
Challenges in Diagnostic Management of PE	Page 6
What is POCUS?	Page 11
POCUS in Cardiopulmonary Pathology	Page 12
Literature Review: Sensitivity of POCUS compared to CTPA for PE detection	
Single organ POCUS	Page 15
Multiorgan POCUS	Page 23
Methods	Page 28
Discussion	Page 28
Conclusion	Page 36
References	Page 40
Appendices	Page 46

**Abstract**

*Background:* Pulmonary embolism (PE) is a serious and potentially life-threatening complication of venous thromboembolism and its diagnosis remains a challenge. The current gold standard to confirm diagnosis of PE is multi-row computed tomography pulmonary angiography (CTPA) but has limitations and alternative imaging modalities are being investigated. Point-of-care ultrasound (POCUS) has been applied in the diagnostic process in PE but whether it can safely replace the gold standard is of question.

*Methods:* A literature review was conducted to evaluate the sensitivity of single versus multiorgan point-of-care ultrasound (POCUS) compared to CTPA in detecting PE in adult patients.

*Discussion:* Several prospective observational studies exist investigating the use of single and multiorgan POCUS but are inconsistent in the selection of subjects, diagnostic reference tests used for comparison, criteria for PE diagnosis on POCUS and combinations of multiorgan POCUS used. A limited number of studies exist for each of the combinations of multiorgan POCUS investigated.

*Conclusion:* Both single organ and multiorgan POCUS have shown inferior sensitivity to CTPA and cannot replace this diagnostic gold standard for PE. Triple multiorgan POCUS (lung, cardiac and vascular) has shown the most promise thus far (sensitivity of 90%, specificity of 86%) and is recommended for patients that cannot receive CTPA and an adjunct to help provide alternative cardiopulmonary diagnoses, potentially reducing unnecessary radiographic imaging and may help to improve the prediction rules in stratifying risk for patients clinical suspicion of PE. More consistent research is needed to clarify the role and validity of POCUS in PE.

## INTRODUCTION

Pulmonary embolism (PE) is the most serious and potentially life-threatening complication of venous thromboembolism (VTE). Pulmonary embolism requires prompt diagnosis and treatment to prevent fatal sequelae. It is estimated that PE causes more than 50,000 deaths annually, has been reported to be the third leading cause of death in hospitalized patients and the second most common cause of unexpected death in outpatients.<sup>1,2</sup> In patients with fatal emboli, less than ten percent received appropriate treatment as the PE went undiagnosed antemortem. When early diagnosis of PE is achieved, and anticoagulation therapy is initiated immediately, it is highly effective with generally a favorable outcome; however, overall prognosis can be variable depending on existing underlying conditions.<sup>1,3</sup>

Pulmonary embolism may be lethal due to its various cardiopulmonary effects. Obstruction of the pulmonary circulation can lead to infarction and hypoxemia due to necrosis of lung parenchyma, atelectasis from surfactant depletion, decreased cardiac output, increased dead space; bronchoconstriction may lead to wheezing and increased work of breathing.<sup>1,2</sup> Additionally, massive thrombus may cause hemodynamic instability and right ventricular failure.<sup>1</sup>

The most common cause of PE is VTE that originate in the deep veins of the lower extremities and migrate to the pulmonary circulation. The signs and symptoms of PE can vary depending on the size and location of the clot. In patients with proximal deep vein thrombosis (DVT), approximately 50% will subsequently developed PE with most of these embolic events being asymptomatic; alternatively, in those with symptomatic PE, up to 70% also had DVT upon evaluation.<sup>1</sup> Since both PE and DVT result from the same disease process, they are often evaluated in tandem and share the same risk factors.

Given the pathophysiology of VTE (including both DVT and PE), the signs and symptoms of PE can be variable in presentation and severity which contribute to the difficulty in making a timely and accurate diagnosis. According to the Prospective Investigation of Pulmonary Embolism Diagnosis (PIOPED) study, patients with diagnosed PE most commonly reported signs and symptoms of dyspnea, pleuritic chest pain or tachypnea; however, other findings may include cough, leg pain and/or a positive Homan's sign, hemoptysis, palpitations, wheezing, angina, tachycardia, temperature, rales, third or fourth heart sound, accentuated S2 heart sound, pleural friction rub and cyanosis.<sup>1</sup> The variation in clinical presentation of PE remains a main factor in missed PE diagnosis and requires clinicians to maintain a high index of suspicion for PE to ensure that it remains in their broad cardiopulmonary differential and work up.<sup>1,3,4</sup>

Another factor complicating evaluation of PE is that it cannot rely on one diagnostic test. Current guidelines recommend a strategy that includes a combination of clinical assessment as well as laboratory and imaging studies for diagnosis. A definitive diagnosis of PE requires imaging, but the use of clinical probability assessment tools combined with a D-dimer blood test help to determine if imaging should be pursued.<sup>2,3,5</sup> Currently, the reference imaging test to initially diagnosis PE is computed tomography pulmonary angiography (CTPA) which has demonstrated a sensitivity of 96-100% and a specificity of 97-98%.<sup>3-6</sup> However, despite the increased use and availability of CTPA, the mortality of PE has not significantly improved.<sup>2,5</sup> Furthermore, CTPA has limitations and cannot be used in every patient case.<sup>5,6</sup> Given the drawbacks to CTPA, alternative diagnostic strategies for PE have been explored.

The use of bedside or point-of-care ultrasound (POCUS) to aid in diagnosis of PE has been described as early as the mid-1960s.<sup>7</sup> In these early, small studies, the use of lung

ultrasound at the bedside may have accurately diagnosed PE lesions in greater than 90% of cases.<sup>4,7</sup> A similar study repeated around 1990 validated these results also reporting a diagnostic accuracy of 90%.<sup>8</sup> However, the routine use of POCUS was likely not employed at the time due to the lack of large, prospective trials. With more recent improvements in ultrasound technology over the last approximately 20 years, ultrasound has been increasingly used by practitioners, other than radiologists and certified sonographers, in various diagnostic and procedural aspects of patient care. Clinical locations in which POCUS has been more commonly utilized are those that rely on succinct and timely diagnosis of acute presentations – such as the emergency department, acute care units and the perioperative setting.<sup>9</sup>

Given the complexity and time sensitivity factors in diagnosing PE as well as the emergence in use and availability of POCUS, it is logical to question if the sensitivity of POCUS now could rival that of CTPA to help assist in early detection of PE in adult patients presenting with clinical suspicion of the disease. In order to explore this question, the initial objectives will be to review the current recommendations and limitations for diagnostic management of PE, what POCUS is as well as how it is currently is utilized to evaluate acute pulmonary pathology. Secondly, a review of the current literature on how POCUS compares to CTPA for diagnostic accuracy will be explored.

## **BACKGROUND**

### ***Challenges in Diagnostic Management of PE***

Given the complexity in diagnosing PE but need for efficient and systematic evaluation, algorithms have been developed to help standardize the work up for this disease (see Figure 1 for an example of such an algorithm). The initial evaluation in proposed algorithms often begin with a clinical assessment to help determine the probability of PE and decrease the amount of

unnecessary and imaging. As previously discussed, signs and symptoms alone can be non-specific to PE; however, when combined with other risk factors or symptoms or included in prediction rules, the risk stratification for true PE incidence can be better estimated. The most widely used prediction rules are the Wells and Geneva rules (see Table 1). Meta-analyses have validated the use of both tools as well as reported their diagnostic performance to be comparable.<sup>10</sup> Some criticism has been made that items for these scoring systems may be subjective rather than objective (e.g., “alternative diagnosis less likely than PE” or “clinical signs of DVT” criteria in Wells score) leading to increased additional and unnecessary diagnostic testing.<sup>11</sup>

If a patient is determined to have an increased probability based on initial clinical assessment, the next test in diagnostic PE algorithms is usually to obtain a D-dimer blood test. Plasma D-dimer is a product of the degradation of cross-linked fibrin by plasmin and typically increases in the presence of thrombus.<sup>1,3,10</sup> The D-dimer test is used as a test of exclusion given it has high sensitivity but cannot be used solely for diagnostic purposes with a lower specificity. One of the most commonly used D-dimer tests is the rapid quantitative enzyme-linked immunosorbent assay (ELISA). D-dimer ELISA levels of 300-500 mcg/L have shown to have a sensitivity of 95% with a specificity of 40-45%.<sup>1,3,10</sup> Given D-dimer results do not have 100% sensitivity and low specificity, their use should be reserved for those patients with non-high probability risk to rule out PE.

The lower specificity of D-dimer in relation to PE diagnosis can be attributed to its elevated presence in other conditions such as cancer, inflammation, infection, chronic kidney failure, pregnancy, trauma, postoperatively, previous VTE, and advancing age. Given the number of elderly patients that may experience VTE, an alternative age-adjusted D-dimer cutoff calculation was developed for patients over the age of 50 (multiply the age of a patient by 10)



while the recommendation is to continue to use the limit of 500 mcg/L for patients younger than 50 years. The age-adjusted D-dimer cutoff has been shown to have a five-fold increase over the conventional cutoff ranges and is now part of the American College of Physicians Best Practice Advice to include in the evaluation of patients with suspected PE. Currently, no other proposed and validated adjusted cutoff values exist for other conditions that affect D-dimer levels in patients prone to VTE (e.g., pregnancy). The use of D-dimer should *only* be used in conjunction with an unlikely or low clinical probability assessment; if used in these cases and a positive result occurs, the clinician should be prepared to pursue appropriate diagnostic imaging. The use of D-dimer is redundant in those with high probability assessment of PE.<sup>3,10</sup>

Historically, the gold standard for confirmation of PE after a positive D-dimer result or high clinical suspicion was to then obtain imaging with pulmonary angiography (PA). This method is invasive as it requires right heart catheterization and contrast injection and is usually less available given it requires expertise to complete.<sup>3</sup> Alternatively, a diagnostic test that has been historically used in the evaluation of PE is ventilation-perfusion lung scintigraphy (commonly referred to as a V/Q scan). A V/Q scan indirectly diagnoses a PE by identifying areas where there is a mismatch in the perfusion and ventilation of lung tissue.<sup>10</sup> However, in clinical trials, a drawback to V/Q scans is that it has been shown to have high number of inconclusive results when compared to other more recent diagnostic imaging modalities such as CTPA.<sup>3,10,12</sup>

The additional use of venous ultrasonography, also referred to as compression ultrasound (CUS), is yet another first-line test employed in the evaluation of PE. Given the previously described association between DVT and PE, the presence of lower extremity DVT must be evaluated when PE is suspected. Proximal lower extremity DVTs more often are associated

with PE and the inability to compress the common femoral veins, popliteal veins or both is diagnostic for a first episode of proximal DVT. This test has been reported to have a sensitivity of 94% and specificity of 98% for proximal DVT evaluation but is less accurate in distal, recurrent or asymptomatic thrombi.<sup>1,3</sup> A positive lower extremity CUS test supports making a diagnosis of PE without pursuing further imaging, and initiating early anticoagulation therapy.<sup>10</sup> However, not all patients with PE have DVT and this test cannot be used to exclude a diagnosis of PE.

With the development and availability of CTPA around the 1990s, this modality has replaced PA and V/Q scanning and become the initial gold standard test to diagnose PE.<sup>3,10</sup> The modality of CTPA requires injection of iodinated contrast medium in order to produce direct visualization of pulmonary arteries. As CTPA technology has evolved from a single to multi-detector row technique, so has its diagnostic accuracy with multi-row imaging (at least four-row) now demonstrating a sensitivity of 96-100% and specificity of 97-98%.<sup>2,3</sup> The use of multi-detector row CTPA as a single imaging test to safely diagnose or rule out PE has been established by multiple prospective outcome studies.<sup>3,10</sup> Furthermore, in those cases in which CTPA can rule out PE, this imaging modality has been shown to have the added benefit of providing an alternative diagnose for the underly cause of symptoms.<sup>1,3</sup>

Several limitations for the use of CTPA exist. Although this imaging modality has been shown to have both high sensitivity and specificity, there is still potential for false-negative results in those patients evaluated to have high clinical probability.<sup>3</sup> It has also been reported that CTPA is the most sensitive for detecting proximal (central) PE but may be less sensitive for detecting peripheral (distal) PE.<sup>3</sup> Furthermore, CTPA is contraindicated for those patients who have significantly impaired renal function or are pregnant.<sup>3,12</sup> In patients with mild to moderate

allergy to contrast media, CTPA is relatively contraindicated but may still be pursued if patients are pre-medicated with a regimen of corticosteroids with or without histamines.<sup>13</sup> Another disadvantage of CTPA is the radiation exposure which has been reported to range from three to five millisieverts (mSv), equating to an estimated risk of 450-750 excess cancer deaths per million exposed to a single CTPA for suspected PE.<sup>3</sup> This imaging modality also requires the patient to be stable enough to be transported to the radiology department and requires specialized staff to perform which may not always be available at all institutions.<sup>3</sup>

With the increased utilization of CTPA, an increase in PE diagnosis has been observed but without a corresponding decrease to mortality.<sup>2,5,6</sup> Furthermore, the number of patients receiving CTPA with negative results has significantly increased indicating that a number of patients are put at increased risk receiving unnecessarily increased radiation exposure and subject to side effects of contrast media.<sup>6</sup> One theory to explain this observation is that with the availability of CTPA, there may be a lower threshold to pursue diagnostic imaging resulting in identification and initiation of anticoagulation therapy for more small, subsegmental (distal) PE that maybe would not have been fatal to begin with. Controversy exists if the benefit outweighs the risk in pursuing treatment of these small emboli as currently there is limited literature investigating this issue. Currently, a prospective, observational cohort study is underway to help answer the question of if it is safe to withhold treatment in those patients with subsegmental PE and negative bilateral lower extremity CUS (NCT01455818).<sup>10,14</sup>

With all testing options available in the evaluation for PE, CTPA currently remains the preferred initial imaging modality for confirmation of this disease. In those patients with negative or indeterminate CTPA results but high clinical suspicion of PE, controversy exists as to whether patients should be further evaluated by CUS, V/Q scans and/or PA.<sup>10</sup> However, these

tests still have a role for patients with suspected PE and in which CTPA may be unavailable or contraindicated.

Despite the currently available diagnostic tests and protocols that exist for the evaluation of PE, this complex condition continues to be underdiagnosed and have a high mortality rate. Given the above described challenges in evaluating PE, other imaging modalities have been explored to help improve the sensitivity, efficiency and inclusivity in the diagnostic approach to PE.

### ***What is POCUS?***

Point-of-care ultrasound refers to the use of portable ultrasonography at the bedside by non-radiology physicians and advanced practice providers for the care of acute and critically ill patients. The most common application of POCUS has been in the emergency department (ED) and in intensive care units (ICUs) where efficient evaluation is crucial to help determine possible pathology and a strategy for management and intervention.<sup>15</sup>

Point-of-care ultrasound differs from the conventional, consultative ultrasonography evaluation in several ways. First, the examination is performed by the managing clinician rather than skilled technicians completing the ultrasound exam with consulting radiologists or cardiologists interpreting the results. This clinician is responsible for all interpretation as well as integration of the images obtained into the management of the patient. This oftentimes is of benefit as information obtained can immediately be used to help narrow a differential diagnosis and direct patient care.<sup>9,15</sup> Second, the POCUS examination is not comprehensive and usually is used to answer a specific question about a condition or help assist with procedural goals. Although POCUS can be a useful exam itself, it is crucial for the safety of patients that clinicians recognize when POCUS does not provide definitive evidence and standard imaging or

consultative ultrasound examination is required to ensure accurate diagnosis in complex or critical cases.<sup>15</sup> The location and timing in which these two evaluations may also differ. Often consultative ultrasonography is postponed until a patient is hemodynamically stable and may be done at the bedside or require the patient to be transported to the echocardiology and/or radiology department; whereas POCUS has the advantage of always being performed at the bedside and, therefore, the stability of the patient does not preclude completion of the examination.<sup>9,15</sup>

The use of POCUS has been gaining increased acceptance as a supplement to the physical examination of a patient. The American Academy of Family Physicians has published a document for recommended curriculum guidelines for POCUS and states that when POCUS is utilized with the physical exam it, "...offers additional anatomic, functional, and physiologic information to guide patient care."<sup>16</sup> In 2012, the Accreditation Council for Graduate Medical Education (ACGM) selected POCUS as one of its required competencies to the curriculum for emergency medicine residents.<sup>16</sup> Many medical institutions have also already incorporated POCUS training into their curriculum as an adjunct to the physical exam. Given this imaging modality is being increasingly used by clinicians, several national and international organizations now offer training and certifications programs for various types of POCUS for those that have not yet had POCUS education included in their curriculum. Aside from emergency medicine, standards are still being developed for other areas of practice.<sup>9</sup>

### ***POCUS in Cardiopulmonary Pathology***

The use of POCUS has wide-ranging applications. Multiple terms have been proposed for various more specific types of POCUS and this paper will focus on those described specifically for cardiopulmonary use. Terms and abbreviations for variations of single organ

POCUS that have been proposed include: lung ultrasonography (LUS), thoracic or transthoracic ultrasonography (TUS; including include lung, pleura and/or heart), vascular (CUS), cardiac (including echocardiography) and multiorgan ultrasound (which includes ultrasound in two or more of the aforementioned locations).<sup>15</sup> In addition to the previously described use of CUS for vascular POCUS, various protocols have been developed to help standardize the use of bedside ultrasound in other cardiopulmonary areas to guide clinicians for observed signs to hone in on pathology. Examples of proposed algorithms include the bedside lung ultrasound in emergency (BLUE) protocol and the focused cardiac ultrasound (FOCUS).<sup>15,16</sup>

Thoracic and LUS are currently utilized by clinicians to help differentiate common causes of acute cardiopulmonary compromise such as pneumonia, pulmonary edema, pleural effusion, and pneumothorax in critically ill patients.<sup>15</sup> The diagnosis of PE has also been included in this list in some studies given the overlap of presenting symptoms and inclusion in the differential diagnosis for these conditions. The use of TUS has been reported to be similar or superior to chest radiography in detecting pneumothorax, pneumonia and consolidation in pulmonary effusion.<sup>15</sup> The BLUE protocol, for example, contains an algorithm that helps guide clinicians in determining the etiology of acute respiratory failure through examination of anterior, lateral and posterolateral points on the thorax bilaterally as well as the addition of CUS (multiorgan POCUS).<sup>17</sup> When this protocol is used, POCUS provided a correct diagnosis for the underlying etiology of respiratory failure in 90.5% of cases – including in 21 cases of PE.<sup>17,18,19</sup>

Ultrasound has potential for improving the diagnostic evaluation of PE given when vascular occlusion occurs, the resulting atelectasis with extravasation of blood or infarction of lung tissue results in consolidation in peripheral lung parenchyma and can be visible on lung

ultrasound.<sup>2</sup> Ultrasound characteristics that are associated with some cardiopulmonary causes of respiratory compromise are summarized in Table 2.<sup>15,17,20</sup>

The use of the BLUE protocol has been shown to significantly reduce the time from admission to diagnosis to initiation of treatment for the underlying cause of respiratory distress in the ED.<sup>18</sup> Therefore, this illustrates that POCUS is already being applied to help narrow down the differential diagnosis for presentations of respiratory compromise and in some cases may be of use to help gather information that may help find alternative etiology to rule out PE versus lead to an expedited diagnosis.

Pulmonary embolism can also have cardiac manifestations that lend to detection on cardiac ultrasound. Historically, the presence (or absence) of right ventricular (RV) strain has been viewed on transthoracic echocardiography (TTE) and can help differentiate the severity of PE (i.e., massive versus lower risk) and predict mortality.<sup>18</sup> However, cardiologists typically perform TTE and therefore this examination may not be available or have delays when needed.<sup>17</sup> The FOCUS protocol has been proposed to help standardize the characteristics of RV strain on ultrasound and may include the following: the measurement of tricuspid annular plane systolic excursion (TAPSE; measurement  $<17$  mm), RV enlargement with comparison to left ventricle (LV) size (RV to LV ratio  $\geq 1$ ); or presence of septal flattening, tricuspid regurgitation (on color Doppler), or McConnell's sign (RV hypokinesis with apical sparing).<sup>21,22,23</sup> In a retrospective chart review study by Taylor et al in 2013, the authors evaluated the ability of ED providers to utilize a point-of-care FOCUS exam in patients with suspected PE. Of the 161 patients with confirmed diagnosis of PE by either CT (n=127), V/Q study (n=19) or clinically if evidence of DVT found on CUS (n=6) that received a FOCUS exam, RV strain found by ED providers was the, "single most important prognostic factor found to predict adverse outcomes."<sup>21</sup> This study,

although did not compare the sensitivity of FOCUS in diagnosing PE, demonstrates that the use of cardiac POCUS likely has a role in the urgent evaluation of PE where consultant cardiology ultrasound is not readily available.

***Literature Review: Sensitivity of POCUS compared to CTPA for PE detection***

In order to understand the role POCUS may play in the evaluation of PE, a comparison to the currently accepted gold standard diagnostic test of CTPA must be explored. Given that POCUS has been used in both single (TUS, LUS, cardiac ultrasound/echocardiography and vascular) and multiorgan ultrasound applications, literature pertaining to each will be evaluated with a focus on TUS/LUS and cardiac single organ ultrasound as CUS has been previously well studied and accepted in the use for DVT evaluation.<sup>10</sup>

*Single organ POCUS: thoracic and lung*

Thoracic ultrasound encompasses imaging of both the lung and pleura and often the name is used interchangeably with LUS or chest ultrasound when described in the literature. One of the earlier, small studies conducted to evaluate TUS was done by Mathis et al in 1993 who sought to investigate results observed by the previously reported early studies from the 1960s.<sup>7,8</sup> In this study, 58 patients who presented with symptoms concerning for PE were consecutively enrolled and received an initial “chest ultrasonography” examination. The diagnosis of PE was verified using ventilation-perfusion lung scanning and PA and reported ultrasound to have a sensitivity of 98%, a specificity of 60% and an overall accuracy of 90% in PE diagnosis.<sup>8</sup> Although this study used a diagnostic method different from this paper’s research question, it is worth mention for comparison, as this group of investigators went on to later do a larger, similar study using CTPA (to be discussed later in this paper). Given the use of CTPA was not routinely



available and used in studies until the twenty-first century, the research in this paper will focus on those studies published after the year 2000.

The predominance of studies that exist for the use of single organ TUS/LUS in the evaluation of PE include small, prospective, observational studies (see Table 3 for a summary of studies reviewed). Four studies exist earlier in the twenty-first century comparing TUS to single-row CTPA.<sup>4,24,25,26</sup> Reissig et al began comparing CTPA to TUS in two separate, small observational studies that yielded similar results in 2001 and 2004.<sup>4,24</sup> In 2001, 69 patients with symptoms suspicious for PE were consecutively enrolled compared to 62 patients in the 2004 study. In both studies, single-row CTPA was used as the reference diagnostic test but was only able to confirmed the diagnosis of PE in 46-50% of the suspected PE cases alone; the remaining patients required additional testing for diagnosis confirmation (e.g., V/Q scan, CUS, echocardiography or D-dimer).<sup>4,24</sup> The overall incidence of PE in the two studies was 64% in 2001 and 63% in 2004. It was disclosed in the 2001 study that only 62 of the 69 subjects received CTPA exams for evaluation of PE and noted that the modality was “unavailable” for unspecified reasons.<sup>4</sup> It was also noted in this study that an additional 138 patients had suspected PE during the study period, but these patients were not included in the study as TUS was “unable to be performed” (again, reasons for inability to complete ultrasound in these patients was not specified).<sup>4</sup> This method of subject selection in the 2001 Reissig et al study may lend to inaccurate representation and bias of the patient population included. Additionally in this study, of those patients with a “correct positive” diagnosis of PE on TUS (n=35), only 32 of them received CTPA exam for comparison with the other patients still having a diagnosis consistent with the alternative criteria.<sup>4</sup> While this makes comparison of TUS to the standard diagnostic

imaging for PE difficult, it may support that when contrast-enhanced imaging is unavailable, the use of TUS may be helpful in evaluating PE.

When TUS was compared to all patients with confirmed PE diagnoses in the Reissig et al 2001 study, the detection of was similar to the 2004 study with a reported sensitivity of 80% and 77%, respectively, and a specificity of 92% and 91%, respectively.<sup>4,24</sup> It should be noted that historically the sensitivity of single-row CTPA alone in other studies has been reported to be only 76% in the diagnosis of PE.<sup>3</sup> While the sensitivity observed in these two studies by Reissig et al are comparable or exceed previously reported sensitivity for single-row CTPA, it remains inferior to more recent advancements in multidetector CTPA.

An additional small pilot study was conducted by Mohn et al in 2003 with the goal to investigate the diagnostic performance of TUS in those patients presenting with suspicion of PE.<sup>25</sup> This study a similar validation strategy as Reissig et al with consecutively enrolling patients and comparing the results of TUS to diagnostic references tests performed by clinicians blinded to each other's exam. Diagnostic criteria for PE included: CTPA with evidence of filling defects or occlusion of pulmonary arteries outlined by contrast media (however, details of the type of CT were not specified in the study to compare to the above two studies), high clinical probability and V/Q scan, DVT on CUS and abnormal lung scan or PA.<sup>25</sup> A total of 74 patients were enrolled with 31 patients (42%) confirmed to have a diagnosis of PE based on the various reference tests<sup>25</sup>. Of those enrolled, CTPA was performed in 52 patients and confirmed the diagnosis of PE in only 15 subjects for comparison to TUS.<sup>25</sup> Therefore, in the 22 patients reported to have a had a PE positive TUS result, only 68% of them were confirmed by CTPA in this study. Overall, when TUS was compared to *all* reference diagnostic tests, the sensitivity was

reported to 71% and a specificity of 77%.<sup>25</sup> It was concluded by the authors that TUS alone was not an accurate overall test to confirm nor exclude the diagnosis of PE.<sup>25</sup>

One of the largest studies available to evaluate single organ TUS use in PE evaluation was subsequently conducted by Mathis et al in 2005.<sup>26</sup> In their prospective, multicenter study of TUS in the evaluation of PE, they also used single-row CTPA as their reference test of choice to initially confirm diagnosis of PE. Similar to Reissig et al, if imaging results were negative or inconclusive, they alternatively used clinical algorithms for diagnosis and comparison to TUS.<sup>4,24,26</sup> The TUS exam in this study was differentiated into four categories based on the number of lesions and/or signs of pleural effusion detected: PE- confirmed, PE-probable, PE-possible and normal. A total of 352 patients were included in the analysis of this study with 194 (55%) diagnosed with PE; of these, 169 patients (87%) were diagnosed with PE using CTPA. When TUS categories were compared to CTPA, the PE-confirmed and PE-probable groups had a combined sensitivity of 74% and specificity of 95% and an overall accuracy of 84%. It was also reported that TUS detected significantly more lesions while demonstrating a congruence with the size and location of those lesions found on CTPA. The authors speculated that TUS may have the capability to detect a larger number of smaller lesions compared to CTPA.<sup>26</sup> However, this may or may not be an advantage to TUS over CTPA when considering the controversy surrounding if all lesions require anticoagulation therapy.

As imaging technology advanced to include multi-row CTPA, additional studies were performed to compare the performance of TUS to this evolving reference test. Four subsequent studies were published between 2010 and 2018 comparing TUS in a similar research design to the above four earlier studies, but this time utilized multi-row detector CTPA in all patients with suspected PE.<sup>27-30</sup> In 2010, Pfeil et al found that in 33 patients presenting with symptoms of PE

and received both multi-row CTPA and TUS, 10 patients were diagnosed with PE by CTPA but only 7 patients had both positive TUS and CTPA, reporting a sensitivity of TUS to for detecting PE to be only 70% with a specificity of also 70%.<sup>27</sup> This study reported the lowest sensitivity of all single organ TUS studies reviewed for this paper but likely can be attributed to the fact that a more sensitive reference test was used in this study compared to earlier studies and/or the very small sample size. Comert et al conducted a similar study in 2013 with a somewhat larger sample size (n=50); of which 60% were diagnosed with PE by multi-row CTPA and 27 patients had a true positive TUS (54%).<sup>28</sup> However, this group did sub-analysis dividing subjects into subgroups based on the quality of TUS findings. They reported a sensitivity of 43% and specificity of 75% for those patients who had two or more characteristic lesions (wedge, triangular or rounded) with or without pleural effusion, sensitivity of 70% and specificity of 65% for those patients with the one characteristic lesions plus pleural effusion and a sensitivity of 90% and specificity of 60% when the two groups were combined.<sup>28</sup> Furthermore, in a prospective observational study in 2017 by Acar et al enrolling 100 patients, 38 patients received multi-row CTPA confirming diagnosis of PE.<sup>29</sup> Of the patients that had positive signs for PE (three or more B-lines in one area, one or more signs of wedge lesions or pleural effusion), it was those with the characteristic wedge sign alone for detection of PE on ultrasound showed the highest sensitivity of 42% with a specificity of 98% (data for groups combined were not analyzed).<sup>29</sup> These two studies illustrates that the criteria for obtaining a positive TUS/LUS for diagnosing PE likely needs standardization for the characteristics found on ultrasound to help optimize the sensitivity of the test when used. Furthermore, it illustrates that TUS has lower specificity and a negative examine alone cannot be used to rule out the diagnosis of PE.

Lastly, the most recent study conducted by Ghanem et al in 2018 investigated the use of TUS compared to multi-row CTPA in diagnosing PE but also additionally looked at how gray-scale TUS compared to doppler ultrasound.<sup>30</sup> The criteria for a positive TUS finding used was similar to Comert et al and Pfeil et al.<sup>29,30</sup> A total of 60 patients with suspected PE received TUS and CTPA; of those, 40 patients were confirmed to have a diagnosis of PE with multi-row CTPA and 33 patients had evidence of PE on grey-scale TUS yielding a sensitivity of 82% with a specificity of 90%. Additionally, it was noted that the addition of color doppler only increased the specificity to 95% while decreasing the sensitivity to 80%.<sup>30</sup>

Two recent meta-analyses exist published investigating the role of TUS and/or LUS in the diagnosis of PE.<sup>31,32</sup> In 2013, Squizzato et al attempted to evaluate the diagnostic accuracy of LUS by selecting studies in which any patient with suspected PE received LUS plus “at least, an imaging test” and evaluated the sensitivity and specificity of LUS; no study was excluded based on the type of reference standard used and there was no restriction to language.<sup>31</sup> Ultimately, ten studies were included (two of which were in German) that spanned the years 1990-2010.<sup>31</sup> Therefore, four of the studies occurred prior to the year 2000 and four did not utilize CTPA for a reference test comparison in diagnosing PE (alternatively used PA, V/Q scans or autopsy).<sup>31</sup> Of the other six studies conducted in 1999 or later, one used MRI as the reference test, four used “composite” reference tests that included CTPA (single-row) and/or historical standards described previously and only one study (from 2010) used multi-row CTPA for confirmation of PE diagnosis. Cumulatively, PE was diagnosed in 507 patients and LUS showed positive symptoms of PE in 417 patients reporting a pooled sensitivity of 87% (95% CI, 80-92%); additionally, LUS was reported to be negative (normal) in 324 of the 380 patients who had PE negative diagnostic tests resulting in a pooled specificity of 82% (95% CI, 71-89%).<sup>31</sup> However,

given this study included variable diagnostic reference tests and potentially with lower sensitivity, the reported diagnostic accuracy of LUS in this analysis may be inflated.

In 2015, Jiang et al recognized weaknesses in the meta-analysis by Squizzato et al and repeated a systematic review and metanalysis that included 13 studies spanning the years 1990-2013 and 1356 subjects.<sup>32</sup> However, Jiang et al also performed sub-analysis for those studies performed prior to the year 2000 versus post-2000 to minimize the influence single versus multi-row CPTA may have had in the comparison of LUS to CTPA. When all studies were analyzed together, the pooled sensitivity of LUS in diagnosing PE was 85% (95% CI, 78-90%) with a specificity of 83% (95% CI, 73-90%).<sup>32</sup> When sub-analysis was performed on the five studies conducted prior to the year 2000, the pooled sensitivity was 94% (95% CI, 89-96%) and specificity was 74% (95% CI, 61-85%); comparatively, in those studies performed after the year 2000, the pooled sensitivity was 77% (95% CI, 70-83%) and specificity was 88% (95% CI, 78-94%).<sup>32</sup> This supports the previously stated hypothesis that earlier (less sensitive) diagnostic methods for PE likely falsely inflated the accuracy of LUS and/or TUS in evaluating PE.

#### *Single organ POCUS: cardiac*

The use of cardiac POCUS (echocardiography) to evaluate for RV dysfunction through a FOCUS exam has been reported to increasingly help ED providers gain information to differentiate the symptoms of chest pain or dyspnea.<sup>22</sup> Four studies prospective, observational studies were found examining the use of cardiac POCUS alone in diagnostic work up for PE.<sup>22,23,33,34</sup> In three of these studies, single cardiac POCUS was evaluated in comparison of the use of multiorgan POCUS and details of the studies will be discussed elsewhere (see “Multiorgan POCUS”) as well as summarized in Table 3.<sup>23,33,34</sup> The results of these three studies showed high variability in sensitivity of cardiac POC ranging from 48-92% for the diagnosis of

PE.<sup>23,33,34</sup> Additionally, Daley et al investigated the use cardiac POCUS in a prospective, observational study in which a convenience sample included 150 patients who were being evaluated for suspected PE.<sup>22</sup> Subjects included were those that had CTPA and were able to have a FOCUS exam completed when ED clinicians were available to do so (convenience sample). The authors in this study focused on the sensitivity of the TAPSE portion of the FOCUS exam, how varying the TAPSE measurement affected sensitivity as well as how TAPSE compared to other components of the exam.<sup>22</sup> A total of 32 patients had PE diagnosed by CTPA but did not specify the number of patients from the total sample that had positive FOCUS exams. The authors reported that a FOCUS exam using a TAPSE of 20 mm had the highest sensitivity of 72% compared to 56% when the standard recommendation for a TAPSE of 17 mm was used; for all other parameters usually included in a FOCUS exam (i.e., RV enlargement, “D” sign or septal flattening, tricuspid regurgitation or McConnell’s sign), the sensitivity ranged from 13-43% (the authors did not report the overall sensitivity for all components of the FOCUS exam).<sup>22</sup> However, it was noted in post hoc analysis that when those patients who were diagnosed with a PE and initially presented with symptoms of tachycardia and/or hypotension (n=17), the sensitivity of TAPSE alone in the FOCUS exam was 94% and 100% when all components were combined in analysis for these patients.<sup>22</sup> In the other three studies reviewed, only Dwyer et al included TAPSE in their FOCUS evaluation and also reported this criteria to have the highest sensitivity out of the FOCUS components but still remained low at only 37%.<sup>23</sup> Furthermore, in the study by Mansencal et al they also reported a higher sensitivity of a cardiac POCUS exam (72% compared to 55%) for patients diagnosed with PE that presented with symptoms of dyspnea.<sup>33</sup> These findings highlight the importance of evaluating the components of protocols used in single organ POCUS as well as their utility in specific symptom presentations of PE.

*Multiorgan POCUS*

The comparison of the aforementioned single organ ultrasound studies highlights the variable and suboptimal sensitivity that exists with single organ POCUS. It further illustrated that even when single organ ultrasound use is intended, oftentimes additional ultrasound modalities, namely CUS and cardiac ultrasonography (echocardiography), have been utilized as well to help ensure accurate diagnosis of PE or when CTPA is inconclusive, unavailable or contraindicated. Given this trend, additional studies have gone on to investigate if combined use of various single organ modalities will improve the diagnostic accuracy of POCUS. Studies of multiorgan POCUS exist as early as 1998 but, given more sensitive diagnostic confirmatory imaging for PE was not available at this time, this paper will focus on those multiorgan POCUS studies only including comparison with CTPA.<sup>35</sup>

The term “triple” POCUS has been coined to describe one modality of multiorgan POCUS that includes the use of combined LUS/TUS, vascular (including CUS and/or IVC evaluation) and cardiac ultrasound. Two studies were found investigating the use of triple POCUS<sup>6,13</sup> but only one evaluated the sensitivity and specifically for use of triple POCUS in PE diagnosis. Nazerian et al conducted a multicenter, blinded, prospective accuracy study in 2014 comparing the use of triple POCUS (LUS, cardiac and vascular/CUS) to confirmed diagnosis of PE by multi-row CTPA in 357 patients presenting with clinical symptoms suspicious for PE.<sup>6</sup> Of the total number patients enrolled, 133 had a positive multiorgan POCUS exam and 99 of those patients had a confirmed diagnosis of PE yielding a sensitivity of 90% and a specificity of 86%. The authors of this study also provided sub-analysis for each single system POCUS and reported the following for sensitivity and specificity: 61% and 96% for LUS alone, respectively; 33% and 91% for cardiac alone, respectively; and for vascular (CUS) 53% and 98%, respectively.<sup>6</sup> This



study combining single and multiorgan POCUS comparisons, illustrates previous conclusions that single organ POCUS is insufficient alone for diagnosis of PE but that the use of triple POCUS may increase the potential of this modality for sensitive diagnosis of PE.

More recently, Zanobetti et al attempted to evaluate the use of multiorgan POCUS (LUS, cardiac) in patients with a broader clinical presentation and differential work up for acute dyspnea.<sup>36</sup> In a prospective, blinded, observational study consecutively enrolling a total of 2683 patients with symptoms of dyspnea in the ED, multiorgan POCUS was performed in addition to routine PE evaluation (including confirmatory contrast CT scans).<sup>36</sup> Of these patients, 95 were diagnosed with PE and 41 of those had a positive multiorgan POCUS exam yielding a sensitivity of 40% and a specificity of 100%.<sup>36</sup> It was also noted that multiorgan POCUS had higher sensitivity and specificity to help in establishing alternative diagnoses in the differential for dyspnea (including pneumothorax, pneumonia and pericardial effusion).<sup>36</sup> Although multiorgan POCUS did not perform well as a diagnostic tool for ruling in PE, it had high specificity for helping to exclude PE as the underlying cause of dyspnea.

Other combinations of POCUS have also been investigated for the use of multiorgan POCUS in detection of PE. In another study, designed similarly to Zanobetti et al, Lichtenstein et al evaluated patients with a presenting symptoms of dyspnea using a dual POCUS exam (LUS plus CUS) to study the accuracy of the previously described BLUE protocol.<sup>17, 36</sup> A total of 260 patients received a dual POCUS examination in addition to standard diagnostic tests (including helical CT for suspected PE).<sup>17</sup> Among these patients, 21 received a diagnosis of PE with 20 of those patients having a positive LUS exam and 17 having a positive CUS exam; when the patients who had both positive LUS and CUS exams were considered, the dual POCUS exam demonstrated a sensitivity of 81% with a specificity of 99%.<sup>17</sup> The authors concluded this

method is more advantageous in ruling out PE in that it also helps to find alternative etiologies for patients presenting with symptoms of dyspnea and reported was able to correctly diagnosis the underlying cause of respiratory compromise in 90.5% of patients to expedite management.<sup>17</sup> This is yet another study that illustrates the value-added use of multiorgan POCUS in patients with respiratory presentations that may or may not include PE.

In a similar study design, Bataille et al evaluated the use of an alternative dual POCUS including LUS and cardiac ultrasound (echocardiography) in accurately diagnosing the cause of acute respiratory failure (including symptoms of tachypnea, hypoxia on room air with respiratory acidosis).<sup>37</sup> Of the 136 patients presenting with symptoms of acute respiratory failure and received the dual POCUS exam plus a standard diagnostic work up (including CT), 13 received a final diagnosis of PE with five of those patients showing a positive dual POCUS exam yielding a sensitivity of 83% and a sensitivity of 84%.<sup>37</sup> The authors also performed sub-analysis in this study for single organ LUS alone for comparison with a resulting sensitivity of 67% and specificity of 94% and concluded that the dual approach was favorable compared to single LUS for diagnosis of PE.<sup>37</sup> This study also demonstrated that this form of dual POCUS had greater accuracy in diagnosis other etiologies such as cardiogenic edema and pneumonia.<sup>37</sup> When considering both the results of Lichtenstein et and Bataille et al with a population of patients presenting with symptoms possibly less specific for PE (i.e., acute respiratory failure), it still resulted in similar suboptimal sensitivity for diagnosis of PE but provided a means to help rule out PE and uncover other underlying etiologies to explain the cardiopulmonary pathology.

Another multiorgan POCUS combination that exists and has been investigated in the use of diagnosing suspected PE is another dual modality of cardiac ultrasonography (echocardiography) plus CUS. Three prospective observational studies evaluated the diagnostic

accuracy of how this dual multiorgan POCUS compares to CTPA.<sup>23,33,34</sup> Mansencal et al attempted to evaluate if form of dual POCUS could help triage patients in the ED with suspected PE and conducted a prospective, blinded, observational trial consecutively enrolling 76 patients that presented to the ED with concern for PE after D-dimer screening was completed.<sup>33</sup> All patients received echocardiography plus CUS using a portable ultrasound device at the bedside and measured for symptoms of RV strain as previously described and CUS for signs of DVT.<sup>33</sup> Of the patients enrolled, 31 patients had PE diagnosis with a majority confirmed by CTPA (only three patients required an additional V/Q scan to confirm the diagnosis) and 41 patients had a positive dual POCUS exam with a reported combined sensitivity of 87% and a specificity of 69%.<sup>33</sup> To further evaluate the impact that more than one POCUS modality has on the accuracy of PE diagnosis, the authors also reported single organ POCUS results for comparison with echocardiography alone demonstrating a sensitivity of 55% and specificity of 69% while CUS alone had a sensitivity of 58% with a specificity of 93%.<sup>33</sup>

In a similar prospective multicenter observational study evaluating the same multiorgan combination described above, Dwyer et al used the FOCUS protocol, including TAPSE, for cardiac ultrasound plus CUS in evaluating 199 patients with suspected PE that were undergoing CTPA (but the number of detector rows in the CTPA was not specified in the study).<sup>23</sup> The dual POCUS exam was considered positive if the patient had any abnormal findings on either modality of ultrasound. The prevalence of PE diagnosis in this group was 46 patients (26 with peripheral PE compared to 20 with centrally located PE) and total of 42 patients had positive POCUS findings (20 patients had a positive CUS, 22 had a positive FOCUS exam and 32 patients had *either* a positive CUS or FOCUS exam).<sup>23</sup> For those patients with a positive FOCUS exam alone (single organ cardiac exam), the reported sensitivity was 48% and specificity was

88% regardless of the location of the PE; however, in the “either” group when CUS was also considered (multiorgan POCUS), the sensitivity for PE increased to 87% with a specificity of 69% regardless of location of PE.<sup>23</sup> It was also reported in the text of the results section of this article (no table summarizing data available) that when considering the location of the PE, the sensitivity for the “either” group decreased to 46% for peripheral (distal) PE but increased to 100% for centrally (proximally) located PE.<sup>23</sup> This suggests that the use of a POCUS strategy that includes cardiac plus CUS helped to identify patients with DVT that may have gone undiagnosed until they manifested as higher risk PE.

One final study worth inclusion in the comparison of cardiac POCUS studies, is that performed by Filipiak-Strezecka et al recently in 2018.<sup>34</sup> This prospective observational study investigated the use of a multiorgan POCUS approach also including cardiac ultrasound and CUS and utilized a pocket-size portable ultrasound device.<sup>34</sup> A total of 100 patients presenting to the ED with 15 patients having a positive CUS exam, 59 patients had a positive cardiac ultrasound exam showing RV enlargement and a total of 24 patients had confirmed PE diagnosis by CTPA.<sup>34</sup> In those patients who had both a positive CUS *and* cardiac ultrasound exam, the reported sensitivity was 54% with a specificity of 100% as well as a positive predictive value for PE of 100%; when data was analyzed for those with a positive CUS *or* a positive cardiac ultrasound exam, the sensitivity was 92% with a specificity of 49%.<sup>34</sup> The authors also analyzed the sensitivity and specificity of each single organ POCUS modality for comparison and reported 54% and 97%, respectively, for CUS alone and 92% and 51%, respectively, for cardiac ultrasound alone.<sup>34</sup> It was also noted that when this exam was incorporated into the physical assessment it took approximately five minutes to perform.<sup>34</sup> These results suggest that when this exam is incorporated to the clinical assessment of a patient with suspected PE, it may help

clinicians increase their suspicion early on for the diagnosis of PE and lead to expedited and improvement of this disease.

## **METHODS**

A literature search was conducted via the Augsburg Library search engine but included libraries worldwide. Peer reviewed articles were requested in the search for primary literature. Databases searched included MEDLINE, Science direct, Pubmed, Google Scholar and UpToDate. Additionally, review articles that were commonly cited in the review of references from other articles retrieved were obtained reviewed as well when not obtained through the above search. Only articles available in English were utilized. Article titles and abstracts were reviewed for inclusion of any type of POCUS (single organ or multiorgan) as well as CTPA in the evaluation of POCUS; if details of either were not available in the abstract, articles were obtained for more thorough examination to see if met this criteria for comparison and inclusion.

Search terms and abbreviations utilized in this research included: pulmonary embolism (PE), point of care ultrasound (POCUS), computed tomography pulmonary angiography (CTPA), lung ultrasound, multiorgan ultrasound, thoracic ultrasound, cardiac ultrasound, diagnosis and sensitivity.

Studies included in the literature review included those performed in adult (> 18 years old) human subjects and excluded animal studies in order to better apply findings to the general population. Literature reviewed included systematic reviews, meta-analyses, prospective observational studies, retrospective chart reviews and case reports.

## **DISCUSSION**

Despite advances in imaging technology and the use of clinical algorithms to help guide systematic diagnostic management of PE, it remains a disease that is frequently underdiagnosed,

undertreated and a fatal complication of VTE. Currently multi-detector row CTPA remains the gold standard given it has both high sensitivity and specificity but can still produce false-negative results, has a lower sensitivity for peripheral (distal) PE, is not always readily available and is contraindicated in some cases. Additionally, CTPA is only helpful when it is obtained and the potential for an inaccurate clinical probability assessment exists that can lead clinicians away from obtaining CTPA in those still with PE. Therefore, one could argue that *any* additional diagnostic information that may add to the efficiency and accuracy (ruling in and/or ruling out) of PE evaluation should be considered and further investigated.

Based on this review of existing literature investigating the use of single and multiorgan POCUS in the diagnosis of PE, the sensitivity of both modalities varies considerably (see Table 3). Overall, both modalities still proved to have inferior sensitivity to CTPA. In single organ POCUS studies for TUS/LUS, sensitivity ranged from 71-80% for single-row CTPA compared to 61-90% with for multi-row CTPA (if omit the data from Acar et al since they did not provide a combined sensitivity result for comparison). The lower range results for the multi-row CTPA comparison may be explained by the findings Jiang et al reported in the previously mentioned meta-analysis that when studies prior to 2000 were omitted in analysis the overall sensitivity was lower likely due to the comparison to the more sensitive multi-row CTPA.<sup>32</sup>

It is difficult to compare results of multiorgan POCUS sensitivity across the board given the different combinations of POCUS used. However, in the five studies reviewed that provided analysis of the sensitivity of single organ POCUS modalities compared to that of combined individual POCUS components, multiorgan POCUS had higher sensitivity for all five studies.<sup>6,23,33,34,37</sup> However, it should be noted that in the study done by Filipiak-Strezka et al, the multiorgan POCUS did report a lower combined sensitivity of 52% for cardiac POCUS *and* CUS

compared to individual component sensitivities of 92% for cardiac POCUS and 54% for CUS; but, the overall sensitivity increased to 92% when cardiac POCUS *or* CUS were compared.<sup>34</sup> Of these five studies found investigating the use multiorgan POCUS in PE diagnosis, only the study by Nazerian et al using a triple POCUS approach reported sensitivity *and* specificity that came somewhat close to that of CTPA but still remained inferior (triple POCUS 90% and 86%, respectively compared to the reported CTPA performance of 96-100% and of 97-98%, respectively).<sup>2,3,6</sup>

The heterogeneity of studies performed not only in single organ but also multiorgan POCUS studies also likely leads to the variable results. Not all studies enrolled patients in the same manner with some using convenience samples and some not utilizing consecutive enrollment leading to bias (see Table 3). In the studies by Bataille et al, they alternatively enrolled patients with symptoms of “acute respiratory failure” (and possibly a lower initial suspicion of PE initially?) and overall had lower prevalence of PE in the enrolled patients (10%) with a reported sensitivity for single organ LUS to be 67% compared to multiorgan POCUS (LUS plus cardiac) of 83%.<sup>37</sup> Lichtenstein et al reported a similar sensitivity of 81% with similar selection criteria and prevalence (8%) but utilized a multiorgan POCUS approach of LUS and CUS (the BLUE protocol).<sup>17</sup> This may suggest that even when there may be lower suspicion of PE, POCUS may still have some value in helping to diagnose PE as the underlying etiology of acute respiratory failure.

One critique to the design of those studies that included blinding of the POCUS examiner. In these studies, the clinician performing the POCUS exam were non-radiology/cardiology clinicians that were usually not involved in the management of the patient and were blinded to the CTPA results (oftentimes the exam was done prior to the CTPA or soon

thereafter without the results being available to the POCUS examiner). While important to avoid having CTPA results influence the interpretation of the POCUS exam it would likely be performed by the managing clinician with additional information about the clinical case and could also alter the results.

The existing single organ POCUS studies also varied in size with a majority having smaller sample sizes. However, when considering the two largest studies using TUS, Nazerian et al and Mathis et al still only reported the sensitivity of TUS to be 61-74% with the higher value from the Mathis et al study which used single row CTPA likely yielding a falsely elevated reported sensitivity for LUS/TUS and also did not consecutively enroll patients possibly contributing to bias in patient selection.<sup>6,26</sup> These findings suggest that the sensitivity of TUS alone *at best* may be consistent with that of single-row CTPA (which has now largely been replaced anyway with improved multi-row detector CTPA) and cannot be recommended for diagnostic purposes in PE.

The International Liaison Committee on Lung Ultrasound recognized the emerging value that LUS can provide in the evaluation of PE in its published “International evidence-based recommendations for point-of-care lung ultrasound” in 2012.<sup>38</sup> In this document (which included data analysis only through the October 2010), Volpicelli et al gave the following recommendations to the following three statements pertaining to PE:

- “Lung ultrasound should be used in the evaluation of lung consolidation because it can differentiate consolidations due to pulmonary embolism, pneumonia, or atelectasis.” (strong: level A)<sup>38</sup>



- “Lung ultrasound is an alternative diagnostic tool to computerized tomography in diagnosis of pulmonary embolism when CT is contraindicated or unavailable.” (strong: level A)<sup>38</sup>
- “Lung ultrasound is a clinically useful diagnostic tool in patients with suspected pulmonary embolism.” (strong: level B)<sup>38</sup>

These recommendations were published prior to the availability of some more recent studies (including the larger study by Nazerian et al in 2014) and did not specify if LUS was evaluated as single organ POCUS versus integrated into a multiorgan POCUS approach.<sup>6,38</sup> No updates to these guidelines were found in this literature search.

Cardiac POCUS alone has also shown variable performance in the diagnostic accuracy for PE. In the studies reviewed for cardiac POCUS (echocardiography) to evaluate for RV dysfunction, the sensitivity ranged from 48-92% and the specificity 51-97% depending on the criteria used in the cardiac POCUS evaluation (which varied between studies) and the location of the PE. The most promising results for applying cardiac POCUS into PE evaluation were in those patients who presented with symptoms of shock or hypotension resulting from central PE. Dwyer et al found that cardiac POCUS alone had a sensitivity of 90% in detecting central PE (and 100% sensitivity when combined with CUS) but decreased to only 48% for all PE when peripheral PE were included in analysis.<sup>23</sup> In the most recent (2014) available version of the “Guidelines on the diagnosis and management of acute pulmonary embolism” published by the European Society of Cardiology (ESC), the use of echocardiography is not recommended in those patients who are normotensive with lower risk PE probability; however, it *does* supports the use for PE diagnosis in patients presenting with hemodynamic instability that are too unstable to confirm diagnosis with CTPA to allow reperfusion therapy to be immediately initiated.<sup>39</sup>

Given the mortality associated with central emboli, the use of cardiac POCUS for evaluation of PE should be reserved for this patient population and may prove to have a significant impact on mortality associated with PE.

Based on the literature available to date, neither single nor multiorgan POCUS can be used as a first line diagnostic tool in the evaluation of PE. However, it has shown promise as an adjunct to the gold standard of CTPA. In the studies in which patients received LUS or TUS as part of either single or multiorgan POCUS, alternative etiology for the presenting symptoms were often found in the cases where PE was not the cause. In a study by Koenig et al in 2014, 96 patients who presented with clinical suspicion of PE and were able (convenience sample) to receive both a multiorgan POCUS exam (using the same triple approach by Nazerian et al in 2014; cardiac, TUS and CUS) and confirmatory CTPA were enrolled; of these patients, 12 (12.5%) had a positive diagnosis of PE, two (2%) were also positive for DVT and 54 (56%) had an alternative diagnosis found on the triple POCUS exam to explain symptoms (which were confirmed by CTPA as well).<sup>13</sup> The Koenig et al study is discussed here rather than included in the previous review of the literature as the authors, unfortunately, did not provide sensitivity data for their triple POCUS diagnostic performance. Koenig et al estimated that in those patients who had alternative diagnosis to PE or DVT found on triple POCUS (56%), those patients could have avoided needing CTPA or even other pulmonary radiographs.<sup>13</sup> Nazerian et al also reported that when multiorgan (triple) POCUS was used in their study, they were able to detect an alternative diagnosis in almost one-third of the patients.<sup>6</sup> In both these studies, triple POCUS enhanced diagnostic management of these patients by 1) providing additional clinical data that would not have necessarily been obtained in a timely manner to help narrow in on the differential diagnosis for presenting symptoms, and 2) those cases where the POCUS exam preceded CTPA, a

theoretical reduction to the amount of radiation exposure. In fact, a specific endeavor entitled the “Lung Ultrasound in the Critically Ill Favoring Limitation of Radiation” project (or LUCI-FLR project) has been developed to utilize LUS to decrease bedside radiographies by one-third and urgent CT by two-thirds in the next three decades.<sup>40</sup>

The use of multiorgan POCUS has also been investigated for how it can contribute more objective data for application into the prediction rules. Two prospective, observational studies have investigated how the integration of clinical data from multiorgan POCUS into the clinical prediction rules might improve the diagnostic process for PE.<sup>11,34</sup> In an blinded, observational cohort multicenter diagnostic accuracy study conducted by Nazerian et al in 2017, the authors calculated both the conventional Wells score (Ws) but also created and calculated an alternative ultrasound Wells score (USWs) in which two questions were changed to include more objective clinical signs obtained from a multiorgan POCUS exam with LUS and CUS.<sup>11</sup> The two questions that were adjusted were as follows: “signs and symptoms of DVT” was changed to “venous ultrasound positive for DVT” and “alternative diagnosis less likely than PE” was changed to “alternative diagnosis less likely than PE after lung ultrasound.”<sup>11</sup> The scoring points assigned to these statements was unaltered and diagnosis for PE was considered “unlikely” still if the score was  $\leq 4$  for either score.<sup>11</sup> Of the 446 patients that were consecutively enrolled with clinical suspicion of PE and were able to receive the multiorgan POCUS exam within three hours (convenience sample), 125 patients were diagnosed with PE with a majority (119) by CTPA (five required lung scintigraphy and one by autopsy). When the USWs was compared to the standard Ws, it had a significantly improved sensitivity of 70% compared to 58% ( $p < 0.01$ ). Furthermore, in those patients who had a USWs  $\leq 4$  and a negative D-dimer, the failure rate was 0.8% compared to 1.9% for Ws (although this difference did not meet statistical significance,

p=0.33).<sup>11</sup> It was estimated that when multiorgan POCUS (LUS and CUS) more objectively adjusted the prediction rule (Wells score) and was combined with D-dimer, CTPA could have been avoided 50.5% of patients compared to 27% of patients using the Ws.<sup>11</sup>

Filipiak-Strzecka et al also investigated how data from a multiorgan POCUS (cardiac and CUS) using a pocket-sized ultrasound device to augment the physical exam, may be integrated into both the Wells and Geneva prediction rules to improve the efficiency and diagnostic accuracy for PE.<sup>34</sup> These authors only adjusted the Wells rule for sign and symptoms of DVT to include “positive CUS result” but added a criteria for RV enlargement (which could award one point to the score); for the Geneva score, “unilateral lower limb pain” was changed to “positive CUS result” and the addition of RV enlargement was added in the same manner as the Wells score.<sup>34</sup> The threshold for the modified Wells score was changed to  $\geq 5$  and  $\geq 7$  for the modified Geneva score. The authors reported that there was a significant improvement in diagnostic accuracy in the conventional versus modified Wells score (81% versus 93%, respectively; p=0.012) as well as in the Geneva score (59% versus 94%, respectively; p=0.02).<sup>34</sup> These two studies demonstrate that multiorgan POCUS may have multiple roles in the diagnostic process for PE. Based on the findings in these two studies, the ability of multiorgan POCUS to help add to the risk stratification of patients presenting with clinical suspicion of PE appears promising.

One of the main drawbacks to the diagnostic evaluation of PE is that CTPA is not always available and cannot be applied to some patient populations. In some of the reviewed studies on both single and multiorgan POCUS, those patients with hemodynamic instability or pregnancy were excluded and, based on this review of the literature, no studies are available looking at the use of POCUS in these populations. As stated previously above, the International Liaison Committee on Lung US recommendations does support the use of at least LUS as an alternative

diagnostic tool when CTPA is unavailable or contraindicated.<sup>38</sup> Given the reported higher sensitivity of triple POCUS, this seems to be the logical alternative for this patient population and a case study reported in the literature illustrates this very point. Silva et al describe a case in which a 26 year-old-man presented to the ED with sudden onset of dyspnea, pleuritic chest pain and fatigue.<sup>41</sup> The patient had no previous medical history except for a recent upper airway infection and essentially had been on bedrest for three days preceding.<sup>41</sup> His physical exam was notable for tachypnea (respiratory rate of 24 breaths per minute), tachycardia (heart rate 115 beats per minute), oxygen saturations of 92%, a blood pressure of 138/79, crepitus in the left lower lung base and swelling of his right leg with normal pulses.<sup>41</sup> A Wells score was calculated to be nine (based on clinical signs and symptoms of DVT) and PE was the most probable diagnosis.<sup>41</sup> However, CTPA was not available at the time of this patient's presentation (for reasons not specified). Therefore, the providers applied the triple POCUS protocol and found the following: On LUS and A profile was observed on all right lung fields with some B-lines in the anterior part of the lung base and a small sub-pleural consolidation in the more posterior position; Cardiac evaluation did not show dilation of the RV nor any thrombi; CUS showed a right popliteal thrombus.<sup>41</sup> Given the finding of DVT on CUS with characteristics of PE per LUS, the patient was immediately started on anticoagulation therapy and made a full recovery in three days.<sup>41</sup>

## **CONCLUSION**

Pulmonary embolism remains a common condition that frequently is misdiagnosed or goes undiagnosed with fatal consequences. When treated early, PE has a mortality rate of 2-8% but if left untreated the mortality may be as high as 25-30%.<sup>32</sup> Therefore, early and accurate diagnosis is vital to allow initiation of anticoagulation therapy to appropriate candidates. The

diagnosis of PE presents challenges to clinicians as the symptoms are non-specific. In the United States, over 10 million patients seek care annually for the symptoms of dyspnea, chest pain or both with the etiology of PE included in differential diagnosis for these symptoms.<sup>34</sup> Currently, multi-row CTPA remains the gold standard for diagnosis of PE due to its high sensitivity and specificity for detection of PE. However, this imaging modality has limitations and cannot be used in all patient scenarios. Furthermore, despite improvements in CTPA sensitivity and algorithms to guide the diagnostic approach to PE, mortality for this disease remains unchanged and new diagnostic techniques should be explored.<sup>2,5</sup>

Point-of-care ultrasound has a promising role in the evaluation of PE. However, based on the literature available to date, the sensitivity of both single and multiorgan POCUS remains inferior to CTPA and should not be used as a first line diagnostic test. Triple multiorgan POCUS, using cardiac ultrasound (echocardiography), LUS and CUS, has shown sensitivity and specificity closer to CTPA when compared to single organ POCUS and should be considered as an alternative when the gold standard is unavailable or contraindicated.

Point-of-care ultrasound has several advantages in the evaluation of PE. First, POCUS is a safe, non-invasive imaging modality that has no contraindications. Secondly, POCUS is readily available for use at the bedside and can be efficiently integrated into the physical exam and clinical assessment of a patient early on in admission. Objective information obtained from POCUS can be incorporated into prediction rules to help improve diagnostic accuracy and expedite management strategies for patients with suspected PE. Studies have demonstrated the POCUS exam can be done in a timely manner with a minimum average time to complete some exams being three minutes (Lichtenstein et al for combined LUS and CUS)<sup>17</sup> and a maximum time reported was 15 minutes (Mohn et al for TUS)<sup>25</sup> in the studies reviewed but likely varies

based on the experience of the clinician. Consideration should be given to include the use of POCUS in algorithms that guide the diagnostic management of PE (see Figure 2 for an example of one proposed algorithm). Third, POCUS can provide information to confirm alternative cardiopulmonary conditions that present with symptoms like PE and narrow the differential diagnosis and rule out PE. Given this potential, POCUS also has the potential to reduce the need for unnecessary imaging. Fourth, POCUS provides an alternative diagnostic test for those patients who may be too unsafe for transport for tests, have contraindications for CTPA or if CTPA is not available. Lastly, as ultrasound technology improves, devices are becoming increasingly compact and an inexpensive imaging option that is widely available for use.<sup>5</sup>

Despite the potential advantages of POCUS in the evaluation of PE, some issues exist that limit the effectiveness and accuracy of this tool. Variability in training and experience in those performing this exam likely will impact the accuracy of POCUS. While medical schools are increasingly incorporating POCUS into their training, variability in curriculum and competency exists among clinicians across different areas of practice.<sup>5,9,16</sup> Furthermore, a need for standardized and validated POCUS protocols exist as evidenced by the variability observed in the literature for criteria defining a “positive” POCUS exam. Additional future opportunities for research to help determine how POCUS could improve the diagnostic evaluation of PE could include studies that use POCUS in those patient populations currently limited in their diagnostic evaluation of PE and cannot receive CTPA; how the addition of multiorgan triple POCUS affects the timeline of PE diagnosis, treatment initiation and outcomes; the impact multiorgan triple POCUS could have on the prediction rules; and, how the use of POCUS performed by the clinical care team privy to patient information would affect the sensitivity of the exam (i.e., reality). Until observational studies can consistently demonstrate that POCUS yields a high

sensitivity and specificity to rival CTPA, POCUS cannot replace the gold standard CTPA for the diagnosis of PE and randomized controlled trials cannot be safely performed to evaluate these two modalities against one another.

The use of POCUS is seemingly evolving and expanding in multiple clinical facets not just pertaining to PE. Given the compact size of devices as well as increasing use and research available on how this tool can enhance the clinical assessment and patient outcomes, I anticipate POCUS may soon become integrated into the routine physical exam in many areas of practice outside the ED and ICU. In fact, POCUS has even been described as an “ultrasound stethoscope” or the “stethoscope of the 21<sup>st</sup> century.”<sup>5</sup> As a new physician assistant, it seems that acquiring the skill of POCUS would not only enhance my clinical evaluation, but also help me in providing accurate and efficient clinical management of my patients. The use of POCUS would be a valuable adjunct or even alternative diagnostic tool in certain situations if I encounter a patient with a PE or any other underlying cardiopulmonary condition. However, it also is apparent that sufficient training, practice with this device and staying current with specific literature pertaining to POCUS in various conditions seems to be crucial to the successful application of POCUS into practice. In the words of Squizzato et al, “the new era of POCUS has just started.”<sup>5</sup>



## REFERENCES

1. Papadakis MA, McPhee SJ, Rabow MW. *Current Medical Diagnosis and Treatment*. 57<sup>th</sup> ed. New York, NY: McGraw Hill Education; 2018: 300-307.
2. Squizzato A, Rancan E, Dentali F, Bonzini M, Guasti L, Steidle L, Mathis G, Ageno W. Diagnostic accuracy of lung ultrasound for pulmonary embolism: a systematic review and meta-analysis. *J Thromb Haemost*. 2013; 11: 1269-78.
3. Huisman VM, Klok FA. Diagnostic management of acute deep vein thrombosis and pulmonary embolism. *J Thromb Haemost*. 2013; 11: 412-22.
4. Reissig A, Heyne J, Kroegel C. Sonography of lung and pleura in pulmonary embolism: sonomorphic characterization and comparison with spiral CT scanning. *Chest*. 2001; 120: 1977-1983.
5. Squizzato A, Galli L, Gerdes VEA. Point-of-care ultrasound in the diagnosis of pulmonary embolism. *Critical ultrasound journal*. 2015;7(1):1-4. doi:10.1186/s13089-015-0025-5
6. Nazerian P, Vanni S, Gigli C, et al. Accuracy of point-of-care multiorgan ultrasonography for the diagnosis of pulmonary embolism. *Chest*. 2014;145(5):950-957. doi:10.1378/chest.13-1087
7. Miller LD, Joyner CR, Dudrick SJ, Eskin DJ. Clinical use of ultrasound in the early diagnosis of pulmonary embolism. *Ann Surg*. 1967; 166: 381-92.
8. Mathis G, Metzler J, Fussenegger D, Sutterlutti G, Feurstein M, Fritzsche H. Sonographic observation of pulmonary infarction and early infarctions by pulmonary embolism. *European Heart Journal*. 1993; 14 (6): 804-808.
9. Morris AE. Point-of-care ultrasound: Seeing the Future. *Current problems in diagnostic radiology*. 2015; 44(1):3-7. doi:10.1067/j.cpradiol.2014.05.012

10. Righini M, Robert-Ebadi H, Le Gal G. Diagnosis of acute pulmonary embolism. *J Thromb Haemost* 2017; 15: 1251–61.
11. Nazerian P, Volpicelli G, Gigli C, et al. Diagnostic performance of wells score combined with point-of-care lung and venous ultrasound in suspected pulmonary embolism. *Academic emergency medicine*. 2017;24(3):270-280. doi:10.1111/acem.13130
12. Koenig S, Chandra S, Alaverdian A, Dibello C, Mayo P, Narasimhan M. Ultrasound assessment of pulmonary embolism in patients receiving CT pulmonary angiography. *Chest*. 2014; 145 (4): 818-823.
13. Davenport MS, Newhouse JH. Patient evaluation prior to oral or iodinated intravenous contrast for computed tomography. Kressel HY, Feldweg AM, Forman JP, eds. UpToDate. January 2018.
14. Carrier M. A Study to Evaluate the Safety of Withholding Anticoagulation in Patients with Subsegmental PE Who Have a Negative Serial Bilateral Lower Extremity Ultrasound (SSPE). [www.clinicaltrials.gov](http://www.clinicaltrials.gov). Accessed July 18, 2019.
15. Huggins JT, Mayo P. Indications for bedside ultrasonography in the critically ill adult patient. Manaker S, Finlay G, eds. UpToDate. February 2019.
16. Recommended Curriculum Guidelines for Family Medicine Residents Point of Care Ultrasound. American Academy of Family Physicians. [https://www.aafp.org/dam/AAFP/documents/medical\\_education\\_residency/program\\_director/Reprint290D\\_POCUS.pdf](https://www.aafp.org/dam/AAFP/documents/medical_education_residency/program_director/Reprint290D_POCUS.pdf). Developed 12/2016. Accessed July 11, 2019.
17. Lichtenstein DA, Mezière GA. Relevance of lung ultrasound in the diagnosis of acute respiratory failure: the BLUE protocol. *Chest*. 2008; 134:117–25.

18. Seyedhosseini J, Bashizadeh-fakhar G, Farzaneh S, Momeni M, Karimialavijeh E. The impact of the BLUE protocol ultrasonography on the time taken to treat acute respiratory distress in the ED. *J of Emergency Medicine*. 2017; 35: 1815-1818.  
doi:10.1016/j.ajem.2017.06.007
19. Bekgoz B, Kilicaslan I, Bildik F, et al. Blue protocol ultrasonography in emergency department patients presenting with acute dyspnea. *The American journal of emergency medicine*. 2019;2019 Feb 20. doi:10.1016/j.ajem.2019.02.028
20. Patel CJ, Bhatt HB, Parikh SN, Jhaveri BN, Puranik JH. Bedside lung ultrasound in emergency protocol as a diagnostic tool in patients of acute respiratory distress presenting to the emergency department. *J Emerg Trauma Shock*. 2018; 11: 125-129.  
<http://www.onlinejets.org/article.asp?issn=0974-2700;year=2018;volume=11;issue=2;spage=125;epage=129;aulast=Patel> Accessed July 25, 2019.
21. Taylor RA, Davis J, Luis R, Gupta V, Dziura J, Moore CL. Point-of-care focused cardiac ultrasound for prediction of pulmonary embolism adverse outcomes. *J of Emergency Medicine*. 2013; 45 (3): 392-399.
22. Daley J, Grotberg J, Pare J, et al. Emergency physician performed tricuspid annular plane systolic excursion in the evaluation of suspected pulmonary embolism. *The American journal of emergency medicine*. 2017;35(1):106-111. doi:10.1016/j.ajem.2016.10.018
23. Dwyer KH, Rempell JS, Stone MB. Diagnosing centrally located pulmonary embolisms in the emergency department using point-of-care ultrasound. *The American journal of emergency medicine*. 2018;36(7):1145-1150. doi:10.1016/j.ajem.2017.11.033

24. Reissig A, Heyne J, Kroegel C. Ancillary lung parenchymal findings at spiral CT scanning in pulmonary embolism. relationship to chest sonography. *European journal of radiology*. 2004;49(3):250-257. doi:10.1016/S0720-048X(03)00141-4.
25. Mohn K, Quiot J, Nonent M, Lacut K, Gall G, Couturaud F, Leroyer C. Transthoracic sonography of the lung and pleura in view of a suspected pulmonary embolism: a pilot study. *J Ultrasound Med*. 2003; 22 (7): 673-8.
26. Mathis G, Blank W, Reibig A, Lechleitner P, Reub J, Schuler A, Beckh S. Thoracic ultrasound for diagnosing pulmonary embolism. *Chest*. 2005; 128: 1531-1538.
27. Pfeil A, Reissig A, Heyne J-P, et al. Transthoracic sonography in comparison to multislice computed tomography in detection of peripheral pulmonary embolism. *Lung*. 2010;188(1):43-50. doi:10.1007/s00408-009-9195-x
28. Comert SS, Caglayan B, Akturk U, et al. The role of thoracic ultrasonography in the diagnosis of pulmonary embolism. *Annals of thoracic medicine*. 2013;8(2):99-104. doi:10.4103/1817-1737.109822
29. Acar H, Yilmaz S, Yaka E, Dogan NO, Ozbek AE, Pekdemir M. *Balkan Med J*. 2017; 34: 356-61.
30. Ghanem MK, Makhoulouf HA, Hasan AA, Alkarn AA. Acute pulmonary thromboembolism in emergency room: gray-scale versus color doppler ultrasound evaluation. *The clinical respiratory journal*. 2018;12(2):474-482. doi:10.1111/crj.12547
31. Squizzato A, Rancan E, Dentali F, et al. Diagnostic accuracy of lung ultrasound for pulmonary embolism: a systematic review and meta-analysis. *Journal of thrombosis and haemostasis*. 2013;11(7):1269-1278. doi:10.1111/jth.12232

32. Jiang L, Ma Y, Zhao C, et al. Role of transthoracic lung ultrasonography in the diagnosis of pulmonary embolism: a systematic review and meta-analysis. *Plos one*. 2015;10(6). doi:10.1371/journal.pone.0129909
33. Mansencal N, Vieillard-Baron A, Beauchet A, et al. Triage patients with suspected pulmonary embolism in the emergency department using a portable ultrasound device. *Echocardiography*. 2008;25(5):451-456. doi:10.1111/j.1540-8175.2007.00623.x
34. Filipiak-Strzecka D, Kasprzak JD, Lipiec P. Brief cardiovascular imaging with pocket-size ultrasound devices improves the accuracy of the initial assessment of suspected pulmonary embolism. *The international journal of cardiovascular imaging*. 2018;34(10):1595-1605. doi:10.1007/s10554-018-1382-5
35. Grifoni S, Olivotto I, Cecchini P, et al. Utility of an integrated clinical, echocardiographic, and venous ultrasonographic approach for triage of patients with suspected pulmonary embolism. *The American journal of cardiology*. 1998;82(10):1230-1235.
36. Zanobetti M, Scorpiniti M, Gigli C, et al. Point-of-care ultrasonography for evaluation of acute dyspnea in the ed. *Chest*. 2017;151(6):1295
37. Bataille B, Riu B, Ferre F, et al. Integrated use of bedside lung ultrasound and echocardiography in acute respiratory failure: a prospective observational study in ICU. *Chest*. 2014;146(6):1586-1593. doi:10.1378/chest.14-0681
38. Volpicelli G, Elbarbary M, Blaivas M, et al. International evidence-based recommendations for point-of-care lung ultrasound. *Intensive care medicine*. 2012;38(4):577-591. doi:10.1007/s00134-012-2513-4

39. Konstantinides S.V, Torbicki A, Agnelli G, et al. 2014 esc guidelines on the diagnosis and management of acute pulmonary embolism. *European heart journal*. 2015;35(43):3033-3080. doi:10.1093/eurheartj/ehv131
40. Lichtenstein D. Lung ultrasound in the critically ill. *Annals of Intensive Care*. 2014; 4:1-12.
41. Silva R, Gonçalves Diana, Cabral João Pina, Gomes Bráulio, Teixeira J, Mariz José António. Triple pocus: a new approach to an old problem. *European journal of case reports in internal medicine*. 2018;5(9):1-1. doi:10.12890/2018\_000938

**APPENDIX**

**Table 1. Wells Score and Geneva Score clinical prediction rules for PE**

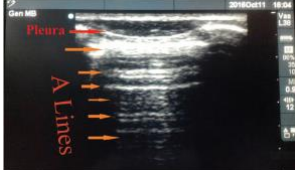

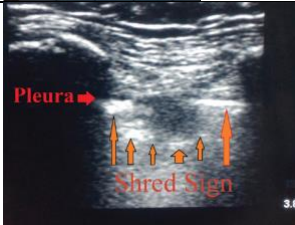
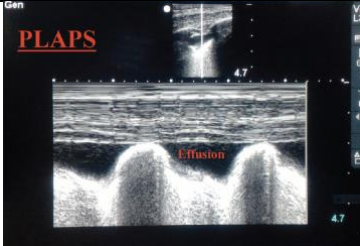
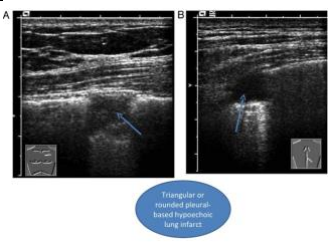
<b>Wells Score*</b>		<b>Geneva Score**</b>	
<b>Variable</b>	<b>Points</b>	<b>Variable</b>	<b>Points</b>
Alternative Dx less likely than PE	<b>3</b>	Age > 65 years old	<b>1</b>
Clinical signs and Sx of DVT (leg swelling and pain with palpation of deep veins)	<b>3</b>	Pain on lower limb deep vein palpitation and unilateral edema.	<b>4</b>
Heart rate > 100 bpm	<b>1.5</b>	Unilateral lower limb pain	<b>3</b>
Immobilization for > 3 days or surgery in previous 4 weeks	<b>1.5</b>	Heart rate 75-94 bpm	<b>3</b>
Previous PE or DVT	<b>1.5</b>	Heart rate $\geq$ 95 bpm	<b>5</b>
Hemoptysis	<b>1</b>	Surgery or fracture within 1 month	<b>2</b>
Cancer (with treatment in the past 6 months or palliative care)	<b>1</b>	Previous PE or DVT	<b>3</b>
		Hemoptysis	<b>2</b>
		Active malignancy	<b>2</b>
<b>Three-level clinical probability assessment (Wells criteria)</b>		<b>Three-level clinical probability assessment</b>	
High	<b>&gt;6</b>	High	<b><math>\geq</math>11</b>
Moderate	<b>2-6</b>	Moderate	<b>4-10</b>
Low	<b>&lt;2</b>	Low	<b>0-3</b>
<b>Two-level clinical probability assessment (Modified Wells criteria)</b>		<b>Two-level clinical probability assessment</b>	
PE likely	<b>&gt;4</b>	PE likely	<b><math>\geq</math>6</b>
PE unlikely	<b><math>\leq</math>4</b>	PE unlikely	<b>0-5</b>

Abbreviations: Sx (symptoms), DVT (deep vein thrombosis), Dx (diagnosis), bpm (beats per minute), PE (pulmonary embolism)

\*Adapted from Papadakis MA, McPhee SJ, Rabow MW. *Current Medical Diagnosis and Treatment*. 57<sup>th</sup> ed. New York, NY: McGraw Hill Education; 2018: 303.

\*\*Adapted from Righini M, Robert-Ebadi H, Le Gal G. Diagnosis of acute pulmonary embolism. *J Thromb Haemost* 2017; 15: 1251–61

**Table 2. Ultrasound characteristics for pulmonary pathology<sup>15,17,20</sup>**

Pulmonary Condition	Ultrasound Characteristics	Example ultrasound images*
<b>Pneumothorax</b>	Absence of lung sliding (A lines) or pulse combined with the presence of a lung point.	
<b>Pulmonary edema or interstitial syndrome.</b>	Profuse, bilateral B+ lines (“lung rockets”) with lung sliding and smooth pleural morphology	
<b>Pneumonia or acute respiratory distress syndrome (ARDS)</b>	Focal B-lines with irregular pleural morphology, consolidation that does not invade the entire lobe (shred sign)	
<b>Pleural effusion</b>	Anechoic area surrounded by typical anatomic boundaries.	
<b>Pulmonary embolism</b>	Triangular or wedge-shaped or round hypoechoic lesions, +/- pleural effusion, A-lines with lung sliding.	

Ultrasound images obtained from the following sources:

\*Patel CJ, Bhatt HB, Parikh SN, Jhaveri BN, Puranik JH. Bedside lung ultrasound in emergency protocol as a diagnostic tool in patients of acute respiratory distress presenting to the emergency department. *J Emerg Trauma Shock*. 2018; 11: 125-129.

<http://www.onlinejets.org/article.asp?issn=0974-2700;year=2018;volume=11;issue=2;spage=125;epage=129;aulast=Patel> Accessed July 25, 2019.

\*Ericsooussi B. Thoracic ultrasound for diagnosing pulmonary embolism. SlideShare.

<https://www.slideshare.net/basselericsoussi/thoracic-ultrasound-for-diagnosing-pulmonary-embolism>. Published February 26, 2009. Accessed July 25, 2019.



Table 3. Summary of single organ and multiorgan POCUS sensitivity and specificity data

Author	Year	Study design	POCUS Type & Criteria for (+) POCUS exam	# enrolled (method of enrollment)	Inclusion Criteria	Exclusion Criteria	# of patients with (+) POCUS exam for PE	Total # of patients with confirmed diagnosis of PE by CTPA (alone vs CTPA + other criteria where applicable)	Reference diagnostic test(s) used	Sensitivity of POCUS type for PE detection	Specificity of POCUS type for PE detection
Reissig et al [4]	2001	Prospective, blinded, observational	"TUS" (+) POCUS Criteria: Not specified	69 (consecutively)	Clinical suspicion of PE per Sx (dyspnea, pleuritic chest pain, hemoptysis, syncope or vertigo, tachypnea)  Received both CTPA and TUS	Not reported.	35 (51%)	32 (46%) – alone 44 (64%)	CTPA (single-row, spiral)  Other criteria: high clinical suspicion, CUS, V/Q scan, PA, echocardiograph y, D-dimer	80%	92%
Mohen et al [25]	2003	Prospective, blinded, observational	"TUS" (+) POCUS Criteria: Wedge-shaped, hypoechoic, homogenous pleural-based lesions OR sharply outlined pleural-based lesion, triangular or rounded to the hilum with hyperechoic reflection at the center	74 (consecutively)	Clinical suspicion of PE per Sx (pleuritic chest pain, unexplained dyspnea, hemoptysis)  Received both CTPA and TUS	Massive PE  Hemodynamic instability	22 (30%)	15 (20%) – alone 31 (42%)	CTPA (row details not available)  Other criteria: high clinical suspicion + V/Q scan, DVT on CUS, PA	71%	77%
Reissig et al [24]	2004	Prospective, blinded, observational	"TUS" (+) POCUS Criteria: Not specified	62 (consecutively)	Clinical suspicion of PE per Sx (dyspnea, pleuritic chest pain, hemoptysis, syncope or vertigo, tachypnea)  Received both CTPA and TUS	Not reported	30 (48%)	31 (50%) – alone 39 (63%)	CTPA (single-row, spiral)  Other criteria: high clinical suspicion, positive V/Q scan and positive D-dimer	77%	91%
Mathiis et al [26]	2005	Prospective, multicenter, blinded, observational	"TUS" (+) POCUS Criteria: 2+ triangular or rounded pleural-based lesions (PE-confirmed) OR 1 of the above typical lesions + corresponding pleural effusion (PE-probable) OR nonspecific subpleural lesions < 5 mm or a single pleural effusion alone (PE-possible)	352 (non-consecutive)	Inpatient and ED referrals from outpatient with "Clinical suspicion of PE under consideration of the risk factors"  Received both CTPA and TUS	DVT but without Sx of PE	144 (41%)	169 (87%) – alone 194 (55%)	CTPA (single-row)  Other criteria: 2 of the following: high clinical suspicion, D-dimer, CUS, echocardiograph y, V/Q scan, PA, or biopsy/necropsy	74%	95%

Pfeill et al [27]	2010	Prospective, blinded, observational	"TUS" (+) POCUS Criteria: Not specified	33 (non-consecutive)	Clinical suspicion of PE per Sx (dyspnea, pleuritic chest pain, hemoptysis, syncope or vertigo, tachypnea) + received both CTPA and TUS.	Not reported	7 (21%)	10 (33%)	CTPA (multi-row, 16)	70%	70%
Comert et al [28]	2013	Prospective, blinded, observational	"TUS" (+) POCUS Criteria: 1+ wedge or triangular-shaped or rounded pleural-based, hypoechoic lesions +/- pleural effusion	50 (consecutively)	"Clinical suspicion of PE under consideration of the risk factors" (Sx included: unexplained dyspnea, tachypnea, pleuritic chest pain, unexplained radiographic and/or blood gas abnormalities) Received TUS and CTPA	Not reported	27 (54%)	30 (60%)	CTPA (multi-row, 64)	90%	60%
Nazerian et al [6]	2014	Prospective, multicenter, blinded, observational	"LUS" (+) POCUS Criteria: 1+ triangular or rounded pleural-based, well-demarcated hypoechoic lesions $\geq 0.5$ cm	357 (consecutively)	Clinical suspicion of PE (Wells score $>4$ , D-dimer $>500$ ) Received both LUS and CTPA	Wells score $<4$ , D-dimer $<500$ ng/mL Consent not obtained CTPA not performed, contra-indicated or inconclusive Pregnancy "Several" diagnoses	77 (22%)	110 (31%)	CTPA (multi-row)	61%	96%
Bataille et al [37]	2014	Prospective, blinded, observational	"LUS" (+) POCUS Criteria: Alveolar consolidation (poorly defined, wedge-shaped hypoechoic structures) RV function measurement (RV dilation, septal eval	136 (consecutively)	Admitted to ICU with Sx of acute respiratory failure (tachypnea, saturations $<90\%$ on room air, PaO <sub>2</sub> $<60$ mmHg, arterial pH $<7.35$ ) Received LUS and appropriate diagnostic evaluation		5 (4%)	13 (10%)	"High resolution CT" as a part of standard medical care.	67%	94%

Acar et al [29]	2017	Prospective, observational	"TUS" (+) POCUS Criteria BLUE protocol used; 3+ B-lines in one area plus wedge sign and/or pleural effusion	100 (convenience)	Clinical suspicion of PE per Sx (sudden onset of shortness of breath, chest pain, unexplained syncope)	Recent trauma Pregnancy Contrast allergy Renal insufficiency (without need for hemodialysis) Unstable Refusal to participate	Not reported	38 (38%)	CTPA (multi-row, 64)	42% (wedge sign) 28% (B-lines) 18% (pleural effusion) *No sensitivity reported for combined criteria.	98%
Ghanem et al [30]	2018	Prospective, multicenter, blinded, observational	"TUS" (+) POCUS Criteria: 1+ typical pleural-based or subpleural hypoechoic lesion +/- pleural effusion	60 (consecutively)	Clinical suspicion of PE (intermediate or high risk per modified Wells score) Received TUS and CTPA	Not reported.	33 (55%)	40 (67%)	CTPA (multi-row, 64)	82% (gray scale)	90% (gray scale)
Mansencal et al [33]	2008	Prospective, blinded, observational	Cardiac (+) POCUS Criteria: RV dilation (RV to LV area ratio was >0.6)	76 (consecutively)	Clinical suspicion of PE (Sx include dyspnea or chest pain) Received cardiac ultrasound (echocardiograph) and CTPA.	Low or moderate clinical probability per Wells D-dimer <500 ng/mL Creatinine clearance > 30 mL/min	41 (40%)	31 (30%)	CTPA (multi-row) +/- V/Q scan if CTPA negative	55%	69%
Daley et al [22]	2017	Prospective, blinded, observational cohort	Cardiac (FOCUS) (+) POCUS Criteria: Any FOCUS exam criteria found (TAPSE <17 mm, RV dilation compared to LV, septal flattening, TV regurgitation or McConnell's sign)	150 (convenience)	Clinical suspicion of PE (Sx not reported) Received cardiac ultrasound (echocardiography) and CTPA	Prisoners or wards of the state Non-English speaking	Not provided for each category	32 (21%)	CTPA (multi-row)	56% (TAPSE 17 mm) 72% (TAPSE 20 mm) 37% (RVD) 31% (D sign) 43% (TR) 13% (McConnell sign)	79% (TAPSE 17 mm) 66% (TAPSE 20 mm) 85% (RVD) 94% (D sign) 80% (TR) 97% (McConnell sign)
Dwyer et al [23]	2018	Prospective, multicenter, blinded, observational	Cardiac (FOCUS) (+) POCUS Criteria: Any FOCUS exam criteria found (TAPSE <17 mm, RV dilation with ratio of	199 (convenience)	Clinical suspicion of PE (Sx not reported) Received cardiac ultrasound (echocardiography) and CTPA	Prisoners Non-English speaking Unable to receive CTPA	22 (11%)	46 (23%); (25 peripheral PE (20 central PE)	CTPA (# rows not specified)	48% (any location) 90% (central)	88% (any location)

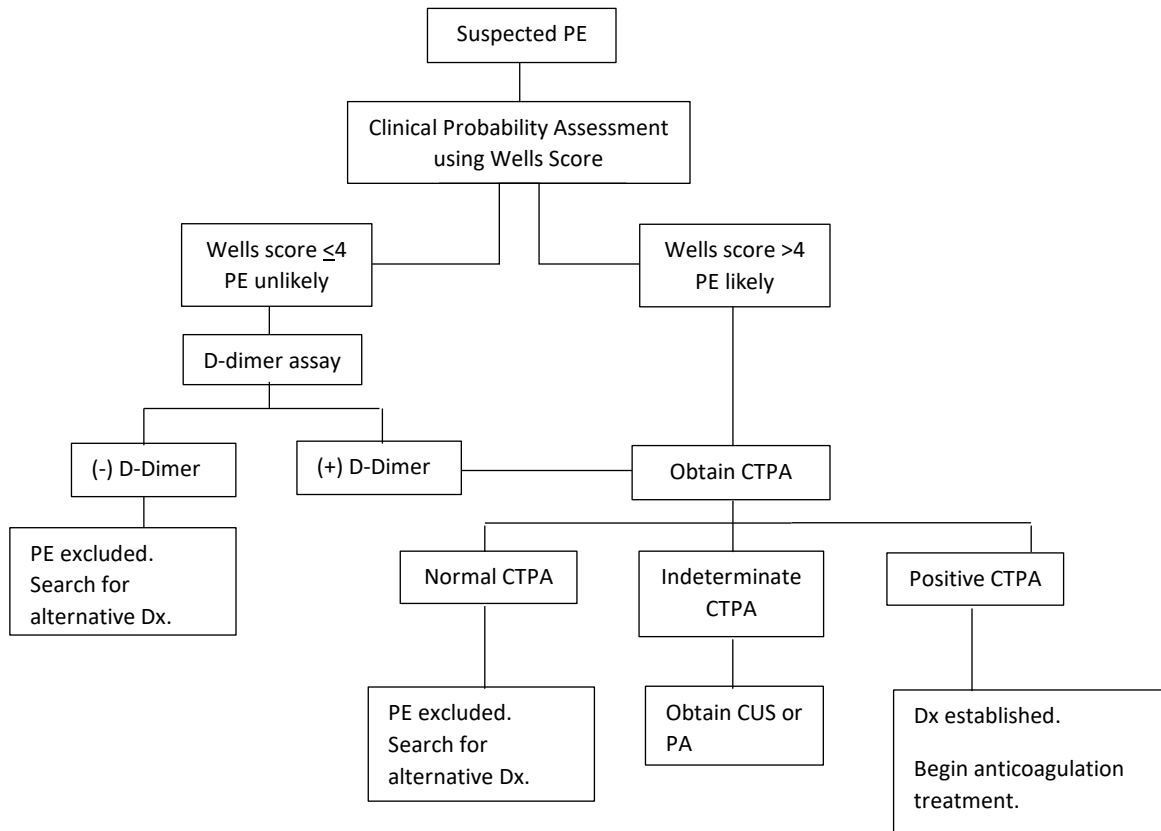
Filipiak-Strzecka et al [34] *	2018	Prospective, blinded, observational	RV to LV dilation >1, septal flattening, or McConnell's sign)	Cardiac (+) POCUS Criteria: RV enlargement (diameter >41 mm)	100 (consecutively)	Clinical suspicion of PE (Sx of dyspnea, chest pain, cough, tachycardia) Received cardiac ultrasound (echocardiography) and CTPA	Not reported	59 (59%)	24 (24%)	CTPA (# rows not specified)	92%	51%
Mansencal et al [33] *	2008	Prospective, blinded, observational	Multiorgan (Cardiac + CUS)	Multiorgan (+) POCUS Criteria: RV to LV area ratio was >0.6 and/or venous incompressibility	76 (consecutively)	Clinical suspicion of PE (Sx include dyspnea or chest pain) Received cardiac ultrasound (echocardiography) and CUS	Low or moderate clinical probability per Wells D-dimer <500 ng/mL Creatinine clearance > 30 mL/min	41 (40%)	31 (30%)	CTPA (multi-row); +/- V/Q scan if CTPA negative	87%	69%
Lichtenstein et al [17]	2008	Prospective, blinded, observational	Multiorgan (LUS + Vascular/CUS) "The Blue protocol"	(+) POCUS Criteria: Predominant, anterior, bilateral A-lines plus venous incompressibility	260 (consecutively)	Presented with Sx of acute respiratory failure (Sx of dyspnea) Received LUS, CUS and standard diagnostic tests (helical CT)	Not reported	17 (6.5%)	21 (8%)	"Helical CT" (row details not specified) + CUS	81%	99%
Koenig et al [12]	2014	Prospective, blinded, observational	Multiorgan (Triple POCUS: TUS+ Cardiac + Vascular/CUS)	(+) POCUS Criteria: A pattern, alveolar consolidation or pleural effusion OR RV size, function, septal kinetics, LV function OR lack of compression	96 (convenience)	Clinical suspicion of PE in ED or inpatient CTPA, TUS, CUS and echocardiography exams completed.	Unable or declined to receive CTPA Pregnancy No consent	Not reported	12 (12.5%)	CTPA (multi-row)	Not reported	Not reported
Nazerian et al [6] *	2014	Prospective, Multicenter, blinded, observational	Multiorgan (Triple POCUS: LUS+ Cardiac + Vascular/CUS)	(+) POCUS Criteria: 1+ triangular or rounded pleural-based, well-demarcated hypochoic consolidations of $\geq 0.5$ cm OR RV dilation or	357 (consecutive)	Clinical suspicion for PE with Wells score >4, D-Dimer >500 ng/mL Received LUS, Cardiac ultrasound, CUS and CTPA	Wells score $\leq 4$ D-dimer <500 ng/mL	133 (37%)	110 (31%)	CTPA (multi-row)	90%	86%

Author	Year	Study Design	Population	Intervention	Comparison	Primary Outcome	Secondary Outcome	Number of Patients	Number of Events	Number of Events (%)	Number of Events (%)	Number of Events (%)	Number of Events (%)	Number of Events (%)	Number of Events (%)
Bataille et al [37]	2014	Prospective, blinded, observational	thrombi in right cavity OR DVT found on CUS	Multiorgan (LUS + Cardiac)	(+ POCUS Criteria: Alveolar consolidation (poorly defined, wedge-shaped hypoechoic structures) OR RV function measurement (RV dilation, septal abnormalities)	136 (consecutive)	Admitted to ICU with Sx of acute respiratory failure (tachypnea, desat <90% on room air, PaO2 <60 mmHg, arterial pH <7.35)	Patients with several final diagnoses for Sx.	5 (4%)	13 (10%)	"High resolution CT"	83%	84%		
Zanobetti et al [36]	2017	Prospective, blinded, observational	Multiorgan (LUS + Cardiac)	(+ POCUS Criteria: 2+ two or more triangular or rounded pleural-based lesions (indicating a pulmonary infarction) or RVD (RV to LV ratio >1)	2683 (consecutive)	Presented with Sx of acute dyspnea	Dyspnea of traumatic origin	41 (1.5%)	95 (4%)	"Contrast CT"	40%	100%			
Dwyer et al [23]	2018	Prospective, multicenter, blinded, observational	Multiorgan (FOCUS/cardiac + CUS)	(+ POCUS Criteria: Any FOCUS exam criteria found (TAPSE <17 mm, RVD with ratio of RV to LV dilation >1, septal flattening, or McConnell's sign) OR venous incompressibility	199 (convenience)	Received cardiac ultrasound (echocardiography), CUS and CTPA	Prisoners Non-English speaking Unable to receive CTPA	32 (both) Vs 22 (FOCUS) 20 (CUS)	46 (23%) for both 26 (peripheral PE) 20 (central PE)	CTPA (# rows not specified)	46% (peripheral) 100% (central)	Not provided			
Filipiak-Strzecka et al [34]	2018	Prospective, blinded, observational	Multiorgan (Cardiac + CUS)	(+ POCUS Criteria: RVD (diameter >41 mm) and/or venous incompressibility	100 (consecutively)	Clinical suspicion of PE (Sx of dyspnea, chest pain, cough, tachycardia)	Not reported	15 (CUS) 59 (Cardiac)	24 (24%)	CTPA (# rows not specified)	54% (both) 92% (either)	100% (both) 49% (either)			

\*Studies in which combined multiorgan POCUS sensitivity was compared to the sensitivity of the individual POCUS components

Abbreviations: PE (pulmonary embolism), POCUS (point-of-care ultrasound), CTPA (computed tomography pulmonary angiography), CT (computed tomography), PA (pulmonary angiography), Sx (symptoms), LUS (lung ultrasound), TUS (thoracic ultrasound), CUS (compression ultrasound), FOCUS (focused cardiac ultrasound), V/Q (ventilation perfusion), TAPSE (tricuspid annular plane systolic excursion), RV (right ventricle), LV (left ventricle), RVD (right ventricular dilation), TR (tricuspid regurgitation)

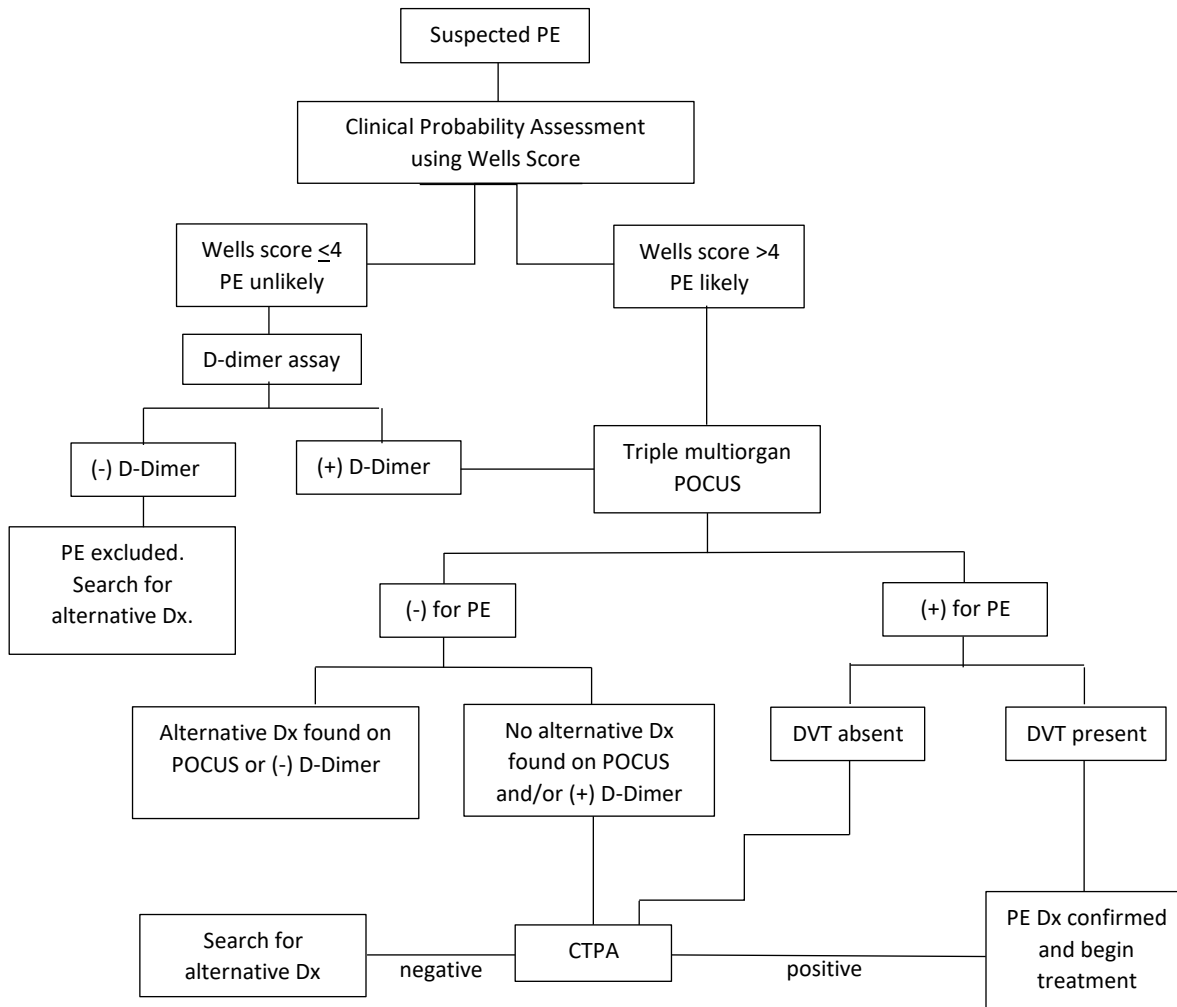
**Figure 1. Current Diagnostic Algorithm for Pulmonary Embolism.**



Abbreviations: PE (pulmonary embolism), Dx (diagnosis), CTPA (computed tomography pulmonary angiography), CUS (compression ultrasound), PA (pulmonary angiography)

Adapted from Papadakis MA, McPhee SJ, Rabow MW. *Current Medical Diagnosis and Treatment*. 57<sup>th</sup> ed. New York, NY: McGraw Hill Education; 2018: 304.

**Figure 2. Proposed diagnostic algorithm for pulmonary embolism incorporating triple multiorgan POCUS**



Abbreviations: PE (pulmonary embolism), Dx (diagnosis), POCUS (point-of-care ultrasound), CTPA (computed tomography pulmonary angiography), CUS (compression ultrasound), PA (pulmonary angiography), DVT (deep vein thrombosis)

Adapted from Nazerian P, Vanni S, Gigli C, et al. Accuracy of point-of-care multiorgan ultrasonography for the diagnosis of pulmonary embolism. *Chest*. 2014;145(5):950-957. doi:10.1378/chest.13-1087



# AUGSBURG UNIVERSITY

## Augsburg University Institutional Repository Deposit Agreement

By depositing this Content ("Content") in the Augsburg University Institutional Repository known as Idun, I agree that I am solely responsible for any consequences of uploading this Content to Idun and making it publicly available, and I represent and warrant that:

- I am *either* the sole creator or the owner of the copyrights in the Content; or, without obtaining another's permission, I have the right to deposit the Content in an archive such as Idun.
- To the extent that any portions of the Content are not my own creation, they are used with the copyright holder's expressed permission or as permitted by law. Additionally, the Content does not infringe the copyrights or other intellectual property rights of another, nor does the Content violate any laws or another's right of privacy or publicity.
- The Content contains no restricted, private, confidential, or otherwise protected data or information that should not be publicly shared.

I understand that Augsburg University will do its best to provide perpetual access to my Content. To support these efforts, I grant the Board of Regents of Augsburg University, through its library, the following non-exclusive, perpetual, royalty free, worldwide rights and licenses:

- To access, reproduce, distribute and publicly display the Content, in whole or in part, to secure, preserve and make it publicly available
- To make derivative works based upon the Content in order to migrate to other media or formats, or to preserve its public access.

These terms do not transfer ownership of the copyright(s) in the Content. These terms only grant to Augsburg University the limited license outlined above.

Initial one:

I agree and I wish this Content to be Open Access.

I agree, but I wish to restrict access of this Content to the Augsburg University network.

Work (s) to be deposited

Title: Sensitivity of single organ versus multiorgan point-of-care ultrasound compared to computed tomography pulmonary angiography in detecting pulmonary embolism in adult patients

Author(s) of Work(s): Jessica Stangenes, PA-S and Eric Barth, PA-C

Depositor's Name (Please Print): Jessica Stangenes

Author's Signature:  Date: 8/6/2019

If the Deposit Agreement is executed by the Author's Representative, the Representative shall separately execute the following representation.

I represent that I am authorized by the Author to execute this Deposit Agreement on the behalf of the Author.

Author's Representative Signature: \_\_\_\_\_ Date: \_\_\_\_\_