

University of Louisville
ThinkIR: The University of Louisville's Institutional Repository

Electronic Theses and Dissertations

5-2019

Alterations in rhythmic licking behaviors following fibrosis in the rat mylohyoid muscle.

Brittany Fletcher
University of Louisville

Follow this and additional works at: <https://ir.library.louisville.edu/etd>

 Part of the [Speech Pathology and Audiology Commons](#)

Recommended Citation

Fletcher, Brittany, "Alterations in rhythmic licking behaviors following fibrosis in the rat mylohyoid muscle." (2019). *Electronic Theses and Dissertations*. Paper 3213.
<https://doi.org/10.18297/etd/3213>

This Master's Thesis is brought to you for free and open access by ThinkIR: The University of Louisville's Institutional Repository. It has been accepted for inclusion in Electronic Theses and Dissertations by an authorized administrator of ThinkIR: The University of Louisville's Institutional Repository. This title appears here courtesy of the author, who has retained all other copyrights. For more information, please contact thinkir@louisville.edu.

ALTERATIONS IN RYTHMIC LICKING BEHAVIORS FOLLOWING FIBROSIS IN
THE RAT MYLOHYOID MUSCLE

By

Brittany Fletcher

B.A.- Bellarmine University, Louisville, KY, May 2016

A Thesis
Submitted to the Faculty of the
School of Medicine of the University of Louisville
in Partial Fulfillment of the Requirements
for the Degree of

Master of Science
in Communicative Disorders

Department of Otolaryngology Head and Neck Surgery and Communicative Disorders
University of Louisville
Louisville, Kentucky

May 2019

© 2019
Brittany Fletcher
All rights reserved

ALTERATIONS IN RYTHMIC LICKING BEHAVIORS FOLLOWING FIBROSIS IN
RAT MYLOHYOID MUSCLE

By

Brittany Fletcher

B.A.- Bellarmine University, Louisville, KY, May 2016

A Thesis Approved on

April 22, 2019

by the following Thesis Committee:

Suzanne King, Ph.D., Thesis Advisor

Teresa Pitts, Ph.D.

Alan Smith, Ed.D.

Rhonda Mattingly, Ed.D.

DEDICATION

To my Mom

ACKNOWLEDGMENTS

I would like to express my gratitude to my thesis advisor, Dr. Suzanne King for the insightful comments, remarks, and engagement through the learning process of this master's thesis. I would also like to thank Dr. Pitts, Dr. Smith, and Dr. Mattingly for their guidance as my thesis committee.

I would like to thank the University of Louisville School of Medicine's Department of Otolaryngology Head and Neck Surgery and Communicative Disorders professors and staff for providing me with the knowledge and experience to make an impact in this career.

Lastly, I would like to thank my mother, step-father, grandparents, and friends who have supported me throughout the entire process, both by keeping me harmonious and helping me putting pieces together. I will be grateful forever for your love.

ABSTRACT

ALTERATIONS IN RHYTHMIC LICKING BEHAVIORS FOLLOWING FIBROSIS IN RAT MYLOHYOID MUSCLE

Brittany Fletcher

April 22, 2019

Muscle injury is a common side effect of radiation treatment for head and neck cancer. To increase understanding of muscle injury related dysfunction, we investigated the effects of oral swallowing function after cryoinjury to mylohyoid muscle in rats. The hypothesis is that injury to the mylohyoid delays the temporal licking pattern, resulting in aberrant drinking behaviors. Six rats received bilateral mylohyoid injuries by applying a 3mm cryoprobe. Licking behavior was measured by electrophysiological recordings of rhythmic tongue movements in a ten-minute drinking session taken pre-and post-injury (one-and two-weeks). Lick frequency and total licks per cluster decreased significantly one-and two-weeks post-injury compared to pre-injury (both $p < 0.03$). Cluster size also significantly reduced ($p < 0.05$) and the number of clusters performed increased post-injury ($p = 0.002$). Results demonstrate that injury to the mylohyoid muscle leads to aperiodicity of licking behaviors likely attributed to delays in tongue motility.

TABLE OF CONTENTS

	PAGE
ACKNOWLEDGMENTS	IV
ABSTRACT	V
INTRODUCTION	1
Radiation-Induced Dysphagia.....	5
Radiation Injury	7
Muscle Fibrosis	8
Mylohyoid Muscle	9
Rat Licking Behavior	12
Model of Fibrosis	15
Objective	17
Hypothesis.....	17
METHODS	18
Mylohyoid Cryoinjury Procedure	18
Histology.....	19
Lick Testing	19
Statistical Analysis.....	21
RESULTS	23
Licking Frequency	23
Clusters	24
Microstructures	25
DISCUSSION	29
Limitations	34
Conclusion and Future Direction	35
REFERENCES	36
APPENDIX: ABBREVIATIONS	44
CURRICULUM VITAE.....	45

CHAPTER 1

INTRODUCTION

Approximately 63,000 Americans are diagnosed with head and neck cancer (HNC) annually (Siegel, Miller, & Jemal, 2018). Of these, oral and pharyngeal cancers have the highest incidence of occurrence (Siegel, Miller, & Jemal, 2018). Patients with HNC typically receive radiation-based therapies, which can result in swallowing mobility disorders (dysphagia). These are a devastating consequence of radiation-based treatments affecting ~30-50% of patients (Caudell, Schaner, Meredith, Locher, Nabell, Carroll, Magnuson, Spencer, & Bonner, 2009; Machtay, Moughan, Trotti, Garden, Webber, & Cooper, 2008; Russi, Corvò, Merlotti, Alterio, Franco, Pergolizzi, De Sanctis, Redda, Ricardi, Paiar, Bonomo, Merlano, Zurlo, Chiesa, Sanguineti, & Bernier, 2012; Schindler, Denaro, Russi, Pizzorni, Bossi, Merlotti, Bissetti, Numico, Gava, Orlandi, Caspiani, Buglione, Alterio, Bacigalupo, De.Sanctis, Pavanato, Ripamonti, Merlano, Lictria, Sanguineti, Langendijk, & Murphy, 2015). Aberrant features include reduced base of tongue retraction, delayed pharyngeal transit time, decreased pharyngeal contraction, incomplete hyoid bone elevation, increased stasis of oral/pharyngeal mucosa, and abnormal upper esophageal sphincter (UES) function (Lin, Hsiao, Chang, Ting, Chen, Chen, & Wang, 2011) (Pei-Hung Lin, 2011). As a result, patients may require compensatory strategies, diet modification, or enteral feeding to prevent malnutrition and/or reduce their risk of aspiration, which can significantly hinder their quality of life. Determining the effects of muscle injury on the behaviors of deglutition (i.e. licking,

swallowing) will provide a more detailed understanding of the problem, which may help improve treatment strategies. The objective of this thesis project is to explore the effects of mylohyoid muscle injury on licking behavior.

Swallowing

Swallowing is a voluntary and automatic response required for the transport of food and liquid from the oral cavity into the stomach (Walton & Silva, 2018).

There are three phases of swallowing, oral, pharyngeal, and esophageal phases. It is driven by sensory information transmitted from the trigeminal (V), glossopharyngeal (IX), and vagus (X) nerves (Sinclair, 1970). The oral phase of swallowing is voluntary and can be interrupted at any time, whereas the pharyngeal phase is involuntary.

Reflexive swallowing is controlled by neural networks that can initiate rhythmic muscle activity without the need of sensory feedback, known as central pattern generators (CPGs). The swallowing CPG is a network of premotor neurons (PMNs) that organizes the sequential activity of swallowing motoneurons active within the medulla (Jean, 2001). Licking behavior consists of rapid rhythmic tongue movements in rats (Davis & Smith, 1992b), innervated by the hypoglossal nerve and controlled by the CPG located within the medulla (Boughter Jr, Baird, Bryant, St. John, & Heck, 2007). Pharyngeal swallowing reflex can be initiated by stimulation of the internal branch of the superior laryngeal nerve (SLN) and CN IX nerve (Doty, 1968). The swallowing CPG can be influenced by sensory input from cranial nerves innervating the licking and swallowing muscles, resulting in adaptations to bolus size, acidity, temperature, etc. (Bazett, Oxon, Eng, Penfield, & Oxon, 1922). CN V motor neurons innervate submental muscles, such as the mylohyoid muscle. Within the swallowing CPG, some neurons may co-participate in other activities, such as respiration, chewing, and licking. Motoneurons and interneurons

can be involved in at least two different tasks, such as licking and swallowing (Jean, 2001).

Radiation-induced dysphagia refers to significant impairments within the oral and pharyngeal stages of swallowing (King, Dunlap, Tennant, & Pitts, 2016). The submental muscles play a major role during oral and pharyngeal swallowing phases, facilitating tongue displacement and hyolaryngeal elevation (Crompton, Cook, Hiiemae, & Thexton, 1975; Spiro, Rendell, & Gay, 1994). These muscles include the anterior belly of digastric, geniohyoid, and the mylohyoid (Crompton, Cook, Hiiemae, & Thexton, 1975). Specifically, the mylohyoid muscle assists with the elevation and depression of the hyoid bone (Spiro, Rendell, & Gay, 1994). The hyoid bone is attached to laryngeal cartilage; therefore, elevation of the hyoid moves the larynx in anterior and superior direction corresponding with vocal fold closure, epiglottic retroflexion and subsequent movement of the bolus through the upper airway. Thus, providing complete airway protection during swallowing (Dodds, Stewart, & Logemann, 1990).

Oral Phase

The oral phases encompass formation and mastication of the bolus requiring displacement of the mandible and tongue to adequately prepare the bolus for transportation. Muscular structures controlled by the cerebellum (Dodds, Stewart, & Logemann, 1990), including the tongue, lips, and mandible coordinate chewing and licking movements to break down food and form the bolus into one cohesive structure. As the bolus mixes with saliva it is positioned in a middle groove of the tongue while the posterior portion of the tongue is pressed against the soft palate. Simultaneously, the tongue tip is against the maxillary incisors to form a seal and prevent premature entry of the bolus into the pharynx (Dodds, Taylor, Stewart, Kern, Logemann, & Cook, 1989).

Clinically important actions which occur during this phase include rotary jaw motion, rotary and lateral tongue motion, and anterior bulging of soft palate. These movements coordinate to allow for adequate formation of the bolus and prevent anterior or posterior spillage. The oral phase involves the initial propulsion of the bolus from the oral cavity into the pharynx. Initially, the tongue tip elevation makes contact with the hard palate. The tongue continues to forcefully move posteriorly to thrust the bolus towards the oropharynx.

Pharyngeal Phase

The pharyngeal phase of swallowing involves multiple muscles for the bolus to safely pass the airway and enter the esophagus. Specifically, the pharyngeal swallow reflex causes a chain reaction resulting in elevation of the soft palate, elevation of the larynx, closure of the vocal folds, epiglottic retroflexion over the laryngeal lumen, and relaxation of the cricopharyngeus muscle. The pharyngeal swallowing reflex is triggered by CN IX and X, resulting in the posterior movement of the tongue towards the anterior faucial arch (Dodds, Stewart, & Logemann, 1990). Simultaneously, the base of the tongue expands the hypopharynx by moving down and forward to provide sufficient access for the bolus to flow into the pharynx. The flattening and forward movement of the posterior tongue allows for the bolus to slide into the pharynx. Superior movement of the palate opens the area between the oral and pharyngeal cavities to facilitate bolus flow (Rubesin, Jones, & Donner, 1987). To prevent nasal regurgitation, the palate creates contact with the posterior pharyngeal wall to seal off the nasopharynx. Additionally, the posterior tongue, hyoid, and larynx move upward and forward to expand the pharynx. The submental muscles elevate the hyoid and thus, the larynx to allow for airway protection (Walton & Silva, 2018). Coordination between swallowing and respiration is

critical during this phase because in adults, respiration is halted for about one second for the bolus to pass into esophagus.

Radiation-Induced Dysphagia

Dysphagia after HNC treatment effects over 59% of patients (Nguyen, Sallah, Karlsson, & Antoine, 2002). Radiation treatment for HNC can lead to swallowing mobility problems that affect the oral and pharyngeal phases of swallowing, resulting in increased risk of aspiration (Pauloski, 2008). Key indicators of dysphagia include: coughing/choking or regurgitation, difficulty or avoidance of certain foods, poor nutrition, presence of a feeding tube, and a history of pneumonia or respiratory disease (Raber-Durlacher, Brennan, Verdonck-de Leeuw, Gibson, Eilers, Waltimo, Bots, Michelet, Sollecito, Rouleau, Sewnaik, Bensadoun, Flidner, Silverman Jr, & Spijkervet, 2012).

Radiation-based treatments for HNC can affect the mobility of the tongue, larynx and pharynx (Pauloski, 2008). Hutcheson performed modified barium swallow studies on laryngeal carcinoma patients six-twelve months following radiation therapy. Findings demonstrated that radiation to the larynx can result in discoordination, delayed or absent pharyngeal reflex, decreased epiglottic inversion, decreased hyolaryngeal elevation, reduced pharyngeal peristalsis, and cricopharyngeal sphincter dysfunction during swallowing (Hutcheson, Barringer, Rosenthal, May, Roberts, & Lewin, 2008). These results demonstrate that radiation injury can lead to significant impairments in swallowing function. Manikantan et al (2009) found that impaired hyolaryngeal motion, incomplete epiglottic inversion, and reduced base of tongue retraction were among the most prevalent abnormalities found post radiation treatment for laryngeal carcinoma. The radiation dose and amount of tissue volume exposed to radiation plays a major role in the

severity of injury and associated fibrosis that can develop (Straub, New, Hamilton, Lominska, Shnayder, & Thomas, 2015).

Starmer et al (2015) compared the effects of radiation dose to the floor of mouth muscles to the constrictor muscles as measured by Penetration Aspiration Scale scores (PAS). Results concluded radiation to the floor of mouth muscles, specifically the geniohyoid, are a primary concern for dysphagia after treatment for oropharyngeal cancers. Based on videofluoroscopic swallowing studies patients with increased PAS scores were strongly correlated with higher radiation doses to the geniohyoid and floor of mouth muscles, suggesting an organ at risk for injury induced dysphagia (Starmer, Quon, Kumar, Alcorn, Murano, Jones, & Humbert, 2015). Kumar et al (2014) also studied the effects of radiation for treatment of oropharyngeal squamous cell carcinoma patients. This work demonstrated that a median dose of 70 Gy to the floor of mouth muscles (geniohyoid, mylohyoid, and anterior belly of the digastric) correlated with declines in swallowing function. Specifically, videofluoroscopy swallow studies taken approximately 6-months post-radiation, showed that minimum and mean radiation doses to the floor of mouth muscles can result in abnormal PAS scores. Together these studies indicate that injury to the floor of mouth muscles likely inhibits swallowing function.

The placement of a percutaneous endoscopic gastrostomy (PEG) is commonly prescribed for patients to maintain adequate nutrition. In a study conducted by Kumar et al (2014) 91% patients were given a PEG post radiation treatment, with 50% of these patients becoming PEG dependent after radiation treatment. Manikantan et al (2009) found that 78% of HNC patients required feeding tube-placement at some point over the course of radiation treatment. Morton et al (2009) surveyed 36 head and neck cancer

patients' being treated primarily with chemoradiation for differences in weight, age, tumor type, details of PEG insertion, and feeding regimens. The survey included the Performance Status Scale, the Functional Measure for Swallowing, Nutritional Mode and a self-assessment of Quality of Life. Although improvement in body mass index were seen within one-month post PEG implementation, declines in quality of life were observed due to problems associated with speech and swallowing dysfunction. Longer PEG duration correlated with poorer performance status and swallowing function, as well as, predicted poorer overall quality of life and poorer swallowing and speech function (Morton, Crowder, Mawdsley, Ong, & Izzard, 2009).

Radiation Injury

The three primary types of radiation injuries include: acute (during or shortly after radiation), subacute or early-delayed (typically up to twelve weeks after radiation), and late (months to years after completion of radiation) (Walker, Ruzevick, Malayeri, Rigamonti, Lim, Redmond, & Kleinberg, 2014). Acute and subacute effects result in cell death and inflammation. Specifically, radiation injury breaks down the mucosa barrier resulting in inflammation and necrosis of the lamina propria. Depending on severity of the ulceration or dose/duration of treatment, acute problems can progress into consequential late injuries.

In some cases, late radiation injuries can present months to years after treatment even without the onset of acute problems. These late radiation injuries are thought to be caused by damage to vasculature and connective tissue that gradually worsen over time. Acute injuries resolve within a few weeks post radiation therapy, however subacute and late term injuries take time to develop and may lead to chronic impairments (King, Dunlap, Tennant, & Pitts, 2016; Naoko Saito, 2012). Long-term changes may be

associated with persistent oxidative damages that have been shown to be a key characteristic in radiation injury (Shaw, Skoretz, O'Sullivan, Hope, Liu, & Martino, 2016). In the head and neck muscles, previous reports using MRI have demonstrated that radiation can result in fibrosis in pharyngeal constrictors as seen by significant increase in tissue inflammation and edema 3-months post radiation (Popovtzer, Cao, Feng, & Eisbruch, 2009).

Muscle Fibrosis

Previous reports have proposed that muscle fibrosis causes swallowing mobility problems, however very little is known about the changes that occur to muscle tissue after radiation. Fibrosis is a complex tissue response resulting in excessive fibroblast production and subsequent, deposits of extracellular matrix. Fibrosis is the result of a lack of feedback regulations of fibroblast productions causing chronic myofibroblast activation to occur. One possible origin of the chronic cellular activation could be an abnormal production of stimulating factors such as cytokines and growth factors. In this context, fibrosis could be defined as a wound where continuous signals for tissue repair are emitted (Martin, Lefaix, & Delanian, 2000). An injury to the muscle elicits inflammatory response, which can increase the expression of transforming growth factor β 1 (TGF- β 1) (Moloney, Brunner, Alexander, & Clark, 2014). TGF-b1 regulates the deposition of extracellular matrix components, such as collagen, which is key component in the production of fibrosis. TGF-b1 has a central role in development and normal wound healing by stimulating cells to produce matrix proteins and increasing the production of inhibitors. Martin et al (Martin, Lefaix, & Delanian, 2000) has shown that TGF-b1 is a key molecule and a master switch for the general fibrotic program. It was

proposed that deregulations of the activities of this cytokine could be involved in the development of fibroproliferative diseases after radiation injury.

Mylohyoid Muscle

The submental muscles are composed of the mylohyoid, anterior belly of the digastric, and the geniohyoid. Of these muscles, mylohyoid plays a crucial role in several behaviors, including chewing, licking, swallowing, respiration, and phonation (Mu, Su, Wang, Han, & Sanders, 2004; Ren & Mu, 2005). To carry out these behaviors, the mylohyoid depresses the mandible and/or elevates the hyoid bone (Groher, 1997). The mylohyoid is a paired muscle, which lies between the anterior belly of the digastric muscle ventrally and the geniohyoid muscle dorsally. It forms a muscular diaphragm across the floor of the mouth (Mu, Su, Wang, Han, & Sanders, 2004), arising from the inner surface of the body of the mandible and running horizontally toward contralateral muscle meeting at the midline raphe (Otonari-Yamamoto, Nakajima, Tsuji, Otonari, Curtin, Okano, & Sano, 2010). It receives sensory and motor innervation via the inferior alveolar branch of the CN V nerve with cell bodies located in the trigeminal ganglion. Previous work has demonstrated connections between CN V pathways and the nucleus tractus solitarius of the medulla oblongata, which is an important area controlling swallowing function (Paton, 1999).

The mylohyoid is one of the first muscles to become active during the pharyngeal phase of swallowing (Gallas, Moirot, Debono, Navarre, Denis, Marie, & Verin, 2007; Mu, Su, Wang, Han, & Sanders, 2004; Spiro, Rendell, & Gay, 1994; Vitti & Basmajian, 1977). It is also actively involved in chewing and licking activity (Schwartz, Enomoto, Valiquette, & Lund, 1989; Yamada, Haraguchi, Uchida, & Meng, 1993). During the process of licking and chewing, the mylohyoid facilitates jaw closing movement. In the

rat, jaw closure occurs simultaneously with tongue extraction during licking. As observed through EMG, there is an increase in mylohyoid activity during singing or sustained phonation to raise pitch as well as during phonation of velar stops such as /k/ and vowels /i/ and /u/ (Faaborg-Andersen & Vennard, 1964) . During the process of deglutition, the mylohyoid along with the remaining floor of mouth musculature move the hyoid forward and upward resulting in the raising of the floor of the mouth and the base of the tongue as well as depression of the mandible (Crompton, Cook, Hiimae, & Thexton, 1975).

Previous research has shown that the composition of the mylohyoid muscle consists of anterior and posterior portions, each thought to have a unique function (Otonari-Yamamoto, Nakajima, Tsuji, Otonari, Curtin, Okano, & Sano, 2010). Fibers composing the anterior three-fourths of mylohyoid run horizontally and insert into the mylohyoid raphe at the midline. Posterior fibers make up approximately one-fourth of the mylohyoid and travel obliquely, inserting into the front of the body of the hyoid bone (Ren & Mu, 2005). Lehr et al (1971) used EMG to investigate the role of the mylohyoids in isolated movements of the tongue and mandible during various functions. While both sections of the mylohyoid are active during mandibular movement, the anterior portion plays a greater role in protruding and retracting the mandible. However, both anterior and posterior aspects of mylohyoid facilitate elevation and retraction of the tongue.

Previous work has differentiated skeletal muscle fibers based on their myosin heavy-chain (MHC) isoforms, which helps categorize the contraction speed of the muscle. There are four major types, including: type I, type IIA, type IIB, and type IIX. There are two general fiber types a slow twitch (type I) and fast twitch (type II). The slow muscle fibers contract slowly and are seen in tonic movement, while the fast muscle

fibers contract rapidly and are observed with a phasic movement (Mu, Su, Wang, Han, & Sanders, 2004). The type I and type IIa MHC isoforms are seen in muscles used for postural adjustment and endurance, however the types IIx and IIb isoforms are observed in muscles used for short-duration and high-intensity power output activity (Mu, Su, Wang, Han, & Sanders, 2004). Mu et al (2004) determined that the mylohyoid is composed of 15% pure MHC fibers and 85% hybrid MHC fibers. Pure fiber types that comprise the mylohyoid are the slow type I (54% of fibers) and fast type II (46% of fibers). Of the fast fiber types, type IIa comprises 92% and type IIx comprises 8%. M/u hybrid fibers constitute the predominant fiber types in the adult human MH muscle, the most common m/u hybrid fiber types were found to be the MHC I/slow-tonic/cardiac (39% of the total fiber population) and MHC IIa/neonatal (33% of the total fiber population) Mu et al (2004) also categorized unusual MHC fiber types into four areas using immunocytochemistry: slow-tonic, cardiac, embryonic, and neonatal. Hybrid fiber types consist of two categories: (m/m) major-major hybrids (a combination of 2 majors: type I, type IIA, type IIB, and type IIX) and (m/u) major-unusual hybrids (a combination of one major: type I, type IIA, type IIB, or type IIX and one unusual: slow-tonic, cardiac, embryonic, or neonatal). These hybrid fibers in the mylohyoid are thought to help the muscle perform several unique functions involved in deglutition (Ren & Mu, 2005). The various combinations of hybrid fiber types in the mylohyoid are believed to provide precise muscle movements, maximal force in a short velocity, and postural and endurance capabilities of the muscle required to displace and stabilize the mandible and hyoid bones (Mu, Su, Wang, Han, & Sanders, 2004; Ren & Mu, 2005).

Innervation by several branches of the mylohyoid nerve derived from the mandibular division of the trigeminal nerve supply the mylohyoid (Paton, 1999). Each of the nerve branches supply a distinct region of the muscle, forming a segmental innervation pattern (Ren & Mu, 2005). The mylohyoid nerve enters in the posterior aspect of the mylohyoid muscle innervating the muscular branches of both the mylohyoid and anterior belly of the digastric muscle. Once reaching the muscle, the mylohyoid nerve divides into a medial and lateral divisions. The medial division consists of five to seven branches: two supply the posterior portion of the mylohyoid, two to three innervate the middle portion of the mylohyoid, one to two supply the most anterior portion of mylohyoid, and one supplies the anterior belly of the digastric muscle. The lateral division of the mylohyoid nerve also consists of a cutaneous branch to the skin in the submental region and a muscular branch to the most anterior part of the mylohyoid (Ren & Mu, 2005).

Rat Licking Behavior

The licking behavior of rats consists of rapidly rhythmic tongue movements (Davis & Smith, 1992b), occurring at a frequency of 6-8 Hz (Bin Lin, Pierce, Light, & Hayar, 2013; Malmo, Malmo, & Weijnen, 1986). These reflexive tongue movements are controlled by a central pattern generator located within the brainstem (Boughter Jr, Baird, Bryant, St. John, & Heck, 2007). Rat licking behavior is thought to be highly consistent, with minimal changes. Specifically, tongue movements are controlled by the hypoglossal nucleus of the medulla oblongata through the hypoglossal cranial nerve (Malmo, Malmo, & Weijnen, 1986). Studies have shown that tongue retraction was controlled by neurons in the dorsal part of the hypoglossal nucleus, whereas protrusion-related activity was seen in the ventral portion (Malmo, Malmo, & Weijnen, 1986). In the rat, the tongue

displacement involves movement of mandible and thus, likely involves activity of other cranial muscles.

Previous work has characterized the microstructure of the rats licking behavior (Boughter Jr, Baird, Bryant, St. John, & Heck, 2007; Davis & Smith, 1992b). Based on these studies, licking behavior can be measured via the following parameters: licking frequency, cluster size, clusters/ten-minute drinking session, licks/cluster, contact duration (CD), intercontact interval (ICI), interlick interval (ILI). Contact duration is measured by the amount of time the tongue is in contact with the metal spout, so a decline in this measure indicates the length of contact with the spout during licks has decreased. Intercontact interval is the period which the tongue was not in contact with the spout, therefore an increase in this measure indicates that the rat needs greater length of rest between licks. Interlick interval is defined as the complete licking cycle, increases in this measure suggest slower tongue protrusion and retraction from the metal spout ($ILI=CD+ICI$) (Weijnen, Wouters, & Van Hest, 1984). Based on previous literature, a licking burst can be defined as consecutive licks with ILIs <250 ms and licking cluster is defined as consecutive licks with ILIs between 250 and 500 ms (Davis & Perez, 1993; Davis & Smith, 1992b).

A host of environmental and physiological factors have been suggested to modulate changes in tongue displacement i.e. ILIs. Such factors include: behavioral alertness, administration of psychoactive drugs, taste stimuli, tactile feedback, deprivation levels, and the type of equipment used to collect lick data (Boughter Jr, Baird, Bryant, St. John, & Heck, 2007). When ILIs increase, this means it takes more time for a rat to complete a licking cycle, decreasing the overall licking rate. When an ILI

decreases, it takes less time for the rat to complete a licking cycle, increasing the overall time it takes to displace the tongue. Studies have shown that altering the taste stimuli can modulate the licking patterns (Boughter Jr, Baird, Bryant, St. John, & Heck, 2007).

Lin et al (2013) analyzed the licking pattern in rats compare effects of sucrose and ethanol on the licking microstructure. Results demonstrated rats use different strategies to adjust the amount of fluid ingested, by changing aspects of licking pattern including: the CD, the ICI, the rhythmic licking pattern, the number of licks within a burst, and the frequency of bursts. In particular, an increased ILI, shorter bursts/clusters of licks, and higher intraburst rate were seen in rats drinking ethanol; however, when ingesting a palatable substance (e.g. sucrose) the rats presented with longer burst/clusters of licks.

Swallowing is thought to be triggered after an adequate volume of fluid has accumulated in the vallecula, typically occurring after every 5-8 licks (Weijnen, Wouters, & Van Hest, 1984) . In the rat, the acts of licking and swallowing do not occur simultaneously. Studies have shown that swallowing interrupts sequential licking periodically, for about a 20 ms duration (Weijnen, Wouters, & Van Hest, 1984). A short cessation of the excitatory inputs of the central mechanism regulating tongue movements occurs prior to initiation of swallowing, suggesting that these behaviors are tightly coupled and likely require network-based rhythmicity. Malmö et al (1986) studied lapping rates over 3-week periods in rats as young adults and then 9.4 months later as middle-aged rats to determine the consistency of licking frequency as controlled by the hypoglossal oscillator. Results showed central neural circuits responsible for regulating rhythmic licking behavior in rats remained at a stable frequency regardless of age. More recent work has shown that licking function is influenced by internal and external

variables, such as age, adaptation, taste of the solution, the consequences of water deprivation and their interactions. For example, Weijnen & Mendelson (1977), compared the effects of high restriction, low restriction, and no restriction environments on tongue movements in rats. High restriction environment consisted of placing the rats drinking tube at a 2mm distance away from the cage. A low restriction environment consisted of placing the drinking tube one cm outside of the rat's cage. No restriction environment consisted of continuous jaw placement in the liquid while rats were lapping. Results found a decrease in licking frequency when high and low environmental restrictions are placed on drinking behaviors. In particular, the licking rate has been shown to decrease in response to increased distance required for the tongue to reach the drinking tube (Marowitz & Halpem, 1973). Therefore, greater distance requires increased tongue movement, which may be helpful in testing the ceiling effect with rats.

Model of Fibrosis

The goal was to study the effects of muscle fibrosis on licking function. To do this, we performed a cryoinjury, which is known to provoke fibrosis-like injury in rat musculature. Fibrosis is a result of acute inflammation triggering immune responses of coagulation, vasodilation, increased capillary permeability and increased of neutrophils and macrophages within minutes of radiation. This injury produces a fibrin network due to microvascular injury causing tissue ischemia, and tissue hypoxia. Vascular changes have been observed to occur within a few weeks of exposure and early inflammatory changes in the vasculature within minutes of exposure in animals (Yarnold & Vozenin Brotons, 2010) .

Shortly after radiation, early inflammation is followed by regeneration of endothelial cells and myofibroblasts which lead to formation of the extra cellular matrix.

Following injury, innate (acute) and adaptive (chronic) immune cells (neutrophils, lymphocytes, monocytes and macrophages) release cytokines resulting in the transition of fibroblasts into myofibroblasts. Cell rejuvenation decreases and a breakdown of epithelial develops due to accumulation of radiation damage. As a result, inflammation is unable to be cured and normal cell repopulation needed for regeneration of the tissue is inhibited (King, Dunlap, Tennant, & Pitts, 2016).

The myofibroblasts produce collagen, however in chronic fibrosis, they are observed to continue to function rather than participating in apoptosis as normal. PDGFR- α is transactivated by TGF β 1 and is especially associated with fibrosis. High expression, produced by fibroblasts and inflammatory cells, correlates with secretion of extracellular matrix resulting in tissue contraction (Yarnold & Vozenin Brotons, 2010) .

Oxidative damage attributed to reactive oxygen species has been reported in mostly rat models of radiation fibrosis exposed to very high single doses. Direct measurement of oxygen tension using platinum electrodes has confirmed hypoxia in head and neck cancer patients after high dose radiotherapy (Yarnold & Vozenin Brotons, 2010). The mylohyoid is mostly compromised of Type I slow twitch fibers which have a high oxidative capacity. Injury caused by radiation is due to oxidative stress leading to increased collagen content within the extracellular matrix.

Cryoinjury produces a similar injury to radiation, eliciting inflammatory response that leads to necrotic wound. Injuries and scarring as a result of cryoinjury have shown to be consistent in size and are observed as early as 2-weeks post-injury (Strungs, Ongstag, O'Quinn, Palatinus, Jourdan, & Gourdie, 2013). Cryoinjury is created by applying a metal cryoprobe, cooled with liquid nitrogen, to the targeted muscle area (Somogyi, Yokoyama,

Szell, Smith, de Groat, Huard, & Chancellor, 2002; van Amerongen, Harmsen, Van Rooijen, Petersen, & Van Luyn, 2007). Irintchev et al (1997) studied the role of existing muscle damage in the promotion of new cells for muscle regeneration in adult rats. Soleus muscles in mice were mildly or severely damaged through cryoinjury leading to reduced contractile force of musculature and loss of muscle tissue. Results concluded cryoinjury produces injuries similar to fibrosis in the heart muscle, and striated muscle, as it results in reduced ability to contract due to scar tissue development and diminished muscle function

Objective

The overall objective of this study is to examine the effects of injury to the rat mylohyoid muscle on rhythmic licking patterns. The mylohyoid is involved in jaw movement, which facilitates the licking process in the rat model. Findings of alterations in the licking rhythmicity after injury will provide detailed support of how fibrosis to the mylohyoid muscle impacts deglutition.

Hypothesis

The hypothesis is that injury to the mylohyoid delays the temporal licking pattern, resulting in aberrant drinking behaviors.

CHAPTER 2

METHODS

Eight male Sprague Dawley rats (450-500kg) were used for these studies. All experimental protocols were approved by the Institutional Animal Care and Use Committee of the University of Louisville.

Mylohyoid Cryoinjury Procedure

Cryoinjury was applied to the belly of the mylohyoid muscles in six Sprague Dawley male rats (450-500kg). Two uninjured rats were used as normal controls. Licking behaviors were studied zero, one-week and two-weeks post injury. The mylohyoid injury process comprised of general anesthesia to the rat, followed by surgical exposure of the mylohyoid muscle, and lastly application of the cryoprobe to the mylohyoid muscle and contralateral muscle. Following two-weeks post-injury the rats were sacrificed for collection of the mylohyoid muscle for fibrosis confirmation.

Using 2-3% isoflurane via inhalation, the animals were anesthetized followed by an intraperitoneal (IP) injection of 90 mg/kg of Ketamine and 9 mg/kg of Xylazine with 0.05 mg/kg of Atropine. 0.01–0.05mg/kg of buprenorphine was then administered for pain management. To surgically expose the mylohyoid muscle, a longitudinal incision was created and the midline of the anterior digastric muscle bluntly dissected. A 2mm cryoprobe (Cry-AC-3 B-800, Brymill Cryogenic Systems; UK) was filled with liquid nitrogen for cooling and then applied to surface of the exposed mylohyoid muscle for 30 seconds. To prevent further injury, the probe was detached from the muscle by allowing

it to incubate to room temperature. A second application to the contralateral muscle belly was then applied for 30 seconds. Following probe detachment, the incision was then sutured closed and animals were removed from inhaled anesthesia. The animals were sacrificed following 2-weeks post injury, with an IP injection of urethane and transcardially perfused with PBS and 4% paraformaldehyde (PFA). The mylohyoid muscles were collected 2-weeks after injury for histological purposes to confirm fibrosis.

Histology

Confirmation of fibrosis to the mylohyoid muscle was performed through the study of frozen tissue samples in six cryoinjured rats and two normal rats. Cross sections of the tissue were stained with Trichrome Stain, Gomori One-Step, Aniline Blue to indicate the presence of increased collagen content. The samples were then analyzed under microscope followed by ImageJ computer software. Results showed increase in collagen content within the cryoinjured mylohyoid muscles.

Lick Testing

Licking behaviors were recorded using an electrical lick sensor (Davis & Smith, 1992a; Lin, Pierce, Light, & Hayar, 2013; Weijnen, 1998) to determine changes in the rhythmic tongue movements following injury to the mylohyoid. With use of a custom designed cage, the rats were trained to independently feed through a spout located in the opening in the side of the chamber. To provide head stabilization without the restriction of jaw movement, the shape of the wall opening was fabricated to the proportion of the rat's zygomatic arch (Weijnen, 1998). Recording of licking behavior was produced by connecting an electrical circuit to a metal spout and metal cage floor. The circuit was completed upon contact of the rat's tongue with the metal spout. To prevent false

signaling by teeth or other structures hitting the metal spout, the outer part of the tubing was covered in hard plastic.

To test the ceiling or upper limit of the rat's tongue movement, we developed a challenging drinking task based on research showing that the licking frequency will decrease when access to the drinking tube is restrained. We believe this is because it requires increased lingual effort to uphold contact with the spout and continue coordinated movements. This challenging activity was implemented by increasing the distance between the rats snout and the liquid being dispensed from the spout to 20mm (Weijnen, 1998). To limit environmental influences on the licking rhythm, the distance was kept at a constant measure throughout the study. Licking behavior was measured for ten-minute drinking session. Prior to testing rats were deprived of water for 3 hours.

Baseline data was obtained following training the rats. This consisted of five trials of drinking within similar testing conditions. Raw data was amplified and recorded using Spike 2 software. Licking variables were calculated zero-, one- and two-weeks injury including: contact duration (CD), intercontact interval (ICI), interlick interval (ILI), lick frequency, number of clusters per ten-minute session, and cluster size (Davis & Smith, 1992a; Davis, Smith, & Kung, 1994; Lin, Pierce, Light, & Hayar, 2013; Spector, Klumpp, & Kaplan, 1998; Weijnen, 1998).

Lick analysis Using Spike 2 software, all licking activity was analyzed for the first 600-second period for each rat. Based off previous studies, we defined a cluster as minimum of 5 licks with an ILI less than 500ms (Bin Lin, Pierce, Light, & Hayar, 2013). Licks occurring after 600 seconds within each file were analyzed only if the cluster was initiated at or before 600 seconds. Biting, or contact of the metal spout with teeth rather

than the tongue, was occasionally observed on the Spike 2 software as denoted by irregular peak formation. These occurrences were not analyzed. Biting which occurred for 500ms or more was determined as the end of a cluster.

Signal was analyzed reducing the time across the x-axis using Spike 2 software until individual waveforms could be observed. The raw signal was negative, and the y-axis was flipped for analysis, to determine the following parameters the moving cursor, falling threshold, minimum, and rising threshold. The software computed the time point of each cursor, which was then copied into an excel file. Means of each variable were then calculated in the excel sheet using time points from Spike 2 software; ILI= Cursor 3(rising threshold) – Cursor 2(minimum), CD= Cursor 3(rising threshold) – Cursor 1(falling threshold), and ICI= Cursor 1 of the next lick (falling threshold) – Cursor 3(rising threshold).

Statistical Analysis

Statistical analyses, using ANOVA, were performed to assess the main effects of licking patterns. Comparison of means pre-injury and post-injury were considered statistically significant when $p < 0.05$.

Table 1Licking Measurement Descriptions

Measurements	Description
Licking Frequency	The average licking rate in a ten-minute drinking session
Total Licks/Cluster	The average total number of licks in each cluster
Cluster Size	The average length of time (seconds) of each cluster in a ten-minute drinking session.
Number of Clusters	The number of clusters in each ten-minute drinking session
Intercontact Interval	The period which the tongue is not in contact with the metal spout
Contact Duration	The period which the tongue is in contact with the metal spout
Interlick Interval	The complete licking cycle, or the time it takes for the tongue to protrude and retract from the metal spout ($ILI=ICI+CD$)

CHAPTER 3

RESULTS

To understand if muscle fibrosis alters licking performance, we created cryoinjuries in the mylohyoid and studied changes in their licking patterns.

Licking Frequency

Figure 1 and Table 2 represent the average frequency and standard deviation of licks per second. Statistically significant ($p < .05$) decreases in licking rate were found when the average licks per second during pre-injury (0 day) were compared to one-week post-injury ($p = .013$). Statistically significant ($p < .05$) decreases in licking rate were also found when pre-injury (0 day) was compared to two-weeks post-injury ($p = .022$).

Table 2.

Licking Frequency Pre-Injury and Post-Injury

	Pre-Injury (0 days) & Post-Injury (1-week)		Pre-Injury (0 days) & Post-Injury (2-weeks)	
	Mean Difference	<i>p</i> value	Mean Difference	<i>p</i> value
Average Licks/Second	.62*	.01	.59*	.02

Clusters

Cluster parameters are represented in Figure 2A-C and Table 3. Significant decreases ($p < .05$) in the average length of time per cluster were found one-week post-injury ($p = .042$) compared to pre-injury (0 day), as well as two-weeks post-injury ($p = .014$) compared to pre-injury (0 day). Statistically significant ($p < .05$) increases in the number of clusters per ten-minute drinking session were found two-weeks post-injury ($p = .005$) compared to pre-injury (0 day). No statistically significant ($p > .05$) differences in the number of clusters per ten-minute drinking session were found one-week post-injury ($p = .216$) compared to pre-injury (0 day). Statistically significant ($p < .05$) decreases in total licks per cluster were observed one-week post-injury ($p = .022$) compared to pre-injury (0 day) and two-weeks post-injury ($p = .019$) compared to pre-injury (0 day).

Table 3

Clusters Pre-Injury and Post-Injury

	Pre-Injury (0 days) & Post-Injury (1-week)		Pre-Injury (0 days) & Post-Injury (2-weeks)	
	Mean Difference	<i>p</i> value	Mean Difference	<i>p</i> value
Cluster Size	10.63*	.04	8.33*	.01
# of Clusters/10-Minute Session	-23.67	.07	16.67*	.002
Total # of Licks/Cluster	57.03*	.02	45.45*	.02

Microstructures

Figure 3A-C and Table 4 represent the microstructural changes in licking pattern. Statistically significant ($p < .05$) increases in intercontact interval were found one-week post-injury ($p = .010$) compared to pre-injury (0 day) and two-weeks post-injury ($p = .017$) compared to pre-injury (0 day). No statistically significant ($p > .05$) changes were found with contact duration one-week post-injury ($p = .741$) or two-weeks post-injury compared to pre-injury (0 day). Statistically significant ($p < .05$) increases in the intercontact interval were observed one-week post-injury ($p = .007$) and two-weeks post-injury ($p = .012$) compared to pre-injury (0 day).

Table 4

Microstructures Pre-Injury and Post-Injury

	Pre-Injury (0 days) & Post-Injury (1-week)		Pre-Injury (0 days) & Post-Injury (2-weeks)	
	Mean Difference	<i>p value</i>	Mean Difference	<i>p value</i>
Intercontact Interval	-.03*	.01	-.02*	.02
Contact Duration	.002	.74	-.003	.47
Interlick Interval	-.02*	.007	-.02*	.01

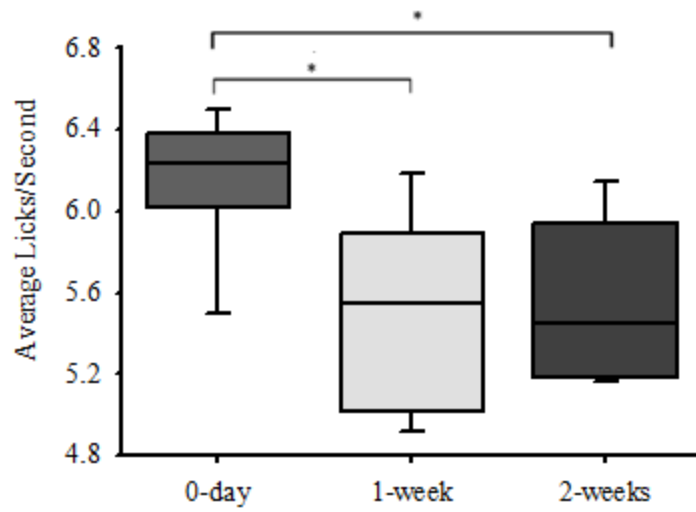


Figure 1. Mylohyoid injury causes a decline in lick frequency. Frequency of licking throughout a ten-minute recording session was calculated. Pre- and post-injury comparisons were made within animals ($n=6$). Significant decreases in licking rate were found after injury compared with pre-injury. Statistical significance of $p<0.05$ is shown as *.

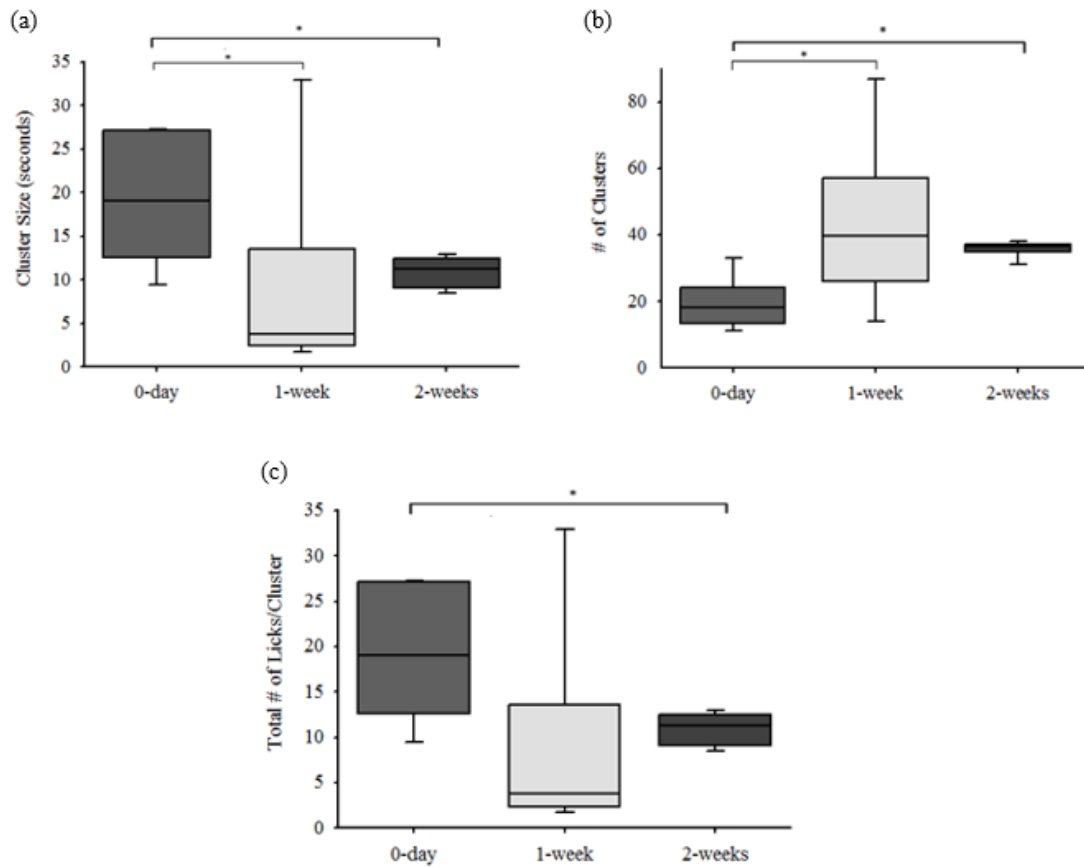


Figure 2. Mylohyoid fibrosis dramatically increased the number of licking clusters performed. Significant decreases in (a) duration of clusters (seconds) and (c) total number of licks/cluster one-and-two-weeks post-cryoinjury to the rat mylohyoid muscle compared to pre-injury. Significant increases in (b) number of clusters/ten-minute drinking session were found one-and-two-weeks post-cryoinjury to the rat mylohyoid muscle compared to pre-injury. Statistical significance of $p < 0.05$ is shown as *.

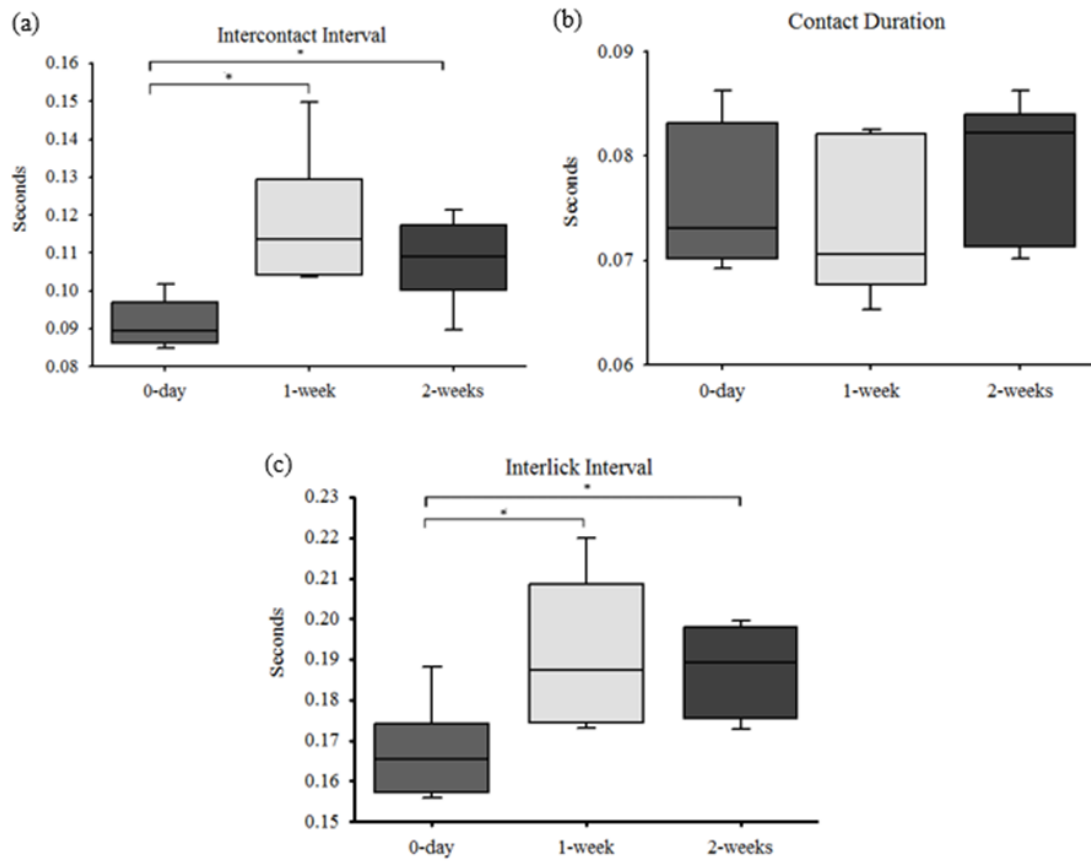


Figure 3. Alterations in licking microstructure reveal a delay in tongue movement after injury to mylohyoid muscle. Significant increases in the (a) intercontact intervals and (c) interlick intervals were found two-weeks post-injury compared to pre-injury. This suggests that duration of the tongue protrusion-retraction cycle was delayed. Statistical significance of $p < 0.05$ is shown as *.

CHAPTER 4

DISCUSSION

Researchers have shown that radiation-based therapies can result in swallowing mobility disorders for patients with head and neck cancer (Hutcheson, Barringer, Rosenthal, May, Roberts, & Lewin, 2008; Kumar, Madanikia, Starmer, Yang, Murano, Alcorn, McNutt, Quon, & Le, 2014; Manikantan, Khode, Sayed, Roe, Nutting, Rhys-Evans, Harrington, & Kazi, 2009; Pauloski, 2008; Starmer, Quon, Kumar, Alcorn, Murano, Jones, & Humbert, 2015; Straub, New, Hamilton, Lominska, Shnyder, & Thomas, 2015). Muscle injury is a common side effect of radiation treatment for head and neck cancer. There is a gap in current knowledge about the impact of muscle injury on behaviors of deglutition (i.e. licking, swallowing). This information is important to development of therapies for treating injury based swallowing disorders. To increase understanding of muscle injury related dysfunction, we investigated the effects of oral swallowing function after cryoinjury to mylohyoid muscle in rats. The hypothesis was that fibrosis of the mylohyoid delays the temporal licking pattern, resulting in aberrant drinking behaviors.

The findings demonstrated that injury to the mylohyoid muscle resulted in aperiodicity in licking patterns. Prior to injury, licking frequency was similar to previous studies showing a consistent licking rate of 6-8Hz (Bin Lin, Pierce, Light, & Hayar, 2013; Malmo, Malmo, & Weijnen, 1986). Previous work has indicated that licking is innervated by the hypoglossal nerve and the rate is controlled by the CPG in the

brainstem (Boughter Jr, Baird, Bryant, St. John, & Heck, 2007). Thus, it is subject to possible modulations due to sensory feedback. For instance, an injury to the mylohyoid muscle could evoke signaling via trigeminal ganglion, altering excitability of the licking CPG as a means of protecting the body from further injury. Studies have shown that muscle inflammation results in alteration in swallowing function. Tsujimuraa et al (2011) studied swallow frequency after administering capsaicin to the whisker pad, masseter muscle, or lingual muscle in rats, which provokes a localized inflammatory response. Results showed the number of swallows elicited, as determined by mylohyoid EMG activity, was significantly less after inflammation. Therefore, this study suggests that peripheral injuries i.e. cryoinjury likely alters excitability of the licking CPG.

Previous research has found a decrease in licking frequency when high and low environmental restrictions are placed on drinking behaviors (Weijnen & Mendelson, 1977). In particular, the licking rate has been shown to decrease in response to increased distance required for the tongue to reach the drinking tube (Marowitz & Halpem, 1973). We believe one of the reasons that we found changes in licking pattern is because we tested the ceiling effect, which means that the licking task required greater tongue movement for the rat to perform. Several researchers have utilized complex tasks to assess the ceiling effect during experiments (Giebels, de Dreu, & van de Vliert, 2003; Kuerzi, Brown, Shum-Siu, Siu, Burke, Morehouse, Smith, & Magnuson, 2010). Kuerzi et al (2010) compared above ground voluntary step training compared to shallow-water walking, to assess locomotion in a rodent model of spinal cord injury. To challenge locomotor functioning, body weight support compared to no support during walking tasks were used. Body weight support is a pre-requisite to allow pattern generation of motor

functioning to be observed (Timoszyk, Nessler, Acosta, Roy, Edgerton, Reinkensmeyer, & de Leon, 2005). Therefore, without providing the challenge of body weight support, the pattern generating capacity of the nervous system may be underestimated. Results allowed researchers to assess the severity of the injuries and better determine the effects of functional locomotor recovery. In the current experiment, method was designed to challenge the rat by increasing the distance between the rats tongue and the drinking spout (Weijnen, 1998). This mirrors similar increased efforts that occurs clinically with patients when testing their swallowing function. When clinically assessing swallowing function in head and neck cancer patients, we tax the system by having the patient swallow larger volumes of liquids/solids or alternate bolus delivery (straw, cup, etc.), which require increased effort and appropriate coordination of the structures. Dysphagia therapy also challenges swallowing musculature as it frequently includes repetitive practice of range of motion exercises and swallowing maneuvers in an attempt to strengthen swallowing musculature (Pauloski, 2008). By using a challenging task, the injury to the rat's mylohyoid likely led to greater alterations in the temporal licking pattern and a decreased licking rate in comparison to standard drinking conditions.

This study revealed no significant differences in licking microstructure between one-week and two-weeks post injury; however, differences were found pre- and one- and two-weeks post-injury. Based on previous literature, at one-week post cryoinjury inflammation and granulation tissue likely persisted within the wound bed (Duerr, Elhafi, Bostani, Ellinger, Swieny, Kolobara, Welz, & Dewald, 2011). Similar to other work, we found increased collagen content in the rat mylohyoid two-weeks post injury, which resembles fibrotic tissue. Therefore, results indicate that either injury or fibrosis of the

mylohyoid muscle in the rat reduces lingual mobility. Previous work has shown that muscle injury can alter regeneration of the tissue. Ramos et al (2016) produced a cryoinjury to the tibialis anterior muscle in rats to study inflammation, regeneration, and extracellular matrix remodeling in the muscle of rats three-, seven- and fourteen-days post-injury. Cross-sections of the muscle seven-days post injury showed myonecrosis, cellular infiltration, and clear areas among the muscle fibers compared to control muscle fibers. Cellular infiltration had reduced seven-days post injury compared to three-days post injury. Muscular regeneration began to occur fourteen-days post injury. Van Amerongen et al (2008) studied cardiomyocyte proliferation after myocardial injury. Results confirmed the high level of cardiomyocyte proliferation at seven-days and fourteen-days post cryoinjury. Therefore, injury to mylohyoid likely inhibits muscle regeneration, which may interfere with its role in mandible and lingual displacement.

Injury to the mylohyoid caused an increase in the number of breaks or pauses the animal took between periods of licking. There are two possible causes for this occurrence. First, rats may have increased the number of clusters performed to adjust for a change in volume intake since the period of time licking was reduced. Hartfield et al (2003) analyzed the effects of various antipsychotics on mean cluster size (licks per cluster). Their findings showed correlations between increased clusters and an increase in liquid intake following ingestion of atypical antipsychotics. Davis et al (1992a) analyzed the effects of sucrose solutions on licking microstructure. Results revealed an increase in the number of clusters and the size of clusters when ingesting sucrose solutions. Thus, palatability of the liquid was found to increase liquid intake. Based on these previous studies, the increase in number of clusters performed may be associated with liquid

volume. Pauloski et al (2008) reported that patients treated for head and neck cancer often present with delays in oral and pharyngeal transit times. Results suggest that this may be caused by muscle injury.

A second possible cause for changes in lick cluster is that shorter, more frequent clusters may be reflective of muscle fatigue after injury. Therefore, the rat required frequent breaks to maintain oral intake. Previous literature has shown muscle fatigue can occur following radiation therapy. Smets et al (1998) interviewed patients with cancer (i.e. HNC, gastrointestinal, gynecological, lung, breast, prostate, and testicular) undergoing radiation pre and post-treatment. Twenty % of these patients reported physical symptoms of muscle weakness associated with fatigue as assessed by the Multidimensional Fatigue Inventory (MFI-20) after radiation therapy. Monga et al (1997) evaluated neuromuscular fatigue in patients with prostate cancer. Results showed patients experienced a significant decline in neuromuscular efficiency, as measured by maximum isometric and isokinetic muscle force and EMG six-weeks post radiation therapy. Therefore, it is possible that changes in licking cluster after injury to mylohyoid may be a result of weakness or muscle fatigue.

After mylohyoid injury we also found reductions in tongue displacement based on increases in interlick interval and intercontact interval found after injury. As such, results may indicate a decline in tongue mobility following injury. During the process of licking and chewing, the mylohyoid facilitates jaw closing movement. In the rat, jaw closure occurs simultaneously with tongue extraction during licking. The increase in intercontact interval and interlick interval following injury to the rat mylohyoid signifies a prolongation in displacement of the tongue during drinking. Tongue base retraction is

also important for moving the bolus posteriorly through the pharynx during swallowing. Previous research has shown that radiation-induced injury after oropharyngeal cancer results in reduced tongue base retraction and reduced duration of tongue base contact to the posterior pharyngeal wall (Pauloski, 2008; Pauloski & Logemann, 2000; Walker, Ruzevick, Malayeri, Rigamonti, Lim, Redmond, & Kleinberg, 2014). Clinically, the mylohyoid plays a role in licking motor movements and may also modulate licking behaviors via sensory changes associated with injury. Specifically, the mylohyoid is active during mandibular movement, protrusion and retraction of the mandible, and elevation and retraction of the tongue (Lehr, Blanton, & Biggs, 1971). Therefore, increases in the microstructures of licking after injury to the mylohyoid may correlate with what is seen clinically after radiation injury.

Limitations

There are several limitations to this study that warrant further discussion. First, during licking analysis post-injury, a couple of the rats were found to occasionally bite the metal spout of the drinking tube resulting in a shift in peak. No biting was found pre-injury. Interestingly, biting was only seen after several minutes of drinking. One might speculate that the increase was a compensation strategy for fatigued or frustration with performing the challenging drinking activity. Although interesting, biting data was not analyzed in this study. Further analysis into changes in mastication after mylohyoid injury may be warranted.

An additional limitation is the use of a cryoinjury model instead of radiation injury. Cryoinjury, provokes similar fibrotic injuries as radiation injury, however the inflammatory response and regeneration of the tissue is likely different (Gao & Critse, 2000; Jurdana, Cemazar, & Mars, 2013). Cryoinjury elicits an immediate inflammatory

response that results in necrosis and formation of fibrotic tissue within two-weeks (Strungs, Ongstag, O'Quinn, Palatinus, Jourdan, & Gourdie, 2013). Injury via radiation transpires through a slower process where fibrosis does not occur until at least 6 months after radiation treatment (King, Dunlap, Tennant, & Pitts, 2016). Therefore, results address a specific population of HNC patients who suffer from late-term effects of radiation. An injury model which simulates the extensive length of time for radiation injury to clinically occur is required for further understanding of radiation injuries.

Conclusion and Future Direction

In summary, an injury to the mylohyoid muscle leads to interruptions in rhythmic licking patterns in the rat. Results demonstrated increases in the number of clusters/ten-minute session, intercontact interval, and interlick interval and decreases in licking frequency, cluster size, and licks/cluster variables. When applied clinically, findings suggest that injury to single swallowing muscle can interrupt rhythmic behaviors during ingestion potentially increasing the risk for swallow disorders.

Future research should include cryoinjury to other important swallowing musculature to provide a more detailed understanding of the effects of individual impairments to swallowing muscles on deglutition and help improve treatment strategies. Further research of fibrosis to the mylohyoid should focus on later time points (ie. one-month and three-months) following cryoinjury to understand the long-term effects of fibrosis to an individual swallowing muscle on lick and swallow functioning.

REFERENCES

- Bazett, H., Oxon, M., Eng, F., Penfield, W., & Oxon, B. (1922). A study of the sherrington decelebrate animal in the chronic as well as the acute condition *Brain*, *45*, 185-265.
- Bin Lin, X., Pierce, D., Light, K. E., & Hayar, A. (2013). The fine temporal structure of the rat licking pattern: what causes the variability in the interlick intervals and how is it affected by the drinking solution? *Chem. Senses*, *38*, 685-704.
- Boughter Jr, J., Baird, J., Bryant, J., St. John, S., & Heck, D. (2007). C57BL/6J and DBA/2J mice vary in lick rate and ingestive microstructure. *Genes Brains and Behavior*, *6*, 619-627.
- Caudell, J., Schaner, P., Meredith, R., Locher, J., Nabell, L., Carroll, W., . . . Bonner, J. (2009). Factors associated with long-term dysphagia after definitive radiotherapy for locally advanced head-and-neck cancer. *Int. J. Radiation Oncology Biol. Phys.*, *73*(2), 410-415.
- Crompton, A., Cook, P., Hiiemae, K., & Thexton, A. (1975). Movement of the hyoid apparatus during chewing *Nature*, *258*.
- Davis, J., & Perez, M. (1993). Food deprivation- and palatability-induced microstructural changes in ingestive behavior. *264*, *1*, R97-103.
- Davis, J., & Smith, G. (1992a). Analysis of the microstructure of the rhythmic tongue movements of rats ingesting maltose and sucrose solutions. *Behav Neurosci*, *106*(1), 217-228.
- Davis, J., & Smith, G. (1992b). Analysis of the microstructure of the rhythmic tongue movements of rats ingesting maltose and sucrose solutions. *Behavioral Neuroscience*, *106*(1), 217-228.
- Davis, J., Smith, G., & Kung, T. (1994). Abdominal vagotomy alters the structure of the ingestive behavior of rats ingesting liquid diets. *Behav Neurosci*, *108*(4), 767-779.

- Dodds, W., Stewart, E., & Logemann, J. (1990). Physiology and radiology of the normal oral and pharyngeal phases of swallowing. *AJR*, *154*, 953-963.
- Dodds, W., Taylor, A., Stewart, E., Kern, M., Logemann, J., & Cook, I. (1989). Tipper and dipper types of oral swallows. *AJR*, *153*, 1197-1199.
- Doty, R. (1968). Neural organization of deglutition. *Am Physiol Soc*, *4*, 1861-1902.
- Duerr, G., Elhafi, N., Bostani, T., Ellinger, J., Swieny, L., Kolobara, E., . . . Dewald, O. (2011). Comparison of myocaridal remodeling between cryoinfarction and reperfused infarction in mice. *Journal of Biomedicine and Biotechnology*, 1-10.
- Faaborg-Andersen, K., & Vennard, W. (1964). Electromyography of extrinsic laryngeal muscles during phonation of different vowels. *Ann Otol Rhinol Laryngol*, *73*, 248-254.
- Gallas, S., Moiro, P., Debono, G., Navarre, I., Denis, P., Marie, J., & Verin, E. (2007). Mylohyoid motor-evoked potentials relate to swallowing function after chronic stroke dysphagia. *Neurogastroenterol Motil*, *19*, 453-458.
- Gao, D., & Critse, J. (2000). Mechanisms of cryoinjury in living cells. *ILAR*, *41*(4), 187-193.
- Giebels, E., de Dreu, C., & van de Vliert, E. (2003). No way out: swallow the bait of two-sided exit options in negotiation: the influence of social motives and interpersonal trust. *Group processes and intergroup relations*, *6*(4), 369-386.
- Groher, M. (1997). *Dysphagia: diagnosis and management* (3rd ed.).
- Hartfield, A., Moore, N., & Clifton, P. (2003). Effects of clozapine, olanzapine and haloperidol on the microstructure of ingestive behaviour in the rat. *Psychopharmacology*, *167*, 115-122.
- Hutcheson, K., Barringer, D., Rosenthal, D., May, A., Roberts, D., & Lewin, J. (2008). Swallowing outcomes after radiotherapy for laryngeal carcinoma. *Arch Otolaryngol Head and Neck Surg*, *134*(2).
- Irintchev, A., Langer, M., Zwyer, M., Theisen, R., & Wernig, A. (1997). Functional improvement of damaged adult mouse muscle by implantation of primary myoblasts. *Journal of Physiology*, *500*(3), 775-785.

- Jean, A. (2001). Brain stem control of swallowing: neuronal network and cellular mechanisms. *Physiological Reviews*, 81(2), 929-969.
- Jurdana, M., Cemazar, M., & Mars, T. (2013). Effect of ionizing radiation on human skeletal muscle precursor cells. *Radiology and Oncology*, 47(4), 376-381.
- King, S., Dunlap, N., Tennant, P., & Pitts, T. (2016). Pathophysiology of radiation-induced dysphagia in head and neck cancer. *Dysphagia*, 31(3), 339-351.
- Kuerzi, J., Brown, E., Shum-Siu, A., Siu, A., Burke, D., Morehouse, J., . . . Magnuson, D. (2010). Task-specificity vs ceiling effect: step-training in shallow water after spinal cord injury. *Exp Neurology*, 224(1), 178-187.
- Kumar, R., Madanikia, S., Starmer, H., Yang, W., Murano, E., Alcorn, S., . . . Le, Y. (2014). Radiation dose to the floor of mouth muscles predicts swallowing complications following chemoradiation in oropharyngeal squamous cell carcinoma. *Oral Oncology*, 50, 65-70.
- Lehr, R., Blanton, P., & Biggs, N. (1971). An electromyographic study of the mylohyoid muscle. *Anat Rec* 169, 4, 651-660.
- Liancai Mu, H. S., Jun Wang, Yingshi Han, Ira Sanders (2004). Adult Human Mylohyoid Muscle Fibers Express Slow-Tonic, -Cardiac, and Developmental Myosin Heavy-Chain Isoforms *The Anatomical Record Part A*, 279A, 749-760.
- Lin, P.-H., Hsiao, T.-Y., Chang, Y.-C., Ting, L.-L., Chen, W.-S., Chen, S.-C., & Wang, T.-G. (2011). Effects of functional electrical stimulation on dysphagia caused by radiation therapy in patients with nasopharyngeal carcinoma. *Support Care Cancer*, 19, 91-99.
- Lin, X., Pierce, D., Light, K., & Hayar, A. (2013). The Fine Temporal Structure of the Rat Licking Pattern: What Causes the Variability in the Interlick Intervals and How is it Affected by the Drinking Solution? *Chem Senses*, 38(8), 685-704.
- Machtay, M., Moughan, J., Trotti, A., Garden, A., Webber, R., & Cooper, J. (2008). Factors associated with severe late toxicity after concurrent chemoradiation for locally advanced head and neck cancer: an RTOG analysis *J Clin Oncol*, 26, 3582-3589.

- Malmö, H., Malmö, R., & Weijnen, J. (1986). Individual consistency and modifiability of lapping rates in rats: a new look at the variance-invariance question *International Journal of Psychophysiology*, 111-119.
- Manikantan, K., Khode, S., Sayed, S., Roe, J., Nutting, C., Rhys-Evans, P., . . . Kazi, R. (2009). Dysphagia in head and neck cancer. *Cancer Treatment Reviews*, 35, 724-732.
- Marowitz, L., & Halpem, B. (1973). The effect of environmental constraints upon licking patterns. *Physiol. Behav.*, 11, 259-263.
- Martin, M., Lefaix, J.-L., & Delanian, S. (2000). TGF- β 1 and radiation fibrosis: a master switch and a specific therapeutic target? *Int. J. Radiation Oncology Biol. Phys.*, 47(2), 277-290.
- Moloney, E. C., Brunner, M., Alexander, A. J., & Clark, J. (2014). Quantifying fibrosis in head and neck cancer treatment: An overview. *CLINICAL REVIEW*.
- Monga, U., Jaweed, M., Kerrigan, A., Luwhon, L., Johnson, J., Vallbona, C., & Monga, T. (1997). Neuromuscular fatigue in prostate cancer patients undergoing radiation therapy *Arch Phys Med Rehabil*, 78, 961-966.
- Morton, R., Crowder, V., Mawdsley, R., Ong, E., & Izzard, M. (2009). Elective gastrostomy, nutritional status and quality of life in advanced head and neck cancer patients receiving chemoradiotherapy. *ANZ J Surg*, 79, 713-718.
- Mu, L., Su, H., Wang, J., Han, Y., & Sanders, I. (2004). Adult Human Mylohyoid Muscle Fibers Express Slow-Tonic, -Cardiac, and Developmental Myosin Heavy-Chain Isoforms *The Anatomical Record Part A*, 279A, 749-760.
- Naoko Saito, R. N. N., Mitsuhiro Nakahira, Masahiro Takahashi, Akira Uchino, Fumiko Kimura, Minh Tam Truong, Osamu Sakai. (2012). Posttreatment CT and MR imaging in head and neck cancer: what the radiologist needs to know. *RadioGraphics*, 32, 1261-1279.
- Nguyen, N., Sallah, S., Karlsson, U., & Antoine, J. (2002). Combined chemotherapy and radiation therapy for head and neck malignancies quality of life issues. *American Cancer Society*.

- Otonari-Yamamoto, M., Nakajima, K., Tsuji, Y., Otonari, T., Curtin, H. D., Okano, T., & Sano, T. (2010). Imaging of the mylohyoid muscle: separation of submandibular and sublingual spaces. *AJR*, *194*, W431-W438.
- Paton, J. (1999). Nucleus tractus solitarii: integrating structures. *Experimental Physiology*, *84*, 815-833.
- Pauloski, B. (2008). Rehabilitation of dysphagia following head and neck cancer. *Physical Medicine and Rehabilitation Clinics of North America*, *19* 889-928.
- Pauloski, B., & Logemann, J. (2000). Impact of tongue base and posterior pharyngeal wall biomechanics on pharyngeal clearance in irradiated postsurgical oral and oropharyngeal cancer patients. *Head and Neck*, 120-131.
- Pei-Hung Lin, T.-Y. H., Yeun-Chung Chang, Lai-Lei Ting, Wen-Shiang Chen, Su-Chiu Chen, Tyng-Guey Wang. (2011). Effects of functional electrical stimulation on dysphagia caused by radiation therapy in patients with nasopharyngeal carcinoma. *Support Care Cancer*, *19*, 91-99.
- Popovtzer, A., Cao, Y., Feng, F., & Eisbruch, A. (2009). Anatomical changes in the pharyngeal constrictors after chemoradiation of head and neck cancer and their dose-effect relationships: MRI-based study. *Radiother Oncol*, *93*(3), 510-515.
- Raber-Durlacher, J., Brennan, M., Verdonck-de Leeuw, I., Gibson, R., Eilers, J., Waltimo, T., . . . Spijkervet, F. (2012). Swallowing dysfunction in cancer patients. *Support Care Cancer*, *20*, 433-443.
- Rachit Kumar, S. M., Heather Starmer, Wuyang Yang, Emi Murano, Sara Alcorn, Todd McNutt, Yi Le, Harry Quon. (2014). Radiation dose to the floor of mouth muscles predicts swallowing complications following chemoradiation in oropharyngeal squamous cell carcinoma. *Oral Oncology*, *50*, 65-70.
- Ramos, G., Pinheiro, C. M., Messa, S. P., Delfino, G. B., Marqueti, R. d. C., Salvini, T. d. F., & Durigan, J. L. Q. (2016). Cryotherapy reduces inflammatory response without altering muscle regeneration process and extracellular matrix remodeling of rat muscle. *Scientific Reports*, 1-12.
- Ren, M., & Mu, L. (2005). Intrinsic properties of the adult human mylohyoid muscle: neural organization, fiber-type distribution, and myosin heavy chain expression. *Dysphagia*, *20*, 182-194.

- Rubeshin, S., Jones, B., & Donner, M. (1987). Radiology of the adult soft palate. *Dysphagia*, 2, 8-17.
- Russi, E., Corvò, R., Merlotti, A., Alterio, D., Franco, P., Pergolizzi, S., . . . Bernier, J. (2012). Swallowing dysfunction in head and neck cancer patients treated by radiotherapy: review and recommendations of the supportive task group of the Italian Association of Radiation Oncology. *Cancer Treatment Reviews*, 38, 1033-1049.
- Schindler, A., Denaro, N., Russi, E., Pizzorni, N., Bossi, P., Merlotti, A., . . . Murphy, B. (2015). Dysphagia in head and neck cancer patients treated with radiotherapy and systemic therapies: literature review and consensus. *Critical Reviews in Oncology/Hematology*, 96, 372-384.
- Schwartz, G., Enomoto, S., Valiquette, C., & Lund, J. (1989). Mastication in the rabbit: a description of movement and muscle activity. *J Neurophysiol*, 62, 273-278.
- Shaw, S., Skoretz, S., O'Sullivan, B., Hope, A., Liu, L., & Martino, R. (2016). Valid and reliable techniques for measuring fibrosis in patients with head and neck cancer postradiotherapy: A systematic review. *CLINICAL REVIEW*.
- Siegel, R., Miller, K., & Jemal, A. (2018). Cancer Statistics, 2018. *CA Cancer J Clin*, 68, 7-30.
- Sinclair, W. (1970). Initiation of reflex swallowing from the naso-and oropharynx. *Am J Physiol*, 218, 956-960.
- Smets, E., Visser, M., Willems-Groot, A., Garssen, B., Oldenburger, F., van Tienhoven, G., & de Haes, J. (1998). Fatigue and radiotherapy: (A) experience in patients undergoing treatment. *British Journal of Cancer*, 7, 899-906.
- Somogyi, G., Yokoyama, T., Szell, E., Smith, C., de Groat, W., Huard, J., & Chancellor, M. (2002). Effect of cryoinjury on the contractile parameters of bladder strips: A model of impaired detrusor contractility. *Brain Research Bulletin*, 59(1), 23-28.
- Spector, A., Klumpp, P., & Kaplan, J. (1998). Analytical issues in the evaluation of food deprivation and sucrose concentration effects on the microstructure of licking behavior in the rat. *Behav Neurosci*, 112(3), 678-694.
- Spiro, J., Rendell, J., & Gay, T. (1994). Activation and coordination patterns of the suprahyoid muscles during swallowing *Laryngoscope*, 104, 1376-1382.

- Starmer, H., Quon, H., Kumar, R., Alcorn, S., Murano, E., Jones, B., & Humbert, I. (2015). The effect of radiation dose on swallowing: evaluation of aspiration and kinematics. *Dysphagia*, *30*, 430-437.
- Straub, J., New, J., Hamilton, C., Lominska, C., Shnyder, Y., & Thomas, S. (2015). Radiation-induced fibrosis: mechanisms and implications for therapy. *J Cancer Res Clin Oncol*, *141*, 1985-1994.
- Strungs, E., Ongstag, E., O'Quinn, M., Palatinus, J., Jourdan, L. J., & Gourdie, R. (2013). Cryoinjury models of the adult and neonatal mouse heart for studies of scarring and regeneration *Wound Regeneration and Repair: Methods and Protocols, Methods in Molecular Biology*, *1037*, 343-353.
- Timoszyk, W., Nessler, J., Acosta, C., Roy, R., Edgerton, V., Reinkensmeyer, D., & de Leon, R. (2005). Hindlimb loading determines stepping quantity and quality following spinal cord transection. *Brain Res*, *1050*, 180-189.
- Tsujimuraa, T., Shinodab, M., Hondab, K., Hitomib, S., Kiyomotod, M., Matsuurae, S., . . . Iwatab, K. (2011). Organization of pERK-immunoreactive cells in trigeminal spinal nucleus caudalis, upper cervical cord, NTS and Pa5 following capsaicin injection into masticatory and swallowing-related muscles in rats. *Brain Research*, *1417*, 45-54.
- van Amerongen, M., Harmsen, M., Petersen, A., Popa, E., & van Luyn, M. (2008). Cryoinjury: a model of myocardial regeneration. *Cardiovascular Pathology*, *17*, 23-31.
- van Amerongen, M., Harmsen, M., Van Rooijen, N., Petersen, A., & Van Luyn, M. (2007). Macrophage depletion impairs wound healing and increases left ventricular remodeling after myocardial injury in mice. *The American Journal of Pathology*, *170*(3), 818-829.
- Vitti, M., & Basmajian, J. (1977). Integrated actions of masticatory muscles: simultaneous EMG from eight intramuscular electrodes. *Anat Rec* *169*, *187*, 173-189.
- Walker, A., Ruzevick, J., Malayeri, A., Rigamonti, D., Lim, M., Redmond, K., & Kleinberg, L. (2014). Postradiation imaging changes in the CNS: how can we differentiate between treatment effect and disease progression? *Future Oncology*, *10*, 1277-1297.

- Walton, J., & Silva, P. (2018). Physiology of swallowing *Surgery*, 36(10), 529-534.
- Weijnen, J. (1998). Licking behavior in the rat: measurement and situational control of licking frequency. *NEUROSCI BIOBEHAV REV*, 22(6), 751-760.
- Weijnen, J., & Mendelson, J. (1977). Drinking behavior: oral stimulation, reinforcement, and preference.
- Weijnen, J., Wouters, J., & Van Hest, J. (1984). Interaction between licking and swallowing in the drinking rat. *Brain Behavior*, 25, 117-127.
- Yamada, Y., Haraguchi, N., Uchida, K., & Meng, Y. (1993). Jaw movements and EMG activities of limb-licking behavior during grooming in rabbits. *PHYSIOL BEHAV*, 53, 301-307.
- Yarnold, J., & Vozenin Brotons, M. C. (2010). Pathogenetic mechanisms in radiation fibrosis. *Radiotherapy and Oncology*, 97, 149-161.

APPENDIX: ABBREVIATIONS

CD	contact duration
CN	cranial nerve
CPG	central pattern generator
EMG	electromyography
HNC	head and neck cancer
ICI	intercontact interval
ILI	interlick interval
IP	intraperitoneal injection
MRI	magnetic resonance imaging
PAS	Penetration Aspiration Scale
PEG	percutaneous endoscopic gastrostomy
PMN	premotor neuron
SLN	superior laryngeal nerve
TGF- β 1	transforming growth factor Beta 1
UES	upper esophageal sphincter

CURRICULUM VITAE

NAME: Brittany Nicole Fletcher

ADDRESS: Department of Otolaryngology- Head and Neck Surgery and
Communicative Disorders Speech-Language Pathology
MDA Building School of Medicine
627 S. Preston Street, Suite 220
University of Louisville
Louisville, Kentucky 40292

DOB: Louisville, Kentucky - November 6, 1994

EDUCATION & TRAINING:

B.A., Elementary Education and Learning Behavioral Disorders
Bellarmine University
2012-2016

PROFESSIONAL SOCIETIES:

National Student Speech-Language Hearing Association
Kentucky Speech and Hearing Association

POSTER PRESENTATIONS:

Fletcher B, Pitts T, King SN. Alterations in Licking Patterns Following Fibrosis in Rat Mylohyoid Muscle. Research! Louisville, University of Louisville, October 12, 2018

Fletcher B, Pitts T, King SN. Alterations in Licking Patterns Following Fibrosis in Rat Mylohyoid Muscle. Kentucky Speech-Language and Hearing Association Conference, Lexington KY, February 21, 2019