

This is the accepted manuscript of:

Alessandro Leone, Jacopo Alfonsi, Emanuele Pilato, Luigi Lovato, Luca Di Marco, Giacomo Murana, Francesco Saia, Davide Pacini, Roberto Di Bartolomeo, Transcatheter Mitral Valve-in-Valve Dislocation: A Rescue Strategy, *The Annals of Thoracic Surgery*, 2018; 106: e137-e139

Final version available: <https://doi.org/10.1016/j.athoracsur.2018.03.024>

Rights / License:

The terms and conditions for the reuse of this version of the manuscript are specified in the publishing policy. For all terms of use and more information see the publisher's website.

This item was downloaded from IRIS Università di Bologna (<https://cris.unibo.it/>)

When citing, please refer to the published version.

Transcatheter Mitral Valve-In-Valve Dislocation: A Rescue Strategy

Running Head: Mitral Valve-in-Valve

Alessandro Leone^{1*}, Jacopo Alfonsi¹, Emanuele Pilato¹, Luigi Lovato², Luca Di Marco¹, Giacomo Murana¹,
Francesco Saia³, Davide Pacini¹, Roberto Di Bartolomeo¹

¹Cardio-Thoracic and vascular Department, division of Cardiac Surgery, S.Orsola Hospital, Bologna university, Italy.

² Cardio-thoracic and Vascular Department, division of Radiology S.Orsola Hospital, Bologna University, Italy.

³ Cardio-thoracic and Vascular Department, division of Cardiology S.Orsola Hospital, Bologna University, Italy.

Key words: prosthesis failure, mitral valve in valve, TAVI, TEVAR.

Total word counts: 1316

***Corresponding author:**

Alessandro Leone, MD

c/o Cardiac Surgery Department.

University of Bologna

S.Orsola-Malpighi Hospital

Via Massarenti, 9

40138 BOLOGNA - ITALIA

Email: leone.alessandro@yahoo.it

Abstract

In the TAVR (transcatheter aortic valve replacement) era, trans-apical valve-in-valve mitral valve implantation (TA-MVI) is considered an alternative treatment for high risk patients with degenerated mitral bioprosthesis. We report an unusual strategy to remedy to a potentially fatal complication as the mitral prosthesis migration into the aortic arch. The dislocated prosthesis was successfully stabilized in the aortic arch with a bare aortic stent, ensuring an adequate perfusion of epiaortic vessels.

ACCEPTED MANUSCRIPT

During the last decade the development and the improvement of transcatheter valve procedures allowed the treatment also of degenerated bioprosthesis, in mitral position, especially in high risk patients [1]. Despite the excellent results reported, potentially fatal complications are still present. In this report we describe a case of mitral prosthesis dislocation and migration into the aortic arch, and the strategy that have been used to remedy.

An 85-year-old male patient (BSA 1.82 m²) presented with a worsening of exertional dyspnoea (NYHA functional class III). In 2004 he underwent to mitral valve replacement for severe mitral regurgitation with a 31-mm Hancock bioprosthesis and a concomitant coronary artery by-pass grafting (CABG). Co morbidity conditions included a chronic obstructive pulmonary disease, previous major stroke (2013), episodes of digestive hemorrhage due to esophageal varicies, chronic gastritis, abdominal aortic aneurysm and chronic atrial fibrillation. In the last month the patient was admitted in our hospital for heart failure, with evidence of mitral bioprosthetic dysfunction. The echocardiography confirmed the severe bioprosthetic mitral regurgitation with elevated pulmonary artery systolic pressure 55 mmHg, moderate aortic valve regurgitation and a left ventricle (LV) ejection fraction of 61%. Preoperative coronary angiography evidenced good patency of previous by-pass. The patient was evaluated by our “heart team” and considering to be high-risk for a conventional mitral valve replacement (European system for cardiac operative risk evaluation standard 18, logistic 78%) and a transcatheter valve procedure was preferred. The procedure was performed in the hybrid operating room by our cardiovascular team (cardiac surgeons, interventional cardiologists and cardiac anesthesiologist). A left anterior thoracotomy was performed through the fifth intercostal space and transapical access through the pericardial was created. The ventricular apex was punctured with a guidewire, which was advanced through the opening of the mitral prosthesis into the left atrium. Transesophageal echocardiography was not used due to esophageal varicies and the coaxial alignment with the ring of the deteriorated bioprosthesis was guided only by fluoroscopy. Before the introduction of the prosthesis the guidewire was accidentally dislocated towards the aortic valve and the 29-mm Edwards SAPIEN III balloon expandable bioprosthesis (Edwards Lifesciences, Irvine, CA) was wrongly released, through a 21F sheath, in ascending aorta with following migration in aortic arch (figure 1A).

The transesophageal echocardiogram was introduced and a new 29- mm SAPIEN III prosthesis was

immediately implanted in the degenerated bioprosthesis using the same approach under fluoroscopy and echocardiography guidance, during rapid ventricular pacing (figure 1B). Fortunately the position of the dislocated mitral prosthesis, perfectly aligned in the arch, did not interfere with the catheters passage. Considering this, the dislocated prosthesis was then successfully stabilized in the aortic arch introducing through the right femoral artery a bare aortic stent (E-xl 36-32, JOTEC), allowing also an adequate perfusion of epiaortic vessels (figure 1C). The patient was extubated 14 hours after the procedure, no complications occurred, the post-operative chest X-ray showed the right positioning of the prosthesis (figure 2A) and he was discharged from hospital 8 days after valve implantation with warfarin therapy. The pre-discharge echocardiogram showed no mitral regurgitation and any paravalvular leakage, mitral valve area was 2.8 cm² with a mean gradient of 7 mmHg, LV ejection fraction was 43% (figure 2B, 2C).

Comment

The first cases of transcatheter aortic valve in valve implantation, performed in high-risk patient for degenerated aortic bioprosthesis, have been described in 2006 [2] and Cheung reported the first case of transapical transcatheter mitral valve in valve implantation in 2009 [3]. The development of the transcatheter heart valve procedures allowed the treatment of degenerated bioprostheses to become an elegant and viable alternative in high risk patients; further studies have likewise praised the transapical approach to allow direct and coaxial access to the mitral valve. The results presented by Wilbring [4] with the TA-MVI confirmed the feasibility and repeatability of the procedure. However, despite the excellent results, also some complications have been reported. Mick et al. [5] presented a case of valve in valve migration to the left atrium, they planned a novel approach: they planned for a catheter-based transatrial approach for a repeat valve-in-valve procedure via right thoracotomy. One case of late dislodgment, 17 month later, was also reported by Zegdi et al. [6]; to solve the problem a mitral and aortic valve replacement was performed with 2 mechanical bileaflet prostheses. From what we know an unusual complication like this that we reported is not yet present in the literature. The dislocation and consequent migration of the SAPIEN III prosthesis in aortic arch is a catastrophic situation that opens the doors at two different possible scenarios: a re-sternotomy with deep or moderate hypothermic circulatory arrest to recover the mitral prosthesis with a prohibitive risk for the

patients, or trying to resolve the problem with a trans-catheter solution. Our choice was motivated by two important aspects: first, the mitral prosthesis presented a 29mm caliber, enough to be expanded against the aortic wall, secondly the alignment of the dislocated mitral valve in the aortic arch allow the passage of the catheters trough the valve. Taking this into account we used a bare aortic stent to fix the valve but also to allow an adequate brachiocephalic trunk and left carotid artery perfusion. This approach provided an expeditious solution to a challenging problem.

ACCEPTED MANUSCRIPT

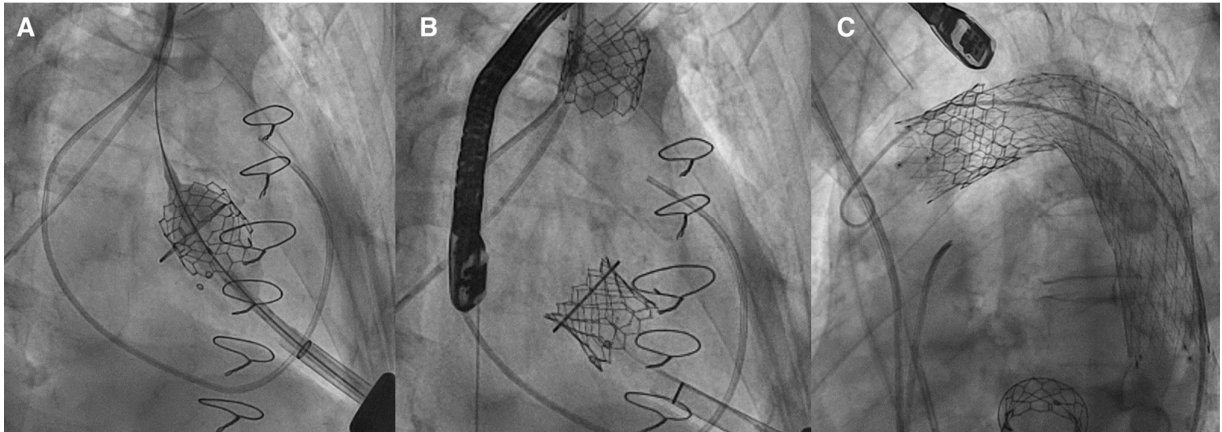
References

1. Elmously A, Worku B, Gray KD, Salemi A. Mitral Valve-in-Valve implantation as an elective or rescue procedure in high risk patients. *Ann Thorac Surg*. 2018 Jan 27.
2. Lichtenstein SV, Cheung A, Ye J, et al. Transapical transcatheter aortic valve implantation in humans: initial clinical experience. *Circulation* 2006;114:591–6.
3. Cheung A, Webb JG, Wong DR, et al. Transapical transcatheter mitral valve-in-valve implantation in a human. *Ann Thorac Surg* 2009;87:e18–20.
4. Manuel Wilbring, MD, Konstantin Alexiou, MD et al. Pushing the limits—further evolutions of transcatheter valve procedures in the mitral position, including valve-in-valve, valve-in-ring, and valve-in-native-ring. *The Journal of Thoracic and Cardiovascular Surgery* c Volume 147, 1.
5. Stephanie L. Mick, MD, Eric E. Roselli, MD, Samir Kapadia, MD, Postoperative Migration of an Edwards-SAPIEN XT Mitral Valve-in-Valve Treated With Direct Vision Implantation During Beating-Heart Bypass *Ann Thorac Surg* 2016;101:1185–8
6. Zegdi R, Allam B, Azarine A, Blanchard D. Late dislodgment of a prosthesis after mitral valve-in-valve implantation. *J Thorac Cardiovasc Surg* 2014;147:e59–61.

Figure Legends

Figure 1. Fluoroscopic image showing (A) the wrong release of 29-mm Edwards SAPIEN prosthesis. (B) the dislocation in arch of 29-mm Edwards SAPIEN prosthesis and the other 29-mm Edwards SAPIEN in mitral position inside the degenerated prosthesis. (C) the bare aortic stent graft (E-xl Aortic stent JOTEC) stabilizing 29-mm Edwards SAPIEN, dislocated in arch.

Figure 2. (A) Post-operative fluoroscopic image showing the right positioning of the prosthesis (B) Three-dimensional transthoracic echocardiography and (C) Bi-dimensional transthoracic echocardiography showing the 29-mm Edwards SAPIEN prosthesis (Edwards Lifesciences LLC, Irvine, CA) successfully placed inside the degenerated 31-mm Hancock bioprosthesis.



ACCEPTED MANUSCRIPT

