



Case report

Pulmonary involvement in adult Still's disease: Case report and brief review of literature



Aldo Guerrieri, Giulia Angeletti*, Massimiliano Mazzolini, Ilaria Bassi, Stefano Nava

Department of Specialistic-Diagnostic and Experimental Medicine (DIMES), Respiratory and Critical Care Unit, S.Orsola-Malpighi Hospital, University of Bologna, Bologna, Italy

ARTICLE INFO

Article history:

Received 22 June 2017

Accepted 1 July 2017

ABSTRACT

Background: Adult onset Still disease (AOSD) is a rare condition characterized by elevated fever along with arthritic symptoms, elevated polymorphonuclear neutrophil count, evanescent rash, and hyperferritinemia. Diagnosis can be made only after have ruled out more frequent conditions, and Yamaguchi or Fautrel criteria should be applied. Parenchymal lung involvement (PLI) is present in less than 5% of AOSD cases and ranges from aspecific reticular interstitial opacities to life threatening conditions, such as acute respiratory distress syndrome (ARDS).

Case: We report the case of a 59 years old man who was referred to our ward because of high fever treated as a pneumonia with antibiotic but not responding to medical treatment, and findings suggestive of interstitial lung disease prevalent in the lower zone on high resolution computed tomography (HRCT). AOSD was diagnosed when the diagnostic Yamaguchi criteria were fulfilled and our suspect was confirmed by the rheumatologist; the patient was then successfully treated with corticosteroids.

Conclusions: PLI in AOSD is very rare but must be considered among differential diagnosis in patients with high fever and aspecific interstitial parenchymal lung involvement.

© 2017 The Authors. Published by Elsevier Ltd. This is an open access article under the CC BY-NC-ND license (<http://creativecommons.org/licenses/by-nc-nd/4.0/>).

1. Introduction

Adult-onset Still disease (AOSD) is a rare inflammatory multi-systemic disease of unknown etiology that was first described in 1971 by Bywaters [1], with an estimated prevalence less than 1/100.000 [2]. AOSD usually presents with high spiking fever, polyarthritis, evanescent salmon-pink rash, sore throat, and lymphadenopathy. Polyarthritis determine joint pain, which is the most common symptom of AOSD and mainly involve wrists, knees and ankles. Fever occurs in 60–100% of the patients and it typically spikes once or twice daily, the highest temperatures (>39 °C) occurring in the evening [3]. Laboratory tests reflect the non specific systemic inflammatory nature of the disease; they include high C-reactive protein (CRP) and erythrocyte sedimentation rate levels, and elevated polymorphonuclear count with a neutrophilic prevalence. As in many other inflammatory disease, in AOSD patients it is possible to observe anemia, thrombocytosis, and elevated ferritin level; however, although a 5-fold increase in the ferritin level is suggestive of AOSD, similar elevated levels can be found also in the

context of infections, neoplastic conditions and storage diseases. For this reason, Fautrel et al. [4] emphasized the needing of combine elevated ferritin level with low glycosylated ferritin to increase the specificity of the diagnosis up to 93%. Along with ferritin and glycosylated ferritin values, Yamaguchi criteria [5] require the presence of five features, with at least two being major diagnostic criteria. The four major Yamaguchi criteria are elevated fever lasting at least one week, arthralgias or arthritis, nonpruritic macular or maculopapular skin rash that is salmon-colored during febrile episodes, and leukocytosis with at least 80 percent granulocytes. The minor Yamaguchi criteria include sore throat, lymphadenopathy, hepatomegaly or splenomegaly, abnormal liver function studies, and negative tests for antinuclear antibody (ANA) and rheumatoid factor (RF). Genetic background has an important role in order to determine susceptibility to develop autoimmune reaction toward ambiental triggers. Interleukine 18 (IL-18) and 1 β (IL-1 β) play a key role in the pathogenesis of the disease, since they activate interleukine 6 (IL-6) and Th1-differentiating cytokines production; moreover, IL-18 and IL-1 β cause natural killer (NK) cells dysregulation, which leads to macrophagic activation. The latter, along with activation of neutrophilic cells, is one of the main biological marker of AOSD [6].

* Corresponding author.

E-mail address: giulia.angeletti@gmail.com (G. Angeletti).

Parenchymal lung involvement during AOSD is rare, and it is thought to be present in less than 5% of all patients. On the other hand, pleural involvement is quite frequent, since 10 to 50% of patients with AOSD experience an episode of pleuritis. Pleurisy may be part of the initial presentation or, more often, may occur during an acute exacerbation of the disease; pleural effusion is often present but is usually small, and there are only few reports on the characteristics of the pleural fluid [7]. In a report [8] the pleural fluid was described as “exudative and sterile”, while in one occasion the pleural fluid turned out to be serosanguinous and exudative [9]. We examine here the case of a 59 years old patient who was diagnosed with AOSD complicated by parenchymal lung involvement.

2. Case report

In September 2016, a 59-years-old smoking man was admitted to our facility. His past medical history was significant only for vitiligo. He had experienced a 6-kg weight loss during the previous 2 months, and he had been discharged 2 days before from a internal medicine ward with the diagnosis of “right basal bronchopneumonia in smoker”. The patient took azithromycin before the hospital stay due to the onset of sore throat and fever. During the first hospitalization he has been treated with amoxicillin-clavulanate and clarithromycin and he was instructed to continue the antibiomatic therapy for one more week. At that time of discharge laboratory tests showed 15.000 white blood cells counts and C-reactive protein (CRP) level of 15 mg/dL. The day following the discharge, the patient was brought to the emergency department because of persistent high fever and pain in the right leg; the abdomen ultrasounds revealed the presence of a 1,9 cm diameter hepatic cyst, and the right leg ultrasounds showed an inflammatory thickening. Chest HRCT revealed the presence of inflammatory interstitial thickening with a subpleural distribution and traction bronchiectasis in both the lower lobes; moreover, there were small subpleural emphysematous bullae in both the upper lobes. The laboratory tests performed in the emergency ward showed leukocytosis (22.220/mL) and high CRP level (23.10 mg/dL). Piperacillin/tazobactam and levofloxacin were started and continued when the patient was referred to our ward. Extended laboratory exams confirmed the leukocytosis with a neutrophilic prevalence (22.220/mL, 89.4%), the elevated CRP level-22.72 mg/dL and erythrocyte sedimentation rate-76 mm per hour; low blood iron level-17 mcg/dL; liver and kidney function tests were normal. High fever persisted in the following days. The infectious diseases specialist suggested to continue the antibiotic treatment; various infectious possibilities were carefully evaluated by performing numerous studies, all of which turned out to be negative (Table 1).

Bronchoscopy with bronchoalveolar lavage (BAL) was

performed. Cytological examination was negative for malignant tumour cells and Mycobacteria microscopic search. The extended polymerase chain reaction (PCR) for respiratory viruses on BAL was also negative. Lymphocyte characterization on BAL showed a prevalence of component T lymphocyte, CD4 + CD103 +. For the persistence of hyperpyrexia, high levels of inflammatory markers, stable aspecific chest radiography opacities, the protocol for fever of unknown origin was applied. Cardiological evaluation was performed with trans-thoracic echocardiogram without images referable to endocarditic vegetations. Serum proteins electrophoresis revealed the presence of hypogammaglobulinemia IgG (464 mg/dL) and blood lymphocyte typing resulted compatible with monoclonal B lymphocytosis. In the suspect of tumoral blood disorder a specific hematological microscopic blood cell count with immunophenotypic analysis was performed. The test showed monoclonal population of B lymphocytes, 1.5% of the total cellularity, which hematologist didn't consider worthy of further investigations. The antibiotic treatment was stopped due to the persistence of fever and absence of respiratory symptoms (cough, dyspnea). Among the numerous investigations carried out (Table 2), the patient also performed pulmonary function tests which demonstrated only a small reduction in DLCO.

After one week of investigations the patient complained right knee articular pain for which ketoprofen was started. After two days the patient showed improvements in symptoms but also in the laboratory tests and in hyperpyrexia. These findings raised the suspect of adult Still's disease. Ferritin dosage showed a high increase in serum levels (3219 ng/dL), which supported the diagnosis. We initiated empiric therapy with ibuprofen, with benefit and performed rheumatological evaluation which confirmed diagnosis of adult Still's disease and started steroid therapy with prednisone 0.8mg/kg/day, with clinical benefit and regression of hyperpyrexia. A new rheumatological evaluation was planned and the patient was discharged afebrile, in good clinical conditions. At the next HRCT (one month later) it was found qualitative improvement of the interstitial reticular opacities (Fig. 1).

3. Discussion

The number of cases reported in literature of parenchymal lung involvement in adult Still's disease is extremely small. PLI in AOSD can be divided in two major categories: one with ARDS and another with other PLIs. In the Mathieu Gerfaud-Valentin et al. case series, ARDS occurred in the 40% of the patients with AOSD and PLI, and

Table 1

Infectious diseases tests. MRSA: methicillin-resistant Staphylococcus Aureus; HIV: Human Immunodeficiency virus.

Pneumococcal and legionella urinary antigens	Negative
Chlamydia, mycoplasma and legionella antibody assays	Negative
Influenza	Negative
Quantiferon Test	Negative
Pharyngeal-tonsillar swab for Streptococcus pyogenes and Influenza A and B	Negative
Nasal cultures for MRSA	Negative
Epstein-Barr virus antibodies assay	IgM negative, IgG positive
Borrelia burgdorferi, Rickettsia conorii, Coxiella burnetii antibodies assays	Negative
HIV antibody assay	Negative
Blood cultures and urine culture	Negative

Table 2

Additional investigations. FVC: Forced vital capacity; FEV1: Forced expiratory volume first second; DLCO: Diffusion Lung Carbon Monoxide; ANA: antinuclear antibodies; ANCA: Anti neutrophil cytoplasmic antibodies; Anti-CCP: anti cyclic citrullinated peptide.

Autoimmune blood tests	ANA, negative ANCA, Ab anti-CCP negative, Immune C1qIgG negative, negative rheumatoid factor, complement C4 in the norm, slight elevation of the complement C3 (201 mg/dL).
Positron Emission Tomography (PET)	Presence of areas of hyperfixation bilaterally at the pulmonary hilar (SUVmax = 3.8 and 4.3 to right and left respectively) and at the level of the Baretty loggia (SUVmax = 3.4). Compatible with inflammatory-infectious process. No obvious Hyperfixant areas in the lung parenchyma. Small and diffuse skeletal fixation compatible with reactive medullary activation of inflammatory-infectious process
Orthopantomogram (OPG)	Structural rarefaction of bone area at focal character, with adjacent bone sclerosis, at the level of the apex medial root of 46. Severe condition of widespread chronic periodontal disease with predominantly horizontal character.
Pulmonary function tests (PFT)	FVC 4.82L/111%, FEV1 3.59/105%, DLCO 19.5 mL/mmHg/min/67%

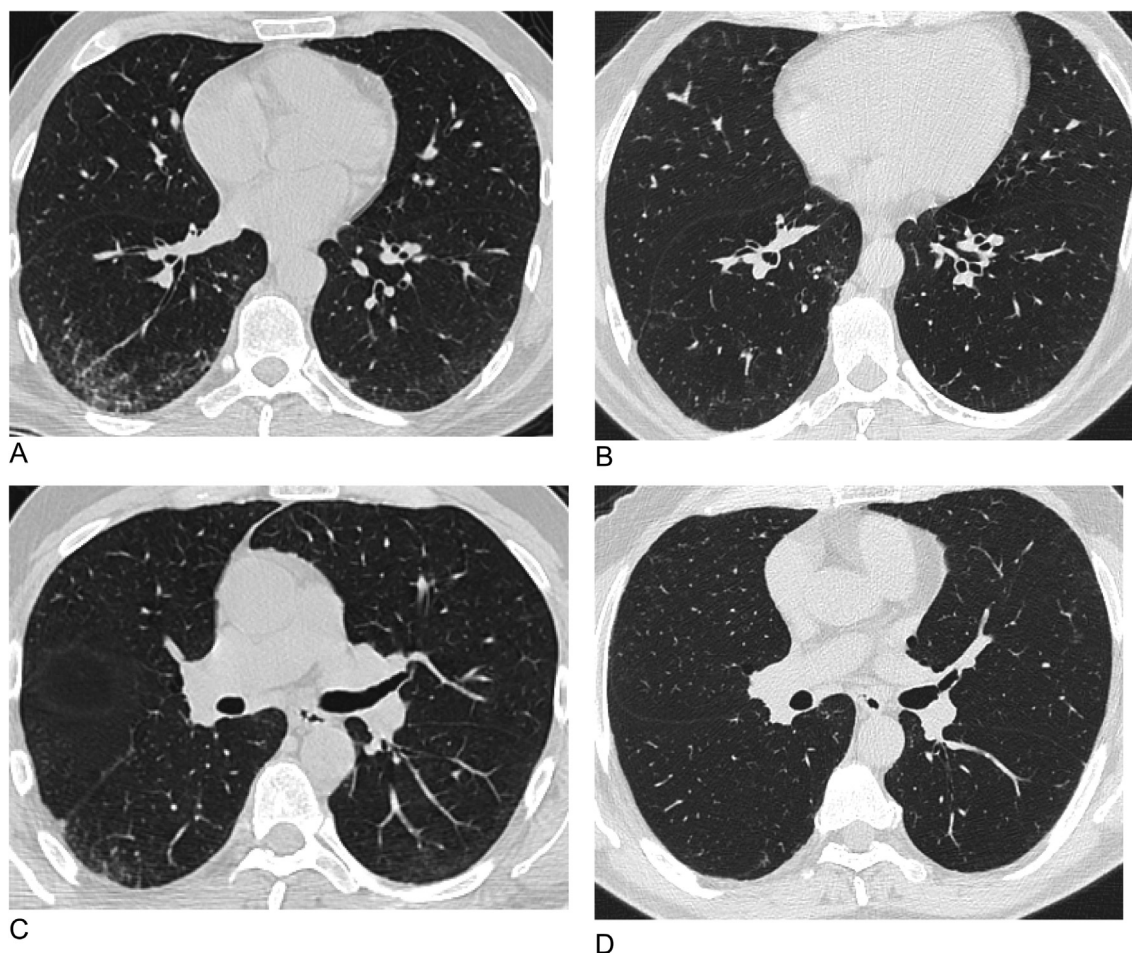


Fig. 1. Comparison between HRCT images before (A and C) and after (B and D) 1 month of high dose steroid therapy.

was moderate or severe - according to Berlin's definition [10] - in 83.3% of the cases [11]. ARDS is thought to be an early complication of AOSD, since it mainly occurs within the first year from diagnosis; moreover, it is the leading cause of death in AOSD-related PLI. Since there are not specific guidelines on the management of ARDS during AOSD, first-line corticosteroid therapy appears to be a reasonable choice; in case of corticosteroid failure, clinicians should consider to start a treatment with IL-1 receptor antagonist (anakinra) or with the humanized anti-IL-6 receptor antibody (tocilizumab). Considering the non-ARDS PLI in AOSD, the most frequent pattern is chronic interstitial lung disease; it occurs mainly during systemic AOSD and at any time during the course of the disease, but it is more rare during chronic rheumatic AOSD. In the Mathieu Gerfaud-Valentin et al. case series [11], the most frequent respiratory symptoms in patients with non-ARDS PLI were cough, dyspnea and chest pain, while the main HRCT patterns were nonspecific interstitial, pneumonia, organizing pneumonia, and unclassified interstitial lung disease; in addition, infrequent imaging findings included pneumomediastinum, atelectasis, excavated nodules and bronchiectasis. PFTs were occasionally performed, but when done they showed restrictive lung function or isolated decreased DLCO; occasionally, PFTs reported an obstructive pattern. Similarly, BAL analysis were rarely available, and the differential cell count usually had neutrophilic profile; anyway, this is not specific for PLI-AOSD. In our case we found an increase in CD103+CD4 lymphocyte in BAL which, although aspecific, can be found in other diffuse parenchymal diseases [12]. Summarizing, imaging and histological

data allow to divide the non-ARDS PLI in AOSD into two groups: a predominant airway involvement with bronchitis and bronchiolitis, and a predominant interstitial lung disease [11]. Treatment of AOSD and PLI-AOSD remains empirical. Corticosteroids are the first-line treatment for AOSD, without considering the clinical presentation; moreover, corticosteroids have greater efficacy toward systemic symptoms than articular ones. Methotrexate remains the first-line steroid-sparing therapy in AOSD, while anakinra and tocilizumab are possible alternatives. Apart from methotrexate, other disease-modifying antirheumatic drugs (such as cyclosporin A, leflunomide, azathioprine, hydroxychloroquine, D-penicillamine and tacrolimus) had infrequently shown positive results; thus, these agents cannot be recommended unless severe complications occur and other more specific drugs have failed [13]. Data regarding intravenous immunoglobulin are more subject to controversy, and this treatment should be considered only in case of reactive hemophagocytic lymphohistiocytosis and in some other life-threatening conditions. Lack of clinical response both to corticosteroids and second-line disease-modifying antirheumatic drugs define "refractory AOSD", which should be treated with biologic agents, such as anti-tumor necrosis factor (TNF) (ie, infliximab, etanercept, adalimumab), IL-1 antagonist (anakinra), and tocilizumab.

4. Conclusion

AOSD can present with parenchymal lung involvement, and it

can be easily treated with steroid therapy. Therefore, AOSD should be considered in the differential diagnosis of lung aspecific radiologic findings in combination with elevated fever.

References

- [1] E.G. Bywaters, Still's disease in the adult, *Ann. Rheum. Dis.* 30 (2) (1971) 121–133.
- [2] Y. Jamilloux, M. Gerfaud-Valentin, T. Henry, et al., Treatment of adult-onset Still's disease: a review, *Ther. Clin. Risk Manag.* 11 (2015) 33–43.
- [3] M. Gerfaud-Valentin, Y. Jamilloux, J. Iwaz, et al., Adult-onset Still's disease, *Autoimmun. Rev.* 13 (2014) 708–722.
- [4] B. Fautrel, E. Zing, J.-L. Golmard, et al., Proposal for a new set of classification criteria fo adult-onset Still disease, *Med. Baltim.* 81 (2002) 194–200.
- [5] M. Yamaguchi, A. Otha, T. Tsunematsu, et al., Preliminary criteria for classification of adult Still's disease, *J. Rheumatol.* 19 (1992) 424–430.
- [6] A. Kontzias, P. Efthimiou, Adult-onset Still's disease: pathogenesis, clinical manifestations and therapeutic advances, *Drugs* 68 (3) (2008) 319–337.
- [7] G.S. Cheema, F.P. Quismorio Jr., Pulmonary involvement in adult-onset Still's disease, *Curr. Opin. Pulm. Med.* 5 (5) (1999 Sep) 305–309. Review.
- [8] J. Pouchot, J.S. Sampalis, F. Beaudet, S. Carette, F. Decary, M. Salusinsky-Sternbach, et al., Adult Still's disease: manifestations, disease course, and outcome in 62 patients, *Med. Baltim.* 70 (1991) 118–135.
- [9] K.G. Moder, R.D. Miller, G.L. Allen, Cardiac tamponade: an unusual feature of adult onset Still's disease, *J. Rheumatol.* 22 (1995) 180–182.
- [10] V.M. Ranieri, G.D. Rubenfeld, B.T. Thompson, et al., Acute respiratory distress syndrome: the Berlin definition, *JAMA* 307 (2012) 2526–2533.
- [11] Mathieu Gerfaud-Valentin, et al., Parenchymal lung involvement in adult-onset Still disease A STROBE-compliant case series and literature review, *Medicine* 95 (2016) 30.
- [12] M. Heron, W.A. Sliker, P. Zanen, E.G. van Lochem, H. Hooijkaas, J.M. van den Bosch, H. van Velzen-Blad, Evaluation of CD103 as a cellular marker for the diagnosis of pulmonary sarcoidosis, *Clin. Immunol.* 126 (3) (2008 Mar) 338–344.
- [13] Y. Jamilloux, M. Gerfaud-Valentin, T. Henry, et al., Treatment of adultonset Still's disease: a review, *Ther. Clin. Risk Manag.* 11 (2015) 33–34.