



LJMU Research Online

Towle, I and Irish, JD

Periapical lesions in hominids: Abscesses on the maxilla of a 2 million-year-old early Homo specimen

<http://researchonline.ljmu.ac.uk/id/eprint/11217/>

Article

Citation (please note it is advisable to refer to the publisher's version if you intend to cite from this work)

Towle, I and Irish, JD (2019) Periapical lesions in hominids: Abscesses on the maxilla of a 2 million-year-old early Homo specimen. International Journal of Osteoarchaeology. ISSN 1047-482X

LJMU has developed **LJMU Research Online** for users to access the research output of the University more effectively. Copyright © and Moral Rights for the papers on this site are retained by the individual authors and/or other copyright owners. Users may download and/or print one copy of any article(s) in LJMU Research Online to facilitate their private study or for non-commercial research. You may not engage in further distribution of the material or use it for any profit-making activities or any commercial gain.

The version presented here may differ from the published version or from the version of the record. Please see the repository URL above for details on accessing the published version and note that access may require a subscription.

For more information please contact researchonline@ljmu.ac.uk

<http://researchonline.ljmu.ac.uk/>

Periapical lesions in hominids: Abscesses on the maxilla of a 2 million-year-old early *Homo* specimen

Ian Towle¹ and Joel D. Irish^{1,2}

¹Research Centre in Evolutionary Anthropology and Palaeoecology, School of Natural Sciences and Psychology, John Moores University, Liverpool, United Kingdom, L3 3AF

²Evolutionary Studies Institute and Centre for Excellence in PaleoSciences, University of the Witwatersrand, Private Bag 3, WITS 2050, South Africa.

Keywords: dental pathology, hominin, periapical lesions, South Africa, tooth wear

Author contact details:

Ian Towle: ianetowle@hotmail.co.uk

Joel Irish: j.d.irish@ljmu.ac.uk

Abstract

Periapical lesions can develop after exposure of a tooth's pulp chamber and are commonly associated with heavy crown wear, trauma, or caries. In this study, maxilla and mandible fragments from the South African fossil hominin collections were studied, including specimens assigned to *Homo naledi*, *Paranthropus robustus*, *Australopithecus africanus*, and early *Homo*. *Gorilla gorilla gorilla*, *Pan troglodytes*, and *Homo sapiens* were also studied for comparative purposes. Only one fossil hominin specimen displayed voids consistent with periapical lesions. The specimen, SK 847, is described as early *Homo* and has been dated to 2.3–1.65 Ma. There is one definite periapical lesion and likely more with post-mortem damage, all on the anterior aspect of the maxilla and associated with the incisors. The lesions originate from the apices of the incisor roots and are therefore unlikely to represent a systemic disease such as multiple myeloma. The one well-preserved lesion was likely an abscess rather than a cyst or granuloma, with a rounded thickened rim around the lesion. These lesions in an early *Homo* specimen highlight that this individual used their anterior dentition extensively, to the point that the pulp chambers were exposed on multiple teeth. This is one of the earliest hominin examples of periapical lesions and shows that this individual was able to cope with potentially several concurrent abscesses, clearly surviving for an extended period. Periapical lesions are relatively common in the great ape (*P. troglodytes*: 1.99%; *G. gorilla gorilla*: 1.86%) and human samples (2.50%) but absent in large samples of *P. robustus* and *A. africanus* ($n = 0/373$ teeth). Therefore, this finding adds additional information to the history of dental pathology in our genus and also suggests that other hominin genera may have been less susceptible to dental abscesses, potentially relating to dietary or behavioural differences.

Introduction

Abscesses and other periapical voids are commonly found in the mandible and maxilla of humans and other animals (e.g., Eshed, Gopher, & Hershkovitz, 2006; Jurmain, 1990; Miles & Grigson, 2003; Sauther, Sussman, & Cuzzo, 2002; Schultz, 1956). These voids can develop after exposure of a tooth's pulp chamber, often through heavy wear (i.e., attrition or abrasion), trauma, and caries (Dias, Prasad, & Santos, 2007; Linn, Srikandi, Clarke, & Smith, 1987; Nair, 2004). As well as abscesses, other types of periapical voids include cysts, fenestrations, and granulomata, and concerns have been raised about the incorrect use of these different terms in archaeological studies (Dias et al., 2007; Dias & Tayles, 1997; Nair, 2004). In particular, the majority of voids may be painless granulomata, with evidence suggesting that less than a third may be chronic abscesses (Ogden, 2008). However, because a granuloma can become a cyst, both can become an abscess, and there is disagreement as to how to define each type (see Dias et al., 2007); there will be times when a lesion is difficult to decipher in the archaeological record.

The frequency of periapical voids varies substantially among human populations, as well as nonhominin primate species (Cuzzo & Sauther, 2012; Dias & Tayles, 1997; Eshed et al., 2006; Lieverse, Link, Bazaliiskiy, Goriunova, & Weber, 2007; Miles & Grigson, 2003; Schultz, 1956; Stoner, 1995). Until recently, they had rarely been reported in the *Homo* fossil record (Gracia-Télez et al., 2013; Lacy, 2014; Lacy et al., 2012; Leek, 1966; Margvelashvili, Zollikofer, Lordkipanidze, Tafforeau, & Ponce de León, 2016; Martín-Torres et al., 2011; Rosas et al., 2006). There are also potential periapical lesions in other hominin genera (e.g., Haile-Selassie, 2001; Schwartz & Tattersall, 2005; Wood, 1991). The most important factor in extant primates, as a whole, is severe occlusal attrition (Legge, 2012). Great apes tend to have higher rates than do other primates, with the canine most frequently involved (Schultz, 1956).

In this study, we recorded the presence/absence of periapical voids in South African fossil hominins, as well as two species of extant great apes and modern humans. Our working hypothesis was that their presence in fossil hominins likely resulted from crown wear, given its ubiquity in many hominin specimens, rather than caries, which are comparatively uncommon (Grine, Gwinnett, & Oaks, 1990; Towle et al., 2019).

Materials and methods

All maxilla and mandible fragments available for study in the South African fossil hominin collections were observed, including specimens assigned to *Homo naledi*, *Paranthropus robustus*, *Australopithecus africanus*, and early *Homo*. All specimens are curated at the Ditsong National Museum of Natural History and University of the Witwatersrand. The comparative great ape samples (*Gorilla gorilla gorilla* and *Pan troglodytes*) are curated at the Powell-Cotton Museum in Kent, UK; all were wild shot early in the 20th century (Guatelli-Steinberg & Skinner, 2000; Macho & Lee-Thorp, 2014). The modern *Homo sapiens* sample is from a mediaeval cemetery in Gloucester, UK, and is curated at Liverpool John Moores University. Table 1 lists the number of specimens studied and the number of teeth not recorded for periapical lesions due to the absence of associated alveolar bone or post-mortem damage. For specimen and species classifications, see Towle (2017).

Table 1. Number of teeth recorded for each species and those not recorded—due to lack of associated alveolar or post-mortem damage.

Species	# teeth recorded	# teeth not recorded
<i>A. africanus</i>	141	362
<i>P. robustus</i>	232	228
<i>H. naledi</i>	32	122
Early <i>Homo</i>	15	55
<i>P. troglodytes</i>	2508	7
<i>G. gorilla gorilla</i>	2099	5
<i>H. sapiens</i>	961	21

All lesions were photographed using a Dino-Lite® AM2111 hand-held microscope, 10 \times to 50 \times zoom magnification. Any ante-mortem bone voids present in a maxilla or mandible associated with a tooth root apex were recorded. Systemic diseases such as multiple myeloma and metastatic carcinoma were not recorded but have been described in the literature (e.g., Odes et al., 2018). A tooth had to have all the surrounding bone present to be included (Table 1). Methods suggested by Dias and Tayles (1997) and Ogden (2008) were used to describe lesions and to suggest an aetiology.

Only one fossil hominin specimen displays clear periapical voids, that is, SK 847, described as early *Homo* dated to 2.3–1.65 Ma (Tobias, 1991). Although the phylogenetic

placement and associated material of this specimen have been debated, it is commonly placed in the genus *Homo* (e.g., Berger et al., 2015; Grine, Demes, Jungers, & Cole, 1993; Schwartz & Tattersall, 2003). It is usually referred to as SK 847, after two fragments were incorporated (Clarke & Howell, 1972; Grine et al., 1993). As well as the maxilla, the specimen also has much of the frontal cranium present (figure 9.1a) and has been associated with different mandibles (Clarke & Howell, 1972; Grine et al., 1993). In the anterior dentition, only the left lateral maxillary incisor remains, with severe wear evident (wear grade 8 in Smith, 1984; figure 1.1c). Alveoli and broken roots for several other teeth are present (Figure 1). In-depth descriptions of the specimen are available in Robinson (1953), Clarke (1979), and Schwartz and Tattersall (2003).

Results and discussion

Table 2 displays the prevalence of periapical lesions for each sample, divided according to anterior and posterior teeth. Only permanent teeth are included due to small sample sizes for deciduous teeth. In addition, only three deciduous teeth, all *P. troglodytes*, are associated with periapical voids. In *G. gorilla gorilla*, it is predominantly permanent canines affected (8.48% with periapical lesion). The same is evident for *P. troglodytes* (i.e., 4%), but the anterior dentition as a whole shows a high prevalence compared with posterior. In contrast, the posterior teeth are predominantly affected in modern humans. These results support dietary and behavioural studies in these groups. Caries is common in the posterior teeth of most agricultural human samples, including this one, which likely explains the high rate of periapical lesions in this region of the dentition. *G. gorilla gorilla* is known to fracture canines regularly and also exhibit extensive anterior tooth wear and damage, to explain their pattern (Schultz, 1956). *P. troglodytes* not only have similar issues with their canines but also use their anterior teeth extensively in food processing, likely explaining the high prevalence of lesions (Hylander, 1975; McGrew, 1999; van Casteren et al., 2018). Therefore, the results for extant primates suggest that these bony lesions may be a useful indicator of diet, behaviour, and health in fossil samples.

On the basis of macroscopic observations, it is possible to conclude that the SK 847 individual likely had at least two/three periapical voids at the time of death; all are associated with the incisors and likely relate to extensive crown wear (Figure 1d). Future microcomputed tomography scans could provide more information. Several voids evidence

substantial post-mortem damage; however, this may relate to a prior periapical lesion, given the definite void associated with the left upper central incisor (Figure 1e). The left upper central incisor is absent, likely post-mortem, judging by the lack of alveolar resorption. There is also a potential lesion on the lingual surface, from what could have been a drainage channel associated with right lateral incisor. However, this void may instead be an unusual foramen, as noted by Robinson (1953; Figure 1b). The heavy wear on the remaining teeth, in particular the removal of most enamel on the left lateral incisor and presence of tertiary dentine, suggests the periapical voids resulted from pulp chamber perforation (Towle, 2019). They originate from the apices of the incisor roots so are unlikely to result from a systemic disease such as multiple myeloma (Dias & Tayles, 1997). The most complete void best fits the description of an abscess rather than cyst or granuloma, with a rounded thickened rim around the void (Figure 1e; Dias & Tayles, 1997; Ogden, 2008).

Table 2. Periapical lesion prevalence for each sample.

	<i>A. africanus</i>	<i>P. robustus</i>	<i>H. naledi</i>	Early <i>Homo</i>	<i>P. troglodytes</i>	<i>G. gorilla gorilla</i>	<i>H. sapiens</i>
Posterior teeth							
No periapical lesion	94	161	22	10	1572	1299	548
Periapical lesion	0	0	0	0	20	9	17
% of teeth with lesions	0%	0%	0%	0%	1.26%	0.69%	2.91%
Anterior teeth							
No periapical lesion	47	71	10	3	886	761	368
Periapical lesion	0	0	0	2	30	30	7
% of teeth with lesions	0%	0%	0%	40.00%	3.28%	3.79%	1.86%
% of all teeth with lesions	0%	0%	0%	13.33%	1.99%	1.86%	2.50%

Robinson (1953) first described this specimen, which at the time consisted only of the maxilla (SK 80), with a focus on its morphology; the extreme incisor wear was also noted and described. Clarke (1979) concentrated on the morphology as well, though described the state of preservation and maxillary voids. He did not mention whether the latter was ante-mortem or post-mortem but reported potential periodontitis on the lingual aspect of the right lateral incisor (Clarke, 1979; Figure 1b). Thus, the present study builds on this research and suggests that the individual suffered from several connected dental issues, that is, extreme wear, dental abscesses, and potentially periodontal disease. Given the small sample size for early *Homo* in this study, it is not possible to conclude if these characteristics were common in this and other early individuals/species in this genera.

[Figure 1 here]

Extreme wear removed the enamel on the anterior teeth and much of the dentine, which ultimately led to exposure of the root canals when reparative tertiary dentine could not be formed quickly enough in response. Subsequently, based on clinical progression, periapical periodontitis would have occurred, caused by chronic root canal infection. Eventually, several periapical cysts would have formed in the anterior maxilla of this individual's mouth and ultimately to abscesses (Dias & Tayles, 1997). This process is common in modern humans, with maxillary anterior teeth most affected (Nair, 2004). Similar lesions caused by heavy wear have been found in archaeological samples of hunter-gatherers (Eshed et al., 2006; Lieverse et al., 2007), as well as in extant primates (Cuozzo & Sauter, 2012). Abscesses and other periapical voids have rarely been reported in fossil remains, but recent studies suggest that they may not be as uncommon as once thought (e.g., Gracia-Téllez et al., 2013; Lacy, 2014; Lacy et al., 2012; Margvelashvili et al., 2016; Martín-Torres et al., 2011). In particular, such voids were described in another specimen of early *Homo* (i.e., Mandible D2600 from Dmanisi), which potentially belongs to the same species, *Homo erectus*, and is roughly contemporary with SK 847, dating to 1.77 Ma (Margvelashvili et al., 2016). Periapical voids have also been frequently described in later *Homo* (Gracia-Téllez et al., 2013; Lebel et al., 2001; Rosas et al., 2006), though not all were wear related, for example, Kabwe 1 (Lacy, 2014). Considerable wear and associated periapical lesions on the anterior dentition were likely common in a variety of *Homo* species, further suggesting that incisors and canines were used extensively in food processing or for nonmasticatory activities (Clarke, 2012; Clement, Hillson, & Aiello, 2012; Estalrich & Rosas, 2013; Frayer et al., 2016; Lozano, Mosquera, De Castro, Arsuaga, & Carbonell, 2009; Wood & Strait, 2004).

The voids in the SK 847 maxilla are therefore of interest on several levels. First, at 2.3–1.65 Ma, this is one of the earliest clear examples of dental abscessing in fossil hominins yet known. Second, the number and severity of these voids suggest that the individual suffered with them for some time. That said, third, their severity and unhealed state might also indicate that they contributed to the individual's death, that is, septicemia (Gracia-Téllez et al., 2013). Finally, the lack of any periapical lesions in the remaining South African fossil hominin specimens, including large samples of *P. robustus* and *A. africanus*, suggests that this individual and perhaps early *Homo* on a broader scale practised a novel behaviour. She/he

may have regularly processed abrasive food items with her/his incisors (i.e., attrition) or, perhaps, used them for a nonmasticatory activity, such as a “third hand” (in which case, the wear would be characterized as abrasion).

In any event, this and alternate evidence of dentition-related behaviour in the South African collections, for example, anterior root grooves in an *A. africanus* specimen (Towle, Irish, Elliott, & De Groote, 2018) and high rates of enamel fractures in *H. naledi* (Towle, Irish, & De Groote, 2017), help personalize the study of our hominin ancestors and relatives. In this case, the SK 847 abscesses provide some measure of individuality to this once-living individual.

Acknowledgements

The authors thank L. Berger and B. Zipfel from the University of the Witwatersrand and S. Potze from the Ditsong Museum of South Africa for access to their collections. This research was supported by a studentship to the first author from Liverpool John Moores University.

References

- Berger, L. R., Hawks, J., de Ruiter, D. J., Churchill, S. E., Schmid, P., Deleuzene, L. K., ... & Skinner, M. M. 2015. *Homo naledi*, a new species of the genus *Homo* from the Dinaledi Chamber, South Africa. *Elife* **4**: e09560.
- Clarke, R. J. 1979. The cranium of the swartkrans hominid, sk 847 and its relevance to human origins (Doctoral dissertation, University of the Witwatersrand, Johannesburg).
- Clarke, R. J., & Howell, F. C. 1972. Affinities of the Swartkrans 847 hominid cranium. *American Journal of Physical Anthropology* **37(3)**: 319-335.
- Clarke, R. J. (2012). A *Homo habilis* maxilla and other newly-discovered hominid fossils from Olduvai Gorge, Tanzania. *Journal of Human Evolution*, **63(2)**, 418-428.
- Clement, A. F., Hillson, S. W., & Aiello, L. C. 2012. Tooth wear, Neanderthal facial morphology and the anterior dental loading hypothesis. *Journal of Human Evolution*, **62(3)**, 367-376.

Cuozzo, F. P., & Sauter, M. L. 2012. What is dental ecology?. *American Journal of Physical Anthropology* **148(2)**: 163-170.

Dias, G., & Tayles, N. 1997. 'Abscess cavity'—a misnomer. *International Journal of Osteoarchaeology* **7(5)**: 548-554.

Dias, G. J., Prasad, K., & Santos, A. L. 2007. Pathogenesis of apical periodontal cysts: guidelines for diagnosis in palaeopathology. *International Journal of Osteoarchaeology*, **17(6)**, 619-626.

Eshed, V., Gopher, A., & Hershkovitz, I. 2006. Tooth wear and dental pathology at the advent of agriculture: new evidence from the Levant. *American Journal of Physical Anthropology* **130(2)**: 145-159.

Estalrich, A., & Rosas, A. (2013). Handedness in Neandertals from the El Sidrón (Asturias, Spain): evidence from instrumental striations with ontogenetic inferences. *PloS one*, **8(5)**, e62797.

Fruyer, D. W., Clarke, R. J., Fiore, I., Blumenshine, R. J., Pérez-Pérez, A., Martínez, L. M., ... & Bondioli, L. 2016. OH-65: The earliest evidence for right-handedness in the fossil record. *Journal of Human Evolution*, **100**: 65-72.

Gracia-Téllez, A., Arsuaga, J. L., Martínez, I., Martín-Francés, L., Martín-Torres, M., de Castro, J. M. B., ... & Lira, J. 2013. Orofacial pathology in *Homo heidelbergensis*: The case of Skull 5 from the Sima de los Huesos site (Atapuerca, Spain). *Quaternary International* **295**: 83-93.

Grine, F. E., Gwinnett, A. J., & Oaks, J. H. 1990. Early hominid dental pathology: interproximal caries in 1.5 million-year-old *Paranthropus robustus* from Swartkrans. *Archives of Oral Biology* **35(5)**: 381-386.

Grine, F. E., Demes, B., Jungers, W. L., & Cole, T. M. 1993. Taxonomic affinity of the early *Homo* cranium from Swartkrans, South Africa. *American Journal of Physical Anthropology* **92(4)**: 411-426.

- Guatelli-Steinberg, D., & Skinner, M. 2000. Prevalence and etiology of linear enamel hypoplasia in monkeys and apes from Asia and Africa. *Folia Primatologica*, **71(3)**, 115-132.
- Haile-Selassie, Y. 2001. Late Miocene hominids from the middle Awash, Ethiopia. *Nature*, **412(6843)**, 178.
- Jurmain, R. 1990. Paleoepidemiology of a central California prehistoric population from CA-Ala-329: Dental disease. *American Journal of Physical Anthropology*, **81(3)**, 333-342.
- Lacy, S. A., Wu, X. J., Jin, C. Z., Qin, D. G., Cai, Y. J., & Trinkaus, E. 2012. Dentoalveolar paleopathology of the early modern humans from Zhirendong, South China. *International Journal of Paleopathology* **2(1)**: 10-18.
- Lacy, S. A. 2014. The oral pathological conditions of the Broken Hill (Kabwe) 1 cranium. *International Journal of Paleopathology* **7**: 57-63.
- Leek, F. F. 1966. Observations on the dental pathology seen in ancient Egyptian skulls. *The Journal of Egyptian Archaeology* **52(1)**: 59-64.
- Lebel, S., Trinkaus, E., Faure, M., Fernandez, P., Guérin, C., Richter, D., ... & Wagner, G. A. 2001. Comparative morphology and paleobiology of Middle Pleistocene human remains from the Bau de l'Aubesier, Vaucluse, France. *Proceedings of the National Academy of Sciences* **98(20)**: 11097-11102.
- Legge, S. S. 2012. Dentoalveolar abscess variation among three groups of chimpanzees (*Pan troglodytes schweinfurthii*, *Pan troglodytes troglodytes*, and *Pan paniscus*). *International Journal of Paleopathology* **2(1)**: 1-9.
- Lieverse, A. R., Link, D. W., Bazaliiskiy, V. I., Goriunova, O. I., & Weber, A. W. 2007. Dental health indicators of hunter-gatherer adaptation and cultural change in Siberia's Cis-Baikal. *American Journal of Physical Anthropology* **134(3)**: 323-339.
- Linn, J., Srikandi, W., Clarke, N. G., & Smith, T. 1987. Radiographic and visual assessment of alveolar pathology of first molars in dry skulls. *American Journal of Physical Anthropology* **72(4)**: 515-521.

- Lozano, M., Mosquera, M., De Castro, J. M. B., Arsuaga, J. L., & Carbonell, E. (2009). Right handedness of *Homo heidelbergensis* from Sima de los Huesos (Atapuerca, Spain) 500,000 years ago. *Evolution and Human Behavior*, **30(5)**, 369-376.
- Macho, G. A., & Lee-Thorp, J. A. 2014. Niche partitioning in sympatric Gorilla and Pan from Cameroon: Implications for life history strategies and for reconstructing the evolution of hominin life history. *PLoS one*, **9(7)**, e102794.
- Margvelashvili, A., Zollikofer, C. P., Lordkipanidze, D., Tafforeau, P., & Ponce de León, M. S. 2016. Comparative analysis of dentognathic pathologies in the D manisi mandibles. *American Journal of Physical Anthropology* **160(2)**: 229-253.
- Martinón-Torres, M., Martín-Francés, L., Gracia, A., Olejniczak, A., Prado-Simón, L., Gómez-Robles, A., ... & de Castro, J. M. B. 2011. Early Pleistocene human mandible from Sima del Elefante (TE) cave site in Sierra de Atapuerca (Spain): a palaeopathological study. *Journal of Human Evolution* **61(1)**: 1-11.
- Miles, A. E. W., & Grigson, C. 2003. *Colyer's Variations and Diseases of the Teeth of Animals*. Cambridge: Cambridge University Press.
- Nair, P. N. R. 2004. Pathogenesis of apical periodontitis and the causes of endodontic failures. *Critical Reviews in Oral Biology & Medicine* **15(6)**: 348-381.
- Odes, E. J., Delezene, L. K., Randolph-Quinney, P. S., Smilg, J. S., Augustine, T. N., Jakata, K., & Berger, L. R. 2018. A case of benign osteogenic tumour in *Homo naledi*: Evidence for peripheral osteoma in the UW 101-1142 mandible. *International Journal of Paleopathology* **21**: 47-55.
- Ogden, A. 2008. Advances in the palaeopathology of teeth and jaws. In: Pinhasi, R., & Mays, S. (Eds.), *Advances in Human Palaeopathology*, 283-307. Hoboken: John Wiley & Sons.
- Robinson, J. T. 1953. Telanthropus and its phylogenetic significance. *American Journal of Physical Anthropology* **11(4)**: 445-502.
- Rosas, A., Martínez-Maza, C., Bastir, M., García-Taberner, A., Lalueza-Fox, C., Huguet, R., ... & Martínez, E. 2006. Paleobiology and comparative morphology of a late Neandertal sample

from El Sidrón, Asturias, Spain. *Proceedings of the National Academy of Sciences* **103(51)**: 19266-19271.

Sauther, M. L., Sussman, R. W., & Cuozzo, F. 2002. Dental and general health in a population of wild ring-tailed lemurs: a life history approach. *American Journal of Physical Anthropology* **117(2)**: 122-132.

Schultz, A. H. 1956. The occurrence and frequency of pathological and teratological conditions and of twinning among non-human primates. *Primatolo Gia* 965-1014.

Schwartz, J. H., & Tattersall, I. 2003. The human fossil record, craniodental morphology of genus *Homo* (Africa and Asia) (Vol. 2). John Wiley & Sons.

Schwartz, J. H., & Tattersall, I. 2005. The Human Fossil Record, Craniodental Morphology of Early Hominids (Genera *Australopithecus*, *Paranthropus*, *Orrorin*), and Overview, vol. 4. WileyLiss, New York.

Smith, B. H. 1984. Patterns of molar wear in hunter-gatherers and agriculturalists. *American Journal of Physical Anthropology* **63(1)**: 39-56.

Stoner, K. E. 1995. Dental pathology in *Pongo satyrus borneensis*. *American Journal of Physical Anthropology*, **98(3)**, 307-321.

Tobias, P. V. 1991. The Skulls, Endocasts and Teeth of *Homo habilis*. Olduvai Gorge (Cambridge Univ. Press, Cambridge, 1991).

Towle, I. E. 2017. Dental pathology, wear and developmental defects in South African hominins (Doctoral dissertation, Liverpool John Moores University).

Towle, I., Irish, J. D., Elliott, M., & De Groote, I. 2018. Root grooves on two adjacent anterior teeth of *Australopithecus africanus*. *International Journal of Paleopathology* **22**: 163-167.

DOI: [10.1016/j.ijpp.2018.02.004](https://doi.org/10.1016/j.ijpp.2018.02.004)

Towle, I., Irish, J. D., & De Groote, I. 2017. Behavioral inferences from the high levels of dental chipping in *Homo naledi*. *American Journal of Physical Anthropology* **164(1)**: 184-192.

DOI: [10.1002/ajpa.23250](https://doi.org/10.1002/ajpa.23250)

Towle, I., Riga, A., Irish, J. D., Dori, I., Menter, C., & Moggi-Cecchi, J. 2019. Root caries on a *Paranthropus robustus* third molar from Drimolen. *bioRxiv* 573964. DOI: 10.1101/573964

Towle, I. 2019. Tertiary dentine frequencies in extant great apes and fossil hominins. *Open Quaternary*, **5(1)**.

Wood, B. 1991. Koobi Fora research project: Hominid cranial remains (Vol. 4). Oxford University Press, USA.

Wood, B., & Strait, D. 2004. Patterns of resource use in early *Homo* and *Paranthropus*. *Journal of Human Evolution*, **46(2)**, 119-162.

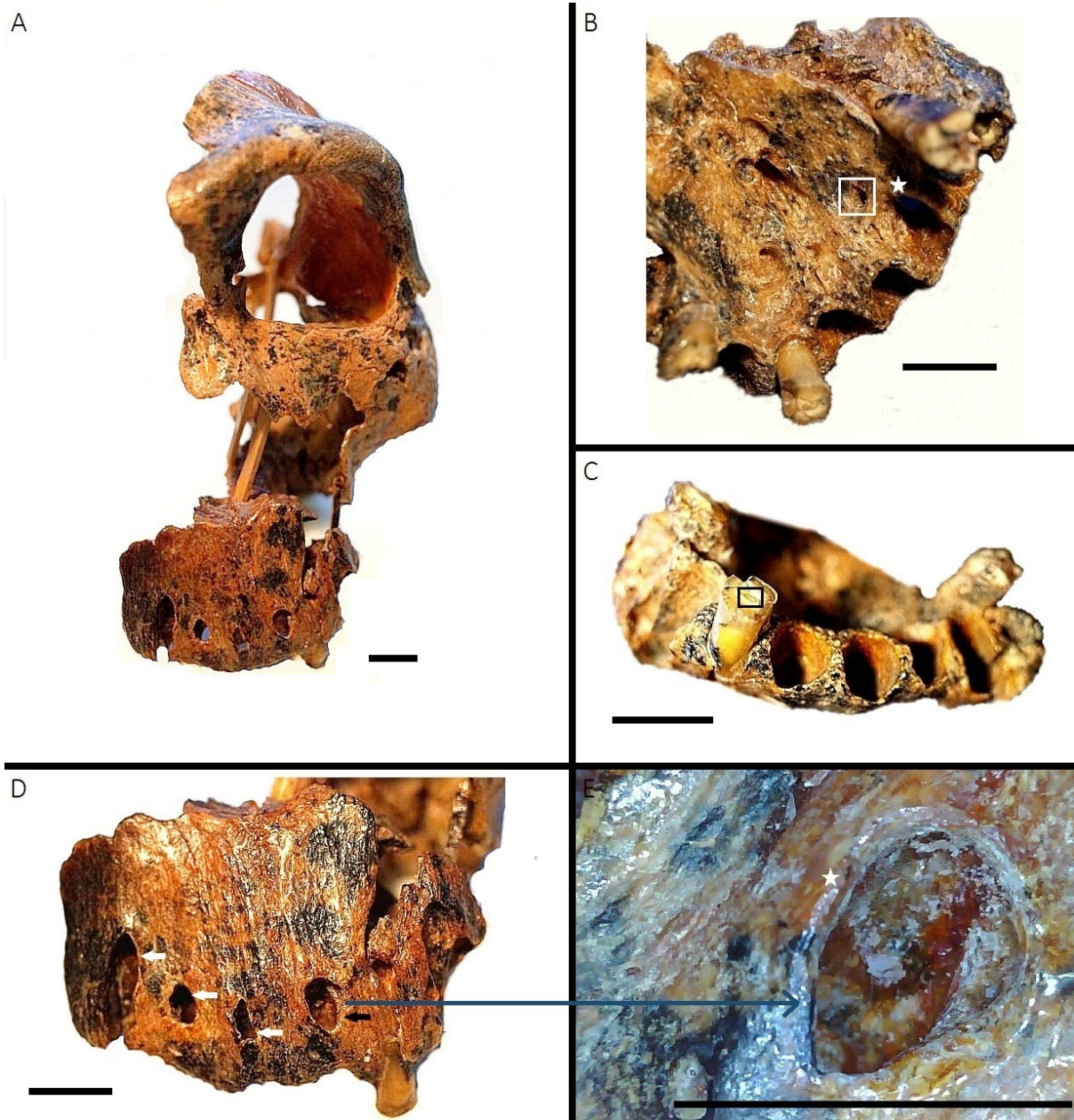


Figure 1. Specimen SK 847 (early *Homo*): A) overview of the entire specimen; B) lingual aspect. The white square shows location of possible periapical lesion and white star a potential area of periodontal disease; C) heavy wear on left lateral upper incisor. Black square highlights tertiary dentine formation; D) buccal periapical lesion (black arrow). White arrows indicate potential additional lesions with postmortem damage; E) detail of buccal abscess, showing thickened bone around circumference of the abscess (white star). All scale bars 1cm.