



CASE REPORT

Adrenocortical Serous Cystadenoma in a Cat

G Spinella, B Brunetti, S Valentini*, A Diana, S Russo, M Morini and F Dondi

Department of Veterinary Medical Sciences, University of Bologna, via Tolara di Sopra n.50, 40064, Ozzano dell'Emilia (BO), Italy

*Corresponding author: simona.valentini@unibo.it

ARTICLE HISTORY (14-576)

Received: November 11, 2014
Revised: October 07, 2015
Accepted: October 09, 2015
Published online: January 11, 2016

Key words:

Adenoma
Adrenal gland
Cat

ABSTRACT

Aim of this paper is to report the first case of a feline cystic adrenocortical tumor. A 9-year-old, castrated male shorthair cat was referred for an abdominal mass accidentally palpated by the owner. Ultrasound showed a large inhomogeneous cystic mass close to the left kidney. A massive ablation of the mass was performed. Four days after surgery, the cat was severely azotemic and presented signs of multiple organ dysfunction. The cat was euthanized the 7th day after surgery. Histopathological examination was consistent for adrenocortical serous cystadenoma.

©2015 PVJ. All rights reserved

To Cite This Article: Spinella G, Brunetti B, Valentini S, Diana A, Russo S, Morini M and Dondi F, 2016. Adrenocortical serous cystadenoma in a cat. *Pak Vet J*, 36(2): 245-247.

INTRODUCTION

Adrenal gland tumors are uncommon in dogs (Massari *et al.*, 2011) and rare in cats (Ash *et al.*, 2005; Lo *et al.*, 2014). Veterinary literature reports single cases of adrenal gland tumors in cats associated to primary hyperaldosteronism, polymyopathy (Ash *et al.*, 2005) and hypertension (Smith *et al.*, 2012). On abdominal ultrasound, these tumors used to lead to hypoechoic adrenal gland enlargement that does not exceed 60 mm major axis length (Ash *et al.*, 2005; Lo *et al.*, 2014). Aim of this report is to describe the clinical and pathological findings of an unique case of giant adrenocortical serous cystadenoma in a cat.

History: A 9-year-old, castrated male domestic shorthair cat weighing 6.10 kg (13.45 lb) was referred for a suspected polycystic kidney. Four months previously, an abdominal mass was accidentally palpated by the owner. A chronic kidney disease was previously diagnosed and treated with a renal diet. The owner reported recent onset of vomiting, polyuria, and polydipsia.

Clinical examination: At physical examination, the body condition score was 4/5, and both kidneys and the abdominal mass with a regular surface were palpable. The cat was normotensive. Hematology and biochemistry profile revealed a mild decrease of hematocrit value (20%; Reference interval [RI]: 24-45), mild hypokalemia (3.3 mEq/L; RI: 3.6-5.8), and increased creatinine (3.12 mg/dL, RI: 0.80-1.80) and urea concentrations (113 mg/dL, RI: 15-60). Based on physical and clinicopathological exam, the cat was staged as CKD stage III/IV, non-proteinuric, minimal risk of hypertension.

On abdominal ultrasound examination, a large inhomogeneous cystic cavitating mass was found in the mesogastric region medially to the left kidney. Color Doppler examination displayed a mild vascularization of the peripheral parenchyma and internal septa of the mass. The kidneys were diffusely hyperechoic, and renal corticomedullary distinction was significantly reduced. Furthermore, irregular hyperechoic foci associated with acoustic shadowing in both kidneys were noted in the pelvis. The left adrenal gland was not detectable on ultrasound; the right gland was normal. Contrast-enhanced ultrasonography (CEUS) of the mass, obtained after the injection of 0.5 mL contrast medium (Sonovue, Bracco diagnostic, Milano, Italy) administered manually through an indwelling cephalic venous 22 G catheter as a bolus, showed a rapid and homogeneous enhancement of the peripheral parenchyma and septa. The central part of cystic mass was not enhanced during the whole examination (Fig. 1). No evidence of metastasis was found on thoracic radiographs. Abdominal exploratory surgery and intraoperative cytology were recommended.

On exploratory surgery, a well-delimited large mass was observed close to left kidney. The mass was partially adherent to left renal hilus and vena cava, but it didn't invade its wall. Fine needle aspiration was performed. Specimens collected were composed of a population of large (up to 25 μ m), round to angular cells with round nuclei and abundant lightly bluish cytoplasm containing well-delineated vacuoles. Moderate anisocytosis and anisokaryosis were noted. Cytological diagnosis was adrenal neoplasia, consistent with adrenal adenoma or low-grade carcinoma. Based on cytological findings, a

mass ablation was performed. However, immediately after its removal, a left renal ischemia occurred, and left nephrectomy was performed, because no signals were displayed at the intraoperative Color-Doppler ultrasound.

The abdomen was flushed with sterile saline solution and routinely closed. The whole procedure (time between the patient intubation and extubation) took 3 hours.

Postmortem findings: Postoperative care included Ringer's lactate solution (2–4 mL/kg/h, IV), ampicillin/sulbactam 20 mg/kg, IV, q 12 h (Unasyn, Pfizer, NY), marbofloxacin 2 mg/kg, IV, q 24 h (Marbocyl fd, Vetoquinol S.A., France), omeprazole 0.7 mg/kg, PO, q 24 h (Antra, AstraZeneca, Milan, Italy), and buprenorphine hydrochloride 10 µg/kg, IM, q 8 h (Temgesic, RB Pharmaceutical Limited, UK). During the immediate postoperative period, the cat had a significant increasing of serum creatinine (5.98 mg/dL; RI: 0.80–1.80), he appeared mildly hypotensive, and had a poor IV fluid response. Forty-eight hours after surgery, mild abdominal fluid and gastrointestinal hypomotility were observed. Moreover, because of persistent hypotension, colloid infusion 2 mL/kg/h (Amidolite, B. Braun, Melsungen,

Germany) was administered, and a urinary catheter was positioned to monitor urine output. Four days after surgery, the cat was severely azotemic (serum creatinine 11.96 mg/dL; RI: 0.80–1.80), and presented signs of multiple organ dysfunction. Seven days after surgery, euthanasia was performed for ethical reasons.

The mass was submitted for histological examination. Macroscopically, it was 12 x 9.5 x 7.5 cm, with multifocal superficial areas of hemorrhage and necrosis. On cut section, the neoplasm was characterized by a large central cyst and multiple smaller cystic areas with gelatinous content. Histopathological examination identified an encapsulated, moderately cellular, and expansive neoplasm completely replacing the adrenal tissue. The neoplasia was characterized by polygonal cells arranged in nests and cords supported by a fine fibrovascular stroma. Multifocally, there were variably sized cystic structures (from 50 µm to 6 mm in diameter) containing abundant eosinophilic, homogeneous material (Fig. 2). The cells had distinct borders and moderate amounts of eosinophilic granules and occasionally contained multiple sharply demarcated and optically empty vacuoles. Nuclei were round and uniform and contained single, small, dot-

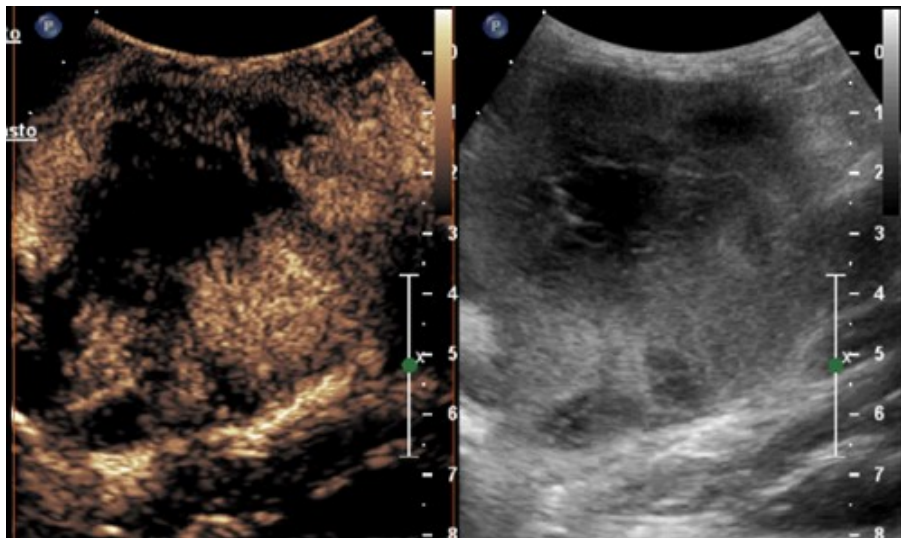


Fig. 1: 9-year-old, castrated male shorthair cat. Contrast enhancement image and gray scale image at peak enhancement. The mass showed a rapid and homogeneous enhancement of the peripheral parenchyma and septa.

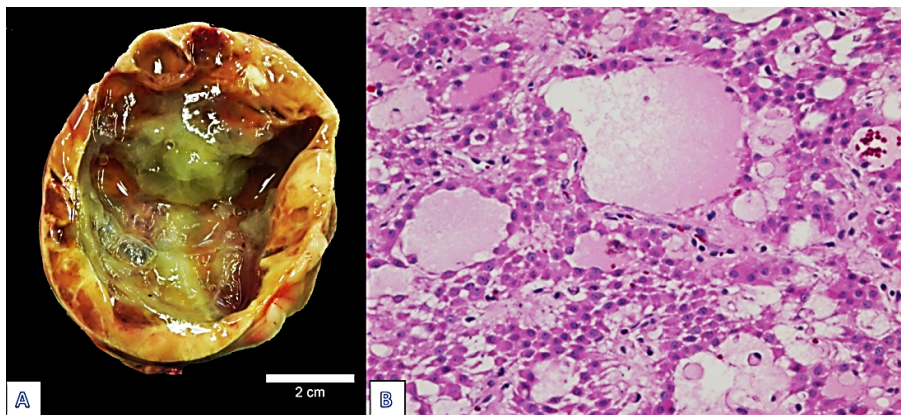


Fig. 2: Part A - Macroscopic cut section of the adrenal gland tumor. The neoplasm is characterized by a large central cyst and multiple smaller cystic areas with gelatinous content. Bar: 2 cm. Part B - The neoplastic cells are arranged in nests and cords in cystic formation. The content of the cystic structure is weakly eosinophilic. Hematoxylin and eosin, 200X.

like nucleoli. Anisokaryosis and anisocytosis were mild. Mitosis was rare. Alcian (pH 2.5)/Period Acid-Schiff (PAS) and Mucicarmine staining were performed for identification of the eosinophilic content of the cystic structure. Staining was negative, confirming serous content and excluding the presence of mucin. Together, these findings were consistent with adrenocortical serous cystadenoma.

DISCUSSION

Adrenal gland adenomas have been reported in cats, including a description of 13 cases (7 adenomas and 6 carcinomas) (Ash *et al.*, 2005) and a recent retrospective study of 10 cases with aldosterone-secreting adrenocortical tumors (Lo *et al.*, 2014). Based on these reports, adrenal gland adenomas could be associated with primary hyperaldosteronism, which is generally diagnosed on the basis of clinical signs, serum chemistry, and adrenal imaging (Lo *et al.*, 2014). The main findings reported for primary hyperaldosteronism in cats are moderate to severe hypokalemia and hypokalemia-related myopathy and hypertension (Lo *et al.*, 2014). In our case report, the unique parameter potentially related to hyperaldosteronism was a mild hypokalemia. However, CKD itself is the most commonly diagnosed cause of spontaneous hypokalemia in cats (Dow *et al.*, 1989), and accordingly with this cat's history and clinical signs, CKD could have contributed to the mild hypokalemia. The authors' opinion of a non-aldosterone-secreting adrenal tumor is also supported by the ultrasound visualization of a normal contralateral adrenal gland and by the absence of other signs, such as polymyopathy, systolic heart murmur, hypertension, and ophthalmologic abnormalities generally associated with primary hyperaldosteronism (Lo *et al.*, 2014). Hormone quantification as aldosterone or aldosterone to renin ratio could likely have better clarified this diagnosis; however, these variables were not assessed in our case.

A relevant aspect of this case report is the large size of the tumor. Literature reports adrenal gland enlargement ranging between 1-6 cm (Ash *et al.*, 2005; Lo *et al.*, 2014). Moreover, the cystic aspect of the adrenocortical adenoma in our case is unusual in a benign lesion, since it has been described only in a benign adrenal adenoma in a newborn (Rathore *et al.*, 2012) and in myxoid adrenocortical carcinomas in humans (Weissferdt *et al.*, 2013) and ferrets (Kiupel *et al.*, 2008). Those carcinomas are characterized as having high metastatic potential grade; however, to the best of the authors' knowledge, this is the first report of a cystic adrenocortical tumor in a cat.

On ultrasound examination, the peripheral parenchyma and the internal septa showed few signals at Color Doppler examination whereas a rapid and homogeneous enhancement of the above structures was evident since CEUS suggesting the complex nature of the cavitating mass. In human medicine, CEUS features of a benign giant adrenal cystic lesion characterized by the enhancement of only tiny vessels disposed peripherally have been recently described (Cantisani *et al.*, 2013).

The differential diagnosis between benign and malignant adrenocortical tumors is not always straightforward at histopathology. Nevertheless, the expansive growth, the presence of a capsule, the absence of necrosis,

and the very low mitotic rate supported the diagnosis of adenoma in this case. Additionally, the absence of invasion of the vena cava, despite the large size of the mass, further support the benign nature of the lesion.

The poor prognosis of our clinical case could be attributed to the associated nephrectomy performed in an advanced CKD-stage; in dogs, the concurrent adrenalectomy and nephrectomy was associated with a poor prognosis, as well as high urea concentration and hypokalemia (Schwartz *et al.*, 2008). Although more cases are necessary to express a prognostic consideration, it is in authors' opinion that the large size of the tumor also influenced the poor prognosis of this case. In a report of 52 dogs with adrenal gland tumors, tumor size influenced survival time, with survival being significantly shorter when the tumor major axis length was ≥ 5 cm. (Massari *et al.*, 2011). Even though in cats prolonged anesthesia time (>4 hours) has also been reported as the only significant factor affecting median survival time (Lo *et al.*, 2014).

Conclusions: In veterinary literature, no reports of cystic adenoma of the adrenal glands in cat has been reported. Adrenal gland neoplasia are rare in cats, however it could be considered for differential diagnosis in geriatric cats with suggestive ultrasound findings or even when symptoms referable to CKD are detected. Therefore, the diagnostic item should always include a thorough physical examination and specific blood and urine tests as well as a standard ultrasound examination, CEUS and, if possible, pre- and/or intraoperative FNB. Since limited data are available about the prognosis of this type of neoplasia, the surgical approach should be careful, in particular when the size of the tumor is elevated.

REFERENCES

- Ash RA, Harvey AM and Tasker S, 2005. Primary hyperaldosteronism in the cat: a series of 13 cases. *J Feline Med Surg*, 7: 173-182.
- Cantisani V, Petramala L, Ricci P, Porfiri A, Marinelli C *et al.*, 2013. A giant hemorrhagic adrenal pseudocyst: contrast-enhanced examination (CEUS) and computed tomography (CT) features. *Rev Med Pharmacol Sci*, 17: 2546-2550.
- Dow SW, Fettman MJ, Curtis CR and Lecouteur RA, 1989. Hypokalemia in cats: 186 cases (1984-1987). *J Am Vet Med Assoc*, 194: 1604-1608.
- Kiupel M, Capen C, Miller M and Smedley R, 2008. Tumors of the adrenal gland. In: *Histological classification of tumors of the endocrine system of domestic animals* (Kiupel M, C Capen, M Miller and R Smedley, 2nd Ed): published by AFIP in cooperation with the CL Davis DVM foundation, Washington, DC, USA, pp: 43-46.
- Lo AJ, Holt DE, Brown DC, Schlicksup MD, Orsher RJ *et al.*, 2014. Treatment of aldosterone-secreting adrenocortical tumors in cats by unilateral adrenalectomy: 10 cases (2002-2012). *J Vet Intern Med*, 28: 137-143.
- Massari F, Nicoli S, Romanelli G, Buracco O and Zini E, 2011. Adrenalectomy in dogs with adrenal gland tumors: 52 cases (2002-2008). *J Am Vet Med Assoc*, 239: 216-221.
- Rathore A, Solomon DG, Simpson JB, Massaro SA, Chhieng D *et al.*, 2012. A novel report of an adrenal adenoma in a newborn. *J Pediatr Surg*, 47: 1436-1439.
- Schwartz P, Kovak JR, Koprowsky A, Ludwig LL, Monette S *et al.*, 2008. Evaluation of prognostic factors in the surgical treatment of adrenal gland tumors in dogs: 41 cases (1999-2005). *J Am Vet Med Assoc*, 232: 77-84.
- Smith RR, Mathew PD and Berent AC, 2012. Laparoscopic adrenalectomy for management of a functional adrenal tumor in a cat. *J Am Vet Med Assoc*, 241: 268-272.
- Weissferdt A, Phan A, Suster S and Moran CA, 2013. Myxoid adrenocortical carcinoma. A clinicopathological and immunohistochemical study of 7 cases, including 1 case with lipomatous metaplasia. *Am J Clin Pathol*, 139: 780-786.