

## Endoscopy-assisted tracheal reconstruction of post-traumatic obstruction in a cat: a case report

M. PIETRA, L. PISONI, N. LINTA, S. PINNA, N. ROMAGNOLI, A. DIANA

University of Bologna, Ozzano dell'Emilia, Bologna, Italy

**ABSTRACT:** A domestic shorthair cat was referred with a history of dyspnoea and lethargy that had arisen gradually within the last few days. The cat had been hit by an automobile 10 days earlier. A thoracic radiograph suggested stenosis of the intrathoracic trachea, proximal to the tracheal bifurcation. Endoscopic examination confirmed a narrowing of the tracheal lumen due to the presence of a fibrotic ring, with remaining patent lumen of about 2 mm. A surgical treatment with a right lateral thoracotomy approach and resection of the narrowed portion of the trachea (a length of about 1 cm) was performed under endoscopic vision. The procedure was unsuccessful because of the size of the tissue removed and the laxity of the remaining tracheal tissue that caused dehiscence of sutures between the tracheal stump and tracheal bifurcation. After consultation with the cat's owners, an intra-operative euthanasia was performed.

**Keywords:** cat; dyspnoea; endoscopy; radiographic findings; tracheal stenosis

Acute tracheal stenosis in the cat is often a consequence of a direct or indirect trauma to the trachea due to animal bites, tracheal foreign bodies, tracheal rupture during orotracheal intubation, or a blunt traumatic incident involving the neck or thorax (Corcoran 1989; Mitchell et al. 2000; White and Burton 2000; Tivers and Hotston-Moore 2006).

In particular, trauma can induce an avulsion injury of the trachea 1–4 cm cranial to its bifurcation. This condition is most likely due to an increase in tracheal intraluminal pressure resulting from thoracic compression associated with a closed glottis, or due to hyperextension of the neck and thoracic spine with consequent tracheal ring avulsion rostral to the carina (Burton 2003).

Clinically, the patient can show dyspnoea immediately after the trauma or worsening dyspnoea after 7–10 days, in relation to progressive scarring of both ends of the avulsed tracheal tract and the creation of a so-called pseudotrachea (White and Burton 2000).

Tracheal avulsion has been reported rarely in the veterinary literature, and the aim of this case report is to describe the clinical, radiological, and endoscopic findings, as well as attempted surgical treatment, in a cat with tracheal stenosis after a

traumatic tracheal avulsion, emphasising the importance of the endoscopic approach to accurately locate and determine the degree of stenosis.

### Case description

A 5-year-old, spayed female, domestic shorthair cat was referred as an emergency case for lethargy, dyspnoea, and respiratory stridor. The cat had been hit by an automobile 10 days prior to referral, and it had been treated by the referring veterinarian with oxygen, corticosteroids, and antibiotics. After an initial improvement, the cat showed a worsening of symptoms with the appearance, in the preceding few days, of anorexia, dyspnoea, and intermittent cough.

On physical examination, the patient was lethargic and afebrile, and showed expiratory dyspnoea with marked abdominal effort, slightly increased respiratory rate, and respiratory stridor. Auscultation of the thorax evidenced increased bronchial sounds in both lung fields.

Because of its unstable condition, and before undertaking further diagnostic procedures, the cat was kept in an oxygen cage with the administration of 40% oxygen.

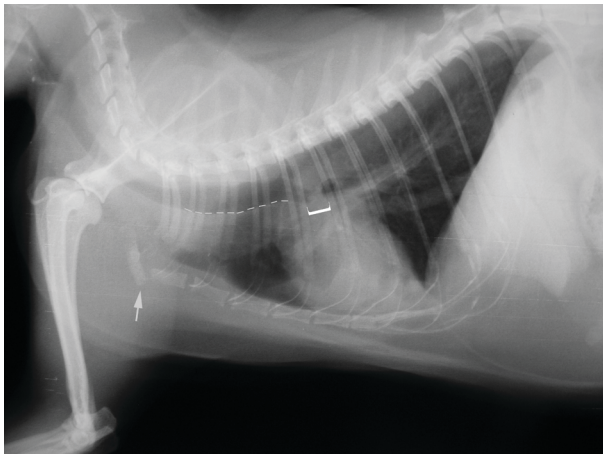


Figure 1. Radiographic lateral view of the thorax. Dotted line indicates the dilated trachea, square bracket the area of tracheal stenosis, and arrow the luxation of the first sternebra

Complete blood count and serum biochemical profile indicated no significant abnormalities; urinalysis and coagulation profile were also within reference limits.

A lateral radiographic view of the thorax showed an area of increased radiopacity proximal to the tracheal bifurcation, for a length of about 7 mm, with moderate dilation of the previous portion of thoracic trachea. Hyperinflated lungs and luxation of the first sternebra were also evident (Figure 1).

In preparation for a tracheal endoscopy, the cat was pre-medicated with butorphanol 0.1 mg/kg *i.m.* (Nargesic<sup>®</sup>, ACME, Italy), followed by induction of general anaesthesia with ketamine 5 mg/kg *i.v.* (Imalgene 1000, Merial, Italy) and midazolam 0.2 mg/kg *i.v.* (Midazolam IBI<sup>®</sup>, I.B.I. Giovanni Lorenzini, Italy), and maintenance with propofol (0.1 mg/kg/min) (Propovet, Merial, Italy) and midazolam (0.1 mg/kg/min) in a constant rate infusion. Haemoglobin saturation, blood pressure by non-invasive procedure, and rectal temperature were monitored every 5 min, and the patient was continuously evaluated with an electrocardiogram.

A tracheal endoscopy was performed using a 1050 mm working length flexible bronchoscope with a 6 mm diameter shaft and a 2 mm instrumental channel (Pentax EG-1840; Pentax, USA). Oxygen (1 l/min) was administered initially through the biopsy channel of the instrument.

A marked and irregular concentric tracheal stenosis of the distal part of the trachea was observed (Figure 2). The tracheal diameter at the level of

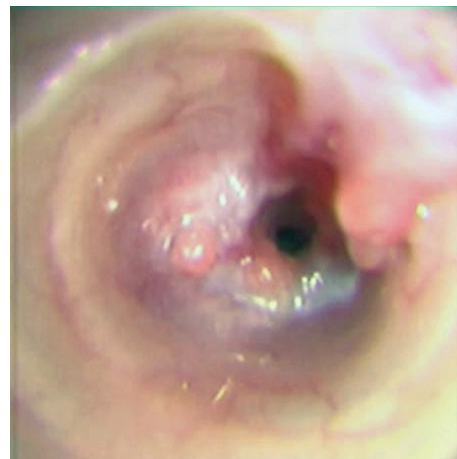

Figure 2. Endoscopic view of the distal trachea (Pentax EG-1840 with 6 mm diameter shaft and 1050 mm working length). Tracheal stenosis with marked luminal narrowing

the stenosis (about 2 mm) was determined by the introduction of a biopsy forceps with a diameter of 1.8 mm (Figure 3).

Keeping the endoscope in front of the stenotic part of the trachea, a catheter was inserted via the endoscopic biopsy channel to carry oxygen beyond the stenotic region to reach the bronchial region.

After the preparation of the surgical field, an intercostal block was performed with bupivacaine 1% (2.2 mg/kg) at the third, fourth, fifth, and sixth right intercostal spaces. A right lateral thoracotomy was performed at the fifth intercostal space. The cranial lung lobe was covered with wet gauze, the right *n. vagus* and right recurrent laryngeal nerve

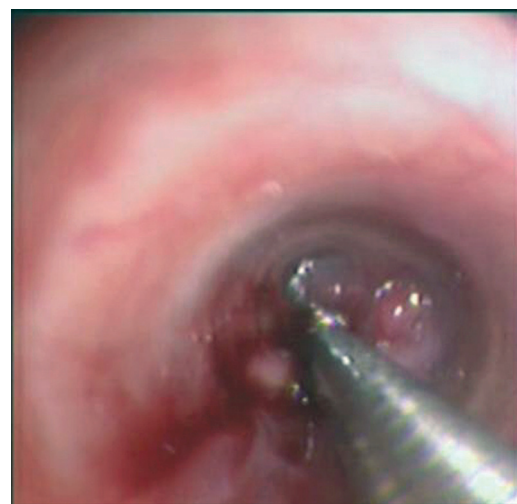


Figure 3. Stenosis calibration through a biopsy forceps with a diameter of 1.8 mm

doi: 10.17221/8250-VETMED

were identified and protected, and the tracheal bifurcation was highlighted.

The trachea, under endoscopic view, was resected 1.5 cm proximal to the tracheal bifurcation and in front of it, and about 1 cm of tissue was excised. Afterwards, the endoscope was retracted and a 3.0 mm diameter, 15 cm long, cuffed silicon endotracheal tube was inserted into the trachea and the right main stem bronchus to support ventilation while tracheobronchial anastomosis was performed. After tracheobronchial intubation, general anaesthesia was maintained with isoflurane (0.5–2% isoflurane vaporizer setting) in oxygen delivered via a Bain circuit with a 1.5 l/min oxygen flow.

Although single interrupted sutures (4-0 polydioxanone) were placed encircling the cartilage rings, proximal and distal to tracheal resection, dehiscence of the suture occurred, making it impossible to connect the tracheal ends. So, with the owner's agreement, intraoperative euthanasia was performed.

Due to the refusal of the owner, a necropsy was not carried out.

## DISCUSSION AND CONCLUSIONS

Post-traumatic tracheal narrowing with consequent obstruction to airflow is uncommonly diagnosed in cats, and only a few cases in the last 25 years have been reported (Corcoran 1989; Berg et al. 1991; White and Milner 1995; White and Burton 2000; Schmierer et al. 2014).

The site of injury is generally located between 1 and 4 cm cranial to the bifurcation and depends, as already reported, on compression of the thorax occurring with a closed glottis or on hyperextension of the neck and thoracic part of the spine with stretching of the trachea (Berg et al. 1991).

As often reported, in the clinical case presented here, dyspnoea developed a few days after the accident; with such cases, the condition of the animal tends to deteriorate rapidly. In particular, in the present case, it is possible to assume that the trauma, at first, created avulsion of the distal part of the trachea, with subsequent formation of a pseudotrachea, composed of tracheal adventitia and mediastinal tissue, in the absence of the development of pneumomediastinum. The repair of tracheal avulsion probably caused a circumferential luminal stenosis due to excessive granulation tissue, which is the cause of the late onset of dyspnoea after trauma.

In a report on thoracic tracheal avulsion in cats, White and Burton (2000) saw dilation at the distal ends of the rupture sites, due to turbulent airflow occurring with changes in airway pressures, either under radiological or endoscopic views. However, in the thoracic radiographs of our case, only a dilation of the entire thoracic portion of the trachea was clearly noted.

Several diagnostic imaging techniques (e.g. radiology and computed tomography) could be used to evaluate, with different degrees of resolution, tracheal narrowing and the condition of the surrounding tissue (Schmierer et al. 2014). Unlike these, endoscopy can provide an added value if used during surgery. In fact, in our experience, endoscopy not only has allowed precise identification of the site and the degree of the stenosis, but it has also permitted maintenance of adequate oxygenation, by the insertion of a catheter beyond the stenosis, during the initial phase of the tracheotomy, before performing ablation of the scar tissue and reconstruction of the trachea, connecting the two edges. We must add, however, that in this case, after tracheal resection and during the tracheal anastomosis, oxygenation was guaranteed by an endotracheal tube.

Due to the chronicity of the disease, and to avoid the risk of possibly breaking the stenotic portion, we chose excision of the scarred tissue rather than using a balloon-tipped valvuloplasty catheter or a self-expanding stent, as indicated by some authors in cases of tracheal stenosis (Berg et al. 1991; Culp et al. 2007; Battersby and Doyle 2010).

A potential cause of surgical failure in this case could be that the removal of 1 cm scar tissue along the stenosis had created excessive tension at the level of the tracheal anastomosis causing dehiscence, or may have been due to the presence of damaged tissue that did not allow an adequate anastomosis.

The negative outcome in this case does not reduce the value of integrating endoscopy and surgery in the resolution of tracheal stenosis, both for the ability to properly determine the degree of stenosis, as well as the ability to provide a supply of oxygen in the early stages of surgery.

## REFERENCES

Battersby I, Doyle R (2010): Use of a biodegradable self-expanding stent in the management of a benign oesoph-

- ageal stricture in a cat. *Journal of Small Animal Practice* 51, 49–52.
- Berg J, Leveille CR, O'Callaghan MW (1991): Treatment of post-traumatic cranial stenosis by balloon dilation during thoracotomy in a cat. *Journal of the American Veterinary Medical Association* 198, 1025–1027.
- Burton C (2003): Surgical diseases of the trachea in the dog and cat. *In Practice* 25, 514–527.
- Corcoran BM (1989): Post traumatic tracheal stenosis in a cat. *Veterinary Record* 124, 342–343.
- Culp WTN, Weisse C, Cole SG, Solomon JA (2007): Intraluminal tracheal stenting for treatment of tracheal narrowing in three cats. *Veterinary Surgery* 36, 107–113.
- Mitchell SL, McCarthy R, Rudloff E, Pernell RT (2000): Tracheal rupture associated with intubation in cats: 20 cases (1996–1998). *Journal of the American Veterinary Medical Association* 216, 1592–1595.
- Schmierer PA, Schwarz A, Bass DA, Knell SC (2014): Novel avulsion pattern of the left principal bronchus with involvement of the carina and caudal thoracic trachea in a cat. *Journal of Feline Medicine and Surgery* 16, 695–698.
- Tivers MS, Hotston-Moore A (2006): Tracheal foreign bodies in the cat and use of fluoroscopy for removal: 12 cases. *Journal of Small Animal Practice* 47, 155–159.
- White RN, Burton CA (2000): Surgical management of intrathoracic tracheal avulsion in cats: long-term results in 9 consecutive cases. *Veterinary Surgery* 29, 430–435.
- White RN, Milner HR (1995): Intrathoracic tracheal avulsion in three cats. *Journal of Small Animal Practice* 36, 343–347.

Received: 2014–05–14

Accepted after corrections: 2015–05–26

---

Corresponding Author:

Marco Pietra, University of Bologna, Department of Veterinary Medical Sciences, Via Tolara di Sopra 50, 40064 Ozzano dell'Emilia (Bo), Italy  
E-mail: marco.pietra@unibo.it

---