



Contents lists available at ScienceDirect

International Journal of Infectious Diseases

journal homepage: www.elsevier.com/locate/ijid

Consensus document on controversial issues in the diagnosis and treatment of prosthetic joint infections

Sebastiano Leone^{a,*}, Silvio Borrè^b, Antonella d'Arminio Monforte^c, Gennaro Mordente^d, Nicola Petrosillo^e, Alberto Signore^f, Mario Venditti^g, Pierluigi Viale^h, Emanuele Nicastrì^{e,k}, Francesco N. Lauria^{e,k}, Giampiero Carosi^{i,k}, Mauro Moroni^{j,k}, Giuseppe Ippolito^{e,k},

and the GISIG (Gruppo Italiano di Studio sulle Infezioni Gravi) Working Group on Prosthetic Joint Infections¹

^a Divisione di Malattie Infettive, Ospedali "Riuniti", Bergamo, Italy

^b Divisione di Malattie Infettive, Ospedale "Sant'Andrea", Vercelli, Italy

^c Divisione di Malattie Infettive e Tropicali, Ospedale "San Paolo", Università di Milano, Milano, Italy

^d S.C.D.O. Ortopedia e Traumatologia, A.S.O. "Maggiore della Carità", Novara, Italy

^e Istituto Nazionale per le Malattie Infettive, I.R.C.C.S. "Lazzaro Spallanzani", Roma, Italy

^f U.O.C. Medicina Nucleare, A.O. "San Andrea", Università "Sapienza", Roma, Italy

^g Dipartimento di Malattie Infettive e Tropicali, Università "Sapienza", Roma, Italy

^h Clinica Malattie Infettive, A.O.U. "Santa Maria della Misericordia", Università di Udine, Udine, Italy

ⁱ Istituto di Malattie Infettive e Tropicali, Università di Brescia, Brescia, Italy

^j Istituto di Malattie Infettive, Ospedale "Luigi Sacco", Università di Milano, Milano, Italy

^k GISIG (Gruppo Italiano di Studio sulle Infezioni Gravi) Coordinating Committee, Italy

ARTICLE INFO

Keywords:

Prosthetic joint infections
Methicillin-resistant staphylococci
Conservative surgical approach
One-stage approach
Two-stage approach

SUMMARY

Background: Joint replacement surgery has been on the increase in recent decades and prosthesis infection remains the most critical complication. Many aspects of the primary prevention and clinical management of such prosthesis infections still need to be clarified.

Controversial issues: The aim of this GISIG (Gruppo Italiano di Studio sulle Infezioni Gravi) working group – a panel of multidisciplinary experts – was to define recommendations for the following controversial issues: (1) Is a conservative surgical approach for the management of prosthetic joint infections effective? (2) Is the one-stage or the two-stage revision for the management of prosthetic joint infections more effective? (3) What is the most effective treatment for the management of prosthetic joint infections due to methicillin-resistant staphylococci? Results are presented and discussed in detail.

Methods: A systematic literature search using the MEDLINE database for the period 1988 to 2008 of randomized controlled trials and/or non-randomized studies was performed. A matrix was created to extract evidence from original studies using the CONSORT method to evaluate randomized clinical trials and the Newcastle–Ottawa Quality Assessment Scale for case–control studies, longitudinal cohorts, and retrospective studies. The GRADE method for grading quality of evidence and strength of recommendation was applied.

© 2010 International Society for Infectious Diseases. Published by Elsevier Ltd. All rights reserved.

* Corresponding author. Tel.: +39 035 266293; fax: +39 035 253382.

E-mail address: sebastianoleone@yahoo.it (S. Leone).

¹ Members of the working group are: A.M. Azzini, Azienda Ospedaliera di Verona – Policlinico Rossi, Verona; M. Camera, Azienda Ospedaliera Universitaria San Martino, Genoa; S. Carbonara, Università Azienda Ospedaliera Policlinico di Bari, Bari; A. Davì, Ospedale Maggiore di Modica, Modica, Ragusa; G. Foti, Azienda Ospedaliera Bianchi-Melacrino-Morelli, Reggio Calabria; V. Galati, INMI L. Spallanzani, Roma; I. Gentile, Azienda Ospedaliera Universitaria Federico II, Napoli; A. Mariano, INMI L. Spallanzani, Roma; S. Piro, Ospedale SS. Trinità, Cagliari; M. Quarta, Azienda Ospedaliera Vito Fazzi, Lecce; G. Raineri, Azienda Ospedaliera Santa Croce e Carle, Cune; G. Riccio, Presidio Ospedaliero di Albenga – Pietra Ligure, Pietra Ligure, Savona; R. Rinaldi, Azienda Ospedaliera di Padova, Padova; S. Rosati, INMI L. Spallanzani, Roma; D. Santopuoli, Azienda Ospedaliera Antonio Cardarelli, Campobasso; C. Tascini, Azienda Ospedaliera Universitaria Pisana, Pisa; S. Veccia, Ospedale Civile Torrette, Ancona.

1. Introduction

Prosthetic joint infections (PJI) result in substantial morbidity, often with pain, immobility, prolonged hospital stay, and further surgery, and thus additional costs.^{1,2} The incidence of PJI varies depending on the joint involved; the rate of arthroplasties becoming infected is as follows: 1.7% of primary and 3.2% of non-primary hip arthroplasties; 2.5% of primary and 5.6% of non-primary knee arthroplasties; and 1.3% of shoulder arthroplasties.³ However, the real overall risk per patient-life is unknown, since in most case series only the first 2 years after implantation are considered.⁴

Several risk factors have been identified for PJI. Berbari et al. conducted a matched case–control study to determine risk factors for PJI. A multiple logistic regression model indicated that risk factors for PJI were the development of a surgical site infection not involving the prosthesis (odds ratio (OR) 35.9, 95% confidence interval (CI) 8.3–154.6), a National Nosocomial Infections Surveillance System (NNIS) surgical patient risk index score of 1 (OR 1.7, 95% CI 1.2–2.3) or 2 (OR 3.9, 95% CI 2.0–7.5), the presence of a malignancy (OR 3.1, 95% CI 1.3–7.2) and a history of joint arthroplasty (OR 2.0, 95% CI 1.4–3.0).⁵ Other risk factors have been identified, such as rheumatoid arthritis, immunocompromised states, diabetes mellitus, poor nutritional status, obesity, psoriasis, long-term urinary catheterization, and extreme age.⁶ Whether or not HIV infection and low CD4+ lymphocyte counts are risk factors for surgical wound infections remains controversial.^{7,8}

An internationally accepted classification for PJI has not yet been established. The infections can be classified in accordance with time of onset after surgery as: early, delayed, or late. Early manifestation is defined as the appearance of the first signs and symptoms of infection during the first 3 months after surgery. However, some authors limit these surgical site infections to the first 2–4 weeks. Delayed manifestation is defined as an infection causing the first signs and symptoms between 3 months and 2 years after surgery. Finally, late manifestation is defined as the appearance of the first signs and symptoms of infection >2 years after surgery.^{2,9}

Staphylococcus aureus and coagulase-negative staphylococci account for approximately 50% of such infections, regardless of the type of implant. Others are anaerobes, Gram-negative bacteria such as *Pseudomonas* species or *Escherichia coli*, *Propionibacterium acnes* and, especially in hematogenous infections, *Streptococcus spp.*⁹ Polymicrobial PJIs account for 4–27% of all PJI infections.¹⁰ Unusual pathogens have also been reported.^{11,12} No microorganisms are detected in about 10% of apparent infections.¹³ Establishing a microbiological diagnosis is imperative because the type of infecting organism often determines the therapeutic approach.² In addition, the rising prevalence of methicillin-resistant staphylococci further complicates matters.¹⁴ Successful treatment of these infections usually requires surgical interventions and prolonged antimicrobial therapy to achieve microbial sterilization and a satisfactory functional result. Possible options for the operative management of a PJI include debridement with retention of the prosthesis, immediate one-stage exchange arthroplasty, and resection arthroplasty, either as a definitive procedure or as the first of a two-stage reconstructive procedure.²

The aim of this work was to define recommendations for some controversial issues on the management of PJI, using an evidence-based approach.

2. Methods

2.1. Controversial issues

As part of a large ‘evidence-based’ study on the management of multidrug-resistant Gram-positive infections, eight national experts were selected on the basis of their personal curricula and were asked to identify three major categories of bone and joint infections and several questions to be addressed for each category. Subsequently, during two workshop meetings held in Milan, Italy, we restricted our work to three main controversial issues listed below:

- Is a conservative surgical approach for the management of prosthetic joint infections effective?
- Is the one-stage or the two-stage revision for the management of prosthetic joint infections more effective?

- What is the most effective treatment for the management of prosthetic joint infections due to methicillin-resistant staphylococci?

2.2. Literature search and study selection

A literature search using the MEDLINE database for the period 1988–2008 was performed. Studies were included if they were written in English, involved human subjects, involved adults, and involved PJI of the knee or hip. We included studies that showed the following data for the three designed controversial issues: systemic antibiotic therapy plus prosthesis retention and debridement compared with systemic antibiotic therapy plus other surgical approach OR one-stage surgical approach compared with two-stage surgical approach OR systemic antibiotic therapy active on methicillin-resistant staphylococci compared with another systemic antibiotic therapy active on methicillin-resistant staphylococci, respectively. We assessed the following outcomes: revision of the surgical site, relapse of infection, mortality, duration of hospitalization, cost-effectiveness, and quality of life.

Three specific search strategies were used. For the first issue, the search terms used were: ((knee replacement arthroplasty OR knee prosthesis OR hip replacement arthroplasty OR hip prosthesis) AND (infection OR infections)) AND (salvage therapy OR prosthesis retention OR debridement OR conservative treatment). For the second issue, the search terms used were: ((knee replacement arthroplasty OR knee prosthesis OR hip replacement arthroplasty OR hip prosthesis) AND (infection OR infections)) AND (‘one stage’ OR ‘single stage’ OR ‘1 stage’) AND (‘two-stage’ OR ‘2 stage’ OR reoperation). Finally, for the third issue, the search terms used were: ((prosthetic joint OR joint prosthesis OR periprosthetic) AND (infection OR infections)) AND ((methicillin resistant AND (Staphylococcus OR staphylococci)) OR (methicillin resistant coagulase negative AND (Staphylococcus OR staphylococci))) AND anti-bacterial agents. Titles and abstracts of potentially relevant studies were checked: when studies met eligibility criteria (or when information was insufficient to exclude them), full text articles were obtained. Finally, if the search showed a lack of clinical comparative trial, non-comparative studies (observational, retrospective, case report, and case series) were included. These were sought using the same database and terms. Additional references were identified from citations in published papers included in the revision. These additional studies were included if published in the last 10 years (1998–2008).

2.3. Classification and evaluation of selected evidence

We assessed methodological quality of randomized controlled trials and non-randomized studies using the CONSORT method and Newcastle–Ottawa Quality Assessment Scale, respectively. Details of quality assessment and summaries of all included studies are available from author SL. The original data from case studies were considered homogeneous after using a predefined format both for single case reports and series of reported cases. In the discussion section, to assign the strength to the level of recommendation, a methodology adapted from the GRADE Working Group was applied. Details of the methodology are reported in this supplement.¹⁵

3. Results

3.1. Is a conservative surgical approach for the management of prosthetic joint infections effective?

Ten comparative non-randomized studies were included in the analysis. Additional data were found in 21 non-comparative

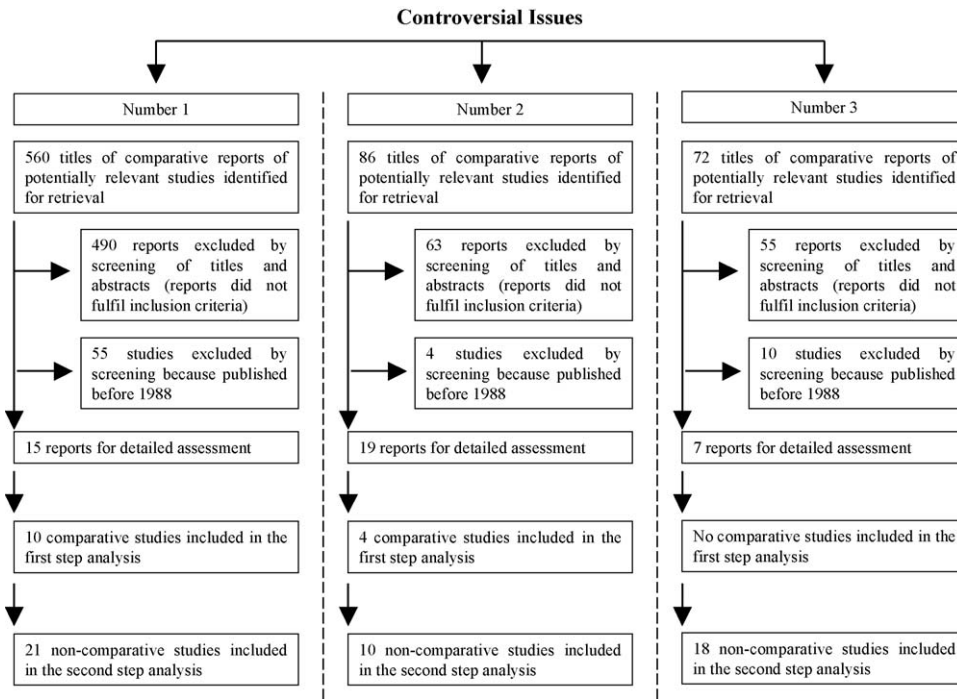
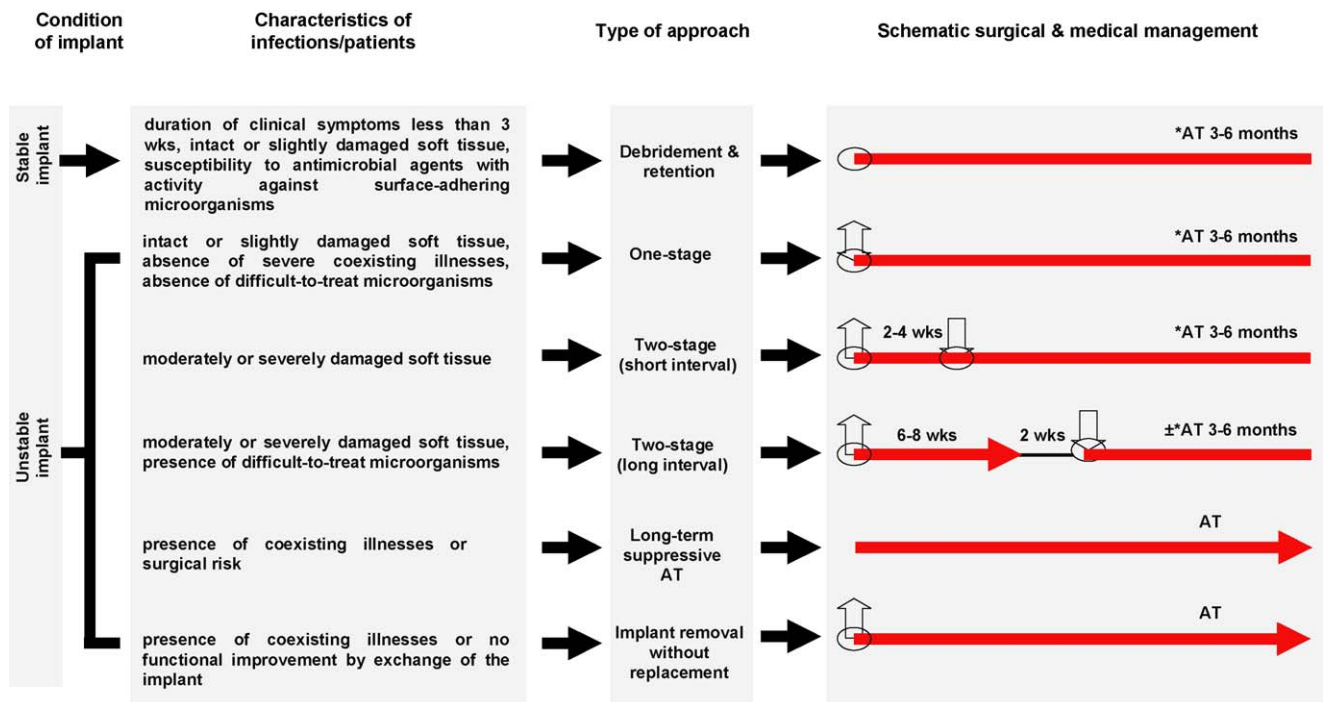


Figure 1. Studies included.

published studies (Figure 1). Out of these, four studies evaluated the clinical validity of the algorithm published by Zimmerli et al. based on the interval after implantation (early, delayed, late manifestations are defined as the appearance of the first signs and symptoms of infection during the first 3 months, between 3

months and 2 years, and at >2 years after surgery, respectively), the type of infection (exogenous vs. hematogenous), the condition of the implant, the soft tissue, and the patient co-morbidities (Figure 2).^{2,4,16–19} According to these recommendations, debridement with retention of the prosthesis is a reasonable option for



Legend:

AT: antibiotic therapy; *Duration of 3 months for hip prostheses and 6 months for knee prostheses (red line); ○ Timing of surgery; ⬆ Explanation of implant; ⬆ Reimplantation of implant

Figure 2. Algorithm for the surgical and antibiotic management of prosthetic joint infection (adapted from^{2,4}).

patients with an early postoperative or acute hematogenous infection, if the duration of clinical signs and symptoms is less than 3 weeks, the implant is stable, the soft tissue is in good condition, and an agent with activity against biofilm-producing microorganisms is available (e.g., rifampin).⁴ Overall, a conservative approach was effective in 36 (69.2%) of 52 patients.

In the analysis of Betsch et al. on prosthetic hip- and knee-associated infection, independent risk factors for treatment failure were a high infection score (hazard ratio (HR) 1.24, 95% CI 1.10–1.40; $p < 0.001$), choice of a surgical treatment strategy in disagreement with published recommendations (HR 1.96, 95% CI 0.97–3.95; $p = 0.05$), and an inadequate antimicrobial regimen (HR 2.79, 95% CI 1.21–6.45, $p = 0.01$).¹⁶ In infection associated with hip arthroplasty, Giulieri et al. showed that retention with debridement had a success rate of 64% (7/11 patients) overall, and of 71% if the indication was chosen according to the algorithm proposed by Zimmerli.¹⁷ In infection associated with knee arthroplasty, Laffer et al. observed that retention had an overall success rate of 95.2% (20/21 patients), with a rate of 100% if the retention was treated surgically with synovectomy (10 episodes) or 90.9% with arthroscopic lavage.¹⁸ Finally, Kösters et al. found a low efficacy of conservative approach in the management of prosthetic knee-associated infection (37.5%; 3/8 patients), but only four patients were treated with the above-mentioned recommendations (success rate of 75% – 3/4 patients) overall.¹⁹

Additional studies showed that retention of implants was higher in early and acute hematogenous infections as opposed to late infections.^{20–29} However, in some studies, the duration of symptoms prior to administration of antibiotics and the timing of infection did not appear to predict success or failure. Segreti et al. reviewed 18 patients with PJs who had been treated with a conservative approach and prolonged antimicrobial suppression. Of these, nine patients (50%) had an early onset infection and eight (44%) experienced an acute inflammatory syndrome. Fifteen of the 18 patients (83.3%) appear to have had a favorable clinical outcome and to have retained a functional prosthesis.³⁰ In a prospective study on long-term suppression of PJs, Rao et al. confirmed a favorable outcome in 86.2% (31/36) of patients after a mean follow-up of 5 years.³¹

Barbari et al. designed a retrospective study to estimate the probability of treatment failure for patients with PJI and rheumatoid arthritis treated with various surgical modalities. The number of episodes treated with debridement and retention was 46. Sinus tract and duration of symptoms < 30 days were observed in 46% and 76%, respectively. The rate of survival free of treatment failure at 5 years for the episodes treated with a conservative approach was 32% (95% CI 21–49%). Compared with joints treated with two-stage exchange, joints treated with debridement and retention had a 5.9-fold increased risk of treatment failure (95% CI 2.6–13.4-fold; $p < 0.001$).³² In another retrospective study on 60 culture-negative PJs, the same authors showed that the 5-year estimate of survival free of treatment failure was 71% (95% CI 44–100%) for patients treated with debridement and retention. Although the difference was not statistically significant, patients who underwent debridement and retention had an increased risk of treatment failure by a factor of 5, compared with those who underwent two-stage exchange (HR 4.80, 95% CI 0.88–27.3; $p = 0.07$).¹³ Marculescu et al. evaluated the outcome of PJs treated with debridement and retention of components. Variables associated with an increased risk of treatment failure in multivariable analysis included the presence of a sinus tract (HR 2.84, 95% CI 1.48–5.44; $p = 0.002$) and a duration of symptoms prior to debridement of ≥ 8 days (HR 1.77, 95% CI 1.02–3.07; $p = 0.04$).³³

Six studies have investigated the role of a rifampin-based regimen on the management of PJs.^{34–39} Four papers reported the

outcome of debridement and prosthesis retention with rifampin and fluoroquinolone (ciprofloxacin or levofloxacin) combination. The rate of success was 65–100%. Overall, the efficacy was higher in patients with a stable implant, shorter duration of symptoms, earlier diagnosis, hip infections, and methicillin susceptibility.^{34–39} Only, one study evaluated the combination of rifampin and fusidic acid. The cumulative risk of treatment failure after 1 year was 11.76% (95% CI 3.08–39.40%).³⁹

Recently, Soriano et al. investigated the role of linezolid for orthopedic implant infections ($n = 85$) caused by methicillin-resistant *S. aureus* (MRSA) and other multidrug-resistant Gram-positive bacteria. For acute ($n = 24$) and chronic ($n = 61$) infections, the respective success rates were 100% and 92.3% when the implant was removed and 72.2% and 42.8% when it was not. The cure rates of the conservative approach and linezolid/rifampin combination in acute and chronic cases were 87.5% and 46.6%, respectively.⁴⁰ A few authors have reported that patients infected by *S. aureus* have a more unfavorable clinical outcome than patients infected with other bacteria.³⁰ In 31 acute Gram-positive infections after total knee arthroplasty treated with debridement and component retention, only one (8%) of the 13 patients infected with *S. aureus* was successfully treated, compared with 10 (56%) of 18 patients with either *Staphylococcus epidermidis* or a streptococcal species ($p < 0.007$).⁴¹ A good outcome in patients with infections caused by streptococci was found in two series.^{42,43} Finally, two studies reported that arthroscopic surgical treatment of PJs is an appealing method, but that it should be used only in selected circumstances, such as in medically unstable or anticoagulated patients.^{44,45}

3.2. Is the one-stage or the two-stage revision for the management of prosthetic joint infections more effective?

Four comparative non-randomized studies were included in the analysis. Additional data were found in 10 non-comparative series (Figure 1). As for the first controversial issue, three studies evaluated the clinical validity of the algorithm published by Zimmerli et al. (Figure 2).^{2,4,16–18} According to these recommendations, if the duration of signs or symptoms of infection exceeds 3 weeks, retention of the implant should not be attempted. One-stage revision is suitable for patients with non-compromising soft tissue situations, in the absence of severe coexisting illnesses, and in the absence of difficult-to-treat microorganisms (MRSA and other multidrug-resistant bacteria). A two-stage revision is chosen in patients with the above-mentioned microorganisms, as well as in those with sinus tracts, swelling, or extended abscess formation in depth.⁴

Success rates after one-stage exchange and after two-stage exchange were 0% (0/4 episodes) and 65% (33/51 episodes) in the study by Betsch et al., 94% (15/16 episodes) and 90% (28/31 episodes) in the study by Giulieri et al., and 100% (2/2 episodes) and 85% (11/13 episodes) in the study by Laffer et al.^{16–18} Overall, the choice of a surgical strategy in agreement with the algorithm increased healing rates from 40% to 60% in the study by Betsch et al., from 62% to 88% in the study by Giulieri et al., and from 86% to 92% in the study by Laffer et al.

In a small retrospective study by Pagnano et al. on the clinical outcome after reinfection following hip arthroplasty reimplantation, only patients treated with two-stage exchange had a favorable outcome.⁴⁶ An additional four reports provided outcome data on 103 direct exchange arthroplasties. Coagulase-negative staphylococci were the most common isolates ($n = 48$). Polymicrobial PJs were observed in nine cases. Antibiotic-impregnated bone cement was used in 66 of these procedures (64%). Winkler et al. performed a one-stage uncemented revision using cancellous allograft bone impregnated with antibiotics in 37 patients. PJI was

controlled in 95 of 103 episodes (92.2%) with a follow-up ranging from 1.4 to 19.6 years.^{47–50}

Six papers reported data on 246 episodes treated with two-stage exchange. Success was achieved in 222 cases (90.2%) with a follow-up ranging from 0.4 to 8.7 years.^{25,51–55} Of note, Hirakawa et al. showed that reimplantation was successful in 80.0% of knees with low-virulence organisms (coagulase-negative *Staphylococcus*, *Streptococcus*), 71.4% with polymicrobial organisms, and 66.7% with high-virulence organisms (MRSA). Reimplantation was successful in 82% of patients with osteoarthritis and in 54% of patients with rheumatoid arthritis ($p = 0.024$).⁵¹

Finally, Mont et al. performed a comparative study to determine whether aspiration of the affected joint and culture of the specimen, performed before reimplantation and after discontinuation of antibiotic therapy, would help to identify patients who might have a recurrent infection. Group I consisted of 35 patients treated with removal of the prosthetic components and irrigation and debridement of the joint, followed by 6 weeks of antibiotic therapy and reimplantation of the prosthesis. Group II was composed of 34 patients treated with removal of the components and irrigation and debridement of the joint, 6 weeks of antibiotic therapy, and culture of further biological samples 4 weeks after the end of the antibiotic course. In the case of a culture-negative sample, the patient was managed with a second-stage reimplantation of a prosthesis. In the case of a culture-positive sample, the protocol was applied again, with irrigation and debridement. Of the 35 patients in group I, five (14%) had recurrence of infection. Of the 34 patients in group II, three (9%) had a positive culture after the antibiotic course. The protocol was repeated for all three patients with a successful second revision. One other patient (3%) in group II with a negative culture, had a recurrent infection and was finally managed with arthrodesis of the knee.⁵⁴

3.3. What is the most effective treatment for the management of prosthetic joint infections due to methicillin-resistant staphylococci?

No comparative studies were found, and required data were collected from 18 non-comparative series only (Figure 1).

Pavoni et al. used a conservative approach to treat 34 patients with PJI. Identified pathogens were methicillin-susceptible *S. aureus* (MSSA; four infections), MRSA (eight infections), methicillin-susceptible *S. epidermidis* (four infections), methicillin-resistant *S. epidermidis* (five infections), *Enterococcus faecalis* (two infections), methicillin-resistant *S. epidermidis* plus *E. faecalis* (one mixed infection), and MRSA plus *Pseudomonas aeruginosa* (one mixed infection). Most infections were initially treated with intravenous or intramuscular teicoplanin ± ciprofloxacin or rifampin. In patients with MRSA and methicillin-resistant *S. epidermidis* infections, oral minocycline 200 mg/day, either alone or in combination with rifampin 600 mg/day, was the usual subsequent therapy. In infections involving methicillin-resistant staphylococci, a favorable outcome was reported in 14 of 15 patients (93.3%). Among these, no relapse was observed in seven patients (46.7%) during the follow-up; improvement with early (6 months from antibiotic discontinuation) or late relapse was observed in three (20%) and three (20%) patients, respectively; one patient improved clinically, but he continued the antibiotic therapy.²⁴

Only one study examined the effectiveness of co-trimoxazole for the treatment of orthopedic implants infected with multidrug-resistant *Staphylococcus spp.* All patients were treated orally with high-dose co-trimoxazole (trimethoprim, 20 mg/kg of body weight/day; sulfamethoxazole, 100 mg/kg/day). Patients with prosthetic hip infections were treated for 6 months, with removal of any unstable prosthesis after 5 months of treatment; patients with prosthetic knee infections were treated for 9 months, with removal of any unstable prosthesis after 6 months of treatment; and patients with infected osteosynthetic devices were treated for

6 months, with removal of the device after 3 months of treatment, if indicated. Treatment success rates were 66.7% (26/39 patients) after a follow-up of 24–75 months (average 38 months): the success rates were 62.5% (5/8 patients) for patients with prosthetic knee infections, 50% (6/12 patients) for patients with prosthetic hip infections, and 78.9% (15/19 patients) for patients with other device infections. Seventeen of the 28 (60.7%) patients with a conservative approach were cured. The remaining 11 patients (36.6%) were treated with the removal of the prosthesis and nine (81.8%) of them were completely cured; eight patients suspended the treatment for adverse events and one patient was lost to follow-up.⁵⁶

In another study, the fusidic acid/rifampin oral combination was effective in 10 of 11 (90.9%) patients with infections involving MRSA. In one patient the persistence of the PJI required the removal of the prosthesis 6 months after the initial debridement.³⁹ A similar favorable outcome was observed in the study of Drancourt et al., which compared fusidic acid/rifampin with ofloxacin/rifampin combination. Overall, treatment was successful for 11 of 20 patients (55%) treated with rifampin and fusidic acid and for 11 of the 22 patients (50%) treated with rifampin and ofloxacin.⁵⁷

Seven studies investigated the role of linezolid in the treatment of PJIs.^{40,58–63} A retrospective study of therapy with linezolid for patients with PJIs reported that treatment was successful in the 80% of cases (16/20 patients). Pathogens isolated were: MRSA, 14 strains; methicillin-resistant coagulase-negative staphylococci, five strains; and *Enterococcus spp.*, one strain. Eleven patients (55%) had an early onset infection, with an acute onset reported in nine cases (45%). The mean duration of linezolid administration was 7.2 weeks. Several antibiotics were administered before linezolid, including vancomycin and the combination rifampin/ciprofloxacin.⁶²

Rao et al. prospectively monitored 51 consecutive adults on linezolid therapy for 53 Gram-positive orthopedic infections, chronic osteomyelitis ($n = 25$) and PJIs ($n = 23$). Identified pathogens were *S. aureus* ($n = 27$) and coagulase-negative staphylococci ($n = 19$); 38 of them were methicillin-resistant. After clinical remission, 17 patients with PJI required long-term suppression. The most common adverse events were thrombocytopenia ($n = 5$) and anemia ($n = 5$); treatment discontinuation was indicated in three patients.⁵³

In six original articles the use of daptomycin for PJIs was reported on a cumulative number of 22 cases.^{64–69} In four cases a favorable clinical outcome was reported using a 6-mg/kg/day dosage in association with rifampin or other antibiotics.^{64,66,67,69}

Rao et al. reported clinical failure in five patients with a conservative approach treated with 4 mg/kg/day.⁶⁵

Finally, one study analyzed the role of quinupristin–dalfopristin in the treatment of MRSA infections including bone and joint infections. Cure or improvement was observed in 31 of 40 (77.5%) cases.⁷⁰

3.4. From the evidence to the recommendations

Infections associated with prosthetic joint implantations occur only in a small proportion of joint recipients, but they represent a severe event. The use of perioperative antimicrobial prophylaxis and a laminar airflow surgical environment has reduced the risk of intraoperative infection to less than 1% after hip and shoulder replacement and to less than 2% after knee replacement.² Since several controversial issues still remain in the management of patients with PJI, a panel of Italian multidisciplinary experts have analyzed all published studies in the last 20 years in order to provide an answer to three basic questions and to propose a standard algorithm for diagnosis and cure.

3.5. Is a conservative surgical approach for the management of prosthetic joint infections effective?

Here the duration of symptoms has been considered to be a reliable predicting factor of treatment outcome. In the analysis by Marculescu et al., duration of symptoms ≥ 8 days was a risk factor for treatment failure³³ (GRADE score 3). Tattevin et al. showed that of the 34 patients initially treated with debridement alone, only 13 (38.2%) required no further surgery. These 13 patients, had significantly shorter intervals between onset of symptoms and surgical treatment than the 21 patients treated with a second intervention (4.8 vs. 54.2 days; $p < 0.0001$)²⁶ (GRADE score 3).

In 19 cases of streptococcal PJI with a duration of symptoms before debridement of 4 days (range 1–10 days), Meehan et al. showed that treatment failure occurred in two cases (10.5%) during a median follow-up period of 3.9 years (range 0.3–21.7 years)⁴³ (GRADE score 3). In a prospective study, Chiu and Chen followed 40 PJIs treated with surgical debridement and parenteral antibiotics with retention of their existing prostheses. Using the classification of Tsukayama et al., 10, 20, and 10 patients had types I (acute postoperative), II (late chronic), and III (acute hematogenous) infections, respectively. Successful implant salvage was achieved in 12 of the 40 patients (30%). However, a favorable outcome depended on the type of infection: patients with type I infection (7/10) and patients with type III infection (5/10) retained their prostheses more often than patients with type II infection (0/20)²⁰ (GRADE score 3). Favorable results were observed by authors who treated patients with clinical signs and symptoms of less than 3 weeks^{16–19} (GRADE score 3 for each paper).

A loose prosthesis has been assumed to be a contraindication to debridement and retention of the prosthesis, and several studies have excluded such patients^{16–19,27,33,43} (GRADE score 3 for each paper). The presence of a sinus tract or an abscess is an additional predictor of treatment failure^{16–19,33} (GRADE score 3 for each paper). Finally, the antimicrobial agent should have bactericidal activity against surface-adhering, slow-growing and biofilm-producing microorganisms² (GRADE score 2).

Rifampin has excellent efficacy to eliminate stationary phase staphylococci in vitro and in clinical trials⁷¹ (GRADE score 3). There is only one randomized placebo-controlled study for the treatment of patients with orthopedic device-related infection³⁴ (GRADE score ≥ 4). The patients were treated with debridement without removal combined with either ciprofloxacin plus placebo or ciprofloxacin plus rifampin. There was a complete cure rate of staphylococcal orthopedic implant-related infections in all patients who tolerated long-term therapy with ciprofloxacin plus rifampin.³⁴ Additional studies have shown the clinical efficacy of the rifampin/fluoroquinolone combination^{35–38} (GRADE score 3 for each paper). However, fluoroquinolone resistance is now at high levels in nosocomial strains of staphylococci, thereby limiting the usefulness of rifampin and fluoroquinolone combinations in this setting⁷² (GRADE score 2). These organisms usually remain susceptible to fusidic acid, but this drug is not available in Italy³⁹ (GRADE score 3). In this scenario, the newer drugs appear to be attractive for this indication.

In the setting of catheter-related bloodstream infections, Raad et al. investigated the efficacies of the newer antibiotics daptomycin, linezolid, and tigecycline, in comparison with vancomycin, minocycline, and rifampin, against MRSA embedded in biofilm. Minocycline, daptomycin, and tigecycline were more efficacious in inhibiting MRSA in biofilm than linezolid, vancomycin, and the negative control ($p < 0.001$) after the first day of exposure to these antibiotics. Minocycline was the most active, followed by daptomycin and then tigecycline, whereas vancomycin and linezolid lacked bactericidal activity, similar to the negative control. After 3 days of 4-h daily exposures, daptomycin was the fastest in eradicating MRSA from biofilm, followed by minocycline and

tigecycline, which were faster than linezolid, rifampin, and vancomycin ($p < 0.001$). When rifampin was used alone, it was less effective in eradicating MRSA from biofilm, due to the emergence of rifampin-resistant MRSA. However, when rifampin was used in combination with other antibiotics, the combination was effective in eliminating MRSA colonization from biofilm more rapidly than any single antibiotics alone⁷³ (GRADE score 1).

In another model, Baldoni et al. showed that linezolid used in combination with rifampin was more effective than linezolid used as monotherapy, reducing the planktonic bacteria ($p < 0.05$)⁷⁴ (GRADE score 1). However, a negative drug interaction between linezolid and rifampin that resulted in decreased serum linezolid levels was identified in an in vivo study⁷⁵ (GRADE score 1).

Finally, John et al. compared the activity of daptomycin (alone and with rifampin) with other antimicrobial regimens against MRSA in the guinea pig foreign-body infection model and concluded that daptomycin plus rifampin is a promising treatment option for implant-associated MRSA infections⁷⁶ (GRADE score 1).

In conclusion, we have shown that debridement and retention of prosthesis has a higher likelihood of treatment success in the following situations: PJIs involving a stable implant; infection by a pathogen with susceptibility to antimicrobial agents active against surface-adhering microorganisms (e.g., rifampin); the absence of a sinus tract or an abscess; if the duration of symptoms of infection is less than 3 weeks.

Recommendations

We suggest the use of the conservative approach whenever possible, with the proper selection of eligible patients. This approach should be used only if the following specific conditions are met: a stable implant; a pathogen with susceptibility to antimicrobial agents active against surface-adhering microorganisms (e.g., rifampin); absence of a sinus tract or an abscess; and a duration of symptoms of infection of less than 3 weeks (B).

We suggest that after a 2-week course of intravenous antibiotic therapy, that this should be replaced with an oral rifampin-based regimen (A). Moreover, we suggest the use of oral antibiotics with high bioavailability when possible (D). Patients with hip prostheses should be treated for 3 months and those with knee prostheses for 6 months (A). After the treatment period, a new white blood cell (WBC) scintigraphy should be performed together with laboratory tests, to verify the absence of infection (D).

We suggest that after 3–6 months of antimicrobial treatment, the oral therapy should be stopped if the patient has no signs and symptoms and if C-reactive protein (CRP) is negative for at least 6 weeks, and/or a WBC scintigraphy is also negative (D).

We recommend the use of rifampin-based regimens as the cornerstone of therapy for the PJIs, except in the circumstances in which antimicrobial resistance prevents its use (A).

We recommend that the first option rifampin-based regimen for susceptible organisms is the combination with a fluoroquinolone (A).

In the case of multidrug-resistant bacteria, we suggest that the use of other agents active against surface-adhering, slow-growing, and biofilm-producing microorganisms, such as glycopeptides, minocycline, co-trimoxazole, and in selected case linezolid and daptomycin, can be considered (D).

3.6. Is the one-stage or the two-stage revision for the management of prosthetic joint infections more effective?

The literature analysis failed to report a better clinical outcome of one surgical treatment compared to the other for

the management of PJI. Silva et al. performed a literature review to identify clinical reports on the use of direct exchange arthroplasty or surgical debridement with prosthesis retention to treat infected knee arthroplasties. This search revealed 35 studies, including 37 knees that underwent direct exchange arthroplasty. Infection was controlled in 33 of 37 infected total knee arthroplasties that were treated by direct exchange arthroplasty (89.2%). Antibiotic-impregnated bone cement was used in 32 (86.5%) of these procedures. Determinant factors associated with the successful direct exchange arthroplasty were infection by Gram-positive organisms, the absence of sinus formation, the aggressive debridement of all infected tissues, the use of antibiotic-impregnated bone cement for fixation of the new prosthesis, and the long-term use of antibiotic therapy⁷⁷ (GRADE score 2).

Jackson et al. performed a literature review to determine parameters related to a successful direct exchange in the treatment of infected total hip replacements. Twelve reports provided outcome data on 1299 infected hip replacements. Of these, 1077 (83%) were thought to be free of infection at the last follow-up. The average duration of follow-up was 4.8 years, but the range was broad (0.1–17.1 years). Antibiotic-impregnated bone cement was used in 1282 of the cases (99%). Determinant factors associated with a successful direct exchange included the absence of wound complications after the initial total hip replacement, good general health of the patient, methicillin-sensitive staphylococci and *Streptococcus spp*, and an organism sensitive to the antibiotic mixed into the bone cement⁷⁸ (GRADE score 2). This surgical procedure appears to offer several advantages such as lower morbidity (single surgery), shorter hospital stay, lower costs, and better functional outcome. Nevertheless, it should only be used if the following specific conditions are found: no need for a bone graft; lack of fistula; no difficult-to-treat bacteria; extensive debridement; and use of antibiotic-impregnated cement⁷⁹ (GRADE score 2). Unfortunately, only a limited number of cases meet the above-mentioned criteria making a favorable outcome with direct exchange highly probable.

Conversely, the two-stage procedure has the highest success rate usually exceeding 90%^{4,80} (GRADE score 2 for each paper). The annual relapse rate of this strategy is between 0.6% and 8.3%^{25,26,81,82} (GRADE score 3 for each paper). The prerequisites for this surgical method include adequate bone stock and minimal medical co-morbidities to allow for multiple surgical procedures² (GRADE score 2). The ideal interval between the two surgeries is not well established, but it frequently results in considerable economic hardship and morbidity. The interval usually accepted is a minimum of 6 weeks, during which antibiotic therapy is prescribed⁷⁹ (GRADE score 2). In infections with difficult-to-treat microorganisms, an interval of 6–8 weeks between removal of the first prosthesis and placement of the second, is preferable² (GRADE score 2). In addition, several others factors must be included in the evaluation of the timing of reimplantation. CRP is elevated after surgery but normalizes in 2–4 weeks⁸³ (GRADE score 3); but persistent elevation of CRP is highly suggestive of infection. The combination of a normal erythrocyte sedimentation rate and CRP level is reliable for predicting the absence of infection⁸⁴ (GRADE score 3). A cell count and culture of the aspirate should be obtained during joint aspiration.

Mont et al. determined whether aspiration of the affected joint and culture of the specimen, performed before the reimplantation and after the discontinuation of the antibiotic therapy, would help to identify patients who might have a recurrence. The authors concluded that cultures of biological samples performed after the discontinuation of the antibiotic treatment and before the

reimplantation, help to identify patients at high risk of recurrence of infection⁵⁴ (GRADE score 3). The use of antibiotics before aspiration, however, can cause false-negative results. Thus, a 4- to 6-week antibiotic wash-out before aspiration is recommended^{85,86} (GRADE score 2 for each paper).

However, it is our opinion that the antibiotic therapy should not be stopped before reimplantation. In this setting, frozen sections for diagnosing persistent infection at the time of reimplantation may be useful⁸⁶ (GRADE score 2). Histopathological examination of periprosthetic frozen tissue to detect more than five neutrophils per at least five high-power fields at a magnification of $\times 400$ has a very high sensitivity and specificity^{87–89} (GRADE scores 3, 3, and 2, respectively).

Finally, it is important to mention that the diagnostic approach may strongly influence the clinical therapeutic decision. To this regard the possibility of including a diagnostic scintigraphy with radiolabeled autologous WBC has been shown to significantly improve the specificity of diagnosis for infection and determine the time for reimplantation of prosthesis⁹⁰ (GRADE score 2).

In conclusion, a diagnostic and therapeutic algorithm was developed by our working group as shown in Figure 3.

Recommendations

We recommend the two-stage exchange procedure as the more effective treatment option. This is the first option in patients with compromised soft tissue and difficult-to-treat microorganisms. The interval between surgeries should be a minimum of 6 weeks (C).

In the case of suspicion of persistent infection before reimplantation (elevated CRP and/or positive WBC scintigraphy), a joint aspiration should also be performed and a new debridement should be planned (D).

In the case of high likelihood of sterilization (CRP persistently in the normal range and/or negative WBC scintigraphy), the surgery approach can be planned. However, during surgery it is advisable to perform an intraoperative frozen section to rule out active infection. In the case of histological evidence of infection, >5 neutrophils per at least five high-power fields at a magnification of $\times 400$ (B) and a second debridement with replacement of the spacer must be done (D).

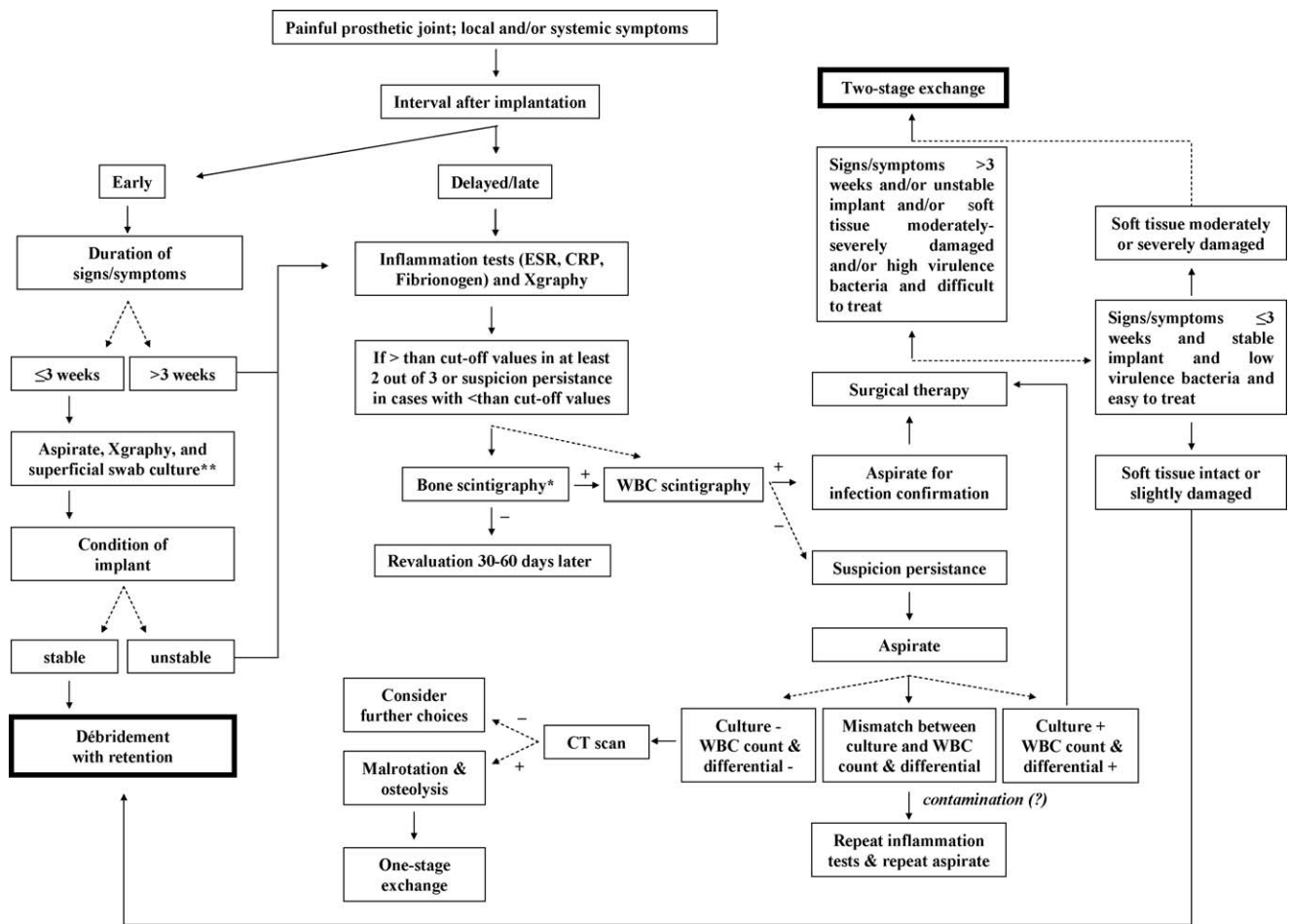
We suggest that antibiotics should not routinely be administered after the second stage surgical procedure. Nevertheless, if the histopathological examination and culture performed during the second stage surgical procedure are positive, a further surgical debridement should be performed with the same management as for early infections (D).

We recommend following the diagnostic and therapeutic algorithm developed by our working group (D).

We suggest the use of a one-stage revision only in selected circumstances with careful selection of patients as follows: no need for a bone graft; an aggressive debridement of all infected tissues; satisfactory condition of the soft tissue; absence of difficult-to-treat microorganisms; and an organism that is sensitive to the antibiotic mixed into the bone cement (C).

3.7. What is the most effective treatment for the management of prosthetic joint infections due to methicillin-resistant staphylococci?

For the third controversial issue, some limitations need to be discussed. Firstly, our revision lacks comparative studies to



* Only if long interval after implantation: >3 years for hip and >5 years for knee; ** It is useful only when *S. aureus* is identified.

Figure 3. Diagnostic and therapeutic algorithm developed by GISIG group (adapted from^{2,4,107}).

demonstrate what is the more effective treatment for the management of PJI due to methicillin-resistant staphylococci. Secondly, the use of antibiotics for the treatment of MRSA PJI is characterized by different biases. Several drugs are approved with non-specific generic indication. For example, glycopeptides are only prescribed for the treatment of serious, life-threatening infections by susceptible Gram-positive isolates that are unresponsive to other antibiotics. In contrast, some drugs are commonly prescribed for not-approved indications: off-label prescription. For example, the new antibiotics (e.g., linezolid, daptomycin) should be used to treat complicated skin and skin structure infections caused by susceptible strains. These agents are not currently approved for the management of PJI. Thirdly, our revision lacks ad hoc studies on the use of vancomycin in the management of PJI. This is paradoxical, since this antibiotic was the only therapeutic option for MRSA PJIs in the last decade, at least in the USA.

Indeed, in the available studies on the use of new antibiotics for the treatment of patients with PJIs, the majority of patients received new drugs only when vancomycin and/or teicoplanin were ineffective. In addition, only one case series on teicoplanin was included in the analysis²⁴ (GRADE score 3). Moreover, according to several author suggestions, teicoplanin can be given once daily or three times a week, which makes it a first choice for outpatient treatments (OPAT)^{91,92} (GRADE score 2 for each paper). For the treatment of bone or prosthetic infections with

this agent, a $C_{min} > 20$ mg/l should be obtained^{93–96} (GRADE scores 2, 2, 3, 2, respectively). However, these agents have some limitations. There is a growing body of evidence indicating that glycopeptide minimum inhibitory concentration (MIC) has an impact on patient outcome⁹⁷ (GRADE score 2). For example, in a retrospective cohort study, Lodise et al. showed that patients with vancomycin MICs of ≥ 1.5 mg/l had a 2.4-fold increase in failure compared to patients with MICs of ≤ 1.0 mg/l (36.4% and 15.4%, respectively; $p = 0.049$). In the Poisson regression analysis, a vancomycin MIC of ≥ 1.5 mg/l was independently associated with failure (adjusted risk ratio (ARR) 2.6, 95% CI 1.3–5.4; $p = 0.01$)⁹⁸ (GRADE score 3). Soriano et al. observed that mortality associated with MRSA bacteremia was significantly higher when the empirical antibiotic was inappropriate and when vancomycin was empirically used for the treatment of infection with strains with a high (> 1 mg/l) vancomycin MIC⁹⁹ (GRADE score 3).

Recently, a multidisciplinary consensus suggested that in severe bacterial infections caused by *S. aureus*, a total trough serum vancomycin concentration of 15–20 mg/l should be achieved. These recommendations are based on the potential to improve penetration, increase the probability of optimal target serum vancomycin concentrations, and improve clinical outcomes. Trough serum vancomycin concentrations in that range should achieve an area under the curve (AUC)/MIC ratio of ≥ 400 in most patients if the MIC is ≤ 1 mg/l. In order to achieve rapid

Table 1
Treatment options for prosthetic joint infections due to MRSA

	Parenteral agents		Oral agents ^{a,b}	
	First option	Alternative option	First option	Alternative option
Standard option for initial treatment and MIC <1 mg/l or unknown MIC	Glycopeptide	Daptomycin or linezolid	Minocycline or co-trimoxazole	Linezolid
Slow response, relapse or breakthrough MRSA bacteremia and/or MIC >1.0 mg/l	Daptomycin or linezolid	Daptomycin or linezolid	Linezolid	Co-trimoxazole or minocycline
Known MIC >1.0 mg/l of glycopeptide, and previous, optimally conducted glycopeptide therapy	Daptomycin or linezolid	Daptomycin or linezolid	Linezolid	Co-trimoxazole or minocycline

MRSA, methicillin-resistant *Staphylococcus aureus*; MIC, minimum inhibitory concentration.

Note: all drugs with or without rifampin: ^afor sequential antibiotic therapy; ^bfusidic acid not available in Italy.

attainment of this target concentration for seriously ill patients, a loading dose of 25–30 mg/kg can be considered¹⁰⁰ (GRADE score 2). However, there are increasing questions regarding the toxicity of such regimens¹⁰¹ (GRADE score 3). A targeted AUC/MIC of ≥ 400 is not achievable with conventional dosing methods if the vancomycin MIC is ≥ 2 mg/l in a patient with normal renal function. Therefore, alternative therapies should be considered. Thus, the isolates causing serious infections and failing to respond to glycopeptide therapy should certainly have their MIC checked.

In addition, glycopeptides showed a worse activity than new drugs against stationary-phase and non-dividing *S. aureus* cells that are common in persistent infections such as PJI. Moreover, the new drugs showed a good tissue penetration. In patients undergoing total hip replacement, Lovering et al. showed that linezolid rapidly penetrated into bone, fat, and muscle at the operation site, to achieve levels in excess of its MIC for susceptible organisms (≤ 4 mg/l). With the soft tissue samples, fat concentrations of linezolid at the time of operation were similar to its MIC for susceptible pathogens, whereas muscle concentrations exceeded the MIC by a factor of three or four, suggesting good penetration into the tissues surrounding the bone. This is supported by the concentrations of linezolid found in drainage from these tissues, which exceeded simultaneous blood levels for up to 12 h after dosing and were above the MIC for susceptible pathogens throughout the dosing interval¹⁰² (GRADE score 1). In addition, Rana et al. demonstrated that at steady-state, linezolid penetrates osteoarticular tissues well. Synovial fluid, synovium, muscle, and bone penetration was 91.9%, 82.1%, 83.5%, and 40.1%, respectively¹⁰³ (GRADE score 1).

There have been no clinical trials for daptomycin, although in vitro data suggest that it penetrates bone well. Recently, Rouse et al. measured the mechanical strength of daptomycin- and vancomycin-loaded polymethylmethacrylate (PMMA), and assayed in vivo release of daptomycin and vancomycin from daptomycin- and vancomycin-loaded PMMA, respectively. The authors showed that treatment with parenteral daptomycin or vancomycin for 21 days results in significantly reduced numbers of bacteria in bone surrounding the infection site in a rat model of experimental osteomyelitis¹⁰⁴ (GRADE score 1). Previously, the same authors have shown that daptomycin is released from PMMA in a continuous flow chamber at a rate similar to that of vancomycin¹⁰⁵ (GRADE score 1). Finally, the ideal dose of daptomycin has not well established. On this point, Lamp et al. observed that the clinical success rate for patients affected by osteomyelitis and orthopedic device infections treated with an initial daptomycin dose ≥ 4 mg/kg was significantly higher than for patients treated with an initial dose ≤ 4 mg/kg (88% vs. 65%; $p = 0.013$)¹⁰⁶ (GRADE score 2).

In conclusion, the new antimicrobial options offer potential alternatives to glycopeptides (Table 1).

Recommendations

There is no evidence that any single agent or combination of agents is superior to the other (D).

We suggest that glycopeptides are the mainstay of treatment for MRSA PJIs. The first-line use of glycopeptides with other adjunctive agents such as rifampin is endorsed. Vancomycin and teicoplanin should achieve trough levels >15 mg/l and >20 mg/l, respectively. An increase in the nephrotoxicity is a likely risk with the use of higher dosages (C).

In the setting where a high (>1 mg/l) vancomycin MIC is reported, we suggest the use of the new antimicrobial options alternative to glycopeptides (D).

In the case of treatment with linezolid or daptomycin for the treatment of MRSA PJI, we recommend dosages of 600 mg twice daily and at least 6 mg/kg once daily, respectively (A and C, respectively).

There are no data demonstrating the need/possibility of different durations of treatment with new antimicrobial agents (D).

Acknowledgement

The GISIG Consensus Conference was organized with support from an unrestricted educational grant from Pfizer.

We wish to thank Tom Jefferson for sharing his expertise and ideas with us.

Conflict of interest

All members of the faculty of GISIG – A. d'Arminio Monforte, S. Borrè, G. Carosi, G. Ippolito, F.N. Lauria, S. Leone, G. Mordente, M. Moroni, E. Nicastrì, N. Petrosillo, A. Signore, M. Venditti, and P. Viale – report no other potential conflict of interest except as reported in the specific section.

The members of the working group have no specific conflict of interest to report.

Funding

For the present research, except for A. d'Arminio Monforte, all members of the faculty of GISIG received a fee from the organizing secretariat of the GISIG Project. The members of the working group have no funding to report.

Additional Conflict of interest

G. Ippolito and F.N. Lauria have received expert opinion fees from Pfizer. E. Nicastrì has received paid expert opinion from MSD and Pfizer. N. Petrosillo has received honoraria as speaker from

Wyeth, GlaxoSmithKline, Pfizer, Merck Sharp & Dohme, Novartis, Janssen Cilag, Astellas, and sanofi-aventis. M. Venditti received honoraria as a speaker at congresses from Pfizer, Wyeth, Gilead, Aventis, Merck Sharp & Dohme, Angelini, Glaxo, Bayer, Novartis in the last three years. Conflict of interest for P. Viale: Novartis, sanofi-aventis, MSD, Astellas, Gilead, Pfizer, Astra-Zeneca.

References

- Zimmerli W. Infection and musculoskeletal conditions: prosthetic joint-associated infections. *Best Pract Res Clin Rheumatol* 2006;**20**:1045–63.
- Zimmerli W, Trampuz A, Ochsner PE. Prosthetic-joint infections. *N Engl J Med* 2004;**351**:1645–54.
- Anguita-Alonso P, Hanssen AD, Patel R. Prosthetic joint infection. *Expert Rev Anti Infect Ther* 2005;**3**:797–804.
- Zimmerli W, Ochsner PE. Management of infection associated with prosthetic joints. *Infection* 2003;**31**:99–108.
- Berbari EF, Hanssen AD, Duffy MC, Steckelberg JM, Ilstrup DM, Harmsen WS, et al. Risk factors for prosthetic joint infection: case-control study. *Clin Infect Dis* 1998;**27**:1247–54.
- Barberán J. Management of infections of osteoarticular prosthesis. *Clin Microbiol Infect* 2006;**12**(Suppl 3):93–101.
- Hoekman P, van de Perre P, Nelissen J, Kwisanga B, Bogaerts J, Kanyangabo F. Increased frequency of infection after open reduction of fractures in patients who are seropositive for human immunodeficiency virus. *J Bone Joint Surg Am* 1991;**73**:675–9.
- Harrison WJ, Lewis CP, Lavy CB. Wound healing after implant surgery in HIV-positive patients. *J Bone Joint Surg Br* 2002;**84**:802–6.
- Widmer AF. New developments in diagnosis and treatment of infection in orthopedic implants. *Clin Infect Dis* 2001;**33**(Suppl 2):94–106.
- Marculescu CE, Cantej JR. Polymicrobial prosthetic joint infections: risk factors and outcome. *Clin Orthop Relat Res* 2008;**466**:1397–404.
- Marculescu CE, Berbari EF, Cockerill 3rd FR, Osmon DR. Fungi, mycobacteria, zoonotic and other organisms in prosthetic joint infection. *Clin Orthop Relat Res* 2006;**451**:64–72.
- Marculescu CE, Berbari EF, Cockerill 3rd FR, Osmon DR. Unusual aerobic and anaerobic bacteria associated with prosthetic joint infections. *Clin Orthop Relat Res* 2006;**451**:55–63.
- Berbari EF, Marculescu C, Sia I, Lahr BD, Hanssen AD, Steckelberg JM, et al. Culture-negative prosthetic joint infection. *Clin Infect Dis* 2007;**45**:1113–9.
- Salgado CD, Dash S, Cantej JR, Marculescu CE. Higher risk of failure of methicillin-resistant *Staphylococcus aureus* prosthetic joint infections. *Clin Orthop Relat Res* 2007;**461**:48–53.
- Lauria FN, De Carli G, Nicastri E. Resistant and multi-resistant Gram-positive severe infections: the GISIG working methodology. *Int J Infect Dis* 2010;**14**:S13–7.
- Betsch BY, Eggl S, Siebenrock KA, Täuber MG, Mühlemann K. Treatment of joint prosthesis infection in accordance with current recommendations improves outcome. *Clin Infect Dis* 2008;**46**:1221–6.
- Giulieri SG, Graber P, Ochsner PE, Zimmerli W. Management of infection associated with total hip arthroplasty according to a treatment algorithm. *Infection* 2004;**32**:222–8.
- Laffer RR, Graber P, Ochsner PE, Zimmerli W. Outcome of prosthetic knee-associated infection: evaluation of 40 consecutive episodes at a single centre. *Clin Microbiol Infect* 2006;**12**:433–9.
- Kösters K, van Crevel R, Sturm PD, Willem Schreurs B, de Waal Malefijt MC, van Kampen A, et al. Treatment of knee prosthesis infections: evaluation of 15 patients over a 5-year period. *Int Orthop* 2009;**33**:1249–54.
- Chiu FY, Chen CM. Surgical debridement and parenteral antibiotics in infected revision total knee arthroplasty. *Clin Orthop Relat Res* 2007;**461**:130–5.
- Theis JC, Gambhir S, White J. Factors affecting implant retention in infected joint replacements. *ANZ J Surg* 2007;**77**:877–9.
- Tsumura H, Ikeda S, Ono T, Itonaga I, Taira H, Torisu T. Synovectomy, debridement, and continuous irrigation for infected total knee arthroplasty. *Int Orthop* 2005;**29**:113–6.
- Trebse R, Piset V, Trampuz A. Treatment of infected retained implants. *J Bone Joint Surg Br* 2005;**87**:249–56.
- Pavoni GL, Giannella M, Falcone M, Scorzoloni L, Liberatore M, Carlesimo B, et al. Conservative medical therapy of prosthetic joint infections: retrospective analysis of an 8-year experience. *Clin Microbiol Infect* 2004;**10**:831–7.
- Segawa H, Tsukayama DT, Kyle RF, Becker DA, Gustilo RB. Infection after total knee arthroplasty. A retrospective study of the treatment of eighty-one infections. *J Bone Joint Surg Am* 1999;**81**:1434–45.
- Tattevin P, Crémieux AC, Pottier P, Hutten D, Carbon C. Prosthetic joint infection: when can prosthesis salvage be considered? *Clin Infect Dis* 1999;**29**:292–5.
- Crockarell JR, Hanssen AD, Osmon DR, Morrey BF. Treatment of infection with debridement and retention of the components following hip arthroplasty. *J Bone Joint Surg Am* 1998;**80**:1306–13.
- Rasul Jr AT, Tsukayama D, Gustilo RB. Effect of time of onset and depth of infection on the outcome of total knee arthroplasty infections. *Clin Orthop Relat Res* 1991;**273**:98–104.
- Teeny SM, Dorr L, Murata G, Conaty P. Treatment of infected total knee arthroplasty. Irrigation and debridement versus two-stage reimplantation. *J Arthroplasty* 1990;**5**:35–9.
- Segreti J, Nelson JA, Trenholme GM. Prolonged suppressive antibiotic therapy for infected orthopedic prostheses. *Clin Infect Dis* 1998;**27**:711–3.
- Rao N, Crossett LS, Sinha RK, Le Frock JL. Long-term suppression of infection in total joint arthroplasty. *Clin Orthop Relat Res* 2003;(414):55–60.
- Berbari EF, Osmon DR, Duffy MC, Harmsen RN, Mandrekar JN, Hanssen AD, et al. Outcome of prosthetic joint infection in patients with rheumatoid arthritis: the impact of medical and surgical therapy in 200 episodes. *Clin Infect Dis* 2006;**42**:216–23.
- Marculescu CE, Berbari EF, Hanssen AD, Steckelberg JM, Harmsen SW, Mandrekar JN, et al. Outcome of prosthetic joint infections treated with debridement and retention of components. *Clin Infect Dis* 2006;**42**:471–8.
- Zimmerli W, Widmer AF, Blatter M, Frei R, Ochsner PE. Role of rifampin for treatment of orthopedic implant-related staphylococcal infections: a randomized controlled trial. Foreign-Body Infection (FBI) Study Group. *JAMA* 1998;**279**:1537–41.
- Berdal JE, Skråmm I, Mowinckel P, Gulbrandsen P, Bjørnhoft JV. Use of rifampicin and ciprofloxacin combination therapy after surgical debridement in the treatment of early manifestation prosthetic joint infections. *Clin Microbiol Infect* 2005;**11**:843–5.
- Soriano A, García S, Bori G, Almela M, Gallart X, Macule F, et al. Treatment of acute post-surgical infection of joint arthroplasty. *Clin Microbiol Infect* 2006;**12**:930–3.
- Barberán J, Aguilar L, Carroquino G, Giménez MJ, Sánchez B, Martínez D, et al. Conservative treatment of staphylococcal prosthetic joint infections in elderly patients. *Am J Med* 2006;**119**:993e7–10.
- Choong PF, Dowsey MM, Carr D, Daffy J, Stanley P. Risk factors associated with acute hip prosthetic joint infections and outcome of treatment with a rifampin based regimen. *Acta Orthop* 2007;**78**:755–65.
- Aboltins CA, Page MA, Busing KL, Jenney AW, Daffy JR, Choong PF, et al. Treatment of staphylococcal prosthetic joint infections with debridement, prosthesis retention and oral rifampicin and fusidic acid. *Clin Microbiol Infect* 2007;**13**:586–91.
- Soriano A, Gómez J, Azanza JR, Pérez R, Romero F, Pons M, et al. Efficacy and tolerability of prolonged linezolid therapy in the treatment of orthopedic implant infections. *Eur J Clin Microbiol Infect Dis* 2007;**26**:353–6.
- Deirmengian C, Greenbaum J, Lotke PA, Booth Jr RE, Lonner JH. Limited success with open debridement and retention of components in the treatment of acute *Staphylococcus aureus* infections after total knee arthroplasty. *J Arthroplasty* 2003;**18**(Suppl 1):22–6.
- Everts RJ, Chambers ST, Murdoch DR, Rothwell AG, McKie J. Successful antimicrobial therapy and implant retention for streptococcal infection of prosthetic joints. *ANZ J Surg* 2004;**74**:210–4.
- Meehan AM, Osmon DR, Duffy MC, Hanssen AD, Keating MR. Outcome of penicillin-susceptible streptococcal prosthetic joint infection treated with debridement and retention of the prosthesis. *Clin Infect Dis* 2003;**36**:845–9.
- Waldman BJ, Hostin E, Mont MA, Hungerford DS. Infected total knee arthroplasty treated by arthroscopic irrigation and debridement. *J Arthroplasty* 2000;**15**:430–6.
- Dixon P, Parish EN, Cross MJ. Arthroscopic debridement in the treatment of the infected total knee replacement. *J Bone Joint Surg Br* 2004;**86**:39–42.
- Pagnano MW, Trousdale RT, Hanssen AD. Outcome after reinfection following reimplantation hip arthroplasty. *Clin Orthop Relat Res* 1997;**338**:192–204.
- Ure KJ, Amstutz HC, Nasser S, Schmalzried TP. Direct-exchange arthroplasty for the treatment of infection after total hip replacement. An average ten-year follow-up. *J Bone Joint Surg Am* 1998;**80**:961–8.
- Callaghan JJ, Katz RP, Johnston RC. One-stage revision surgery of the infected hip. A minimum 10-year follow-up study. *Clin Orthop Relat Res* 1999;**369**:139–43.
- Buechel FF, Femino FP, D'Alessio J. Primary exchange revision arthroplasty for infected total knee replacement: a long-term study. *Am J Orthop* 2004;**33**:190–8.
- Winkler H, Stoiber A, Kaudela K, Winter F, Menschik F. One stage uncemented revision of infected total hip replacement using cancellous allograft bone impregnated with antibiotics. *J Bone Joint Surg Br* 2008;**90**:1580–4.
- Hirakawa K, Stulberg BN, Wilde AH, Bauer TW, Secic M. Results of 2-stage reimplantation for infected total knee arthroplasty. *J Arthroplasty* 1998;**13**:22–8.
- Fehring TK, Calton TF, Griffin WL. Cementless fixation in 2-stage reimplantation for periprosthetic sepsis. *J Arthroplasty* 1999;**14**:175–81.
- Haddad FS, Muirhead-Allwood SK, Manktelow AR, Bacarese-Hamilton I. Two-stage uncemented revision hip arthroplasty for infection. *J Bone Joint Surg Br* 2000;**82**:689–94.
- Mont MA, Waldman BJ, Hungerford DS. Evaluation of preoperative cultures before second-stage reimplantation of a total knee prosthesis complicated by infection. A comparison-group study. *J Bone Joint Surg Am* 2000;**82**:1552–7.
- Karpas K, Sporer P. Management of the infected hip arthroplasty by two-stage reimplantation. *Acta Medica* 2003;**46**:113–5.
- Stein A, Bataille JF, Drancourt M, Curvale G, Argenson JN, Groulier P, et al. Ambulatory treatment of multidrug-resistant *Staphylococcus*-infected orthopaedic implants with high-dose oral co-trimoxazole (trimethoprim-sulfamethoxazole). *Antimicrob Agents Chemother* 1998;**42**:3086–91.
- Drancourt M, Stein A, Argenson JN, Roiron R, Groulier P, Raoult D. Oral treatment of *Staphylococcus spp* infected orthopaedic implants with fusidic acid or ofloxacin in combination with rifampicin. *J Antimicrob Chemother* 1997;**39**:235–40.

58. Bassetti M, Di Biagio A, Cenderello G, Del Bono V, Palermo A, Cruciani M, et al. Linezolid treatment of prosthetic hip infections due to methicillin-resistant *Staphylococcus aureus* (MRSA). *J Infect* 2001;**43**:148–9.
59. Jover-Sáenz A, Gaité FB, Ribelles AG, Porcel-Pérez JM, Garrido-Calvo S. Linezolid treatment of total prosthetic knee infection due to methicillin-resistant *Staphylococcus epidermidis*. *J Infect* 2003;**47**:87–8.
60. Rao N, Ziran BH, Hall RA, Santa ER. Successful treatment of chronic bone and joint infections with oral linezolid. *Clin Orthop Relat Res* 2004;**427**:67–71.
61. Razonable RR, Osmon DR, Steckelberg JM. Linezolid therapy for orthopedic infections. *Mayo Clin Proc* 2004;**79**:1137–44.
62. Bassetti M, Vitale F, Melica G, Righi E, Di Biagio A, Molfetta L, et al. Linezolid in the treatment of Gram-positive prosthetic joint infections. *J Antimicrob Chemother* 2005;**55**:387–90.
63. Rao N, Hamilton CW. Efficacy and safety of linezolid for Gram-positive orthopedic infections: a prospective case series. *Diagn Microbiol Infect Dis* 2007;**59**:173–9.
64. Finney MS, Crank CW, Segreti J. Use of daptomycin to treat drug-resistant Gram-positive bone and joint infections. *Curr Med Res Opin* 2005;**21**:1923–6.
65. Rao N, Regalla DM. Uncertain efficacy of daptomycin for prosthetic joint infections: a prospective case series. *Clin Orthop Relat Res* 2006;**451**:34–7.
66. Antony SJ. Combination therapy with daptomycin, vancomycin, and rifampin for recurrent, severe bone and prosthetic joint infections involving methicillin-resistant *Staphylococcus aureus*. *Scand J Infect Dis* 2006;**38**:293–5.
67. Burns CA. Daptomycin–rifampin for a recurrent MRSA joint infection unresponsive to vancomycin-based therapy. *Scand J Infect Dis* 2006;**38**:133–6.
68. Antony SJ, Angelos E, Stratton CW. Clinical experience with daptomycin in patients with orthopedic-related infections. *Infect Dis Clin Pract* 2006;**14**:144–9.
69. Carlyn CJ, Baltch AL, George MJ, Smith RP. Daptomycin in the treatment of persistent bacteremia with invasive complications caused by small colony variant of methicillin-resistant *Staphylococcus aureus* in an orthopaedic patient. *Infect Dis Clin Pract* 2006;**14**:394–8.
70. Drew RH, Perfect JR, Srinath L, Kurkumil E, Dowzicky M, Talbot GH. Treatment of methicillin-resistant *Staphylococcus aureus* infections with quinupristin–dalfopristin in patients intolerant of or failing prior therapy. For the Synercid Emergency-Use Study Group. *J Antimicrob Chemother* 2000;**46**:775–84.
71. Perlröth J, Kuo M, Tan J, Bayer AS, Miller LG. Adjunctive use of rifampin for the treatment of *Staphylococcus aureus* infections: a systematic review of the literature. *Arch Intern Med* 2008;**168**:805–19.
72. Diekema DJ, Pfaller MA, Schmitz FJ, Smayevsky J, Bell J, Jones RN, et al. Survey of infections due to *Staphylococcus* species: frequency of occurrence and antimicrobial susceptibility of isolates collected in the United States, Canada, Latin America, Europe, and the Western Pacific region for the SENTRY Antimicrobial Surveillance Program, 1997–1999. *Clin Infect Dis* 2001;**32**(Suppl 2):114–32.
73. Raad I, Hanna H, Jiang Y, Dvorak T, Reitzel R, Chaiban G, et al. Comparative activities of daptomycin, linezolid, and tigecycline against catheter-related methicillin-resistant *Staphylococcus* bacteremic isolates embedded in biofilm. *Antimicrob Agents Chemother* 2007;**51**:1656–60.
74. Baldoni D, Haschke M, Rajacic Z, Zimmerli W, Trampuz A. Linezolid alone or combined with rifampin against methicillin-resistant *Staphylococcus aureus* in experimental foreign-body infection. *Antimicrob Agents Chemother* 2009;**53**:1142–8.
75. Gebhart BC, Barker BC, Markewitz BA. Decreased serum linezolid levels in a critically ill patient receiving concomitant linezolid and rifampin. *Pharmacotherapy* 2007;**27**:476–9.
76. John AK, Baldoni D, Haschke M, Rentsch K, Schaerli P, Zimmerli W, et al. Efficacy of daptomycin in implant-associated infection due to methicillin-resistant *Staphylococcus aureus*: importance of combination with rifampin. *Antimicrob Agents Chemother* 2009;**53**:2719–24.
77. Silva M, Tharani R, Schmalzried TP. Results of direct exchange or debridement of the infected total knee arthroplasty. *Clin Orthop Relat Res* 2002;**404**:125–31.
78. Jackson WO, Schmalzried TP. Limited role of direct exchange arthroplasty in the treatment of infected total hip replacements. *Clin Orthop Relat Res* 2000;**381**:101–5.
79. Bernard L, Hoffmeyer P, Assal M, Vaudaux P, Schrenzel J, Lew D. Trends in the treatment of orthopaedic prosthetic infections. *J Antimicrob Chemother* 2004;**53**:127–9.
80. Langlais F. Can we improve the results of revision arthroplasty for infected total hip replacement? *J Bone Joint Surg Br* 2003;**85**:637–40.
81. Tsukayama DT, Estrada R, Gustilo RB. Infection after total hip arthroplasty. A study of the treatment of one hundred and six infections. *J Bone Joint Surg Am* 1996;**78**:512–23.
82. Brandt CM, Sistrunk WW, Duffy MC, Hanssen AD, Steckelberg JM, Ilstrup DM, et al. *Staphylococcus aureus* prosthetic joint infection treated with debridement and prosthesis retention. *Clin Infect Dis* 1997;**24**:914–9.
83. Niskanen RO, Korkala O, Pammo H. Serum C-reactive protein levels after total hip and knee arthroplasty. *J Bone Joint Surg Br* 1996;**78**:431–3.
84. Spangehl MJ, Masri BA, O'Connell JX, Duncan CP. Prospective analysis of preoperative and intraoperative investigations for the diagnosis of infection at the sites of two hundred and two revision total hip arthroplasties. *J Bone Joint Surg Am* 1999;**81**:672–83.
85. Barrack RL, Jennings RW, Wolfe MW, Bertot AJ. The Coventry Award. The value of preoperative aspiration before total knee revision. *Clin Orthop Relat Res* 1997;**345**:8–16.
86. Burnett RS, Kelly MA, Hanssen AD, Barrack RL. Technique and timing of two-stage exchange for infection in TKA. *Clin Orthop Relat Res* 2007;**464**:164–78.
87. Della Valle CJ, Bogner E, Desai P, Lonner JH, Adler E, Zuckerman JD, et al. Analysis of frozen sections of intraoperative specimens obtained at the time of reoperation after hip or knee resection arthroplasty for the treatment of infection. *J Bone Joint Surg Am* 1999;**81**:684–9.
88. Athanasou NA, Pandey R, de Steiger R, Crook D, Smith PM. Diagnosis of infection by frozen section during revision arthroplasty. *J Bone Joint Surg Br* 1995;**77**:28–33.
89. Trampuz A, Hanssen AD, Osmon DR, Mandrekas J, Steckelberg JM, Patel R. Advances in the laboratory diagnosis of prosthetic joint infection. *Rev Med Microbiol* 2003;**14**:1–14.
90. Prandini N, Lazzeri E, Rossi B, Erba P, Parisella MG, Signore A. Nuclear medicine imaging of bone infections. *Nucl Med Commun* 2006;**27**:633–44.
91. Esposito S, Leone S, Noviello S, Ianniello F, Fiore M, Russo M, et al. Outpatient parenteral antibiotic therapy for bone and joint infections: an Italian multicenter study. *J Chemother* 2007;**19**:417–22.
92. Rouveix B, Jehl F, Drugeon H, Brumpt I, Caulin E. Randomized comparison of serum teicoplanin concentrations following daily or alternate daily dosing in healthy adults. *Antimicrob Agents Chemother* 2004;**48**:2394–9.
93. Wilson AP, Grüneberg RN, Neu H. Dosage recommendations for teicoplanin. *J Antimicrob Chemother* 1993;**32**:792–6.
94. Schaison G, Graninger W, Bouza E. Teicoplanin in the treatment of serious infection. *J Chemother* 2000;**12**(Suppl 5):26–33.
95. Pea F, Viale P, Pavan F, Tavio M, Poz D, Beltrame A, et al. The effect of multifactorial, multidisciplinary educational interventions on appropriate use of teicoplanin. *Int J Antimicrob Agents* 2006;**27**:344–50.
96. Garau J, Bouza E, Chastre J, Gudiol F, Harbarth S. Management of methicillin-resistant *Staphylococcus aureus* infections. *Clin Microbiol Infect* 2009;**15**:125–36.
97. Gould IM. The problem with glycopeptides. *Int J Antimicrob Agents* 2007;**30**:1–3.
98. Lodise TP, Graves J, Evans A, Graffunder E, Helmecke M, Lomaestro BM, et al. Relationship between vancomycin MIC and failure among patients with methicillin-resistant *Staphylococcus aureus* bacteremia treated with vancomycin. *Antimicrob Agents Chemother* 2008;**52**:3315–20.
99. Soriano A, Marco F, Martínez JA, Pisos E, Almela M, Dimova VP, et al. Influence of vancomycin minimum inhibitory concentration on the treatment of methicillin-resistant *Staphylococcus aureus* bacteremia. *Clin Infect Dis* 2008;**46**:193–200.
100. Rybak M, Lomaestro B, Rotschafer JC, Moellering Jr R, Craig W, Billeter M, et al. Therapeutic monitoring of vancomycin in adult patients: a consensus review of the American Society of Health-System Pharmacists, the Infectious Diseases Society of America, and the Society of Infectious Diseases Pharmacists. *Am J Health Syst Pharm* 2009;**66**:82–98.
101. Hidayat LK, Hsu DI, Quist R, Shriner KA, Wong-Beringer A. High-dose vancomycin therapy for methicillin-resistant *S. aureus* infections: efficacy and toxicity. *Arch Intern Med* 2006;**166**:2138–44.
102. Lovering AM, Zhang J, Bannister GC, Lankester BJ, Brown JH, Narendra G, et al. Penetration of linezolid into bone, fat, muscle and haematoma of patients undergoing routine hip replacement. *J Antimicrob Chemother* 2002;**50**:73–7.
103. Rana B, Butcher I, Grigoris P, Murnaghan C, Seaton RA, Tobin CM. Linezolid penetration into osteo-articular tissues. *J Antimicrob Chemother* 2002;**50**:747–50.
104. Rouse MS, Piper KE, Jacobson M, Jacofsky DJ, Steckelberg JM, Patel R. Daptomycin treatment of *Staphylococcus aureus* experimental chronic osteomyelitis. *J Antimicrob Chemother* 2006;**57**:301–5.
105. Hall EW, Rouse MS, Jacofsky DJ, Osmon DR, Hanssen AD, Steckelberg JM, et al. Release of daptomycin from polymethylmethacrylate beads in a continuous flow chamber. *Diagn Microbiol Infect Dis* 2004;**50**:261–5.
106. Lamp KC, Friedrich LV, Mendez-Vigo L, Russo R. Clinical experience with daptomycin for the treatment of patients with osteomyelitis. *Am J Med* 2007;**120**:13–20.
107. Savarino L, Tigani D, Baldini N, Bochicchio V, Giunti A. Pre-operative diagnosis of infection in total knee arthroplasty: an algorithm. *Knee Surg Sports Traumatol Arthrosc* 2009;**17**:667–75.